



RBO

REVISTA BRASILEIRA DE ORTOPEDIA

www.rbo.org.br/



Original Article

Treatment of complex acute proximal humerus fractures using hemiarthroplasty

Bruno Lobo Brandão,^{1*} Marcus Vinicius Galvão Amaral,² Marcio Cohen,²
Rickson Guedes de Moraes Correia,² Carlos Henrique Gazineu Abdenur,³
Martim Teixeira Monteiro,⁴ Geraldo Rocha Motta Filho⁵

¹MSc in Medicine from the Department of Orthopedics and Traumatology, Universidade Federal do Rio de Janeiro (UFRJ). Attending Physician, Shoulder and Elbow Surgery Center, National Institute for Traumatology and Orthopedics (INTO), Rio de Janeiro, RJ, Brazil.

²Attending Physician, Shoulder and Elbow Surgery Center, National Institute for Traumatology and Orthopedics (INTO), Rio de Janeiro, RJ, Brazil.

³Trainee (2010-2011), Shoulder and Elbow Surgery Center, National Institute for Traumatology and Orthopedics (INTO), Rio de Janeiro, RJ, Brazil.

⁴Head of the Shoulder and Elbow Surgery Center, National Institute for Traumatology and Orthopedics (INTO), Rio de Janeiro, RJ, Brazil.

⁵MSc in Medicine from the Department of Orthopedics and Traumatology, Universidade Federal de São Paulo (UNIFESP/EPM), São Paulo, SP.

Attending Physician, Shoulder and Elbow Surgery Center, National Institute for Traumatology and Orthopedics (INTO), Rio de Janeiro, RJ, Brazil.

Work performed at the National Institute for Traumatology and Orthopedics (INTO), Rio de Janeiro, RJ, Brazil.

ARTICLE INFO

Article history:

Received April 22 2012

Approved July 23 2012

Keywords:

Shoulder

Arthroplasty

Humeral fractures

A B S T R A C T

Objective: Evaluate the clinical and radiological results of hemiarthroplasty for treatment of complex proximal humerus fractures. **Methods:** Sixty-seven patients were included, with follow-up of 12 to 62 months. Mean age was 65 years (44 to 88), and 47 patients were female (70%). Clinical assessment was performed using the University of California Los Angeles score (UCLA) and measurement of range of motion (ROM) according to the American Academy of Orthopaedic Surgeons criteria. A standardized radiological evaluation was conducted, with special attention to healing and position of tuberosities. Patients were divided into two groups: A (anatomical healing of tuberosities) and B (without anatomical healing of tuberosities). Statistical analyses were performed using the t test. Level of significance was set at $p < 0.05$. **Results:** Considering the entire sample, the mean UCLA score was 26 points, with 8 points for pain and 64 patients subjectively satisfied (96%). The mean values for active ROM were 104° of forward flexion and 36° of external rotation. In group A, with 33 patients, we found a mean of 122° forward flexion and 29.5 points on UCLA. In group B the mean forward flexion were 87° and 22.7 points for UCLA. Comparing these parameters in the two groups, we found statistically significant differences for both forward flexion ($p < 0.0001$) and UCLA ($p < 0.0001$). **Conclusion:** We conclude that hemiarthroplasty for treatment of complex proximal humerus fractures has a low incidence of complications and a high subjective satisfaction rate, with favorable results related to pain. A good functional result is less predictable and depends on anatomical reestablishment of proximal humerus anatomy, particularly healing of the greater tuberosity.

© 2013 Sociedade Brasileira de Ortopedia e Traumatologia. Published by Elsevier Editora Ltda. All rights reserved.

*Corresponding author at: Rua Maria Angélica 146/802, Lagoa, Rio de Janeiro, Brazil. CEP: 22470-202.

E-mail: brunolobobrandao@yahoo.com.br.

Introduction

Fractures of the proximal extremity of the humerus in adults account for approximately 5% of all fractures.¹ They are more frequent in elderly people, resulting from low-energy trauma, and are especially common in postmenopausal women because of osteoporosis, in proportions of 2:1.^{1,2} The main mechanism consists of falling from a standing position, onto the extended hand. These fractures may also occur in a younger population when associated with high-energy trauma, such as in a car accident.²

Most of these fractures are classified as minimally displaced or in two parts, and nonoperative treatment or osteosynthesis (when there is significant deviation of the fragments) presents a very favorable prognosis.³ On the other hand, these satisfactory results are not so easily obtained in cases of injuries of greater severity, i.e. complex fractures of the proximal extremity of the humerus. This group can include fractures in three or four parts, fractures affecting the joint surface of the humeral head (of "head split" type) and fractures with dislocation.³ In these cases, osteosynthesis is not always possible, due to bone fragmentation and osteopenia, as well as the risk of avascular necrosis caused by impairment of the vascular supply to the humeral head.^{3,4} Depending on the severity of the lesion and the patient's age, arthroplastic treatment may be the best indication.

Use of hemiarthroplasty for treating complex fractures of the proximal humerus was popularized in the 1970s by Neer, who reported excellent results in around 90% of the patients.⁵ Since then, this technique has been widely used around the world, but most of the results published by Neer could not be reproduced in subsequent studies.⁶⁻¹⁰ In a general manner, the reports in the literature show that the patients are satisfied, with a pain-free shoulder, but that they do not present adequate functional recovery, especially because of their limited active elevation⁶⁻²³ (Figure 1).

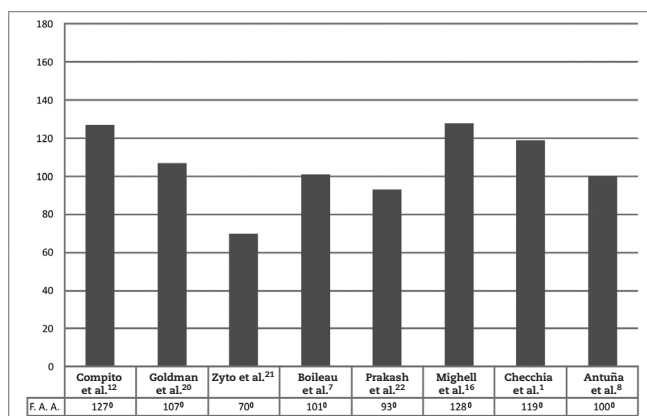


Fig. 1 - Variation in active anterior flexion according to different authors.

The aim of the present study was to evaluate the clinical and radiographic results from patients who underwent hemiarthroplasty of the shoulder for treatment of complex acute fractures of the proximal extremity of the humerus, with operations performed at the Shoulder and Elbow Surgery Center of the National Institute for Traumatology and Orthopedics (INTO).

Material and methods

This study consisted of a retrospective analysis that used the accumulated data in our register of shoulder arthroplasty cases. We analyzed all the patients who consecutively underwent hemiarthroplasty at the Shoulder and Elbow Surgery Center of the National Institute for Traumatology and Orthopedics (INTO) for treatment of acute fractures of the proximal extremity of the humerus, between July 2004 and March 2009. All the fractures were evaluated in accordance with the classification of Neer⁴ and only complex fractures were found, i.e. fractures in three or four parts, dislocated fractures or fractures that affected the joint surface (head split type). The exclusion criteria were that the fractures should not have evolved for more than six weeks and the patients should not present previous disease in the shoulder operated or outpatient follow-up of less than 12 months. Cases were also excluded if the data available regarding the clinical or radiographic evaluations of the postoperative follow-up were insufficient.

Out of the 97 patients, 67 fulfilled the inclusion criteria. The mean length of follow-up was 38 months, with a range from 12 to 62 months. The mean age was 65 years (range: 44 to 88), and 47 patients were female (70%). The right side was affected in 39 patients (58%) and the left side in 28 (42%). In accordance with Neer, 46 fractures were classified as being in four parts, 18 as being in three parts, 19 as associated with anterior dislocation and three as associated with posterior dislocation. The commonest trauma mechanism consisted of falling from a standing position, which affected 59 patients (88%). The remainder of the fractures were related to higher-energy trauma, such as car accidents and convulsive crises. The mean interval between the trauma and the surgical treatment was 18 days, with a range from three to 40 days.

All the patients were operated in the deckchair position, through a deltopectoral access, without deinsertion of the deltoid. Tenodesis of the tendon of the long head of the biceps was performed routinely at the humeral insertion of the pectoralis major muscle. The Global FX prosthesis (DePuy, Warsaw, Indiana, USA) was used in all the cases, with use of bone cement on the diaphysis and placement of a cemented plastic restrictor in the humeral canal. To position the humeral component, we used an instrument called a positioning jig, which maintained provisional fixation of the test prosthesis on the diaphysis and thus enabled greater precision and security with regard to assessing the height and retroversion established by the surgeon (Fig. 2). This guide also allowed reproduction of these parameters during cementation of the definitive prosthesis.



Fig. 2 - Positioning of the test prosthesis using the positioning jig.

After cementation, the tubercles were fixed using No. 5 non-absorbable polyester thread, by means of orifices in the diaphysis, with fixation to the fins of the prosthesis, fixation between the tubercles and circumferential fixation around the neck of the prosthesis and circumferential fixation around the neck of the prosthesis (“around the world”). In this manner, approximately six threads were used for fixation in the horizontal and vertical planes (Fig. 3). In all cases, an autologous bone graft from the humeral head was used, between the tubercles and the diaphysis. Perioperative control radiographs were performed routinely, with the aim of confirming the positioning of the prosthesis and the tubercles.

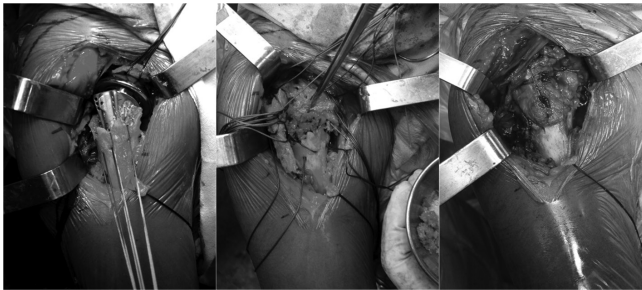


Fig. 3 - Sequence showing the binding of the tubercles, associated with bone grafting.

After the operation, the patients were kept using slings for six weeks. After the first week, pendular exercises and passive anterior flexion exercises were started. Active exercises were started after the sixth week, while strengthening exercises were started after 12 weeks. It has to be noted that, unfortunately, because many patients lived far from our hospital and had transportation difficulties, they were unable to do the physiotherapy treatment at our hospital.

For this reason, monitoring the protocol that was used for the rehabilitation was more difficult. The patients underwent postoperative clinical-functional and radiographic evaluations at the Shoulder and Elbow Center of INTO. The active and passive ranges of motion were measured using a goniometer, in accordance with the criteria of the *American Academy of Orthopaedic Surgeons (AAOS)*.²⁴ The functional assessment was performed by means of the UCLA score.²⁵ Patients with scores greater than 33 points were considered to present excellent results; scores between 28 and 33 were good; scores between 21 and 27 were fair; and scores of 20 or below were poor.

The radiographic evaluation was performed by means of the true AP view, scapular lateral view and axillary lateral view. The positioning and consolidation of the tubercles were observed, along with the positioning of the prosthesis and the quality of cementation. To evaluate the position of the greater tubercle on the AP radiograph, we used the method described by Boileau et al.⁷ A line was traced out perpendicularly to the longitudinal axis of the humeral shaft, tangential to the apex of the cephalic component of the prosthesis, and another line tangential to the uppermost region of the greater tubercle. The distance between these two parallel lines was then measured (Fig. 4). Taking into consideration the parameters determined in previous anatomical studies,²⁶ we defined that the greater tubercle was correctly positioned when its apex was located between 5 and 10 mm below the apex of the prosthesis. In accordance with this radiographic evaluation, the patients were divided into two groups. Group A included the patients who presented anatomical consolidation of the tubercles and group B included the patients who could not be included in group A, i.e. those with pseudarthrosis or skewed consolidation, or cases in which reabsorption of the tubercles occurred.

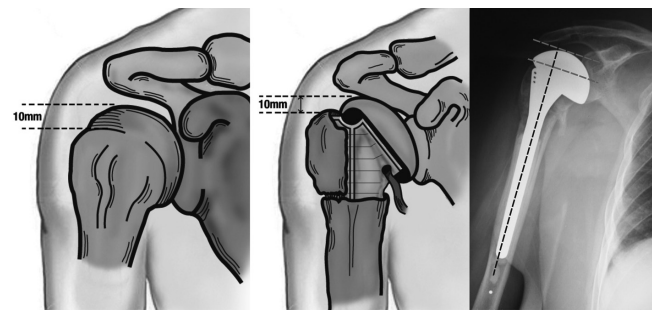


Fig. 4 - Technique for measuring the height of the greater tubercle.

The data on the patients who fulfilled the inclusion criteria were entered into an electronic spreadsheet (Microsoft Office Excel 2007) and were subjected to statistical analysis by means of the Stata v10.0 software. After our samples had been shown to present normal characteristics (skewness and kurtosis tests), these data were analyzed by means of Student's t test (comparison between means) and Pearson's test (correlation), and findings with $p < 0.05$ were considered to be significant.

Results

In evaluating the active range of motion, we found the following means: anterior flexion of 104° (range: 20° to 160°); external rotation of 36° (range: -5° to 60°); and internal rotation to L1 (range: gluteus to T7). In evaluating the UCLA score, we found a mean of 26 points, with six excellent results, 24 good, 26 fair and 11 poor (Fig. 5). In analyzing the score parameters separately, we found a mean of 8.25 for pain; 6 for function; 3 for elevation and 3.75 for elevation strength. We found a high rate of subjective satisfaction, such that 64 patients (96%) were satisfied with the procedure.

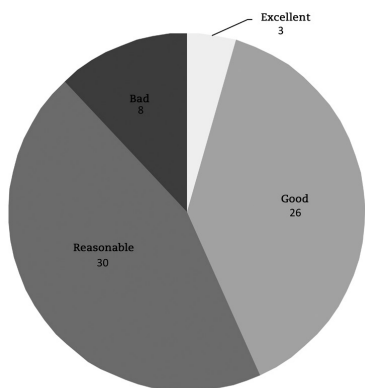


Fig. 5 - Results according to UCLA score.

From the radiographic evaluation, we identified 33 patients who presented tubercles consolidated in the anatomical position, and these were included in group A. Thus, the other 34 patients were included in group B. In group A, we found a mean UCLA score of 29.5 and active anterior flexion of 122°. In group B, we found a mean UCLA score of 22.7 points and mean active anterior flexion of 87° (Table 1). Using Student's t test, we comparatively analyzed the mean active elevation and UCLA scores between groups A and B (Figs. 6 and 7). We found statistically significant differences both for anterior flexion ($p < 0.0001$) and for UCLA score ($p < 0.0001$).

The male individuals had functional results that were better than those of the females. This result was statistically significant according to Student's t test. The mean active

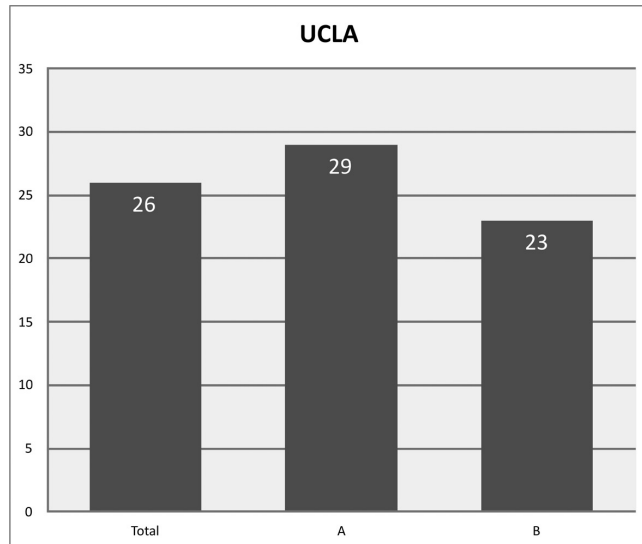


Fig. 6 - Comparison of UCLA score between groups A and B.

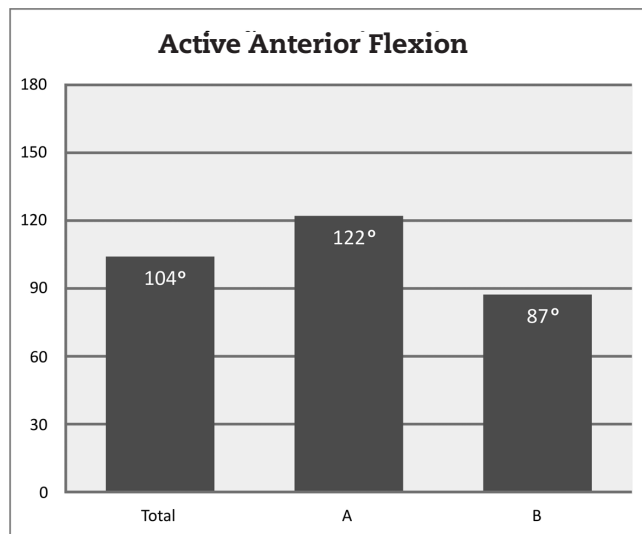


Fig. 7 - Comparison of active anterior flexion between groups A and B.

	#	UCLA	Active anterior flexion
Total	67	26,0	104°
A	33	29,5	122°
B	34	22,7	87°

elevation was 119° for the men and 98° for the women ($p = 0.0268$). The UCLA score was 29.7 for the men and 24.5 for the women ($p = 0.0005$). Through Pearson's test, we did not find any statistically significant correlation between the patients' ages and functional results.

The complications encountered included two cases of periprosthetic fracture, which were treated by means of osteosynthesis, using a plate and screws. One of these was a case of perioperative fracture and the other was a diaphyseal fracture that occurred 11 months after hemiarthroplasty. Two patients presented neuropraxia as a surgical complication: one in the median nerve and the other in the axillary nerve. Both of these presented complete resolution. There was only one case of infection, which was treated by means of surgical debridement and venous antibiotic therapy, with complete resolution.

Discussion

Since the 1970s, when hemiarthroplasty was popularized by Neer, it has been widely used around the world for treatment of complex fractures of the proximal extremity of the humerus,⁵⁻²³ particularly among elderly patients. However, differing from the excellent results reported by Neer, most of the studies in the literature have reported disappointing results. The results generally show high incidence of subjective satisfaction and absence of complaints of pain, but with disappointing functional results, particularly because of limitations of active elevation.⁶⁻²³ In a systematic review published in 2008, Kontakis et al.⁹ included 16 studies with 810 patients who underwent hemiarthroplasty for treatment of acute fractures of the proximal extremity of the humerus. The means for anterior flexion and the Constant functional score were 105° and 56 points, respectively, from which it can be concluded that most of the patients presented functional limitation in the final evaluation.

In our study, we found results that were similar to those described in the literature, and we also identified high incidence of satisfaction among the patients, particularly in relation to pain, even when they did not present satisfactory active mobility. In our series, it was possible to demonstrate that consolidation of the tubercles in the anatomical position had a large influence on the functional result. Several studies in the literature have emphasized the importance of reestablishing the anatomy of the tubercles, in order to obtain satisfactory functional results.⁷⁻²¹ Bono et al.²⁷ demonstrated that changes to the height of the greater tubercle that were more than 5 mm modified the lever arm of the shoulder operated, thereby diminishing the deltoid abduction strength. In 2008, Antuña et al.⁸ stated that the commonest complication following hemiarthroplasty is displacement of the greater tubercle, and correlated this with worse functional scores. Compito et al.¹² also identified displacement of the greater tubercle as the main factor responsible for poor results in this type of procedure. These authors found that 43% of the results were excellent, such that all the tuberosities became consolidated with displacements of less than 5 mm. Mighell et al.¹⁶ reported that their worst results were related to excessive lowering of the greater tubercle.

Because of the importance of anatomical consolidation of the tubercles, we believe that the surgical technique should include special attention to measures that might influence this objective. Since these cases present fragile and osteopenic bone tissue, handling the tubercles should be done carefully, thus avoiding rough or excessive manipulation that might increase their fragmentation. Binding the tubercles is extremely important and should be done meticulously, using strong thread that can function in both the horizontal and the vertical plane. Extra attention is needed so that the greater tubercle is not lowered too much during the binding process. This is a frequent mistake, with undesirable consequences. Boileau et al.⁷ reported that the worst results from this surgery were related to the presence of an unfortunate trio of factors: high prosthesis, excessive retroversion and lowered greater tubercle.

Although tubercle fixation is traditionally done by means of binding with non-absorbable threads, other methods have been proposed. Krause et al.¹⁹ compared traditional binding of the tubercles with fixation by means of steel wires, thereby obtaining superior results in this group. Another measure that may be very useful is to perform perioperative control radiographs, which enable timely correction of possible imperfections regarding the tubercle height, given that the presence of the rotator cuff makes it difficult to directly view the relationship between the tubercle and the prosthesis. Lastly, the importance of bone grafts for facilitating consolidation between the diaphysis and the tubercles should be borne in mind.

Another of the great challenges in conducting this surgery is to correctly establish the height of the prosthesis, which is one of the crucial points regarding reestablishment of the anatomical functioning of the shoulder. Loss of the anatomical reference points of the upper region of the humerus makes it much more difficult to identify the precise position of the implant. Furthermore, there is difficulty in maintaining the positioning of the prosthesis during its testing, and even more so in reproducing this position at the time of cementation. In the system that we use, there is a very useful guide that enables provisional fixation of the prosthesis so that its height and version can be tested, and enables reproduction of this position at the time of placing the definitive implant. Other ways of correctly establishing the height of the prosthesis have been described, such as measurement of the distance between the cephalic component and the upper edge of the pectoralis major.²⁸ The most serious mistake is excessive stretching of the humerus, since this causes upward migration of the prosthesis and elevated pressure on the rotator cuff, and creates difficulty regarding consolidation. Shortening of the humerus tends to be better tolerated, even though this may alter the tension and power of the deltoid if it is greater than 20 mm.²⁹

In addition to the heights of the humeral shaft and tubercles, precise determination of the retroversion of the prosthesis is extremely important for correct functioning of the system. Retroversion is important not only for prosthesis stability but also in influencing the position of the tubercles and, fundamentally, for their consolidation. Boileau et al.⁷ found an association between retroversion greater than 40° and posterior migration of the greater tubercle, with consequent compromising of the functional result. Excessive retroversion leads to elevated tension upon fixation of the greater tubercle, which is subject to traction caused by the tendons of the infraspinatus and teres minor, especially when the arm is placed in internal rotation. For this reason, Boileau et al.⁷ avoided placing a sling in internal rotation during the period of tubercle consolidation and preferred immobilization in neutral rotation.

Another factor of great importance is the postoperative management. In a general manner, there is a current tendency to implement rehabilitation more slowly and to keep the patient using a sling for a longer time,^{7,30} so that consolidation of the greater tubercle is achieved, which is defined as fundamental for the quality of the functional result. In addition, the patient's motivation during the postoperative period, along with a good team of physiotherapists, plays an important role in the final result.

As also described by Boileau et al.,⁷ we found that the functional result among female patients was inferior to the result among males, probably due to osteopenia and the fragility of the tubercles. Moreover, many studies have suggested that there is a progressive worsening of the results with advancing age.^{7,10,18,22} However, in our case series, we were unable to demonstrate any statistically significant correlation between age and the functional results.

Because of the many technical details described previously, it can be expected that the team's experience and training will have a large influence on the results from a surgical procedure of such complexity. This can be proven from a multicenter study that was conducted by Kralinger et al.¹⁰ Even when the surgical technique is implemented adequately, the result is not as predictable as the functional result.⁷ Thus, we believe that this surgical procedure should continue to be refined through technical innovations and technologies, so that satisfactory functional results can be achieved more frequently (Fig. 8).

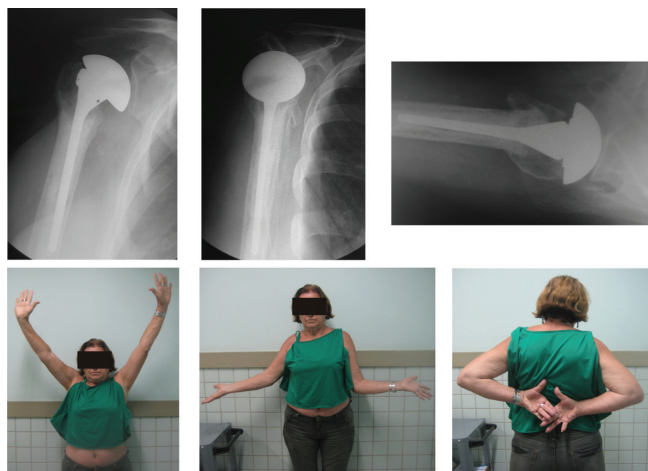

Fig. 8 - Example of patient with good radiological and clinical results.

Conclusion

Hemiarthroplasty for treatment of complex fractures of the proximal extremity of the humerus among elderly people presented a low complication rate and high subjective satisfaction rate, with absence of pain. Satisfactory functional results are not readily predictable and fundamentally depend on precise reestablishment of the anatomy of the proximal extremity of the humerus, especially anatomical consolidation of the greater tubercle.

Conflicts of interest

The authors declare that there was no conflict of interests in conducting this study.

R E F E R E N C E S

- Lind T, Kroner K, Jensen J. The epidemiology of fractures of proximal humerus. *Arch Orthop Trauma Surg.* 1989;108(5):285-7.
- Habermeyer P, Schweiberer L. Fractures of the proximal humerus. *Orthopade.* 1989;18(3):200-7.
- Hertel R, Hempfing A, Stiehler M, Leunig M. Predictors of humeral head ischemia after intracapsular fracture of the proximal humerus. *J Shoulder Elbow Surg.* 2004;13(4):427-33.
- Neer CS 2nd. Displaced proximal humeral fractures. I. Classification and evaluation. *J Bone Joint Surg Am.* 1970;52(6):1077-89.
- Neer CS 2nd. Displaced proximal humeral fractures. II. Treatment of three part and four-part displacement. *J Bone Joint Surg Am.* 1970;52(6):1090-103.
- Movin T, Sjöden GO, Ahrengart L. Poor function after shoulder replacement in fracture patients. A retrospective evaluation of 29 patients followed for 2-12 years. *Acta Orthop Scand.* 1998;69(4):392-6.
- Boileau P, Krishnan SG, Tinsi L, Walch G, Coste S, Molé D. Tuberosity malposition and migration: reasons for poor outcomes after hemiarthroplasty for displaced fractures of the proximal humerus. *J Shoulder Elbow Surg.* 2002;11(5):401-12.
- Antuña SA, Sperling JW, Cofield RH. Shoulder hemiarthroplasty for acute fractures of the proximal humerus: a minimum fiveyear follow-up. *J Shoulder Elbow Surg.* 2008;17(2):202-9.
- Kontakis G, Koutras C, Tosounidis T, Giannoudis P. Early management of proximal humeral fractures with hemiarthroplasty: a systematic review. *J Bone Joint Surg Br.* 2008;90(11):1407-13.
- Kralinger F, Schwaiger R, Wambacher M, Farrell E, Menth-Chiari W, Lajtai G, et al. Outcome after primary hemiarthroplasty for fracture of the head of the humerus. A retrospective multicentre study of 167 patients. *J Bone Joint Surg Br.* 2004;86(2):217-9.
- Hawkins RJ, Switlyk P. Acute prosthetic replacement for severe fractures of the proximal humerus. *Clin Orthop Relat Res.* 1993;(289):156-60.
- Compito CA, Self EB, Bigliani LU. Arthroplasty and acute shoulder trauma. Reasons for success and failure. *Clin Orthop Relat Res.* 1994;(307):27-36.
- Checchia SL, Doneux PS, Miyazaki AN, Fregoneze M, Silva LA, Faria FN, et al. Tratamento das fraturas do terço proximal do úmero com a prótese parcial Eccentra. *Rev Bras Ortop.* 2005;40(3):130-40.
- Veado MAC, Machado LP, Soares CGN, Souza SVS. Avaliação da função do ombro pós-hemiarthroplastias em fraturas em três e quatro partes do úmero proximal. *Rev Bras Ortop.* 2001;36(5):710-7.
- Santos PS, Bonamin C, Sobania LC, Otsuka N, Sobania RL, Lucio SRE, et al. Hemiarthroplastias em fraturas e fraturasluxações do ombro. *Rev Bras Ortop.* 1994;29:651-5.
- Mighell MA, Kolm GP, Collinge CA, Frankle MA. Outcomes of hemiarthroplasty for fractures of the proximal humerus. *J Shoulder Elbow Surg.* 2003;12(6):569-77.
- Tanner MW, Cofield RH. Prosthetic arthroplasty for fractures and fracture-dislocations of the proximal humerus. *Clin Orthop Relat Res.* 1983;(179):116-28.
- Robinson CM, Page RS, Hill RM, Sanders DL, Court-Brown CM, Wakefield AE. Primary arthroplasty for treatment of proximal humeral fractures. *J Bone Joint Surg Am.* 2003;85(A):1215-23.

19. Krause FG, Huebschle L, Hertel R. Reattachment of the tuberosities with cable wires and bone graft in hemiarthroplasties done for proximal humeral fractures with cable wire and bone graft: 58 patients with a 22-month minimum follow-up. *J Orthop Trauma*. 2007;21(10):682-6.
20. Goldman RT, Koval KJ, Cuomo F, Gallagher MA, Zuckerman JD. Functional outcome after humeral head replacement for acute three- and four-part proximal humeral fractures. *J Shoulder Elbow Surg*. 1995;4(2):81-6.
21. Zyto K, Wallace WA, Frostick SP, Preston BJ. Outcome after hemiarthroplasty for three- and four-part fractures of the proximal humerus. *J Shoulder Elbow Surg*. 1998;7(2):85-9.
22. Prakash U, McGurty DW, Dent JA. Hemiarthroplasty for severe fractures of the proximal humerus. *J Shoulder Elbow Surg*. 2002;11(5):428-30.
23. Grönhagen CM, Abbaszadegan H, Révay SA, Adolphson PY. Medium-term results after primary hemiarthroplasty for comminute proximal humerus fractures: a study of 46 patients followed up for an average of 4.4 years. *J Shoulder Elbow Surg*. 2007;16(6):766-73.
24. AAOS – American Academy of Orthopedic Surgeons: Joint Motion: Method of Measuring and Recording. Chicago: American Academy of Orthopedics; 1965.
25. Ellman H, Hanker G, Bayer M. Repair of the rotator cuff: endresult study of factors influencing reconstruction. *J Bone Joint Surg Am*. 1986;68(8):1136-44.
26. Iannotti JP, Gabriel JP, Schneck SL, Evans BG, Misra S. The normal glenohumeral relationships. An anatomical study of one hundred and forty shoulders. *J Bone Joint Surg Am*. 1992;74(4):491-500.
27. Bono CM, Renard R, Levine RG, Levy AS. Effect of displacement of fractures of the greater tuberosity on the mechanics of the shoulder. *J Bone Joint Surg Br*. 2001;83(7):1056-62.
28. Murachovsky J, Ikemoto RY, Nascimento LG, Fujiki EN, Milani C, Warner JJ. Pectoralis major tendon reference (PMT): a new method for accurate restoration of humeral length with hemiarthroplasty for fracture. *J Shoulder Elbow Surg*. 2006;15(6):675-8.
29. Neer CS, Kirby RM. Revision of humeral head and total shoulder arthroplasties. *Clin Orthop*. 1982;(172):189-95.
30. Amirfeyz R, Sarangi P. Shoulder hemiarthroplasty for fracture with a conservative rehabilitation regime. *Arch Orthop Trauma Surg*. 2008;128(9):985-8.