


Outcomes of the Management of Distal Radius Fractures in the Last 5 Years: A Meta-analysis of Randomized Controlled Trials*

Resultados do manejo de fraturas do rádio distal nos últimos 5 anos: Metanálise de ensaios clínicos controlados e randomizados

Anak Agung Gede Yuda Asmara¹ Made Bramantya Karna¹ Putu Feryawan Meregawa¹
Maria Florencia Deslivia¹

¹ Orthopedics and Traumatology Department, Faculty of Medicine, Udayana University, Sanglah General Hospital, Bali, Indonesia

Address for correspondence Anak Agung Gede Yuda Asmara, Orthopedics and Traumatology Department, Faculty of Medicine, Udayana University, Sanglah General Hospital, Jl. Kesehatan no.1, Bali, Indonesia (e-mail: yudaasmara17@yahoo.com).

Rev Bras Ortop 2022;57(6):899–910.

Abstract

Objective Over the last decades, volar locking plates (VLPs) have been the mainstay treatment for distal radius fractures (DRFs). With the growing body of evidence, we systematically reviewed studies on recent VLP modifications.

Methods A systematic search was performed in the PubMed/MEDLINE database for studies published in English in the past five years. The inclusion criteria were randomized controlled trials (RCTs) on the operative treatment of DRFs. We excluded ongoing trials and studies not directly addressing DRF. The primary outcomes assessed were subjective (such as the scores on the Disabilities of the Arm, Shoulder and Hand [DASH] questionnaire, the Patient-rated Wrist Evaluation [PRWE], the European Quality of Life–5 Dimensions [EQ-5D], the 36-item Short Form Health Survey [SF-36], and the Visual Analog Scale [VAS]) and objective clinical outcomes (the complication rate).

Results We identified 29 articles published from 2016 to 2020 with high quality of evidence, except for one, which had evidence of moderate quality. In total, 3,079 DRFs were analyzed in the present study. All studies except one had a greater proportion of female participants, and only in 1 study the mean age of the sample was < 40 years old. There were no significant differences between the VLP and external fixation (EF) in terms of the scores on the DASH ($p = 0.18$) and PRWE ($p = 0.77$). The VLP alone without pronator quadratus (PQ) repair yielded significantly better outcomes.

Keywords

- ▶ bone plates
- ▶ external fixators
- ▶ radius fractures
- ▶ wrist injuries

* Work developed at the Orthopedics and Traumatology Department, Faculty of Medicine, Udayana University, Sanglah General Hospital, Bali, Indonesia.

received
July 17, 2021
accepted
June 14, 2022

DOI <https://doi.org/10.1055/s-0042-1754379>.
ISSN 0102-3616.

© 2022. Sociedade Brasileira de Ortopedia e Traumatologia. All rights reserved.
This is an open access article published by Thieme under the terms of the Creative Commons Attribution-NonDerivative-NonCommercial-License, permitting copying and reproduction so long as the original work is given appropriate credit. Contents may not be used for commercial purposes, or adapted, remixed, transformed or built upon. (<https://creativecommons.org/licenses/by-nc-nd/4.0/>)
Thieme Revinter Publicações Ltda., Rua do Matoso 170, Rio de Janeiro, RJ, CEP 20270-135, Brazil

Resumo

Conclusion In unstable fractures, the VLP and EF yielded comparable long-term results. There is no clear benefit of adding PQ repair to current the VLP surgical technique.

Level of Evidence Level I

Palavras-chave

- ▶ placas ósseas
- ▶ fixadores externos
- ▶ fraturas do rádio
- ▶ traumatismos do punho

Objetivo Nas últimas décadas, a placa volar bloqueada (PVB) tem sido o tratamento principal para fraturas do rádio distal (FRDs). Com o crescente conjunto de evidências, revisamos sistematicamente estudos sobre modificações recentes na PBV.

Métodos Uma pesquisa sistemática foi realizada utilizando o banco de dados PubMed/MEDLINE por estudos publicados em inglês nos últimos cinco anos. Os critérios de inclusão foram ensaios clínicos controlados e randomizados (ECCRs) sobre o tratamento cirúrgico de FRDs. Excluímos ensaios e estudos em andamento que não abordavam diretamente a FRD. Os desfechos primários avaliados foram desfechos clínicos subjetivos (como as pontuações no questionário de Deficiências do Braço, Ombro e Mão [Disabilities of the Arm, Shoulder and Hand, DASH, em inglês], na Avaliação do Punho Classificada pelo Paciente [Patient-rated Wrist Evaluation, PRWE, em inglês], no questionário Qualidade de Vida Europeia – 5 Dimensões [European Quality of Life–5 Dimensions, EQ-5D, em inglês], na Pesquisa de Saúde por Formulário Curto de 36 Itens [36-item Short Form Health Survey, SF-36, em inglês], e na Escala Visual Analógica [EVA]) e objetivos (taxa de complicações).

Resultados Identificamos 29 artigos publicados entre 2016 e 2020 com alta qualidade de evidência, exceto por um, de qualidade moderada. Ao todo, foram analisadas 3.079 FRDs neste estudo. Todos os estudos analisados, exceto por um, tinham maior proporção de participantes do gênero feminino, e somente em 1 estudo a idade média da amostra foi < 40 anos. Não houve diferença significativa entre a PVB e fixação externa (FE) em termos das pontuações no DASH ($p = 0,18$) e na PRWE ($p = 0,77$). Os resultados da PVB isolada, sem qualquer reparo do pronador quadrado (PQ), foram significativamente melhores.

Conclusão Em fraturas instáveis, a PVB e a FE produziram resultados comparáveis no longo prazo. Não há um benefício claro em se adicionar reparo do PQ à técnica cirúrgica atual da PVB.

Nível de Evidência Nível I

Introduction

The transition from being quadrupedal to bipedal played an important role in making distal radius fractures (DRFs) one of the most common fractures in the human species. It rendered us vulnerable to “fall onto an outstretched hand” as a mechanism of injury.^{1,2} Operative techniques for DRFs started to gain popularity in the 1960s as a result of the increased incidence of malunion related to the conservative treatment.³ Early surgical techniques include the percutaneous pinning first described by Kapandji,⁴ external fixation (EF),⁵ and internal fixation using plates.⁶ Over the last decades the volar locking plate (VLP) has been the treatment of choice.⁷ However, there are still complications^{8,9} and technical difficulties^{10–12} reported regarding the VLP.

In an effort to improve the operative management of DRFs, an increasing number of randomized controlled trials (RCTs)

and meta-analyses are studying the comparison between the VLP and other emerging methods of internal fixation,^{13–18} as well as improvements in the surgical technique for VLP.¹⁹ With this growing body of evidence concerning DRFs, it is imperative to systematically review the studies with the highest level of evidence and summarize the current findings. The objective of the present work to describe the current options of operative treatment for DRF, especially VLP and the modification in its surgical technique, as well as to examine the functional outcomes.

Material and Methods

The present systematic review and meta-analysis was performed in accordance to the Preferred Reporting Items for Systematic Reviews and Meta-Analyses (PRISMA) statement and the Quality of Reporting of Meta-analyses (QUOROM) flowchart. A review protocol was drafted and registered on

Table 1 Inclusion and exclusion criteria based on the PICO strategy

	Inclusion criteria	Exclusion criteria
Population	Patients aged ≥ 18 years with distal radius fractures of any clinical presentation.	<ul style="list-style-type: none"> • Animal studies. • Chronic injury to the distal radius. • Underlying congenital condition or neoplasm.
Intervention	Operative procedures and the modification, including internal fixation with plating other than volar plating, external fixation, and pinning.	<ul style="list-style-type: none"> • Nonoperative procedures. • Pharmacological treatment. • Nutritional treatment. • Physical therapy or rehabilitation which stands alone.
Comparison	Operative procedure with volar plating	
Outcome	<p>Primary outcome measures: clinical outcomes, including the scores on the Disabilities of the Arm, Shoulder, and Hand (DASH) questionnaire, Visual Analogue Scale (VAS) for pain, and 36-Item Short Form Health Survey (SF-36) regarding quality of life.</p> <p>Secondary outcome measures Additional outcomes of interest, including complications.</p>	<ul style="list-style-type: none"> • The study is ongoing, and no results have been reported yet. • The outcome measures have not been completely reported.

Abbreviation: PICO, population, intervention, comparison, outcome.

the International Prospective Register of Systematic Reviews (PROSPERO; registration number: CRD42020212627).

Search Strategy and Selection Criteria

We performed a systematic search of the literature published from October 2016 to October 2020 in English on the following databases: PubMed/MEDLINE, Cochrane Central Register of Controlled Trials (CENTRAL), and ClinicalTrials.gov. The search terms included, but were not limited to, *distal radius fracture*, *Colles fracture*, *management*, *treatment*, *external fixation*, *internal fixation*, *pinning*, *plate*, and *intra-medullary nail*.

The criteria for inclusion in the present study were RCTs on the operative treatment of DRFs. We excluded ongoing trials and studies not directly addressing DRF. The articles were also selected according to the Population, Intervention, Comparison, Outcome (PICO) strategy, as depicted in ►Table 1.

Data Extraction

The data were extracted by a research team using a standardized data collection form, and each selected article was screened independently by two reviewers. Disagreements between the reviewers regarding whether to include or exclude a study were resolved by consensus, and if necessary, consultation with a third reviewer.

The variables collected included age, gender, fracture classification, interventions performed, follow-up, the scores on the Disabilities of the Arm, Shoulder and Hand (DASH) questionnaire, the Patient-rated Wrist Evaluation (PRWE), the European Quality of Life–5 Dimensions (EQ-5D), the 36-item Short Form Health Survey (SF-36), and the Visual Analogue Scale (VAS), the presence of complications (such as infection, for example), and reoperation.

Quality Assessment

The RCTs included were assessed in terms of quality by two independent reviewers based on the 13 items of the “2015 Updated Method Guideline for Systematic Reviews in the Cochrane Back and Neck Group”.²⁰

Data Synthesis

The studies selected in the systematic review were included in the meta-analysis if they contained one or more outcomes of interest, as aforementioned. The heterogeneity among the studies was calculated using the I-squared (I^2) statistic. For outcomes reported as numeric variables, the mean differences (MDs) were reported with 95% confidence intervals (95%CIs). Any study with outcomes reported as a median value was submitted to an estimation of the mean using a previously reported method.²¹ The complications were presented using relative risk, 95%CIs, and number needed to treat, wherever it was appropriate. Comparisons were inferred to be statistically significant if the 95%CI of the MD was ≤ 0 or if the 95%CI of the relative risk was ≤ 1 .

Results

Literature Search and Study Characteristics

The preliminary electronic search of all databases resulted in 3,972 records (►Fig. 1). A total of 3,500 clinical studies other than RCTs were excluded, and 472 studies remained. In the second step, 384 studies were excluded due to: the performance of nonoperative treatments, pain treatment, rehabilitation after DRF, proposed protocol, treatment of injury around the DRF, and 88 studies remained. After examining the full text of the collected RCTs, we excluded ongoing studies, studies with the same cohort of patients, and those with incomplete reports of outcome measures, in a

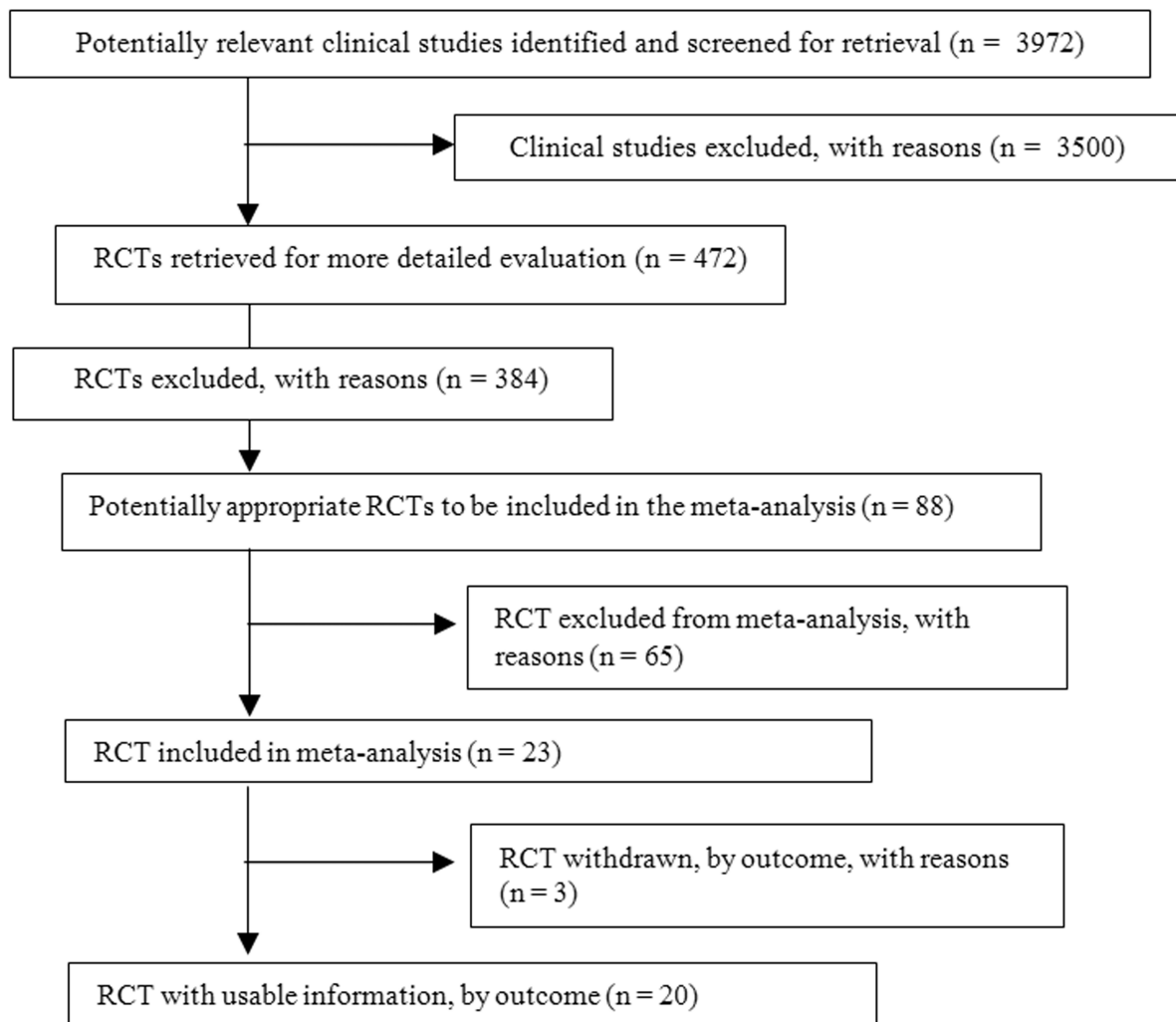


Fig. 1 Identification of studies in the primary literature search and the flowchart of the selection process.

total of 65 studies. Finally, 20 articles were assessed, with 19 articles categorized as having high-quality evidence, and 1 identified as of moderate quality¹² (► **Table 2**).

Baseline Characteristics

In the present study, 2,103 DRFs were analyzed. All studies except for 1²² had a greater proportion of female participants, and only in 1 study²³ the sample had a mean age < 40 years old (► **Table 2**).^{11,12,22-39}

Operative Treatment for Distal Radius Fractures

In total, five RCTs addressed modifications in surgical techniques: three were on pronator quadratus (PQ) muscle repair, one was on brachioradialis muscle release, and one was on the minimally-invasive technique. As for the comparison of different operative procedures, four RCTs compared the VLP and EF, and four compared the VLP and Kirschner wires. There were also comparisons of different plates based on their relationship to the watershed line ($n = 1$), the plate material ($n = 1$), and the use of fragment-specific fixation ($n = 1$). Two studies discussed the postoperative immobilization period, and another two discussed the

importance of three-dimensional (3D) preoperative planning (► **Table 3**). The pooled scores on the DASH significantly favored the isolated use of the VLP without PQ repair (MD = 6.22; 95%CI = 2.96–9.48; $p = 0.0002$; $I^2 = 0\%$) (► **Fig. 2**). Individually, the p -values of these studies showed non-significant differences between patients treated with and without PQ repair. A meta-analysis was also performed to compare the scores on the DASH ($p = 0.18$) and PRWE ($p = 0.77$) regarding VLP and EF, which resulted in non-significant differences between the two methods (► **Fig. 3**).

Discussion

The present is the first study to summarize high-quality evidence regarding recent advancements in the management of DRFs. At first, DRF management seemed to reach its plateau of satisfactory outcomes, especially with the widespread use of the VLP. Despite that, there is still room for improvement, as well as for the performance of studies with better methodology, which will lead to more reliable results. In addition to that, the present study also investigated which modifications in the VLP will not result in additional benefits.

Table 2 Baseline characteristics of the selected studies

No	Author (year)	Intervention	Control	Sample size (n)	Gender (male/ female)	Age in years: median (range)	Fracture classification	Follow-up
1	Häberle et al. ³¹ (2015)	VLP + PQ repair	VLP	I: 31; C: 29	I: 7/24; C: 5/24	I: 52 (22-77); C: 56 (25-76)	A2/A3	3 months
2	Hohendorff et al. ³² (2018)	VLP + PQ repair	VLP	I: 20; C: 20	I: 4/16; C: 6/10	I: 64 (18-77); C: 54 (18-80)	A2/A3/B3/C1	15 months
3	Sonntag et al. ³³ (2019)	VLP + PQ repair	VLP	I: 36; C: 36	I: 15/57; C: 26/10	I: 62.0 (10.8); C: 63.6 (15.6)	A2/A3/B1/C1/C2	12 months
4	Ma et al. ²⁹ (2017)	VLP+ brachioradialis muscle release	VLP	I: 37; C: 37	I: 20/17; C: 18/19	I: 50.1 (14.4); C: 49.8 (16)	C1/C2/C3	12 months
5	Zhang et al. ²² (2017)	VLP + minimal incision	VLP	I: 83; C: 74	I: 49/34; C: 46/28	I: 42 (18-67); C: 41 (22-65)	A2/A3/B3/C1/C2	24 months
6	Mellstrand Navarro et al. ²⁷ (2016)	K-wire + EF	VLP	I: 69; C: 70	I: 4/65; C: 7/63	I: 63 (50-74); C: 63 (50-74)	A2/A3/C1/C2/C3	12 months
7	Saving et al. ²⁸ (2019)	EF	VLP	I: 56; C: 62	I: 2/54; C: 7/55	I: 63 (50-74); C: 63 (51-74)	A2/A3/C1/C2/C3	36 months
8	Hammer et al. ²⁶ (2019)	EF	VLP	I: 82; C: 84	I: 27/55; C: 25/59	I: 54 (12.4); C: 56 (10.5)	C1/C2/C3	24 months
9	Chung et al. ²⁵ (2020)	Group I: EF; group II: K-wire	VLP	I: group I - 64; group II - 58; C: 65	I: group I - 5/59; group II - 9/49; C: 10/55	I: group I - 70 ± 8.4; group II - 68 ± 7.0; C: 67 ± 6.2	A1/A2/A3/C1/C2/C3	12 months
10	Lee et al. ³⁴ (2016)	Group I: VLP + DRUJ transfixion; group II: VLP + TFCC repair	VLP + splint	I: group I - 72; group II - 10 C: 74	I: group I - 28/47; group II - 22/50; C: 6/4	I: group I: A1-43.4; B1-49.2; C1-64.3; group II: A2-66.6; B2-46.8; C2-67.1; C: 49.2	Group A: without ulnar styloid process fracture; group B: with fracture of the tip of the ulnar styloid process; group C: with fracture of the base of the ulnar styloid process	13.5 months (range: 12-18 months)
11	Athar et al. ³⁵ (2018)	K-wire + EF	K-wire	I: 24; C: 27	NA	NA	Frykman VII-VIII	12 months
12	Costa et al. ²⁴ (2019)	K-wire	VLP	I: 217; C: 231	I: 38/179; C: 37/194	I: 59.1 (16.5); C: 58.3 (14.3)	Intra- and extraarticular	60 months
13	Grادل et al. ³⁶ (2016)	Nailing	VLP	I: 14; C: 14	I: 2/12; C: 2/12	I: 63.8 ± 8.9; C: 64.8 ± 11.6	C2.1	24 months
14	Tanaka et al. ³⁰ (2016)	VLP + distal to watershed line	VLP + proximal to watershed line	I: 32; C: 32	I: 8/24; C: 7/25	I: 62.9 (14.2); C: 61.5 (13.9)	A2/A3/B2/B3/C1/C2/C3	6 months
15	Perugia et al. ³⁷ (2017)	Carbon PEEK VLP	Titanium VLP	I: 15; C: 15	I: 5/10; C: 4/11	I: 56.8 ± 7.1; C: 52.6 ± 8.4	B1/B2/C1/C2/C3	12 months
16	Landgren et al. ³⁸ (2017)	Fragment-specific fixation	VLP	I: 25; C: 24	I: 4/21; C: 7/18	I: 55 (24-68); C: 56 (21-69)	A/C	12 months
17	Watson et al. ²³ (2018)						A2/A3/B1/B2/B3/C1/C2	

(Continued)

Table 2 (Continued)

No	Author (year)	Intervention	Control	Sample size (n)	Gender (male/ female)	Age in years: median (range)	Fracture classification	Follow-up
18	Andrade-Silva et al. ³⁹ (2019)	VLP + immobilization: group I – week 1; group II – week 3	VLP + immobilization in 6 weeks	I: group I – 46; group II – 41; C: 46	I: group I – 17/29; group II – 10/31; C: 21/25	I: group I – 20 (43.5); group II – 21 (51.2); C: 21 (45.7)	B3/C1/C2/C3	26 weeks (6.5 months)
19	Yoshii et al. ¹² (2019)	VLP + splint	VLP	I: 19; C: 20	I: 8/11; C: 9/11	I: 51.2 (16.6); C: 47.6 (15.1)	A2/A3/C1/C2/C3	6 months
20	Kong et al. ¹¹ (2020)	VLP + 3D model	VLP	I: 30 C: 30	I: 9/21 C: 8/22	I: 60.1 (17–86); C: 62.6 (16–87)	AO types B and C	6 months

Abbreviations: 3D, three-dimensional; AO, Arbeitsgemeinschaft für Osteosynthesefragen (“Working Group for Bone Fusion Issues”); C, control; DRUJ, distal radioulnar joint; EF, external fixation; I, intervention; K-wire, Kirschner wire; NA, not available; PEEK, polyether ether ketone; PQ, pronator quadratus; TFCC, triangular fibrocartilage complex; VLP, volar locking plate.

Patient Reported Outcome Measures (PROMs) for the Upper Extremity

The present meta-analysis focuses on studies using patient-reported outcome measures (PROMs), which are of particular importance in studies with short-term follow-ups, since there is recent strong evidence that PROMs do not correlate with radiological parameters.^{40–42} However, this should be done carefully. A constantly-reliable PROM measurement tool is a prerequisite to perform valid analyses regarding several treatment modalities. Previous studies^{43,44} have shown evidence of the reliability, validity, and responsiveness of tools such as the DASH and PRWE in the assessment of the outcomes of injuries to the upper limbs, as compared with other outcome measures.

It is crucial to assess studies using PROMs as the outcome score based on the length of the follow-up period, since it significantly correlates with the progress of the patients. In the short term, two treatment modalities may show significant differences, which may become non-significant in the long term.^{24,25} Despite the superiority of the VLP,⁷ a large multicenter study⁴⁵ found that at the 12-month assessment patients treated with VLPs and those treated with other modalities reported similar outcomes. Even compared with patients treated with plaster casting, no differences were found in terms of PROMs as soon as six weeks after the fracture.⁴⁵ This result is interesting since it defies the common notion that radiological parameters are of the utmost importance, and places more weight on how the patient perceives the result of the treatment. Moreover, the temporal relationship with PROMs for each treatment will be an interesting focus for future studies, since it will influence how we communicate treatment decisions to patients and manage their expectations.

Can we Improve Volar Plating?

One of the most debated questions in DRF management is whether anatomical restoration equates to a satisfactory long-term functional outcome. The VLP has been associated with a precise anatomical reduction, but its cost is higher when compared to that of other options of surgical treatment.⁴⁶ Furthermore, despite the clinical and biomechanical studies favoring anatomical reduction, it was later analyzed that very few studies used validated PROMs.^{7,47} This raised the question of whether anatomical reduction as provided by the VLP is necessary. Other options have been considered, such as EF and non-operative treatments. In the present study, we pooled the DASH and PRWE scores of recent RCTs that showed that VLP yielded long-term results comparable to those of EF,^{27,28} especially for unstable fractures. However, the VLP is still the treatment of choice when compared with plaster casting.^{48–50} More studies with larger cohorts and the use of PROMs are needed to explore further issues regarding the need for anatomical reduction in DRFs.

Several studies^{51–54} have also reported complications related to the VLP. One of the most reported complications is rupture of the finger flexor tendon due to plate prominence at the watershed line.^{8,9} Therefore, several authors have attempted to avoid the problem by performing PQ

Table 3 Comparison of the outcomes of operative studies

No	Author (year)	Conclusion	DASH	PRWE	EQ-5D	SF-36	VAS	Complication
Comparison of Surgical Technique Modification								
1	Häberle et al. ³¹ (2015)	An improved pronation strength after PQ repair in the early rehabilitation period could not be confirmed. However, the PQ repair might reduce pain in the early postoperative period.	PQ repair: 3.5 (0-55); no repair: 5 (0-23); data expressed as median (range)	NA	NA	NA	Pain level between 0 and 2- PQ repair: 91%; no repair: 93%	NA
2	Hohendorff et al. ³² (2018)	PQ repair with insertion of a part of the BR muscle is a reliable technique to cover a VLP by slight distal transposition.	VLP + PQ repair: 9(11); VLP: 2(3)	NA	NA	NA	VLP + PQ repair: 9(1); VLP: 9(1)	None
3	Sonntag et al. ³³ (2019)	PQ repair made no difference to the clinical outcome, 12 months after DRF treat by VLP.	PQ repair: 15 (95%CI: 9.56-20.77); no repair: 13 (95%CI: 7.03-18.56)	NA	NA	NA	NA	NA
4	Ma et al. ²⁹ (2017)	Release of the BR for type-C DRFs facilitated the surgical 3 procedure and did not adversely affect elbow and wrist function.	BR release: 8.8 (12.3); no BR release: 7.4 (10.6)	NA	NA	NA	BR release: 0.5 (0.7); no BR release: 0.5 (0.8)	BR release: 16.2%; no BR release: 8.1% (p=0.708)
5	Zhang et al. ²² (2017)	Minimally-invasive VLP for DRFs is a safe and reliable technique, resulting in better pronation, function, and appearance.	Minimally-invasive: 3.6 ± 3.71; VLP: 3.9 ± 3.66 (DASH of A3 patients)	NA	NA	NA	Minimally-invasive: 3.5 ± 3.2; VLP: 7.47 ± 6.61 (scar pain)	NA
Comparison of Operative Procedures								
1	Mellstrand Navarro et al. ²⁷ (2016)	VLP and EF with optional addition of K-wires are two equally suitable treatment options for dorsally-displaced DRFs after low-energy trauma in a population aged 50-74 years.	VLP: 11 (0-77); EF: 13 (0-62)	VLP: 13 (0-80); EF: 14 (0-69)	VLP: 0.85 (0-1); EF: 0.89 (0.62-1)	NA	NA	EF: reoperation (n = 3), carpal tunnel release (n = 2); VLP: reoperation (n = 2), carpal tunnel release (n = 1); plate removal within 1 year (n = 7); rupture extensor pollicis longus tendon (n = 1)
2	Saving et al. ²⁸ (2019)	Three years after surgery for unstable dorsally-displaced DRFs, the clinical and radiological results for VLP and EF were comparable.	EF: 7.0 (9.9); VLP: 5.4 (7.1)	EF: 6.6 (12.0); VLP: 6.1 (9.2)	EF: 6.6 (12.0); VLP: 6.1 (9.2)	NA	NA	Reoperation rate: 21% (13 of 62) in the VLP group, and 14% (8 of 56) in the EF group; OA rate: 42% (25 of 59) in the VLP group and 28% (15 of 53) in the EF group.
3	Hammer et al. ²⁶ (2019)	VLP fixation resulted in faster recovery of function compared with EF, but no functional advantage was demonstrated at two years.	VLP: 7.6 (12.9); EF: 8.1 (14.0)	NA	NA	NA	VLP: 0.4 (1.0); EF: 0.4 (1.1)	VLP: 44%; EF: 55%
4	Chung et al. ²⁵ (2020)	Recovery was fastest for internal fixation and slowest for EF according to most measures, but after 12 months there were no meaningful differences in outcomes.	NA	NA	NA	NA	NA	Malunion- EF: 16%; VLP 6%. VLP: wound infection (n = 1); hardware removal (n = 3)
5	Lee et al. ³⁴ (2016)	Conservative treatment (supination sugar-tong splinting) and surgical treatments provided similar long-term outcomes for acute DRUJ instability with DRF.	In the group without fracture of the ulnar styloid process: VLP + splint: 14 ± 10; VLP + DRUJ transfixation (K-wire): 16 ± 12; VLP + TFCC repair: 13 ± 11	NA	NA	NA	NA	VLP + splint: mild instability and pain (1 patient)
6	Althar et al. ³⁵ (2018)	In the supplementation of K-wire stabilization of a non-committed DRF, application of an external fixator for four weeks was associated with lower pain, higher satisfaction, and greater range of	NA	NA	NA	NA	Mean VAS - K-wire + EF: 14.9; K-wire + PC: 28.1	NA

(Continued)

Table 3 (Continued)

No	Author (year)	Conclusion	DASH	PRWE	EQ-5D	SF-36	VAS	Complication
7	Costa et al. ²⁴ (2019)	This follow-up study continues to show no evidence of a difference in wrist pain, wrist function, or quality of life for patients treated with wires versus locking plates in the five years following a dorsally-displaced DRF.	K-Wire: 4.9 (11.9); VLP: 4.9 (11.3)	K-Wire: 2.3 (7.4); VLP: 2.9 (9.5)	NA	K-Wire: 0.93 (0.16); VLP: 0.93 (0.17)	NA	K-Wire: restricted wrist movement (n = 1); VLP: late tendon rupture (n = 1), retained suture removal (n = 1)
8	Gradl et al. ³⁶ (2016)	IM nail fixation is a reasonable alternative to VLP fixation for the treatment of intra-articular DRFs, and both techniques can yield reliably good results.	NA	NA	NA	NA	VLP: 0.00 ± 0.00; IM nail: 0.91 ± 2.21	VLP: carpal tunnel release (n = 1), implant removal (n = 1); IM nail: paresthesia of the superficial radial nerve (n = 1), implant removal (n = 1)
Comparison of Different Plates								
1	Tanaka et al. ³⁰ (2016)	Internal fixation using palmar locking plates with different placements in relationship to the watershed line provide similar and satisfactory outcomes six months after surgery. However, locking plates placed distal to the watershed line may delay recovery of the wrist ROM.	Distal to watershed line: 14.9 (12.1); proximal to watershed line: 12.8 (9.2)	NA	NA	NA	NA	Distal to watershed line: extensor tendon rupture (n = 1), CRPS (n = 1); proximal to watershed line: CRPS (n = 1)
2	Perugia et al. ³⁷ (2017)	Carbon PEEK VLPs seem to be analogue to titanium VLPs in terms of radiographic parameters and functional outcome.	Carbon PEEK 15.3 (2.5–5.89); titanium: 12.2 (10.6–54.8)	NA	NA	NA	Carbon PEEK 3.6; titanium: 2.9	
3	Landgren et al. ³⁸ (2017)	In the treatment of primarily non-reducible or secondarily displaced DRFs, VLPs and fragment-specific fixation both achieve good and similar patient-reported outcomes, although more complications were recorded in the fragment-specific group.	VLP: 12 ± 16; fragment-specific fixation: 9 ± 9	NA	NA	NA	VLP: 1.4 ± 2.1; fragment-specific fixation: 1.4 ± 1.8	VLP (n = 5): fragment-specific fixation (n = 13) (p < 0.05)
Comparison of Postoperative Immobilization Period								
1	Watson et al. ²³ (2018)	Immobilization periods of 1 and 3 weeks produced superior short-term outcomes compared with those after 6 weeks of immobilization. These differences were not evident at 3 and 6 months following surgery, with the immobilization period having no significant effect on long-term function, ROM, or pain. There were no significant differences in adverse events associated with shorter immobilization periods.	Immobilization for: 1 week: 12.9 (19.6); 3 weeks: 10.4 (14.7); 6 weeks: 14.4 (17.7)	Immobilization for: 1 week: 18.2 (23.8); 3 weeks: 13.5 (14.8); 6 weeks: 21.6 (20.6)	NA	NA	Immobilization for: 1 week: 11.4 (18.3); 3 weeks: 4.9 (9.7); 6 weeks: 12.2 (17.5)	Postoperative adverse event: 1 week: 15% (n = 6); 3 weeks: 3% (n = 1); 6 weeks: 13% (n = 5)
2	Andrade-Silva et al. ³⁹ (2019)	There was a trend toward a greater use of tramedol in patients who did not use immobilization and started early wrist mobilization after VLP for DRF, compared with patients who were immobilized for two weeks. The functional results and complication rates were not influenced by the use of immobilization.	No splint: 10.4 (11.8); splint: 14.5 (20.5)	NA	NA	NA	No splint: 1.1 (1.4); splint: 1.7 (2.9)	No splint: 1 patient with loss of fracture reduction at 6 weeks, who underwent reoperation
3D Preoperative Planning								
1	Yoshii et al. ¹² (2019)	3D preoperative planning offers better reduction accuracy and reduces correction loss in the osteosynthesis of DRFs.	NA	NA	NA	NA	NA	Loss of corrections: - difference in volar tilts = 2.53 ± 1.78 degrees (3D plan) and 4.00 ± 3.10 degrees (control) (p = 0.03);

Table 3 (Continued)

No	Author (year)	Conclusion	DASH	PRWE	EQ-5D	SF-36	VAS	Complication
2	Kong et al. ¹¹ (2020)	With the assistance of the 3D printing technique, the operative time, the amount of intraoperative bleeding, and rounds of intraoperative fluoroscopy can be reduced during the surgical treatment of intra-articular DRFs with VLP and K-wire fixation.	VLP + 3D model: 68.0 ± 9.6; VLP: 71.5 ± 10	NA	NA	NA	VLP + 3D model: 3.7 ± 1.3; VLP: 14.2 ± 1.4	- radial inclination difference = 2.00 ± 1.58 degrees (3D plan) and 3.40 ± 3.00 degrees (control) (p = 0.03) VLP + 3D model: loss of reduction (n = 1); VLP: loss of reduction (n = 1), superficial wound infection (n = 1)

Abbreviations: 3D, three-dimensional; 95%CI, 95% confidence interval; BR, brachioradialis; CRPS, DASH, Disabilities of the Arm, Shoulder and Hand questionnaire; DRF, distal radius fracture; DRUJ, distal radioulnar joint; EF, external fixation; EQ-5D, European Quality of Life-5 Dimensions; IM, intramedullary; K-wire, Kirschner wire; NA, not available; OA; PC, plaster cast; PEEK, polyether ether ketone; PQ, pronator quadratus; PRWE, Patient-rated Wrist Evaluation; ROM, range of motion; SF-36, 36-item Short Form Health Survey; TFCC, triangular fibrocartilage complex; VAS, Visual Analog Scale; VLP, volar locking plate.

repair,⁵⁵ brachioradialis (BR) repair,²⁹ and changing the placement of the plate in relation to the watershed line.³⁰ Despite that, recent studies showed no additional benefits of the PQ repair in the short-³¹ and long-term follow ups.^{32,33} In addition to that, our pooled results showed significantly better functional outcomes in patients only submitted to the VLP. One possible explanation presented was the failure in repairing the PQ when the soft tissue is too damaged.³¹

Another emerging topic in DRF management is the use of 3D modelling. In intraarticular DRFs, identification of the fracture pattern, such as the angle of the fracture line or overlapping fracture patches, is difficult, which often leads to extended operative time, excessive blood loss, and an uneven joint surface. This will result in increasing incidence of postoperative complications. The 3D modelling technique was introduced to provide multi-angle and a comprehensive view of the fracture patterns.¹⁰⁻¹²

Study Limitations

There are several limitations to the present study. We limited our search to studies published only in the past five years. Due to the rapid advances in information technology and the medical device industry in general, it is expected that surgical techniques as well as the function and design of plates will advance exponentially in the next decade. Another limitation is that the present meta-analysis only involved studies published in English. Despite the suspected bias toward studies published in English, especially those showing positive results, in the present systematic review we attempted to minimize this bias by collecting studies with diverse outcomes.

Final Considerations

In unstable fractures, the VLP and EF yielded comparable long-term results. Regarding improvement of the current VLP surgical technique, adding PQ repair to the procedure does not yield clear benefits. More studies with larger cohorts and reliable PROMs should be performed to confirm the results of previous studies and to explore promising modifications in the VLP, such as the use of preoperative 3D modelling.

Contribution of Authors

Anak Agung Gede Yuda Asmara: conceptualization, methodology, writing of the original draft, and supervision; Made Bramantya Karna: conceptualization, methodology, and writing of the original draft; Putu Feryawan Meregawa: data curation and investigation; Maria Florencia Deslivia: software, writing, review, and editing of the article.

Financial Support

The authors declare that they have received no financial support for the research, authorship, and/or publication of the present article.

Conflict of Interests

The authors have no conflict of interests to declare.

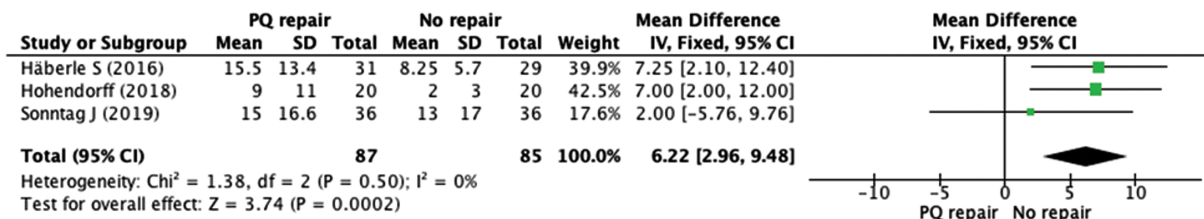


Fig. 2 Forest plot of the comparison of DASH scores favoring no PQ repair in the long-term follow-up ($p < 0.05$).

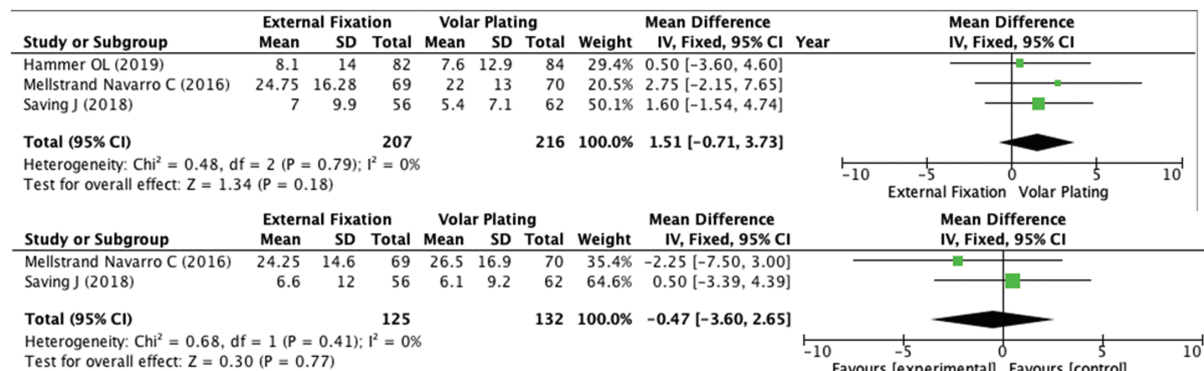


Fig. 3 Forest plot of the scores on the DASH (above) and PRWE (below) regarding the comparison between EF and VLP, showing non-significant differences between the two methods ($p < 0.05$).

Acknowledgments

We would like to thank Ketut Gede Mulyadi Ridia, the head of the Orthopedics and Traumatology Department, Faculty of Medicine, Udayana University, Sanglah General Hospital, for all the support.

References

- Chung KC, Spilson SV. The frequency and epidemiology of hand and forearm fractures in the United States. *J Hand Surg Am* 2001; 26(05):908–915
- Diaz-Garcia RJ, Chung KC. The evolution of distal radius fracture management: a historical treatise. *Hand Clin* 2012;28(02):105–111
- Older TM, Stabler EV, Cassebaum WH. Colles fracture: evaluation and selection of therapy. *J Trauma* 1965;5:469–476
- Greatting MD, Bishop AT. Intrafocal (Kapandji) pinning of unstable fractures of the distal radius. *Orthop Clin North Am* 1993;24(02):301–307
- Zanotti RM, Louis DS. Intra-articular fractures of the distal end of the radius treated with an adjustable fixator system. *J Hand Surg Am* 1997;22(03):428–440
- Carter PR, Frederick HA, Laseter GF. Open reduction and internal fixation of unstable distal radius fractures with a low-profile plate: a multicenter study of 73 fractures. *J Hand Surg Am* 1998;23(02):300–307
- Downing ND, Karantana A. A revolution in the management of fractures of the distal radius? *J Bone Joint Surg Br* 2008;90(10):1271–1275
- Asadollahi S, Keith PP. Flexor tendon injuries following plate fixation of distal radius fractures: a systematic review of the literature. *J Orthop Traumatol* 2013;14(04):227–234
- Kitay A, Swanstrom M, Schreiber JJ, et al. Volar plate position and flexor tendon rupture following distal radius fracture fixation. *J Hand Surg Am* 2013;38(06):1091–1096
- Yoshii Y, Totoki Y, Sashida S, Sakai S, Ishii T. Utility of an image fusion system for 3D preoperative planning and fluoroscopy in the osteosynthesis of distal radius fractures. *J Orthop Surg Res* 2019;14(01):342
- Kong L, Yang G, Yu J, et al. Surgical treatment of intra-articular distal radius fractures with the assistance of three-dimensional printing technique. *Medicine (Baltimore)* 2020;99(08):e19259
- Yoshii Y, Totoki Y, Tung WL, Akita K, Ishii T. A Comparison of Radiographic Outcomes between 3D Preoperative Planning and Conventional Planning in the Osteosynthesis of Distal Radius Fractures. *J Hand Surg Asian Pac Vol* 2019;24(03):303–310
- Ochen Y, Peek J, van der Velde D, et al. Operative vs Nonoperative Treatment of Distal Radius Fractures in Adults: A Systematic Review and Meta-analysis. *JAMA Netw Open* 2020;3(04):e203497
- Vannabouathong C, Hussain N, Guerra-Farfan E, Bhandari M. Interventions for Distal Radius Fractures: A Network Meta-analysis of Randomized Trials. *J Am Acad Orthop Surg* 2019;27(13):e596–e605
- Gouk CJC, Bindra RR, Tarrant DJ, Thomas MJE. Volar locking plate fixation versus external fixation of distal radius fractures: a meta-analysis. *J Hand Surg Eur Vol* 2018;43(09):954–960
- Wang J, Lu Y, Cui Y, Wei X, Sun J. Is volar locking plate superior to external fixation for distal radius fractures? A comprehensive meta-analysis. *Acta Orthop Traumatol Turc* 2018;52(05):334–342
- Xu GY, Qiu Y, Mao HJ. A Network Meta-analysis of Outcomes of 7 Surgical Treatments for Distal Radius Fractures. *Am J Ther* 2016; 23(06):e1320–e1328
- Hardman J, Al-Hadithy N, Hester T, Anakwe R. Systematic review of outcomes following fixed angle intramedullary fixation of distal radius fractures. *Int Orthop* 2015;39(12):2381–2387

- 19 Lu CK, Liu WC, Chang CC, Shih CL, Fu YC, Jupiter JB. A systematic review and meta-analysis of the pronator quadratus repair following volar plating of distal radius fractures. *J Orthop Surg Res* 2020;15(01):419
- 20 Furlan AD, Malmivaara A, Chou R, et al; Editorial Board of the Cochrane Back, Neck Group. 2015 Updated Method Guideline for Systematic Reviews in the Cochrane Back and Neck Group. *Spine* 2015;40(21):1660–1673
- 21 Wan X, Wang W, Liu J, Tong T. Estimating the sample mean and standard deviation from the sample size, median, range and/or interquartile range. *BMC Med Res Methodol* 2014;14:135
- 22 Zhang X, Huang X, Shao X, Zhu H, Sun J, Wang X. A comparison of minimally invasive approach vs conventional approach for volar plating of distal radial fractures. *Acta Orthop Traumatol Turc* 2017;51(02):110–117
- 23 Watson N, Haines T, Tran P, Keating JL. A Comparison of the Effect of One, Three, or Six Weeks of Immobilization on Function and Pain After Open Reduction and Internal Fixation of Distal Radial Fractures in Adults: A Randomized Controlled Trial. *J Bone Joint Surg Am* 2018;100(13):1118–1125
- 24 Costa ML, Achten J, Rangan A, Lamb SE, Parsons NR. Percutaneous fixation with Kirschner wires versus volar locking-plate fixation in adults with dorsally displaced fracture of distal radius: five-year follow-up of a randomized controlled trial. *Bone Joint J* 2019;101-B(08):978–983
- 25 Chung KC, Kim HM, Malay S, Shauver MJ. Wrist and Radius Injury Surgical Trial Group. The Wrist and Radius Injury Surgical Trial: 12-Month Outcomes from a Multicenter International Randomized Clinical Trial. *Plast Reconstr Surg* 2020;145(06):1054e–1066e
- 26 Hammer OL, Clementsen S, Hast J, Šaltytė Benth J, Madsen JE, Randsborg PH. Volar Locking Plates Versus Augmented External Fixation of Intra-Articular Distal Radial Fractures: Functional Results from a Randomized Controlled Trial. *J Bone Joint Surg Am* 2019;101(04):311–321
- 27 Mellstrand Navarro C, Ahrengart L, Törnqvist H, Ponzer S. Volar Locking Plate or External Fixation With Optional Addition of K-Wires for Dorsally Displaced Distal Radius Fractures: A Randomized Controlled Study. *J Orthop Trauma* 2016;30(04):217–224
- 28 Saving J, Enocson A, Ponzer S, Mellstrand Navarro C. External Fixation Versus Volar Locking Plate for Unstable Dorsally Displaced Distal Radius Fractures—A 3-Year Follow-Up of a Randomized Controlled Study. *J Hand Surg Am* 2019;44(01):18–26
- 29 Ma T, Zheng X, He XB, Guo KJ. The role of brachioradialis release during AO type C distal radius fracture fixation. *Orthop Traumatol Surg Res* 2017;103(07):1099–1103
- 30 Tanaka H, Hatta T, Sasajima K, Itoi E, Aizawa T. Comparative study of treatment for distal radius fractures with two different palmar locking plates. *J Hand Surg Eur Vol* 2016;41(05):536–542
- 31 Häberle S, Sandmann GH, Deiler S, et al. Pronator quadratus repair after volar plating of distal radius fractures or not? Results of a prospective randomized trial. *Eur J Med Res* 2015;20:93
- 32 Hohendorff B, Knappwerth C, Franke J, Müller LP, Ries C. Pronator quadratus repair with a part of the brachioradialis muscle insertion in volar plate fixation of distal radius fractures: a prospective randomised trial. *Arch Orthop Trauma Surg* 2018;138(10):1479–1485
- 33 Sonntag J, Woythal L, Rasmussen P, et al. No effect on functional outcome after repair of pronator quadratus in volar plating of distal radial fractures: a randomized clinical trial. *Bone Joint J* 2019;101-B(12):1498–1505
- 34 Lee SK, Kim KJ, Cha YH, Choy WS. Conservative Treatment Is Sufficient for Acute Distal Radioulnar Joint Instability With Distal Radius Fracture. *Ann Plast Surg* 2016;77(03):297–304
- 35 Athar SM, Ashwood N, Aerealis G, Bain GI. Is external fixation a better way than plaster to supplement K-wires in non-comminuted distal radius fractures? *Postgrad Med J* 2018;94(1107):20–24
- 36 Gradl G, Falk S, Mittlmeier T, Wendt M, Mielsch N, Gradl G. Fixation of intra-articular fractures of the distal radius using intramedullary nailing: a randomized trial versus palmar locking plates. *Injury* 2016;47(Suppl 7):S25–S30
- 37 Perugia D, Guzzini M, Mazza D, Iorio C, Civitenga C, Ferretti A. Comparison between Carbon-PEEK volar locking plates and titanium volar locking plates in the treatment of distal radius fractures. *Injury* 2017;48(Suppl 3):S24–S29
- 38 Landgren M, Abramo A, Geijer M, Kopylov P, Tägil M. Fragment-Specific Fixation Versus Volar Locking Plates in Primarily Non-reducible or Secondarily Redisplaced Distal Radius Fractures: A Randomized Controlled Study. *J Hand Surg Am* 2017;42(03):156–165.e1
- 39 Andrade-Silva FB, Rocha JP, Carvalho A, Kojima KE, Silva JS. Influence of postoperative immobilization on pain control of patients with distal radius fracture treated with volar locked plating: A prospective, randomized clinical trial. *Injury* 2019;50(02):386–391
- 40 Hohmann E, Meta M, Navalgund V, Tetsworth K. The relationship between radiological alignment of united distal radius fractures and functional and patient-perceived outcomes in elderly patients. *J Orthop Surg (Hong Kong)* 2017;25(01):2309499016684976
- 41 Gutiérrez-Monclus R, Gutiérrez-Espinoza H, Zavala-González J, Olguín-Huerta C, Rubio-Oyarzún D, Araya-Quintanilla F. Correlation Between Radiological Parameters and Functional Outcomes in Patients Older Than 60 Years of Age With Distal Radius Fracture. *Hand (N Y)* 2019;14(06):770–775
- 42 Kwok IH, Leung F, Yuen G. Assessing results after distal radius fracture treatment: a comparison of objective and subjective tools. *Geriatr Orthop Surg Rehabil* 2011;2(04):155–160
- 43 Dacombe PJ, Amirfeyz R, Davis T. Patient-Reported Outcome Measures for Hand and Wrist Trauma: Is There Sufficient Evidence of Reliability, Validity, and Responsiveness? *Hand (N Y)* 2016;11(01):11–21
- 44 Kleinlugtenbelt YV, Nienhuis RW, Bhandari M, Goslings JC, Poolman RW, Scholtes VA. Are validated outcome measures used in distal radial fractures truly valid? A critical assessment using the Consensus-based Standards for the selection of health Measurement Instruments (COSMIN) checklist. *Bone Joint Res* 2016;5(04):153–161
- 45 Sando IC, Malay S, Chung KC. Analysis of publication bias in the literature for distal radius fracture. *J Hand Surg Am* 2013;38(05):927–934.e5
- 46 Shyamalan G, Theokli C, Pearse Y, Tennent D. Volar locking plates versus Kirschner wires for distal radial fractures—a cost analysis study. *Injury* 2009;40(12):1279–1281
- 47 Wilcke MK, Abbaszadegan H, Adolphson PY. Patient-perceived outcome after displaced distal radius fractures. A comparison between radiological parameters, objective physical variables, and the DASH score. *J Hand Ther* 2007;20(04):290–298, quiz 299
- 48 Martinez-Mendez D, Lizaur-Utrilla A, de-Juan-Herrero J. Intra-articular distal radius fractures in elderly patients: a randomized prospective study of casting versus volar plating. *J Hand Surg Eur Vol* 2018;43(02):142–147
- 49 Mulders MAM, Walenkamp MMJ, Goslings JC, Schep NWL. Internal plate fixation versus plaster in displaced complete articular distal radius fractures, a randomised controlled trial. *BMC Musculoskelet Disord* 2016;17:68
- 50 Saving J, Severin Wahlgren S, Olsson K, et al. Nonoperative Treatment Compared with Volar Locking Plate Fixation for Dorsally Displaced Distal Radial Fractures in the Elderly: A Randomized Controlled Trial. *J Bone Joint Surg Am* 2019;101(11):961–969
- 51 Arora R, Lutz M, Hennerbichler A, Krappinger D, Espen D, Gabl M. Complications following internal fixation of unstable distal radius fracture with a palmar locking-plate. *J Orthop Trauma* 2007;21(05):316–322

- 52 Esenwein P, Sonderegger J, Gruenert J, Ellenrieder B, Tawfik J, Jakubietz M. Complications following palmar plate fixation of distal radius fractures: a review of 665 cases. *Arch Orthop Trauma Surg* 2013;133(08):1155–1162
- 53 Rampoldi M, Marsico S. Complications of volar plating of distal radius fractures. *Acta Orthop Belg* 2007;73(06):714–719
- 54 Rozentel TD, Blazar PE. Functional outcome and complications after volar plating for dorsally displaced, unstable fractures of the distal radius. *J Hand Surg Am* 2006;31(03):359–365
- 55 Ahsan ZS, Yao J. The importance of pronator quadratus repair in the treatment of distal radius fractures with volar plating. *Hand (N Y)* 2012;7(03):276–280