



Original article

Functional evaluation of arthroscopic treatment of SLAP lesions through the O'Brien portal[☆]



Fabiano Rebouças, Bruno Cesar Pereira, Ricardo Dantas Rocha*, Cantídio Salvador Filardi, Miguel Pereira da Costa, Romulo Brasil Filho, Antonio Carlos Tenor Junior

Hospital do Servidor Público Estadual, São Paulo, SP, Brazil

ARTICLE INFO

Article history:

Received 25 August 2013

Accepted 29 May 2014

Available online 12 June 2015

Keywords:

Shoulder joint

Shoulder dislocation/surgery

Joint instability

Arthroscopy

ABSTRACT

Objective: To evaluate the functional results from arthroscopic repair of SLAP lesions through the portal described by O'Brien.

Methods: A retrospective evaluation was conducted on 19 shoulders in 18 patients who underwent arthroscopic repair of SLAP lesions through the O'Brien portal between November 2007 and January 2012.

Results: Nineteen shoulders in 18 patients were evaluated: 16 male patients (84.2%) and three female patients (15.7%). The patients' ages ranged from 27 to 40 years (mean of 34.3 years). There were 12 patients (63.1%) with injuries on the right shoulder, six (31.5%) with injuries on the left shoulder and one (5.2%) with bilateral injury. In relation to dominance, 13 patients (68.4%) presented the injury on the dominant limb and five (26.3%) were affected on the non-dominant limb. We observed that nine cases (47.3%) had SLAP lesions alone and 10 cases (52.6%) were related to glenohumeral instability. There was one case (5.2%) of recurrence of glenohumeral dislocation, but this patient chose not to undergo a new surgical intervention. According to the UCLA and ASES scales translated and adapted to the Portuguese language, 96% of the results were good or excellent.

Conclusion: The approach for treating SLAP lesions through the portal described by O'Brien et al. is easy to reproduce, with a high rate of good and excellent results and a low complication rate.

© 2014 Sociedade Brasileira de Ortopedia e Traumatologia. Published by Elsevier Editora Ltda. All rights reserved.

Avaliação funcional do tratamento artroscópico da lesão SLAP pelo portal O'Brien

RESUMO

Objetivo: Avaliar os resultados funcionais do reparo artroscópico da lesão SLAP pelo portal descrito por O'Brien.

Palavras-chave:

Articulação do ombro

[☆] Work developed in the Department of Orthopedics and Traumatology, Hospital do Servidor Público Estadual, São Paulo, SP, Brazil.

* Corresponding author.

E-mail: ricardortop@yahoo.com (R.D. Rocha).

<http://dx.doi.org/10.1016/j.rboe.2015.05.006>

2255-4971/© 2014 Sociedade Brasileira de Ortopedia e Traumatologia. Published by Elsevier Editora Ltda. All rights reserved.

Luxação do ombro/cirurgia
Instabilidade articular
Artroscopia

Métodos: Foi feita avaliação retrospectiva de 19 ombros de 18 pacientes submetidos ao reparo artroscópico da lesão SLAP pelo portal de O'Brien, de novembro de 2007 a janeiro de 2012.

Resultados: Foram avaliados 19 ombros de 18 pacientes, 16 (84,2%) do sexo masculino e três (15,7%) do feminino. A idade variou de 27 a 40 anos (média de 34,3). No estudo, 12 (63,1%) pacientes tiveram lesão no ombro direito, seis (31,5%) no ombro esquerdo e houve um (5,2%) caso de lesão bilateral. Em relação à dominância, 13 (68,4%) pacientes apresentaram a lesão no membro dominante e cinco (26,3%) tiveram o membro não dominante acometido. Observamos que nove (47,3%) casos tiveram lesão SLAP isolada, 10 (52,6%) casos foram relacionados a instabilidade glenoumeral e apenas um (5,2%) caso teve recidiva da luxação glenoumeral. Esse paciente optou por não fazer nova intervenção cirúrgica. De acordo com as escalas ULCA e ASES traduzida e adaptada para a língua portuguesa, obteve-se 96% de excelentes e bons resultados.

Conclusão: A abordagem da lesão SLAP pelo portal descrito por O'Brien et al. é de fácil reprodutibilidade, com alto índice de excelentes e bons resultados e baixo índice de complicações.

© 2014 Sociedade Brasileira de Ortopedia e Traumatologia. Publicado por Elsevier Editora Ltda. Todos os direitos reservados.

Introduction

With the advent of arthroscopy of the shoulder, it is now possible to diagnose types of labral lesion that was not diagnosed by means of radiographic methods. One type of lesion involving the upper area of the glenoid labrum, which begins posteriorly and extends anteriorly to the glenoid cavity, is named the SLAP lesion (superior labrum anterior and posterior). This area of the glenoid labrum is functionally important for the upper stability of the shoulder and also serves as an "anchor" for the insertion of the long head of the tendon of the biceps brachii muscle.^{1,2}

SLAP lesions were first described by Andrews et al.³ in 1985 and were subsequently classified into four subtypes by Snyder et al.¹ in 1990. In 1995, Maffet et al.⁴ added type V to the classification of Snyder et al.¹ This comprises lesions of the upper glenoid labrum that extends to the anteroinferior region. In 1998, Morgan et al.⁵ subdivided type II into three subtypes according to the location of the lesion in the upper glenoid labrum: anterior, posterior or combined.

The exact etiology of SLAP lesions remains a matter of controversy. However, two possible causes have been described in the literature: compression forces applied to the glenohumeral joint consequent to a fall with the shoulder in a position of abduction and flexion; or tension forces applied to the arm, caused by a traction mechanism applied to the upper limb as a result of a throwing movement, which is particularly observed among baseball players.⁶⁻⁸

The objective of the present study was to evaluate the functional results from arthroscopic repair of SLAP lesions through the portal described by O'Brien.^{9,10}

Materials and methods

A retrospective evaluation was performed on 19 shoulders of 18 patients who underwent arthroscopic repair of SLAP lesions through the O'Brien portal between November 2007 and January 2012. The inclusion criterion was that

the patients undergoing arthroscopic surgical treatment of SLAP lesions had not responded clinically to conservative treatment. Patients with histories of previous surgery or extra-articular diseases in the shoulder that was to be evaluated were excluded.

SLAP lesions were diagnosed when there was a positive O'Brien test in association with magnetic resonance imaging of the knee suggestive of a lesion in the upper glenoid labrum and arthroscopic observation of the lesion.

The following were recorded: the time that elapsed between the start of symptoms of the lesion and the surgical treatment; and the patient's age, sex, occupation and return to sport (activity level). Postoperative function was assessed using the UCLA and ASES scales in the versions translated and adapted to the Portuguese language.^{2,11-13} Data were gathered by means of physical examination (O'Brien, Jobe and Patte tests) and a questionnaire that was applied to all the patients.

The surgical procedures were performed by the same surgical team, with the patient under general anesthesia, without blockage of the brachial plexus. The patient was placed in the "deckchair" position. A posterior portal was used to introduce the arthroscopic optical device, and this was located 2 cm distally and 2 cm medially to the posterolateral angle of the acromion. The joint was investigated using the reference point of the tendon of the long head of the biceps brachii muscle and its upper labral origin. Following this, the anterior, inferior and posterior labra, joint surfaces, glenohumeral ligaments, rotator cuff, capsule and joint recesses were evaluated.

The following intraoperative diagnostic criteria for SLAP lesions were then used: a positive drive-through test (easy passage of the arthroscopic optical device through the glenohumeral space); positive peel-back test (glenoid labrum opening greater than 1 cm during abduction and external rotation of the shoulder); and direct viewing of the degenerated and fibrillated labral tissue with signs of avulsion¹⁴ (Fig. 1).

A portal was constructed in the anterior region in order to place the first 8.5 mm cannula (portal 1), while keeping to the side of the coracoid process in order to minimize the risk

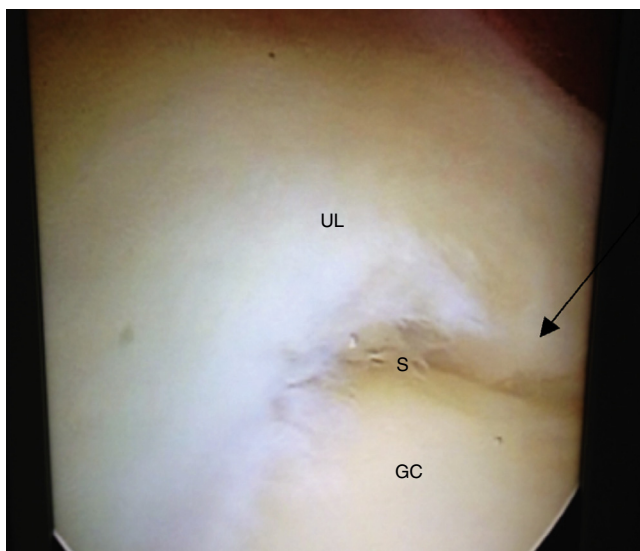


Fig. 1 – Identification of SLAP lesion (arrow). UL, upper labrum; S, SLAP lesion; GC, glenoid cavity.

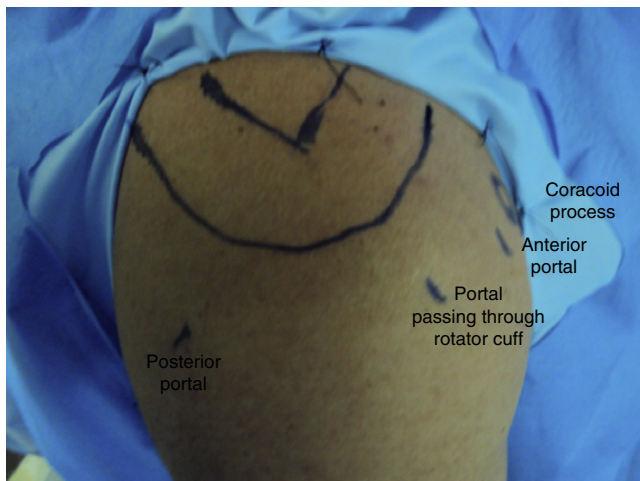


Fig. 2 – Demarcation of the bone anatomical parameters and probable location of the anterior portal and the portal passing through the rotator cuff.

of neurovascular injuries. This cannula was placed above the upper border of the tendon of the subscapular muscle (anterior rotator interval).

To construct the arthroscopic portal described by O'Brien et al.⁹ (portal 2) (Fig. 2) and place the second 8.5 mm cannula, a

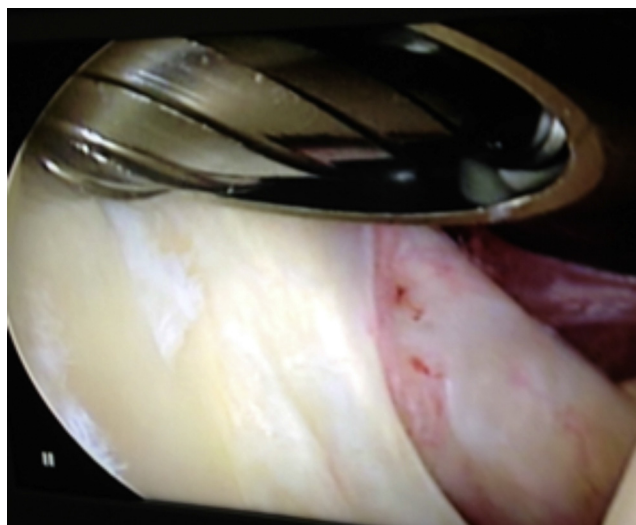


Fig. 4 – Opening up of the upper glenoid rim using a shaving blade.

Jelco no. 14 needle was placed in the superolateral region of the shoulder, through the rotator cuff, in the direction of the posterosuperior region of the glenoid (Fig. 3). The location of the portal varied according to the anatomy of the patient's shoulder and the location of the posterior labral deinsertion, with the aim of facilitating access to the posterosuperior region of glenoid and to the glenoid labrum.

After the portals had been constructed, the process of opening up the upper glenoid rim (and the anterior rim when necessary) was started, using a 4 mm bone shaving blade (Fig. 4), in order to form a bloody bed that would favor healing of the labrum-capsule complex that would be reinserted.

To reinsert the glenoid labrum, two absorbable polylactic acid anchors of size 2.7 m were placed using nonabsorbable thread, starting from the anterosuperior region. The anterior portal (portal 1) was used as the main one and the O'Brien portal (portal 2) was used as an auxiliary. To reinsert the labrum posteriorly to the tendon of the biceps, the O'Brien portal (portal 2) was used as the main one and the anterior portal (portal 1) as an auxiliary. To pass the threads through the glenoid labrum, curved bird-beak instruments alone were used (Fig. 5A-F).

In the cases in which the patient presented anterior glenohumeral instability with an anteroinferior lesion of the glenoid

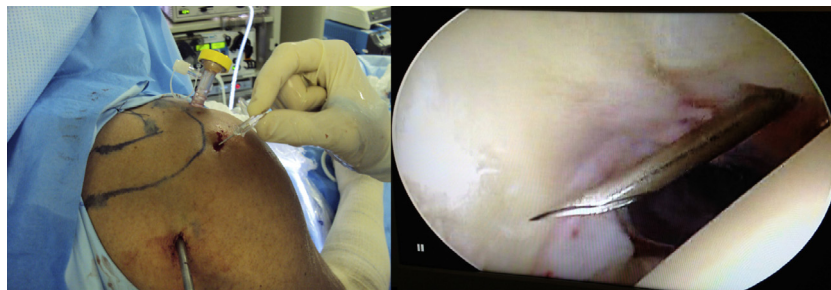

Fig. 3 – Construction of O'Brien portal under external viewing and arthroscopic viewing of the joint.

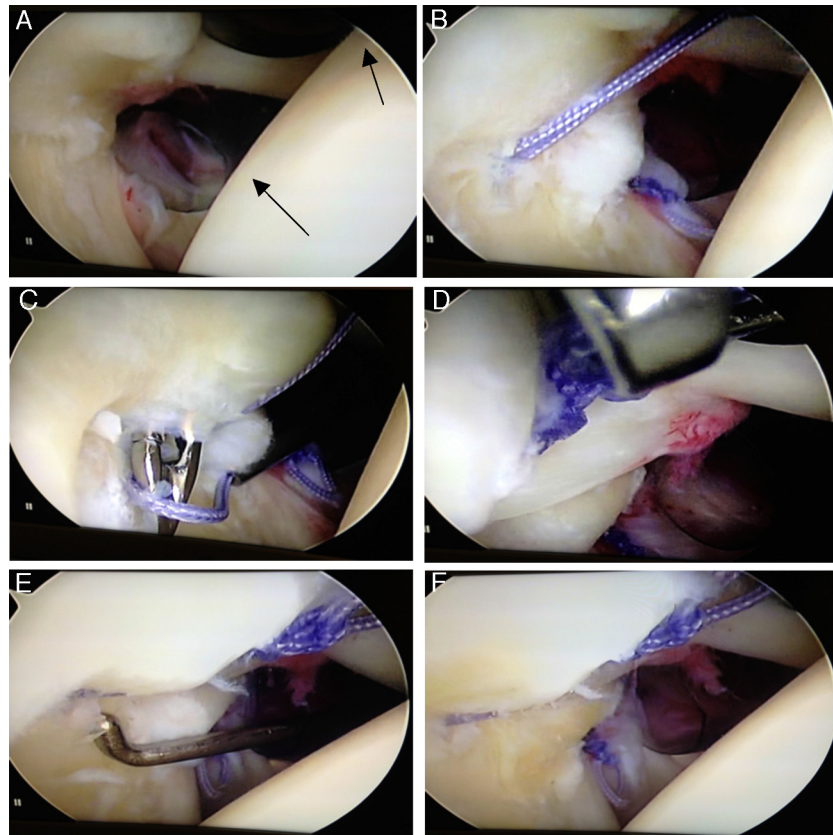


Fig. 5 – (A) Arthroscopic view of the cannulae at the anterior portals of O'Brien (arrows). (B) Anterior labrum reinserted and anchor inserted at the posterior glenoid rim. (C) Passage of bird beak through the posterosuperior glenoid labrum. (D) Suturing of the posterior labrum. (E) Stability test on the upper glenoid labrum using probe. (F) Negative peel-back test.

labrum (Bankart lesion), labral reinsertion was always started in an anticlockwise direction, from the anteroinferior region to the posterior region, using another two anchors (total of four). After labral reinsertion, dermal suturing of the portals was performed and the operated limb was then immobilized using a Velpeau sling.

Results

Nineteen shoulders were evaluated, in 18 patients: 16 males (84.2%) and three females (15.7%). The minimum postoperative follow-up was seven months and the maximum was 56 months (mean of 33.9). The patients' ages ranged from 27 to 40 years (mean of 34.3). There were 12 patients (63.1%) with a lesion in the right shoulder, six cases (31.5%) in the left shoulder and one case (5.2%) of bilateral lesions. In relation to dominance, 13 patients (68.4%) presented the lesion in the dominant limb and five (26.3%) in the non-dominant limb.

From the evaluations on these 19 shoulders, we observed that nine cases (47.3%) had SLAP lesions alone, 10 cases (52.6%) were related to glenohumeral instability and a single case (5.2%) presented recurrence of glenohumeral dislocation. This patient decided not to undergo a new surgical intervention (Table 1).

In relation to sports activity, nine patients were practicing a variety of sports before the injury (volleyball, swimming and

tennis) and nine were not. After the surgical treatment, eight of the nine patients returned to the sports that they had been doing before the treatment. One patient did not return to the sports activity that he had practiced, but he did not correlate this with the surgical result.

According to the UCLA scale, as adapted to the Portuguese language, 10 patients (52.6%) obtained results that were considered to be excellent, seven (36.8%) presented good results, a single patient (5.2%) obtained a fair result and these were no poor results^{2,13} (Fig. 6).

Table 1 – Sample of patients with SLAP lesions who underwent surgical treatment.

No. of shoulders	19
No. of patients	18
Mean age (years)	34.3
Sex	
Male	16 (84.2%)
Female	3 (15.7%)
Limb affected	
Right	12 (63.1%)
Left	6 (31.5%)
Bilateral	1 (5.2%)
Dominant	13 (68.4%)
Non-dominant	5 (26.3%)

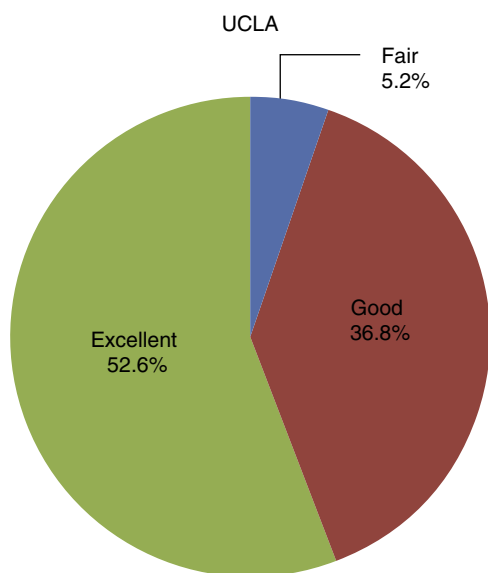


Fig. 6 – Result from postoperative evaluation according to UCLA scale, as adapted to the Portuguese language.

In relation to the ASES scale, as adapted to the Portuguese language, 58% of the patients obtained scores of 100%, 17% obtained 95%, 21% obtained 90% and 4% obtained 70% (Fig. 7).

All the 18 patients, who all completed the study follow-up, presented negative Jobe and Patte tests in the physical examination conducted at the time of the functional evaluation. The mean time taken for release from the outpatient follow-up was six months.

Discussion

In our sample, we found epidemiological agreement with the literature consulted, with predominance of SLAP lesions in males (84.2%) and higher frequency of lesions affecting the dominant limb (68.4%).^{1,6,8,10,11} The mean age among our patients was 34.3 years, which was similar to the age found

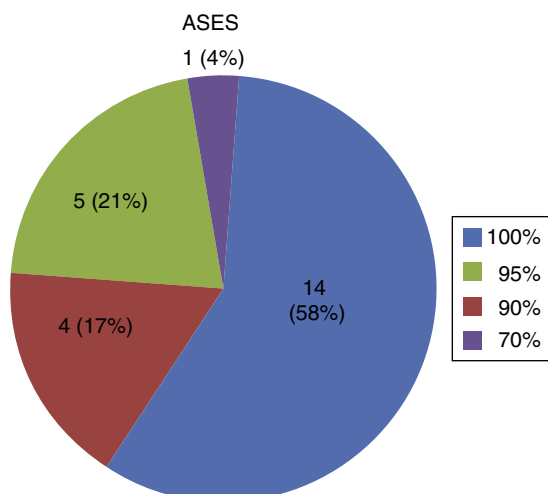


Fig. 7 – Result from postoperative evaluation according to ASES scale, as adapted to the Portuguese language.

in the study by Miyazaki et al.,⁶ but greater than that of other studies.^{7,11}

The treatment for SLAP lesions varies from conservative to arthroscopic surgery. In arthroscopic procedures, an anterosuperior and/or anteroinferior portal is used in most cases, with a route through the rotator interval to reach the labral lesions of the upper and lower glenoid. These portals limit access to the posterior and superior region of the glenoid for placement of an anchor and reinsertion of the posterior labrum.

Accessory portals for attempting to facilitate posterolateral access have been described, such as the Neviaser portal and transacromial portals. However, there is a risk of injury to the suprascapular nerve and fractures of the acromion.¹⁴⁻¹⁶

More recently, Warner et al.¹⁷ described the use of an anterolateral portal for accessing the posterolateral region of the glenoid labrum. However, this portal would require a wide incision in the tendon of the rotator cuff.

O'Brien et al.⁹ developed a portal for accessing upper labral lesions that would enable access to the anterior and posterolateral regions of the glenoid labrum. This was described as a reliable technique that was easily reproducible, using a needle to locate the most appropriate region for accessing the posterior labral lesions. The potential risk of injury to the rotator cuff was minimized by using cannulae of smaller diameters, which only gave rise to division of the fibers at the muscle-tendon junction of the supraspinatus muscle.

In the study by O'Brien et al.,⁹ arthroscopic repair of SLAP lesions was performed in 31 patients using a portal passing through the rotator cuff. No injuries to the rotator cuff confirmed by magnetic resonance imaging were observed. Oh et al.¹⁸ obtained excellent postoperative results from arthroscopic repairs to SLAP lesions using a portal passing through the rotator cuff in 58 shoulders, thus confirming the safety and efficiency of this portal. In our sample, no evidence of weakness of the rotator cuff, as assessed through the Jobe and Patte tests, was observed. Nor was there any diminution of the range of motion of the operated shoulder.

In our series of 19 shoulders, in 18 patients who were treated for SLAP lesions with a mean postoperative follow-up of 33.9 months, good clinical results were found through evaluations using the ASES and UCLA scales, as translated and adapted to the Portuguese language. It was found that 96% of the results were excellent or good, similar to the findings from other studies.^{6,8,18}

Conclusion

The present study demonstrated that accessing SLAP lesions from portals passing through the rotator cuff, as described by O'Brien et al., was easily reproducible, with a high rate of excellent and good results and a low complication rate.

Conflicts of interest

The authors declare no conflicts of interest.

REFERENCES

1. Snyder SJ, Karzel RP, Del Pizzo W, Ferkel RD, Friedman MJ. Slap lesions of the shoulder. *Arthroscopy*. 1990;6(4):274-9.
2. Keener JD, Brophy RH. Superior labral tears of the shoulder: pathogenesis, evaluation, and treatment. *J Am Acad Orthop Surg*. 2009;17(10):627-37.
3. Andrews JR, Carson WG Jr, McLeod WD. Glenoid labrum tears related to the long head of the biceps. *Am J Sports Med*. 1985;13(5):337-41.
4. Maffet MW, Gartsman GM, Moseley B. Superior labrum-biceps tendon complex lesions of the shoulder. *Am J Sports Med*. 1995;23(1):93-8.
5. Morgan CD, Burkhart SS, Palmeri M, Gillespie M. Type II Slap lesions: three subtypes and their relationships to superior instability and rotator cuff tears. *Arthroscopy*. 1998;14(6):553-65.
6. Miyazaki AN, Fregoneze M, Santos PD, Silva LA, Sella GV, Soares AL, et al. Avaliação dos resultados e complicações da sutura artroscópica da lesão Slap. *Rev Bras Ortop*. 2011;46(1):51-6.
7. Selby RM, Altchek DW, Di Giacomo G. The Di Giacomo technique: simplified suture passing in Slap repair. *Arthroscopy*. 2007;23(4):439, e1-2.
8. Kim SH, Ha KI, Kim SH, Choi HJ. Results of arthroscopic treatment of superior labral lesions. *J Bone Joint Surg Am*. 2002;84(6):981-5.
9. O'Brien SJ, Allen AA, Coleman SH, Drakos MC. The trans-rotator cuff approach to Slap lesions: technical aspects for repair and a clinical follow-up of 31 patients at a minimum of 2 years. *Arthroscopy*. 2002;18(4):372-7.
10. Brockmeier SF, Voos JE, Williams RJ 3rd, Altchek DW, Cordasco FA, Allen AA. Outcomes after arthroscopic repair of type-II SLAP lesions. *J Bone Joint Surg Am*. 2009;91(7):1595-603.
11. Godinho GG, Freitas JMA, Leite LMB, Pina ERM. Lesões Slap no ombro. *Rev Bras Ortop*. 1998;33(5):345-52.
12. Coleman SH, Cohen DB, Drakos MC, Allen AA, Williams RJ, O'Brien SJ, et al. Arthroscopic repair of type II superior labral anterior posterior lesions with and without acromioplasty: a clinical analysis of 50 patients. *Am J Sports Med*. 2007;35(5):749-53.
13. Kim TK, Queale WS, Cosgarea AJ, McFarland EG. Clinical features of the different types of Slap lesions: an analysis of one hundred and thirty-nine cases. *J Bone Joint Surg Am*. 2003;85(1):66-71.
14. McFarland EG, Neira CA, Gutierrez MI, Cosgarea AJ, Magee M. Clinical significance of the arthroscopic drive-through sign in shoulder surgery. *Arthroscopy*. 2001;17(1):38-43.
15. Katz LM, Hsu S, Miller SL, Richmond JC, Khetia E, Kohli N, et al. Poor outcomes after Slap repair: descriptive analysis and prognosis. *Arthroscopy*. 2009;25(8):849-55.
16. Coen MJ, Jobe CM, Pak K. Acromial compromise with use of a transacromial portal: a biomechanical study. *J Shoulder Elbow Surg*. 1995;4(4):249-53.
17. Warner JJ, Kann S, Marks P. Arthroscopic repair of combined Bankart and superior labral detachment anterior and posterior lesions: technique and preliminary results. *Arthroscopy*. 1994;10(4):383-91.
18. Oh JH, Kim SH, Lee HK, Jo KH, Bae KJ. Trans-Rotator cuff portal is safe for arthroscopic superior labral anterior and posterior lesion repair: clinical and radiological analysis of 58 Slap lesions. *Am J Sports Med*. 2008;36(10):1913-21.