

Limb Length Discrepancy on an 11-Month-Old Boy with Osteoid Osteoma*

Discrepância de membros em menino de 11 meses de idade associada a osteoma osteoide

Ana Cotta¹ Renato Cesar Rezende de Castro² Julia Filardi Paim¹ Leonardo Sardenberg Fiuza²
Maria Henriqueta Freire Lyra³

¹Departamento de Patologia, Rede SARAH de Hospitais de Reabilitação, Belo Horizonte, MG, Brazil

²Departamento de Cirurgia e Ortopedia, Rede SARAH de Hospitais de Reabilitação, Belo Horizonte, MG, Brazil

³Departamento de Radiologia, Rede SARAH de Hospitais de Reabilitação, Belo Horizonte, MG, Brazil

Address for correspondence Ana Cotta, Departamento de Patologia, Rede SARAH de Hospitais de Reabilitação, Belo Horizonte, MG, Brazil (e-mail: ana_cotta@yahoo.com.br).

Rev Bras Ortop 2019;54:210–213.

Abstract

Osteoid osteoma is a benign bone tumor that frequently occurs between the ages of 10 and 25 years old; in about 80% of the patients, it is associated with intense pain. The present article describes the case of an 11-month-old infant with claudication, right lower limb shortening, and painless right leg volume increase. Image studies demonstrated an osteolytic lesion with small ossifications within, involved by cortical thickening of the right tibial diaphysis. The diagnostic hypotheses were osteoid osteoma, chronic osteomyelitis (Brodie abscess), Ewing sarcoma, and Langerhans cell histiocytosis. Microorganism cultures were negative and the histopathological exam demonstrated osteoid osteoma. The present report expands the knowledge on osteoid osteoma as a cause of painless limping and lower limb shortening in infancy. The early differential diagnosis is important, as surgical excision is curative and prevents further complications.

Keywords

- ▶ osteoid osteoma
- ▶ diagnosis
- ▶ bone neoplasm
- ▶ child
- ▶ biopsy

Resumo

Osteoma osteoide é um tumor ósseo benigno, mais frequente dos 10 aos 25 anos de idade e, em cerca de 80% dos pacientes, está associado a dor forte. O presente artigo descreve um paciente masculino apresentando claudicação, encurtamento do membro inferior direito e aumento de volume indolor da perna direita desde os 11 meses de idade. Os exames de imagem demonstraram lesão osteolítica contendo pequenas ossificações de permeio, envolvidas por espessamento cortical da diáfise da tíbia direita. As hipóteses diagnósticas de osteoma osteoide, de osteomielite crônica (abscesso de Brodie), de sarcoma de Ewing e de histiocitose de células de Langerhans foram levantadas. As culturas para microrganismos foram negativas e o exame histopatológico demonstrou osteoma osteoide. O presente relato expande o conhecimento sobre osteoma osteoide como causa de claudicação e discrepância de membros inferiores indolor em lactente. O diagnóstico diferencial precoce é importante, pois a exérese da lesão é curativa e previne sequelas futuras.

Palavras-chave

- ▶ osteoma osteoide
- ▶ diagnóstico
- ▶ neoplasias ósseas
- ▶ criança
- ▶ biópsia

* Study conducted at Rede SARAH de Hospitais de Reabilitação, Belo Horizonte, MG, Brazil. Published originally by Elsevier Ltda.

Introduction

Osteoid osteoma is a benign bone tumor, smaller than 2 cm diameter, constituted by osteoid bone microtrabeculae and circumscribed by sclerotic bone tissue.¹⁻³ Image studies demonstrate a radiolucent nidus circumscribed by cortical sclerosis, that may contain an ossified center with an aspect of a target. Computed tomography is considered the best method for diagnosis and it must be performed using 1 mm thick intervals.²

Clinically, osteoid osteoma presents disproportionate pain, that initially occurs intermittently at night, generally responsive to non-steroid anti-inflammatory drugs in 80% of the patients.²

Osteoid osteoma is more prevalent between 10 and 25 years old, but rarely it may occur from seven months

old until 70 years old.^{4,5} The most common sites are long bone diaphysis and metaphysis, specially femur and tibia.⁴

Case Report

A 14 months old boy was admitted on our service. He had started gait at 11 months old, with right limping since gait acquisition and right leg volume increase. There was no history of fever, local trauma, falls, inflammatory signs, joint movements restriction or contralateral involvement.

In another service, he had been submitted to roentgenogram of the right leg, with the visualization of a lesion in the right tibial proximal third. He had received a diagnosis of fracture. He had received a prescription of physical therapy that was performed for two months (12 and 13 months old) without any improvement.

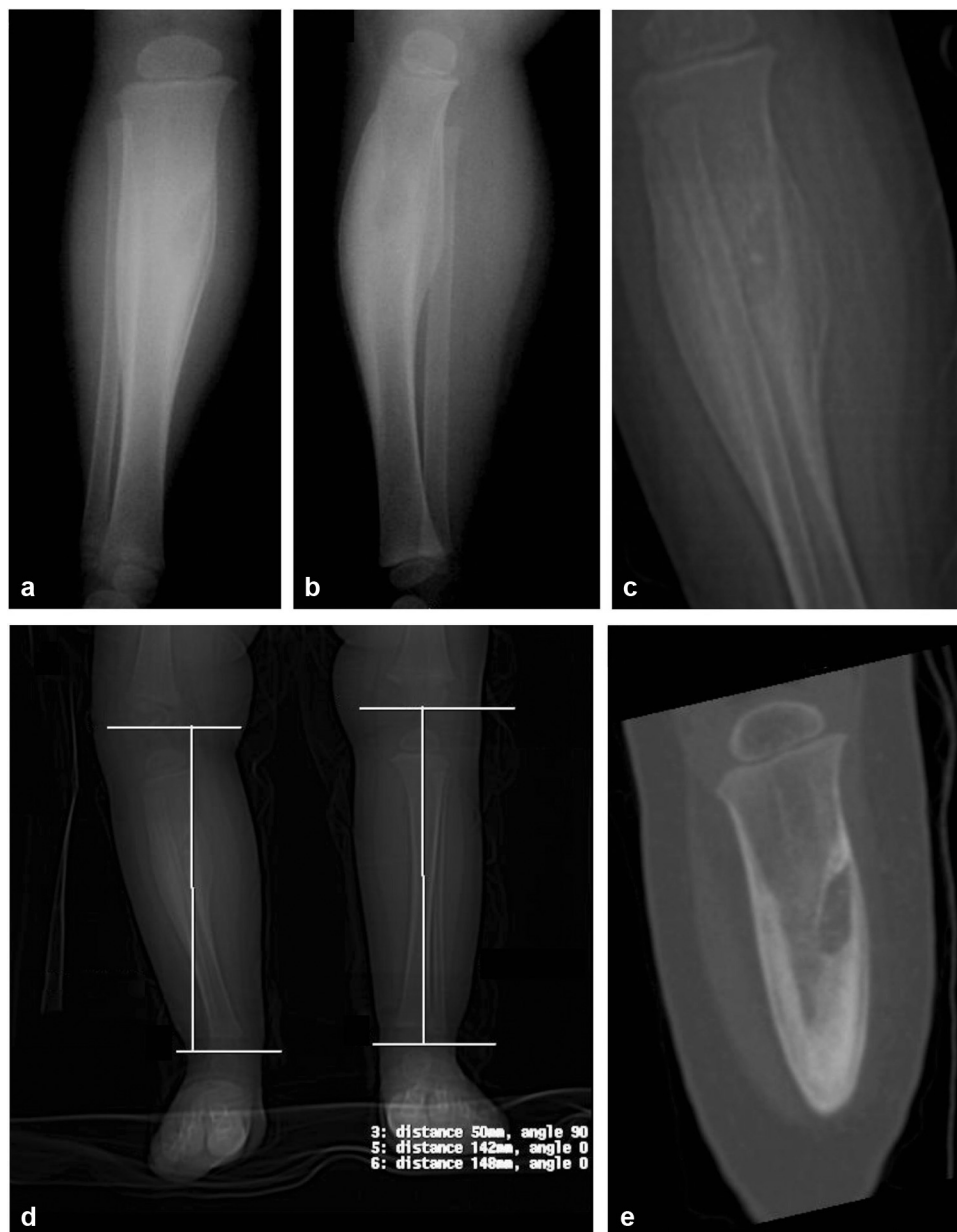

Fig. 1 Osteolytic lesion with sclerosis and calcifications in the right tibia; a, roentgenogram AP; b, profile, c, magnification; d, scanometry; e, coronal oblique reformation.

After admission in this service, at 14 months old, he was submitted to scanometry and computed tomography. Scanometry demonstrated a 6 mm right lower limb shortening: 14.2 cm right tibia, 14.8 cm left tibia, 16.4 right femur, 16.4 left femur, 30.6 right lower limb, and 31.2 left lower limb (►Fig. 1). Right leg computed tomography demonstrated an extensive medium and proximal third right tibia cortical thickening, with a small 1.6×0.7 cm radiolucent area in the tibial medial third with small ossifications within (►Fig. 2).

Laboratorial exams demonstrated normal erythrocyte sedimentation rate 10 mm in the first hour (reference below 2), C reactive protein below 3.1 mg/L (reference below 3.5), negative sickle cells test, slight microcytosis and no leukocytosis.

Diagnostic hypotheses were tibial cortical osteoid osteoma, chronic osteomyelitis (Brodie's abscess), Ewing sarcoma and Langerhans cell histiocytosis (eosinophilic granuloma).

Due to the differential diagnosis of chronic osteomyelitis, the patient was submitted to scopy guided open bone

biopsy, after the incision site was marked with computed tomography (►Fig. 2). Samples were collected for microorganisms cultures and histopathological exam. The cultures were negative for microorganisms. The histopathological exam demonstrated a benign bone lesion, characterized by a central nidus, formed by osteoid immature tissue trabeculae, partially mineralized, admixed with richly vascularized soft connective tissue and involved externally by sclerotic bone (►Fig. 3).

Discussion

On a recent study of 31 patients, lower limb shortening was caused by fracture sequelae, hip development dysplasia, infantile paralysis, infection sequelae, and congenital short femur.⁶ Among these causes, pathological fractures below the age of five years may be associated with osteomyelitis, Langerhans cell histiocytosis, congenital tibial pseudoarthrosis, long immobilization, radiotherapy, metastasis, and Ewing sarcoma.⁷

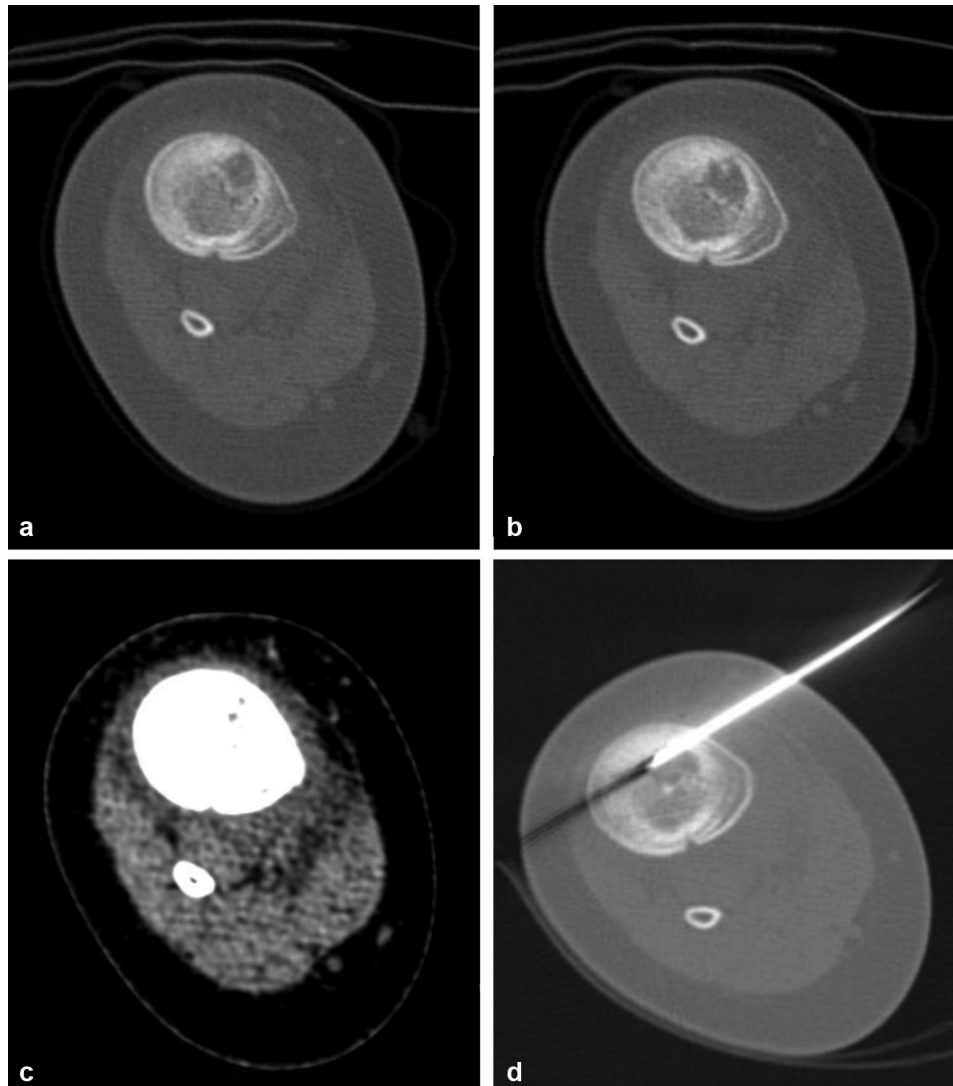


Fig. 2 Right tibia osteolytic lesion (a) with calcifications (b) and slight soft tissue heterogeneity (c). Biopsy site determination with surgical wire (d) (a, b, c, d: axial computed tomography).

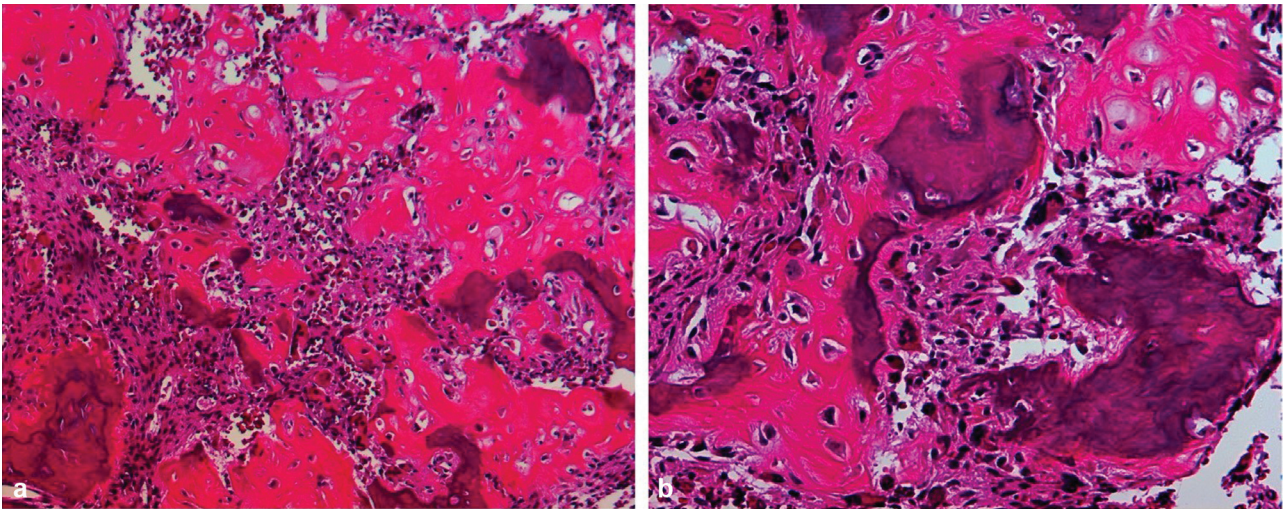


Fig. 3 Osteoid tissue microtrabeculae and vascularized soft tissue. a, HE 100 \times ; b, HE 200 \times .

Osteoarticular infections are frequent in children, with an estimated incidence of 10–25 per 100,000 children, with the possibility of deformities.⁸ There are reports of osteomyelitis mimicking osteoid osteoma.⁹ The patient did not present any systemic signs of infection and the microorganisms cultures were negative.

Langerhans cell histiocytosis occurs in patients below 30 years of age in 80% of the cases. There is pain, local volume increase and well demarcated osteolytic lesions with thick periosteal bone neoformation. Below the age of two years, there may be visceral disseminated disease with high mortality risk.² The histopathological exam of this patient did not demonstrate neither Langerhans cells nor eosinophilic proliferation.

Ewing sarcoma is a bone tumor formed by round blue cells and EWSR1 gene fusions in chromosome 22. It occurs in patients below 20 years of age in more than 80% of the cases with a higher incidence in the second decade of life. It occurs preferentially on the long bone diaphyseal of metadiaphyseal regions. Pain is usually pronounced in 96% of the patients. Intermittent fever and anemia may be observed in 21% of the patients. Image studies demonstrate a poorly defined osteolytic lesion with “moth eaten” pattern, associated with onion skin periosteal reaction. In some cases, it may present sclerosis in long bone diaphyseal lesions.² The histopathological examination of this patient did not demonstrated round blue cell proliferation.

The histopathological examination of this patient biopsy demonstrated typical osteoid osteoma abnormalities, that usually are not seen in infants and are usually followed by pain. A Pubmed/Medline search for indexed articles with the keywords “osteoid osteoma” and “limb shortening” did not find any publications of osteoid osteoma as a cause of limb shortening. This suggests that this tumor may only rarely be the etiological cause of limb shortening.

This report considerably expands the knowledge of osteoid osteoma as it demonstrates that osteoid osteoma may occur in infancy, and it may cause limping, and painless lower limb discrepancy. The correct diagnosis is fundamental as

surgical treatment is curative and it prevents further complications.

Conflicts of Interest

The authors declare no conflicts of interest.

Acknowledgments

The authors thank Cleides Campos de Oliveira and Simone Ferreira do Nascimento for histological technical assistance.

References

- Dahlin DC, Unni KK. Bone tumors: general aspects and data on 8542 cases. 4th ed. Springfield, IL: Thomas; 1987
- Fletcher CD, Bridge JA, Hogendoorn PCW, Mertens F, eds. World Health Organization (WHO) classification of tumours of soft tissue and bone. 4th ed. Lyon, France: IARC Press; 2013
- Endo RR, Gama NF, Nakagawa SA, Tyng CJ, Chung WT, Pinto FFE. Osteoid osteoma - radiofrequency ablation treatment guided by computed tomography: a case series. *Rev Bras Ortop* 2017;52(03):337–343
- Cotta AC, Melo RT, Castro RC, Souza FS, Najjar YSJ, Paim JFO, et al. Diagnostic difficulties in osteoid osteoma of the elbow: clinical, radiological and histopathological study. *Radiol Bras* 2012;45(01):13–19
- Virayavanich W, Singh R, O'Donnell RJ, Horvai AE, Goldsby RE, Link TM. Osteoid osteoma of the femur in a 7-month-old infant treated with radiofrequency ablation. *Skeletal Radiol* 2010;39(11):1145–1149
- Fernandes HP, Barronovo DG, Rodrigues FL, Hono M. Femur lengthening with monopolar external fixator associated with locked intramedullary nail. *Rev Bras Ortop* 2016;52(01):82–86
- Canavese F, Samba A, Rousset M. Pathological fractures in children: Diagnosis and treatment options. *Orthop Traumatol Surg Res* 2016;102(1, Suppl):S149–S159
- Ilharreborde B. Sequelae of pediatric osteoarticular infection. *Orthop Traumatol Surg Res* 2015;101(1, Suppl):S129–S137
- Agrawal P, Sobti A. A Brodie's abscess of femoral neck mimicking osteoid osteoma: diagnostic approach and management strategy. *Ethiop J Health Sci* 2016;26(01):81–84