






# Animal Model Standardization for Studying Avascular Necrosis of the Femoral Head in Legg-Calvé-Perthes Disease

## *Padronização de modelo animal para o estudo da necrose isquêmica da cabeça femoral na doença de Legg-Calvé-Perthes*

Edson Hidenori Miashiro<sup>1</sup> Luis Francisco Zanella<sup>2</sup> Guilherme Schiess Cardoso<sup>2</sup>  
Gislene dos Santos Silva<sup>3</sup> Kauana de Angelis<sup>3</sup> Silvio Henrique Maia de Almeida<sup>3</sup>

<sup>1</sup> Discipline of Orthopedics and Traumatology, Faculty of Medicine, Fundação Educacional do Município de Assis (FEMA), Assis, São Paulo, Brazil

<sup>2</sup> Department of Veterinary Medicine, Universidade Estadual de Londrina, Londrina, PR, Brazil

<sup>3</sup> Department of Surgery, Universidade Estadual de Londrina, Londrina, PR, Brazil

Address for correspondence Edson Hidenori Miashiro, PhD, Avenida Getúlio Vargas, 1200, Bloco 11, Vila Nova Santana, Assis, SP, Brazil (e-mail: miashirocor@gmail.com).

Rev Bras Ortop 2023;58(5):e771–e780.

### Abstract

**Objective** Testing an experimental model for ischemic necrosis of the femoral head in Legg-Calvé-Perthes disease by evaluating gait, imaging and morphohistology.

**Methods** The operation was done in 11 piglets. Necrosis by cerclage in the right femoral neck was induced. Piglets were divided into group A, with 8 animals, euthanizing two in the 2<sup>nd</sup>, 4<sup>th</sup>, 6<sup>th</sup>, and 8<sup>th</sup> weeks, respectively; and group B, with 2 animals (*sham*), submitted to the surgical procedure without cerclage of the right femoral neck. The gait classification used was that of Etterlin. The frozen femurs were submitted to digital radiography and computed tomography. The height and width of the epiphysis and epiphysary coefficient were measured at study times. Light microscopy and immunohistochemistry with TGF- $\beta$ 1 were performed.

**Results** One animal died of sepsis in Group A. In this group, claudication was observed in all animals. On digital radiography and computed tomography, bone sclerosis, enlargement of the right femoral neck, flattening, collapse, and fragmentation of the right femoral head were observed. All epiphysis height and epiphysary coefficient values of the right femoral head were lower than the contralateral ones, in which were observed chondrocytes disordered and separated by gaps. A reduction in TGF- $\beta$ 1 expression was observed at 2 and 6 weeks in the right femoral head and at eight in the left. In group B, there were no signs of necrosis and gait was normal.

### Keywords

- ▶ femur head necrosis
- ▶ ischemia
- ▶ Legg-Calvé-Perthes disease
- ▶ models, animal

*Work developed at the Veterinary Hospital of the Universidade Estadual de Londrina (surgeries); at the Universidade de São Paulo (light microscopy tests); at the Instituto de Radiologia Manoel de Abreu de Apucarana (imaging exams); at the Tumor Biology Laboratory of the Universidade Estadual do Oeste do Paraná (immunohistochemistry tests), Londrina, PR, Brazil.*

received  
October 26, 2021  
accepted  
March 28, 2022

DOI <https://doi.org/10.1055/s-0042-1749419>.  
ISSN 0102-3616.

© 2023. Sociedade Brasileira de Ortopedia e Traumatologia. All rights reserved.

This is an open access article published by Thieme under the terms of the Creative Commons Attribution-NonDerivative-NonCommercial-License, permitting copying and reproduction so long as the original work is given appropriate credit. Contents may not be used for commercial purposes, or adapted, remixed, transformed or built upon. (<https://creativecommons.org/licenses/by-nc-nd/4.0/>)

Thieme Revinter Publicações Ltda., Rua do Matoso 170, Rio de Janeiro, RJ, CEP 20270-135, Brazil

**Resumo**

**Conclusions** The model presented reproduced macroscopic necrosis on digital radiography, computed tomography, and microscopy. Gait evaluation showed a good correlation with other ischemia findings.

**Level of Evidence** V. Diagnostic studies.

**Objetivo** Testar um modelo experimental para necrose isquêmica da cabeça femoral na doença de Legg-Calvé-Perthes avaliando a marcha, exames de imagens e morfohistologia.

**Métodos** Operaram-se 11 leitões. Induziu-se a necrose por cerclagem no colo femoral direito. Dividiram-se os leitões em grupo A com 8 animais, sacrificando-se dois nas 2ª, 4ª, 6ª e 8ª semanas, respectivamente; e grupo B, com 2 animais (*sham*), submetidos ao procedimento cirúrgico sem a cerclagem do colo femoral direito. A classificação da marcha utilizada foi a de Etterlin. Os fêmures congelados foram submetidos à radiografia digital e tomografia computadorizada. Mediram-se a altura e largura da epífise e o coeficiente epifisário nos tempos de estudo. Realizou-se, microscopia de luz e imunohistoquímica com TGF-β1.

**Resultados** Um animal morreu por sepse no grupo A. Neste grupo, observou-se claudicação em todos os animais. Na radiografia digital e tomografia computadorizada observaram-se: esclerose óssea, alargamento do colo femoral direito, achatamento, colapso e fragmentação da cabeça femoral direita. Todos os valores da altura da epífise e coeficiente epifisário da cabeça femoral direita foram menores que os contralaterais, nos quais observaram-se condrócitos desordenados e separados por lacunas. Observou-se redução da expressão do TGF-β1 com 2 e 6 semanas nas cabeças femorais direitas e nas esquerdas com oito. No grupo B, não ocorreram sinais de necrose e a marcha foi normal.

**Conclusões** O modelo apresentado reproduziu a necrose macroscopicamente, na radiografia digital, tomografia computadorizada e microscopia. A avaliação da marcha demonstrou boa correlação com os demais achados de isquemia.

**Nível de Evidência** V. Estudos diagnósticos.

**Palavras-chave**

- ▶ necrose da cabeça do fêmur
- ▶ isquemia
- ▶ doença de Legg-Calvé-Perthes
- ▶ modelos animais

**Introduction**

The Legg-Calvé-Perthes disease (LCPD)<sup>1,2</sup> affects children, causing sequelae in the hip joint. There is no treatment to discontinue progressive deformity of the femoral head (FH). The scarcity of human material for the study of LCPD makes it necessary to use experimental animal models.<sup>3–10</sup>

Among emerging countries, only Argentina has a study published in this area.<sup>10</sup>

Our objective is to standardize an experimental model of femoral head ischemic necrosis (FHIN) for the study of feasible LCPD in Brazil. Also, we proposed to introduce gait evaluation tests for functional analysis.<sup>11–18</sup>

**Material and Methods**

This work was approved under the Commission of Ethics in the Use of Animals of our institution.

**Sample**

The sample was chosen according to the literature,<sup>11–20</sup> under the guidance of the Ethics Committee. Piglets were divided into two groups: group A, with 8 animals, of which 2

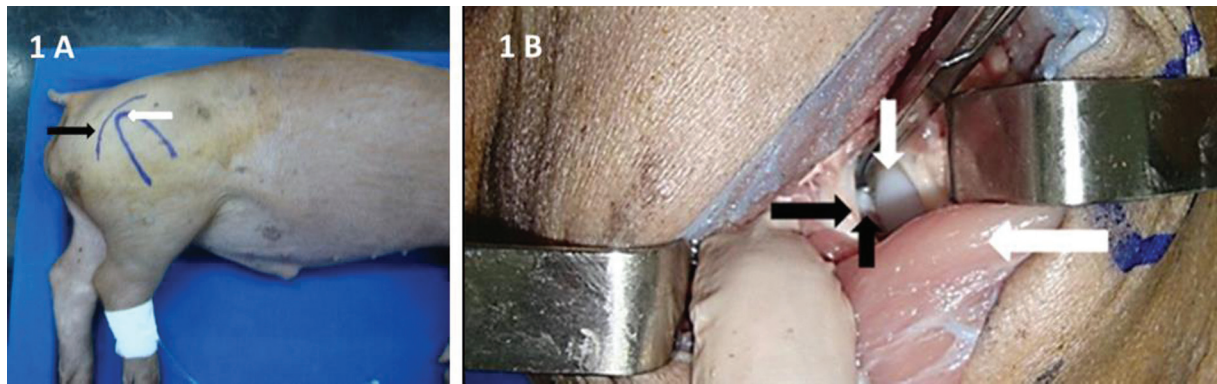
animals were euthanized in the 2<sup>nd</sup>, 4<sup>th</sup>, 6<sup>th</sup>, and 8<sup>th</sup> week after surgical induction of necrosis, respectively; group B had 2 animals submitted to the surgical procedure without cercling the right femoral neck (RFN), to prove it as a FHIN (*sham*) inducing factor. The piglets of this group were euthanized in the 6<sup>th</sup> week because the FH deformity is more evident starting from this period of ischemia.<sup>11</sup>

Eleven piglets were operated, commercial hybrids (crossing of Large White and Landrace breeds), males, weighting from 4 to 6 kg, age of 3 to 4 weeks. In group A, a piglet was removed from the study due to postoperative death from sepsis and replaced. The substitute was euthanized in the 4<sup>th</sup> week after surgery.

**Surgical Technique**

The anesthetic model used intravenous acepromazine. Then, Ketamine hydrochloride along with diazepam were applied also intravenously. Lidocaine 2% was applied via the lumbosacral epidural.

The same surgeon performed all the procedures in the operating room. The femur operated was the right one using the left one as control. The piglet was positioned in left lateral decubitus. The posterior approach was used, using the



**Fig. 1** (A) Description of posterior approach parameters. Posterior approach (black arrow). Apex of the greater trochanter (white arrow). (B) Posterior approach: deep plans. Clearance of the gluteus medius muscle with a Farabeuf (larger white arrow). Identification of the femoral head (smaller white arrow). Capsulotomy (larger black arrow). Identification of the ligamentum teres (smaller black arrow).

greater trochanter as a parameter (►Fig. 1A). Dissection was performed by planes with incision of the gluteus maximus muscle and removal of the gluteus medius muscle for capsule exposure; then, capsulotomy and longitudinal traction for hip dislocation and ligamentum teres section (►Fig. 1B) to avoid irrigation through the artery of the ligamentum teres. The procedure previously described was performed in groups A and B. Only, in group A double cerclage was performed on RFN with Prolene 2 Ethicon wire (Ethicon

Inc., Raritan, NJ, USA) using a “wire pass instrument” to induce FHIN (►Figs. 2A and 2B). The mononylon 2.0 Ethicon yarn was closed in both groups.

Tramadol and the anti-inflammatory flunixin meglumine were applied intramuscularly for analgesia.

Benazine penicillin was used, also intramuscularly.

#### Gait Assessment

The piglets were observed walking, the moment before anesthesia, on a flat surface. Gait alterations were compared in groups A and B (*sham*), in the various study times to verify the correlation of FHIN images with the presence of claudication. The gait classification for pigs proposed by Etterlin et al.<sup>21</sup> was used, ranging from 0 to 3, with grade 0: normal; grade 1: irregular gait with stride shortening and uneven load in one or more limbs; grade 2: moderate claudication with evident deviation of the load of one or more limbs and clear difficulty of ambulation; and grade 3: severe claudication without support in the affected limb or inability to move.

#### Imaging Exams

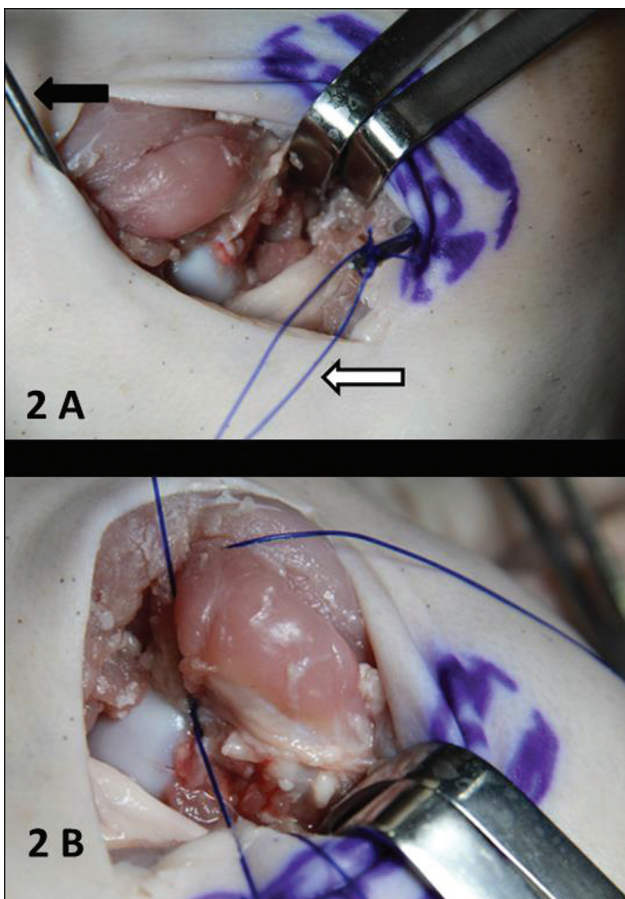
Immediately after euthanasia, the femurs were dissected and stored in a common domestic refrigerator at an average temperature of -20°C.

In both groups, digital radiography (DR) was performed at anteroposterior incidence and computed tomography (CT) was performed in frontal, axial and three dimensional (3D) sections in all entire femoral heads. The left FH was used as control. The RD Toshiba 12M 500MAS radiography device (Minato, Tokyo, Japan) and the GE Hispeed Dual model CT scanner (General Electric Company, Boston, MA, USA) were used.

#### Description of Femoral Head

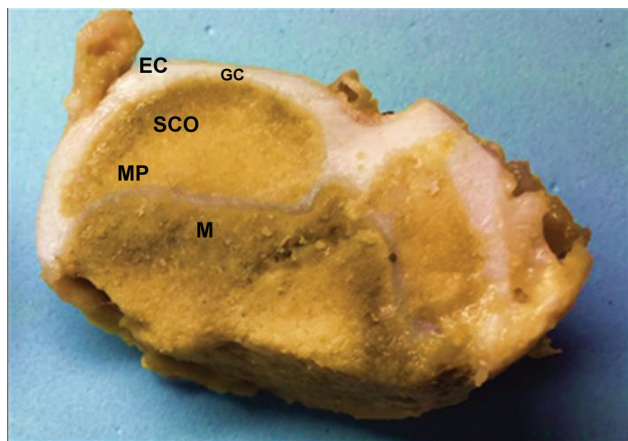
The normal FH of the immature piglet is divided into (►Fig. 3):

- Secondary center of ossification (SCO) with a semispherical format;
- Epiphyseal cartilage (EC) bypassing the SCO;
- Growth plate (GP) between the EC and the SCO, responsible for circumferential growth;



**Fig. 2** (A) Passage of two Prolene 2 Ethicon wires (white arrow) around the femoral neck with a “wire pass instrument” (black arrow). (B) Double cerclage around the femoral neck with Prolene 2 Ethicon wires.



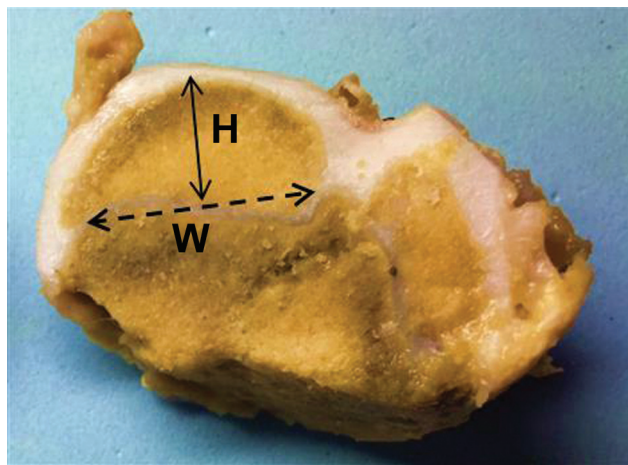


**Fig. 3** Description of the femoral head of the piglet. Front cut of the femoral head at midpoint. Secondary center of ossification (SCO) surrounded by epiphyseal cartilage (EC). Growth plate (GP) located between EC and SCO. Metaphyseal physis (MP) located at the base of the SCO. Metaphysis (M) of the proximal femur, located below MP.

- Metaphyseal physis (MP) covering the entire proximal metaphysis, being responsible for the longitudinal growth of the proximal portion of the femur.

#### Description of the Measures Used in the FH

After imaging, the femurs were cut in their proximal 1/3, in the central region of the frontal plane using a nitrogen surgical saw. Immediately, the height and width of the epiphysis were measured in the sectioned part in centimeters. The height (H) was measured from the apex of the articular surface to the midpoint of the metaphysary physis. The width (W) of the medial maximum point to the lateral maximum was measured in the metaphysary head-physis transition. The epiphysary coefficients (EC) were calculated using the ratio between A and D; they indicate the prognosis of the LCPD. The decrease in EC values indicates a worsening in prognosis.<sup>22-24</sup> (→ Fig. 4).



**Fig. 4** Description of the height and width of the epiphysis and epiphyseal coefficient (EC). The height of the epiphysis is represented by the closed arrow (H). The width of the epiphysis is represented by the dotted arrow (W). The EC is calculated by the ratio between H and W.

#### Light Microscopy

The slides were colored in hematoxylin eosin (HE) to evaluate the alterations in GP. Light microscopy (LM) was analyzed with magnifications of 40, 100, 140, 240, and 340 times.

#### Immunohistochemical Analysis

In all slides, the primary antibodies Transforming Growth Factor Beta 1 (TGF- $\beta$ 1, 1:300, Santa Cruz Biotechnology, Dallas, TX, USA) were applied.

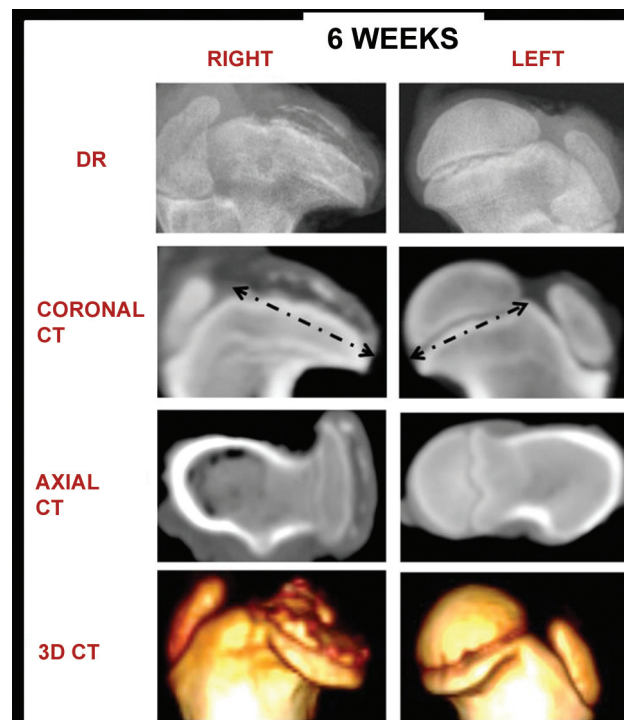
#### Statistical analysis

The descriptions included for categorical variables were: frequency calculation and respective percentage; and for the scaling variables: calculation of mean and respective standard deviation, maximum, minimum, and percentiles (25%, median - 50%, and 75%). The Wilcoxon Signed Rank Test was applied to verify possible differences between both sides, in each studied group, for the variables of interest (W, Wond, EC) with significance level  $p = 0.050$ .

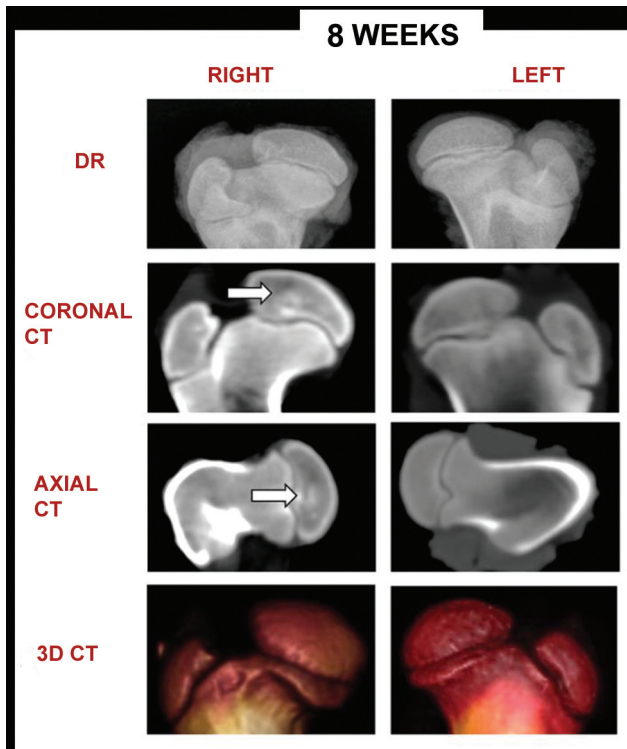
The results of immunoeexpression of TGF- $\beta$ 1 were compared two by two, i.e., the right side against the left side, at certain study times. The student's t-test, with significance level  $p = 0.050$ , was used.

#### Results

There was one death from sepsis on the second day in group A, being replaced, totaling 11 animals in the experiment.



**Fig. 5** Digital radiography (DR) and computed tomography (CT) of the proximal 1/3 of the right and left femurs of piglets euthanized after 6 weeks of ischemic induction. Total collapse and fragmentation were observed on right femora head, in DR and CT, with loss of the semispherical format. A large enlargement of the femoral neck (arrows) was observed. Collapse and fragmentation were detailed in 3D CT.



**Fig. 6** Digital radiography (DR) and computed tomography (CT) of the proximal 1/3 of the right and left femurs of piglets euthanized after 8 weeks of ischemic induction. In RD and CT, a loss of the semispherical shape and flattening of the right femoral head (FH) and sclerotic areas suggestive of necrosis of the femoral head (arrows) were observed.

In the gait evaluation, all piglets in group A presented moderate claudication with clear difficulty of ambulation (grade 2 of Etterlin et al.<sup>21</sup>). In group B, piglets presented normal gait. In group A, in DR and CT scans (►Figs. 5 and 6

and ►Table 1), and in the macroscopic evaluation (►Fig. 7 and ►Table 2), all the right FHs presented characteristic alterations of FHIN. In group B, no changes were observed (►Fig. 8).

In group A, all piglets presented values for the right FH epiphysis height and the EC lower than those for the left FH. In this group, the width of the right femoral epiphysis was greater than that of the left in 7 piglets (87.5%). The measurements of the height and width of the epiphysis and EC of the right and left FHs showed a statistically significant difference ( $p < 0.050$ ) (►Table 3).

In group B, no differences in measurements were observed between the sides of the right and left FHs ( $p^3 = 0.050$ ) (►Table 2).

There was no development of right FHIN in group B; consequently, the EC values remained equal on both sides. This corroborates that the factor inducing necrosis is RFN cerclage (►Table 2).

In the histological evaluation by LM, in the right FHs of group A piglets, chondrocytes were arranged in a disorganized way and separated by gaps. There was no clear separation between the physal layers. In the left FHs, a normal aspect was observed, that is, organization of chondrocytes in columns and visible division between the layers of the physis: proliferative, hypertrophic, and calcification zones. In group B, the same normal aspect was observed, described above, in the right and left FHs (►Fig. 9 and ►Table 3).

In the evaluation by immunohistochemical reaction in group A, a decrease in TGF-β1 expression was observed in the slides of the right FHs with 2 and 6 weeks of ischemia, and in the left FHs with eight weeks of ischemia.

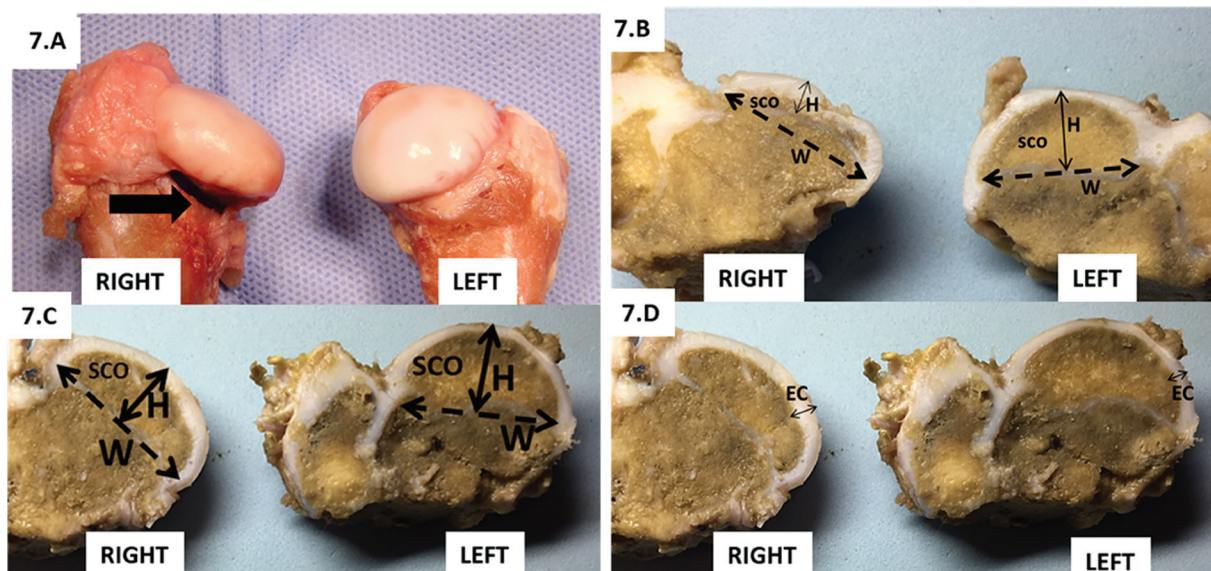
In group B, there was no difference in the expression of TGF-β1 between the right and left FHs ( $p^3 = 0.050$ ) (►Fig. 10).

**Table 1** Descriptions of the alterations found in the right FHs in RD and CT at the timepoints in groups A and B

Group A	Digital radiography	Coronal and axial CT	3D CT
2 weeks	Discreet FH flattening	Discreet FH flattening Presence of sclerotic areas, suggestive of FHIN - Enlargement of the RFN	Discreet FH flattening
4 weeks	Loss of the right FH semispherical shape and presence of depression areas of the articular surface	Loss of the right FH semispherical shape and presence of depression areas of the articular surface	Loss of the right FH semispherical shape and presence of depression areas of the articular surface
6 weeks	Total collapse and fragmentation of the right FH with loss of the semispherical shape and great enlargement of the femoral neck	Total collapse and fragmentation of the right FH with loss of the semispherical shape and great enlargement of the femoral neck	Total collapse and fragmentation of the right FH with loss of the semispherical format and great enlargement of the femoral neck
8 weeks	Loss of the semispherical shape and right FH flattening. Suggestive sclerotic areas of FHIN	Loss of the semispherical shape and right FH flattening. Suggestive sclerotic areas of FHIN	Loss of the semispherical shape and right FH flattening.
Group B	Digital radiography	Coronal and axial CT	3D CT
6 weeks	No changes	No changes	No changes

**Abbreviations:** FH, femoral head; RFN, right femoral neck; FHIN, ischemic necrosis of the femoral head; RD, digital radiography; CT, CT scan.





**Fig. 7** (A) Photograph of the femoral heads (FHs) right and left of the piglet euthanized after 6 weeks of ischemia. Flattening of the right femoral head and tight cerclage to the femoral neck (black arrow) are observed. (B) Frontal cut photograph of femoral heads (FHs) of the piglet euthanized after 6 weeks of ischemia. The right femoral head (FH) has a smaller height (H) and a width (W) greater than the control left side. The secondary center of ossification (SCO) of the right FH is deformed and decreased. It is observed the loss of the semispherical format of the SCO. (C) Front cut photograph of the FHs from a piglet euthanized after 8 weeks of ischemia. The right FH has H smaller and W greater than the left control side. (D) Front cut photograph of the FHs from a piglet euthanized after 8 weeks of ischemia. The epiphyseal cartilage (EC) on the right side is thicker than the EC on the left side.

## Discussion

The model proposed using frozen bone parts provided alterations of the FHIN in DR, CT, macroscopy, histology, and gait.

In all surgeries, during dissection, the presence of cerclage was still fair in the RFN, confirming it as the factor inducing necrosis.

Although nuclear magnetic resonance imaging (NMR) <sup>9,10,13</sup> is the most sensitive test for the diagnosis of FHIN, <sup>12</sup> CT <sup>8,9,22,25</sup> and DR <sup>10-12,15,18,26-28</sup> demonstrate the same alterations. Similarly, in this study with frozen parts we observed: decrease and increase, respectively, of the height and width of the femoral epiphysis, as well as flattening, collapse, and fragmentation of FH. All at a lower cost.

**Table 2** Descriptions of the changes found in the right FHs in macroscopic analysis of anatomical parts in groups A and B

Group A	Macroscopic analysis
2 weeks	RFN enlargement
4 weeks	FH flattening and RFN enlargement
6 weeks	Total collapse of FH and RFN enlargement Increased EC thickness
8 weeks	FH flattening Increased EC thickness
Group B	Macroscopic analysis
6 weeks	No changes

Abbreviations: EC, epiphyseal cartilage; FH, femoral head; RFN, right femoral neck.

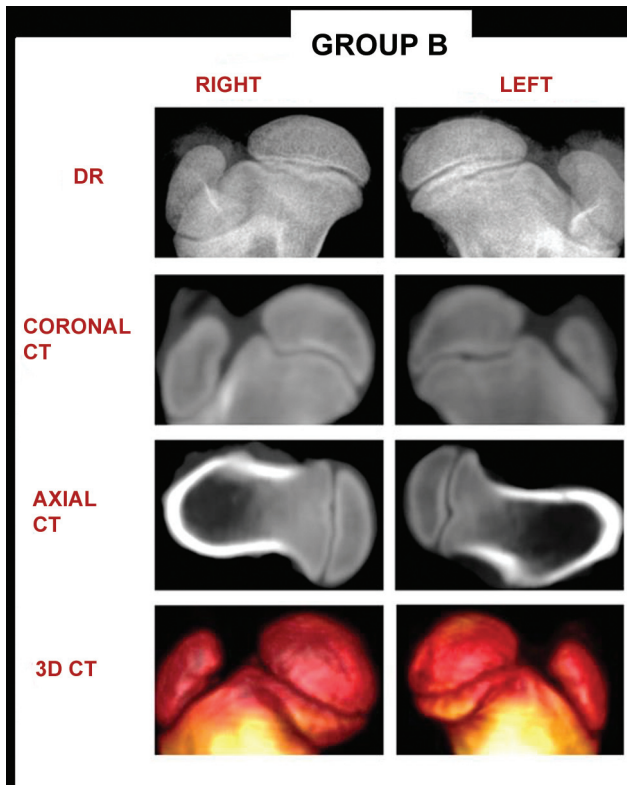
Taking into consideration that CT and NMR exams are limited to very few veterinary hospitals and the use of human laboratories by animals is prohibited by health surveillance standards, dissection and freezing of the femurs allowed for the examinations of these anatomical parts in these laboratories.

The use of NMR in dissected femurs is more difficult because it requires the presence of soft tissues, i.e., the whole animal should be examined and anesthetized. Alternatively, DR and CT could be performed on dissected bones.

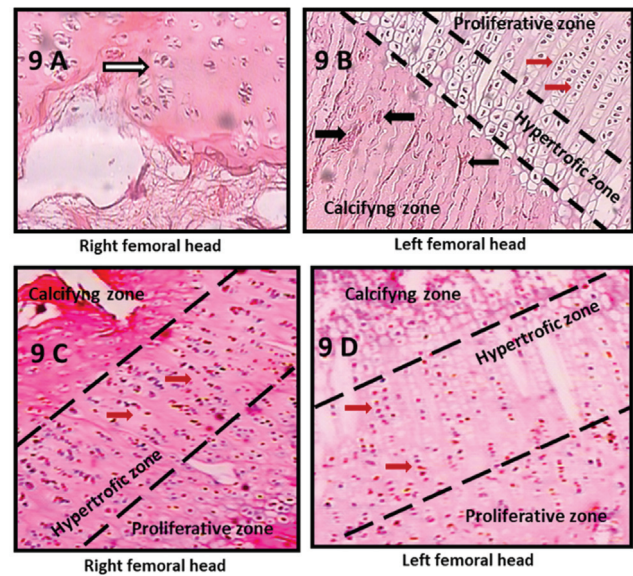
Thus, the femurs were dissected and frozen, and imaging tests were performed by a collaborating laboratory on the availability of vacancies.

It was observed that this storage method can reduce costs, does not affect the quality of the exams, and makes conducting it possible on a scheduled date, according to the possibility of care. This feature allows the use of DR and CT even without having them in your service.

Kim et al., <sup>11</sup> in 2001, made radiographs of frontal cuts with a thickness of 3 mm with diamond saw for better image definition. We do not have the necessary material to perform millimetric cuts, so the whole FH was radiographed. Nevertheless, signs of FH necrosis were observed with only two weeks of RFN cerclage, and, after six weeks, fragmentation and collapse of FH, in the same way as the authors above. Additionally, 3DCT also allowed the visualization of the lesions in greater detail, also verifying that freezing did not hinder the method, nor the LM results. There were gaps splitting the disorganized chondrocytes and losing their arrangement in columns, without the clear identification of proliferative, hypertrophic, and



**Fig. 8** Digital radiography (DR) and computed tomography (CT) of the proximal 1/3 of the right and left femurs of piglets of group B. The right femoral heads (FHs) did not present differences compared to the control left FHs, without radiographic signs of ischemic necrosis of the femoral head (FHIN), remaining semispherical without areas of depression and sclerosis.

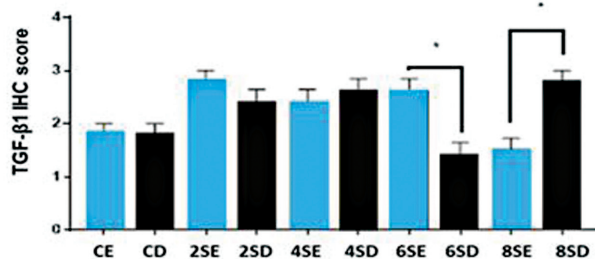


**Fig. 9** Photograph of growth plates (GP) of the femurs from piglets euthanized after 6 weeks of surgery. Photomicrography in 100-fold increase from growth plates of the femurs from piglets euthanized after 6 weeks of surgery. (A) In group A, in GP of the right femoral head (FH), the presence of chondrocytes grouped in a disorganized way (white arrow) and separated by large empty gaps was identified. (B) In the GPs of the left FHs (control), chondrocytes were well organized in columns arranged in parallel (red arrows). The proliferative, hypertrophic, and calcification zones are clearly divided and visible. Vascular proliferation was observed in the calcification zone (black arrows). (C. and D) In Group B, the growth plates of the right and left FHs showed no differences. Normal aspect, with the proliferation, hypertrophic, and calcification zones clearly identified, and chondrocytes were organized in columns (red arrows).

**Table 3** Description of epiphyseal height and width of the femoral heads in centimeters and epiphyseal coefficient in the timepoints after ischemia

Group	Timepoints	Measures (cm)	Piglet 1		Piglet 2	
			R	L	R	L
A	2 weeks					
		H	0.8	1.0	1.0	1.1
		W	1.7	1.6	1.6	1.6
		EC	0.5	0.6	0.6	0.7
	4 weeks	H	1.0	1.2	1.0	1.1
		W	1.9	1.8	2.0	1.9
		EC	0.5	0.7	0.5	0.6
	6 weeks	H	0.9	1.0	0.4	1.2
		W	2.0	1.9	1.9	1.8
		EC	0.4	0.5	0.2	0.7
		H	0.9	1.1	1.0	1.2
	8 weeks	W	2.2	1.9	2.3	2.1
EC		0.4	0.6	0.4	0.6	
B	6 weeks	H	1.0	1.0	1.0	1.0
		W	1.9	1.9	1.9	1.9
		EC	0.5	0.5	0.5	0.5

Abbreviations: H, height; FH, femoral head; EC, epiphyseal coefficient; W, width; R, right; L, left; cm, centimeters.



**Fig. 10** Description of TGF-β1 expression in femoral heads (FHs) according to ischemia time. The columns indicate TGF-β1 expression. CE: Left FHs of group B. CD: Right FHs of Group B. 2SE: Left FHs from piglets euthanized with 2 weeks. 2SD: Right FHs from piglets euthanized with 2 weeks. 4SE: Left FHs from piglets euthanized with 4 weeks. 4SD: Right FHs from piglets euthanized with 4 weeks. 6SE: Left FHs from piglets euthanized with 6 weeks. 6SD: Right FHs from piglets euthanized with 6 weeks. 8SE: Left FHs from piglets euthanized with 8 weeks. 8SD: Right FHs from piglets euthanized with 8 weeks. The test used was the Student t-test, significance level  $p = 0.050$ .

calcification zones, thus characterizing the areas of necrosis.

The EC of the right femoral heads of group A were smaller than the EC on the contralateral side, demonstrating FH flattening by necrosis, and the lower the EC, the greater the deformity and the worse the prognosis.<sup>16,22–24</sup> However, the greatest deformity was observed at six weeks of ischemia and not at eight. A possible explanation would be that in LCPD, the longer the evolution time, the worse the FH deformity, with the collapse of FH varying directly with the amount of weight bearing on the joint.

Kim et al.<sup>22</sup> demonstrated, in a swine model, that the weight bearing on the hip worsens the prognosis of the disease. Our piglets were housed with free movement, so the amount of load on the ischemic limb was dependent on the degree of voluntary activity of each test subject. A higher degree of activity in the piglet with 6 weeks of ischemia could justify the greater deformity. Also, Etterlin et al.,<sup>21</sup> evaluating the gait of piglets with arthrosis, observed that more active piglets had a better gait pattern than inactive, even with severe changes in the joints, attributing this to the musculature better developed by exercise. Thus, a more active piglet wanders more, imposes more weight bearing on the joint, deforming the FH more markedly.

Another hypothesis would be that the femoral heads with eight weeks of ischemia had developed a neocirculation, but this is unlikely because in the FHIN repair process, accessories secondary centers of ossification nuclei emerged that promoted disordered and irregular growth that gave the aspect of fragmentation on radiographs.<sup>11</sup> Perhaps a longer study time, with controlled movement and a greater number of piglets could help clarify these findings.

Frequently, FHIN evolves into arthrosis, causing functional impairment of this joint<sup>1</sup> and, consequently, claudication. There are no experimental models using functional gait assessment in LCPD studies. In this study, it was possible to study gait and observe very evident alterations without

the need for sophisticated instruments that could hinder the performance of functional evaluation. Santangelo et al.,<sup>29</sup> in 2014, used a breed of guinea pigs that spontaneously developed knee arthrosis to test the effects of flunixin meglumine. The authors used a computerized gait platform and observed an improvement in the gait pattern of the animals using the drug.

Thus, a swine experimental model with the functional evaluation of effective and low-cost gait can be an advent to test new drugs for FHIN, making it possible to associate the effects of treatment on morphological and biochemical tests with functional clinical changes in gait.

The surgical technique was described by Kim et al.,<sup>11</sup> in 2001, when these authors had four successes in 18 piglets, of which 1 piglet developed septic arthritis and 3 did not develop necrosis by failure of the surgical technique in cerclage. In our experiment with 11 piglets, there was only one death from sepsis, with success in the ischemia process in all piglets. There is no in-depth demonstration of surgical steps with sufficiently detailed images in the literature.

It is believed that our result can be justified by the surgeries being performed by the same experienced surgeon, who is a specialist in hip surgery. Although we had a simple surgical center, with minimal conditions, it was observed that these structural conditions were not limiting. And it is considered that the main factor for the success of the procedure is technical knowledge.

It is our opinion that the thorough knowledge of the regional anatomy and surgical technique are necessary, being fundamental to train with cadavers to acquire skill. Preoperative evaluation and confinement, as well as postoperative veterinary care, can also avoid losses.

The TGF-β1, therefore, can be used as an indirect measure of damage and immune alteration triggered by FHIN, because it is involved in bone regeneration.<sup>30</sup>

Tao et al.,<sup>31</sup> in 2017, observed a decrease in TGF-β1 expression in femoral heads with ischemic necrosis, taken from patients submitted to total hip arthroplasty for this reason.

In this study, there was no decrease in TGF-β1 expression in all right femoral heads of group A, although macroscopic, microscopic, radiographic, and clinical signs of FHIN were identified. This finding may be related to the small number of slides performed, limited by the need of the part for other tests. For future experiments, we suggest allocating half of the sectioned FH for immunohistochemistry examination and the other half for macroscopic and histological analysis. Thus, it would be possible to use larger fragments with a larger amount of bone tissue. A greater number of guinea pigs will allow greater conclusions.

## Conclusions

The changes in FH in the LCPD were reproduced in macroscopic analysis, DR, CT, and LM.

Gait evaluation showed a good correlation with macroscopic changes and imaging.



### Authors' Contributions

All authors contributed to the bibliographic survey, realization, analysis, and interpretation of the exams, design, and review of the article as well as in the approval of the final version.

### Financial Support

There was no financial support from public, commercial, or non-profit sources.

### Acknowledgements

Our thanks to the veterinary doctors of the Veterinary Hospital of the Universidade Estadual de Londrina, Ana Paula Abreu Mendonça, Stefany Lia Oliveira Camilo, and Laís Muniz Arruda Pereira, for their dedication, respect, and competence with the test subjects. To the veterinarian Gustavo Bispo dos Santos, from the Faculdade de Medicina de São Paulo, for his assistance in performing microscopy tests. To the radiologist Lara Nable Elias, from the Instituto Manoel de Abreu for her valuable assistance in performing imaging. To Prof. Dr. Carolina Panis, from the Tumor Biology Laboratory of the Universidade Estadual do Oeste do Paraná, for her assistance in performing immunohistochemistry tests. To Prof. Dr. Roberto Guarniero, from the Institute of Orthopedics and Traumatology of the Universidade de São Paulo, to Prof. Dr. Takeshi Chikude and Joel Murachovski, from the Centro Universitário Faculdade de Medicina do ABC, for the precious guidelines that made it possible to carry out this work.

### Conflict of Interest

The authors have no conflict of interest to declare.

### References

- Koob TJ, Pringle D, Gedbaw E, Meredith J, Berrios R, Kim HKW. Biomechanical properties of bone and cartilage in growing femoral head following ischemic osteonecrosis. *J Orthop Res* 2007;25(06):750–757
- Guarniero R. Doença de Legg-Calvé-Perthes: 100 anos. *Rev Bras Ortop* 2011;46(01):1–2
- Boss JH, Misselevich I. Osteonecrosis of the femoral head of laboratory animals: the lessons learned from a comparative study of osteonecrosis in man and experimental animals. *Vet Pathol* 2003;40(04):345–354
- Dailiana ZH, Stefanou N, Khalidi L, et al. Vascular endothelial growth factor for the treatment of femoral head osteonecrosis: An experimental study in canines. *World J Orthop* 2018;9(09):120–129
- Komiyama T, Nishida K, Yorimitsu M, et al. Decreased levels of insulin-like growth factor-1 and vascular endothelial growth factor relevant to the ossification disturbance in femoral heads spontaneous hypertensive rats. *Acta Med Okayama* 2006;60(03):141–148
- Xu T, Jin H, Lao Y, et al. Administration of erythropoietin prevents bone loss in osteonecrosis of the femoral head in mice. *Mol Med Rep* 2017;16(06):8755–8762
- Kothapalli R, Aya-ay JP, Bian H, Garces A, Kim HK. Ischaemic injury to femoral head induces apoptotic and oncotic cell death. *Pathology* 2007;39(02):241–246
- Zhang P, Liang Y, Kim H, Yokota H. Evaluation of a pig femoral head osteonecrosis model. *J Orthop Surg Res* 2010;5:15
- Wang G, Zhang CQ, Sun Y, et al. Changes in femoral head blood supply and vascular endothelial growth factor in rabbits with steroid-induced osteonecrosis. *J Int Med Res* 2010;38(03):1060–1069
- Dello Russo B, Baroni EL, Saravia N, et al. Prevention of femoral head deformity after ischemic necrosis using ibandronate acid and growth factor in immature pigs. *Surg Sci* 2012;3(04):194–199
- Kim HK, Su PH, Qiu YS. Histopathologic changes in growth-plate cartilage following ischemic necrosis of the capital femoral epiphysis. An experimental investigation in immature pigs. *J Bone Joint Surg Am* 2001;83(05):688–697
- Kim HKW, Skelton DN, Quigley EJ. Pathogenesis of metaphyseal radiolucent changes following ischemic necrosis of the capital femoral epiphysis in immature pigs. A preliminary report. *J Bone Joint Surg Am* 2004;86(01):129–135
- Shapiro F, Connolly S, Zurakowski D, et al. Femoral head deformation and repair following induction of ischemic necrosis: a histologic and magnetic resonance imaging study in the piglet. *J Bone Joint Surg Am* 2009;91(12):2903–2914
- Adapala NS, Kim HKW. Comprehensive genome-wide transcriptomic analysis of immature articular cartilage following isquemic osteonecrosis of the femoral head in piglets. *PLoS One* 2016;11(04):e0153174
- Rowe SM, Lee JJ, Chung JY, Moon ES, Song EK, Seo HY. Deformity of the femoral head following vascular infarct in piglets. *Acta Orthop* 2006;77(01):33–38
- Kong SY, Kim HW, Park HW, Lee SY, Lee KS. Effects of multiple drilling on the ischemic capital femoral epiphysis of immature piglets. *Yonsei Med J* 2011;52(05):809–817
- Kim HKW, Stephenson N, Garces A, Aya-ay J, Bian H. Effects of disruption of epiphyseal vasculature on the proximal femoral growth plate. *J Bone Joint Surg Am* 2009;91(05):1149–1158
- Rowe SM, Kim MS, Moon ES, Song EK, Yoon TR, Cho SB. Developmental pattern of femoral shortening following devascularization of the capital femoral epiphysis in piglets. *J Pediatr Orthop* 2005;25(03):300–304
- Kilkenny C, Browne WJ, Cuthill IC, Emerson M, Altman DG. Improving bioscience research reporting: the ARRIVE guidelines for reporting animal research. *PLoS Biol* 2010;8(06):e1000412
- Fitts DA. Ethics and animal numbers: informal analyses, uncertain sample sizes, inefficient replications, and type I errors. *J Am Assoc Lab Anim Sci* 2011;50(04):445–453
- Etterlin PE, Morrison DA, Österberg J, Ytrehus B, Heldmer E, Ekman S. Osteochondrosis, but not lameness, is more frequent among free-range pigs than confined herd-mates. *Acta Vet Scand* 2015;57:63
- Kim HK, Aruwajoye O, Stetler J, Stall A. Effects of non-weight-bearing on the immature femoral head following ischémie osteonecrosis. *J Bone Joint Surg Am* 2012;94(24):2228–2237
- Laredo Filho J, Ishida A, Lourenço AF, Kuwajima SS, Jorge SRN. Avaliação radiográfica da cobertura acetabular da cabeça femoral em pacientes portadores da doença de Legg-Calvé-Perthes unilateral submetidos à osteotomia de Salter. *Rev Bras Ortop* 1993;28(05):299–303
- Luzo CAM, Guarniero R, Montenegro NB, Godoy RM Junior. Experiência inicial com o uso de fixador externo articulado no tratamento da doença de Legg-Calvé-Perthes por meio de artrodiástase na fase ativa da moléstia. *Rev Bras Ortop* 2016;51(03):337–345
- Terayama H, Ishikawa M, Yasunaga Y, et al. Prevention of osteonecrosis by intravenous administration of human peripheral blood-derived CD34-positive cells in a rat osteonecrosis model. *J Tissue Eng Regen Med* 2011;5(01):32–40
- Boss JH, Misselevich I, Bejar J, Norman D, Zinman C, Reis DN. Experimentally gained insight - based proposal apropos the treatment of osteonecrosis of the femoral head. *Med Hypotheses* 2004;62(06):958–965
- Kim HKW, Randall TS, Bian H, Jenkins J, Garces A, Bauss F. Ibandronate for prevention of femoral head deformity after

- ischemic necrosis of the capital femoral epiphysis in immature pigs. *J Bone Joint Surg Am* 2005;87(03):550–557
- 28 Peng J, Wen C, Wang A, et al. Micro-CT-based bone ceramic scaffolding and its performance after seeding with mesenchymal stem cells for repair of load-bearing bone defect in canine femoral head. *J Biomed Mater Res B Appl Biomater* 2011;96(02):316–325
- 29 Santangelo KS, Kaeding AC, Baker SA, Bertone AL. Quantitative Gait Analysis Detects Significant Differences in Movement between Osteoarthritic and Nonosteoarthritic Guinea Pig Strains before and after Treatment with Flunixin Meglumine. *Arthritis (Egypt)* 2014;2014:503519
- 30 Li MO, Wan YY, Sanjabi S, Robertson AK, Flavell RA. Transforming growth factor- $\beta$  regulation of immune responses. *Annu Rev Immunol* 2006;24:99–146
- 31 Tao J, Dong B, Yang LX, Xu KQ, Ma S, Lu J. TGF- $\beta$ 1 expression in adults with non-traumatic osteonecrosis of the femoral head. *Mol Med Rep* 2017;16(06):9539–9544