



Original Article

Distal femoral cut in total knee arthroplasty in a Brazilian population[☆]



Marcos Areias Vieira Costa, Alan de Paula Mozella*,
Hugo Alexandre de Araujo Barros Cobra

Instituto Nacional de Traumatologia e Ortopedia (INTO), Rio de Janeiro, RJ, Brazil

ARTICLE INFO

Article history:

Received 6 June 2014

Accepted 10 July 2014

Available online 12 June 2015

Keywords:

Knee arthroplasty

Alignment in arthroplasty

Femoral cut

ABSTRACT

Objective: To determine the ideal angle for making the distal femoral cut in total knee arthroplasty in a Brazilian population.

Methods: Panoramic radiographs of the lower limbs bearing weight from 79 patients (57 women and 22 men) were studied, totaling 107 knees with an indication for total knee arthroplasty. The femoral anatomical axis, femoral mechanical axis and cervical-diaphyseal angle were traced out. The angle of the femoral cut was determined from the meeting point between the femoral anatomical and mechanical axes. The ideal degree of femoral valgus was compared between men and women and between knees presenting varus and valgus alignment of the lower limb. The ideal distal femoral cut was also correlated with the cervical-diaphyseal angle.

Results: The ideal femoral valgus angle ranged from 4.2 to 8.6 degrees, with a mean of 6.3 degrees. There was no statistically significant difference in the distal femoral cut between patients with coronal varus and valgus alignment ($p=0.180$). Comparing men and women, there was no statistically significant difference regarding the ideal femoral valgus between the groups ($p=0.057$). The cervical-diaphyseal angle presented an inverse relationship with the distal femoral cut.

Conclusions: The mean angle between the femoral mechanical and anatomical axes was 6.3 degree. Neither preoperative coronal alignment nor sex had any influence on the distal femoral cut. The cervical-diaphyseal angle presented an inverse relationship with the distal femoral cut.

© 2014 Sociedade Brasileira de Ortopedia e Traumatologia. Published by Elsevier Editora Ltda. All rights reserved.

[☆] Work developed at the Knee Surgery Center, Instituto Nacional de Traumatologia e Ortopedia (INTO), Rio de Janeiro, RJ, Brazil.

* Corresponding author.

E-mail: apmozella@terra.com.br (A.d.P. Mozella).

<http://dx.doi.org/10.1016/j.rboe.2015.05.007>

2255-4971/© 2014 Sociedade Brasileira de Ortopedia e Traumatologia. Published by Elsevier Editora Ltda. All rights reserved.

Corte femoral distal na artroplastia total de joelho na população brasileira

R E S U M O

Palavras-chave:

Artroplastia do joelho
Alinhamento em artroplastia
Corte femoral

Objetivo: Determinar o ângulo ideal para feitura do corte femoral distal na artroplastia total do joelho em população brasileira.

Métodos: Foram estudadas radiografias panorâmicas com carga dos membros inferiores em 79 pacientes (57 mulheres e 22 homens), num total de 107 joelhos com indicação de artroplastia total. Foram traçados o eixo anatômico femoral (EAF), o eixo mecânico femoral (EMF) e o ângulo cervicodiafisário (âCD). O ângulo do corte femoral distal foi determinado pelo encontro entre o EMF e o EAF. O valor do valgo femoral ideal foi comparado entre homens e mulheres e entre joelhos com alinhamento em varo e valgo do membro inferior. O corte femoral distal ideal foi correlacionado ainda com o ângulo cervicodiafisário.

Resultados: O ângulo do valgo femoral ideal variou de 4,2 até 8,6 graus, com média de 6,3. O corte femoral distal não mostrou diferença quando comparados pacientes com alinhamento coronal em varo e valgo, sem significância estatística ($p = 0,180$). Quando comparados homens e mulheres, o valgo femoral ideal não mostrou diferença entre os grupos estatisticamente significante ($p = 0,057$). O ângulo cervicodiafisário mostrou relação inversa com o corte femoral distal.

Conclusões: A média do ângulo entre os eixos mecânico femoral e anatômico femoral foi de 6,3 graus. Alinhamento coronal pré-operatório, assim como o sexo, não exerceu influência no corte femoral distal. O ângulo cervicodiafisário mostrou relação inversa com o corte femoral distal.

© 2014 Sociedade Brasileira de Ortopedia e Traumatologia. Publicado por Elsevier Editora Ltda. Todos os direitos reservados.

Introduction

Numerous studies have shown a correlation between the durability of total knee arthroplasty (TKA) and restoration of the normal limb alignment.¹⁻³ It is believed that restoration of the mechanical axis with a maximum variation of 3° toward varus or valgus is associated with the best results from TKA.¹⁻⁶ However, some authors have demonstrated that postoperative alignments of the limb outside of the interval of $\pm 3^\circ$ in the coronal plane are observed in up to 30% of the cases.⁷⁻⁹

In normal knees, the tibial joint surface is at a varus angle of approximately 3° in relation to the mechanical axis, while the femoral surface is at a valgus angle of 9° . Historically, attempts have been made to reproduce this anatomical alignment of the knee in total arthroplasty by cutting the tibia at a varus angle. However, several studies have demonstrated that tibial components placed at varus angles greater than 5° tend to fail due to medial collapse.^{3,10}

Incorrect alignment of TKA has been identified as a cause of long-term complications, including accelerated wear,^{11,12} premature mechanical loosening of the implant^{1,13,14} and patellofemoral problems¹⁵⁻¹⁷ such as patellofemoral instability and patellar fracture.

Thus, it is recommended that the tibial component should be implanted perpendicularly to the mechanical axis of the tibia in the coronal plane. The femoral component is usually implanted at a valgus angle of 5° to 6° , which is the size of angle supposedly necessary for reestablishing a neutral mechanical axis in the limb.

The aim of the present study was to measure the ideal angle for making the distal femoral cut in Brazilian patients who

Table 1 – Inclusion and exclusion criteria.

Inclusion criteria	Exclusion criteria
<ul style="list-style-type: none"> • Patients awaiting total knee arthroplasty operations • Primary osteoarthritis 	<ul style="list-style-type: none"> • Secondary osteoarthritis • Osteoarthritis of the hip • Ipsilateral hip prosthesis
<ul style="list-style-type: none"> • Failure of conservative treatment 	<ul style="list-style-type: none"> • Previous femoral osteotomy • Previous tibial osteotomy • Extra-articular deformity

underwent TKA at the Knee Surgery Center of the National Institute of Traumatology and Orthopedics (INTO).

Material and methods

Between August 2011 and February 2012, panoramic radiographs on 79 patients (22 men and 57 women) were analyzed, thus totaling 107 limbs, in accordance with the inclusion and exclusion criteria listed in Table 1.

This study was submitted for evaluation and approval by our institution's research ethics committee.

Radiographic evaluation

The radiographic evaluation was done on anteroposterior (AP) panoramic radiographs of the lower limbs with weight-bearing on both feet. All the radiographs were produced at the imaging examination center of our service. The examinations were

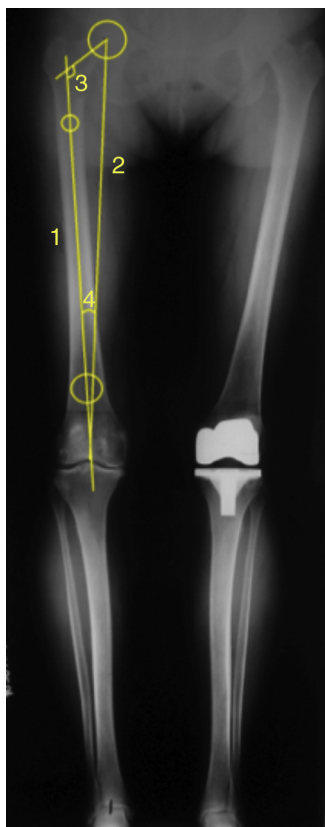


Fig. 1 – Panoramic radiograph of the lower limbs. (1) Femoral anatomical axis. (2) Femoral mechanical axis. (3) Cervicodiaphyseal angle. (4) Ideal femoral valgus.

performed with the patients positioned with their limbs at neutral rotation and maximum extension.

In all the radiographic examinations, we defined: (1) the anatomical axis of the femoral diaphysis; (2) the mechanical femoral axis; and (3) the cervicodiaphyseal angle.

The mechanical axis of the femoral diaphysis was defined by a straight line that joined the centers of two circles that were tangential to the medial and lateral cortical bone of the femur. The first circle was located 2 cm distally to the lesser trochanter. The second was at the junction between the distal metaphysis and the femoral diaphysis, as determined using Heim's square.¹⁸

The mechanical axis was defined in accordance with the current concepts in the literature, as a straight line passing through the center of the femoral head to the midpoint of the width of the distal femur.

The ideal distal femoral cut angle corresponded to the intersection between the anatomical axis and the femoral mechanical axis (Fig. 1).

Measurement of the angle formed between the femoral anatomical axis and the line of the femoral neck defined the cervicodiaphyseal angle. Two circles that were tangential to the lower cortex and upper cortex of the femoral neck were used to trace out the line of the neck.

The measurements were always made by two evaluators at different times using the same instruments with precision of the order of millimeters.

Statistical analysis

Statistical analysis was performed with the aim of evaluating the degree of significance of the parameters measured. The Shapiro-Wilks W test was used to evaluate whether the variance had normal distribution and the Levene test was used to assess its homoscedasticity. The distal femoral cut angles and the cervicodiaphyseal angles were considered to have normal distribution and Student's t test was used to compare the means. The Statistica 8.0 software was used for the statistical calculations.

Results

Seventy-nine patients (22 men and 57 women) were studied, with a total of 107 limbs. The patients' mean age was 67 years, with a range from 58 to 86. Surgery was performed on the right side in 53 cases and on the left side in 54 cases.

Seventy knees presented alignment with varus angles between 3° and 20° (mean 8.4°; standard deviation 3.5°). Twenty-six knees presented preoperative alignment with valgus angles between 2.7° and 16° (mean 6.6°; standard deviation 3.1). Neutral preoperative alignment was observed in 11 cases.

The ideal femoral valgus angle ranged from 4.2° to 8.6°, with a mean of 6.3°. Fig. 2 shows the distribution of the ideal distal femoral cut for the patients studied.

The male patients presented an ideal distal femoral cut of 6.6° (range from 4.9° to 8°), while for the women, 6.2° was the ideal angle for the distal femoral cut (range from 4.2° to 8.6°).

Among the patients with preoperative varus alignment, the ideal distal femoral cut was 6.2° (range from 4.2° to 8.4°). Among the patients with preoperative valgus alignment, the ideal femoral valgus angle was 6.5° (range from 4.2° to 8.6°).

The cervicodiaphyseal angle ranged from 114.3° to 138.3°, with a mean of 127.2°. Fig. 3 correlates the distal femoral cut and cervicodiaphyseal angle values for each patient.

Among the male patients, the mean cervicodiaphyseal angle was 127.5° (range from 118.1° to 138.3°), while among the women it was 127° (range from 114.3° to 136.5°). The mean cervicodiaphyseal angle identified among the patients with preoperative varus alignment was 127.2° (range from 114.3° to 136.5°), while among those with preoperative valgus alignment, it was 127.1° (range from 115.1° to 138.3°).

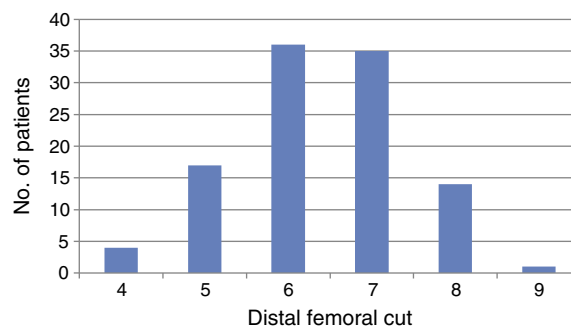


Fig. 2 – Distribution of the numbers of patients among different femoral cut angles.

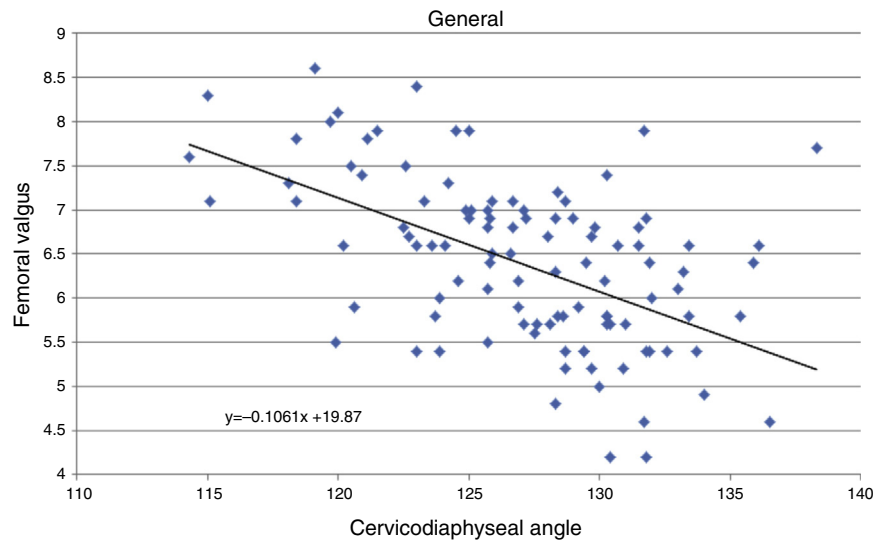


Fig. 3 – Correlation between the distal femoral cut and the cervicodiaphyseal angle.

Statistical analyses were performed using Student's *t* test with a 95% confidence interval. No statistical difference in the ideal distal femoral valgus values or the cervicodiaphyseal angle was observed between the men and women ($p=0.57$). The statistical analysis on these angles also did not show any statistical difference in comparing the preoperative varus and valgus deformities ($p=0.18$).

Discussion

The analysis on the ideal femoral valgus angle showed small absolute angle values. Thus, precise radiographic standards need to be used in panoramic radiographs, especially with regard to controlling the external rotation of the lower limbs while the examination is being performed. Radiographs with rotational deviation of the lower limbs, which most frequently occurs during external rotation, produce larger femoral valgus angles because of the anatomical bowing of the femur along the sagittal axis. This bowing also impedes proper measurement of the anatomical axis of the femoral canal. For this reason, only radiographs with perfect rotational control, such that the lesser trochanter did not appear and the patella was centralized on the knee, were included in this study.¹⁹

Another complicating factor in determining the angles was extra-articular deformity, which altered the axes and angles analyzed unpredictably. Radiographs with extra-articular deformity were excluded from the study.

One of the objectives of TKA is to restore neutral alignment of the lower limb through making bone cuts perpendicularly to the mechanical axes of the femur and tibia.²⁰ It is a common practice among many surgeons to use the same distal femoral cut angle for all patients and to assume that there is minimal variation in the angle between the mechanical and anatomical axes of different patients' knees. However, some studies have advocated preoperative planning using panoramic radiographs as a means of obtaining alignment that is more precise and individualized.^{21,22}

The mean value of the distal femoral cut that was found for the present study population did not show any statistical difference in relation to what was found by Resende et al.²³ in another Brazilian population. If we had empirically used the mean angle found for the patients in this study, all of them would have had acceptable alignment, while taking into account a permissible error of up to 3° , as put forward in the literature.^{24,25} This diverges from the data of one Brazilian author, who found that 19.7% of the population operated had insufficient alignment, based on an acceptable error of 3° in the coronal plan.²³

Despite a tendency for the distal femoral cut to be greater in men than in women (6.6° versus 6.2°), there was no statistical difference between the groups, which is concordant with the current literature.^{23,26,27}

We identified an inverse trend between the cervicodiaphyseal angle values and the ideal distal femoral cut values. This was due to the greater distance of the diaphysis from the central axis of the body in the femoral necks with greater varus angle and the smaller distance of the diaphysis from the central axis of the body in the femoral necks with greater valgus angle.

The preoperative coronal alignment did not significantly correlate with the distal femoral cut in this study. The distal femoral cut value was related to the anatomical factors of the femur, without using any tibial parameter to determine it. This makes us think that the overall alignment of the limb does not influence the distal cut. On the other hand, Deakin et al.²⁰ demonstrated a relationship between the distal femoral cut and the alignment of the lower limb, which should be less than 6° in valgus cases and greater than 6° in severe varus cases.

Conclusion

The mean angle between the femoral mechanical axis and the femoral anatomical axis was 6.3° .

The preoperative coronal alignment and sex did not have any influence on the distal femoral cut.

The cervicodiaphyseal angle had an inverse relationship with the distal femoral cut.

Conflicts of interest

The authors declare no conflicts of interest.

REFERENCES

- Bargren JH, Blaha JD, Freeman MA. Alignment in total knee arthroplasty. Correlated biomechanical and clinical observations. *Clin Orthop Relat Res.* 1983;(173):178-83.
- Bäthis H, Perlick L, Tingart M, Lüring C, Zurakowski D, Grifka J. Alignment in total knee arthroplasty. A comparison of computer-assisted surgery with the conventional technique. *J Bone Joint Surg Br.* 2004;86(5):682-7.
- Jeffery RS, Morris RW, Denham RA. Coronal alignment after total knee replacement. *J Bone Joint Surg Br.* 1991;73(5):709-14.
- Lotke PA, Ecker ML. Influence of positioning of prosthesis in total knee replacement. *J Bone Joint Surg Am.* 1977;59(1):77-9.
- Rand JA, Coventry MB. Ten-year evaluation of geometric total knee arthroplasty. *Clin Orthop Relat Res.* 1988;232:168-73.
- Ritter MA, Faris PM, Keating EM, Meding JB. Postoperative alignment of total knee replacement. Its effect on survival. *Clin Orthop Relat Res.* 1994;(299):153-6.
- Petersen TL, Engh GA. Radiographic assessment of knee alignment after total knee arthroplasty. *J Arthroplasty.* 1988;3(1):67-72.
- Mahaluxmivala J, Bankes MJ, Nicolai P, Aldam CH, Allen PW. The effect of surgeon experience on component positioning in 673 Press Fit Condylar posterior cruciate-sacrificing total knee arthroplasties. *J Arthroplasty.* 2001;16(5):635-40.
- Mielke RK, Clemens U, Jens JH, Kershally S. Navigation in knee endoprosthesis implantation – preliminary experiences and prospective comparative study with conventional implantation technique. *Z Orthop Ihre Grenzgeb.* 2001;139(2):109-16.
- Tew M, Waugh W. Tibiofemoral alignment and the results of knee replacement. *J Bone Joint Surg Br.* 1985;67(4):551-6.
- Eckhoff DG, Piatt BE, Gnadinger CA, Blaschke RC. Assessing rotational alignment in total knee arthroplasty. *Clin Orthop Relat Res.* 1995;1995(318):176-81.
- Wasielewski RC, Galante JO, Leighty RM, Natarajan RN, Rosenberg AG. Wear patterns on retrieved polyethylene tibial inserts and their relationship to technical considerations during total knee arthroplasty. *Clin Orthop Relat Res.* 1994;299:31-43.
- Hood RW, Vanni M, Insall JN. The correction of knee alignment in 225 consecutive total condylar knee replacements. *Clin Orthop Relat Res.* 1981;(160):94-105.
- Moreland JR. Mechanisms of failure in total knee arthroplasty. *Clin Orthop Relat Res.* 1988;1988(226):49-64.
- Berger RA, Rubash HE, Seel MJ, Thompson WH, Crossett LS. Determining the rotational alignment of the femoral component in total knee arthroplasty using the epicondylar axis. *Clin Orthop Relat Res.* 1993;1993(286):40-7.
- Arima J, Whiteside LA, McCarthy DS, White SE. Femoral rotational alignment, based on the anteroposterior axis, in total knee arthroplasty in a valgus knee. A technical note. *J Bone Joint Surg Am.* 1995;77(9):1331-4.
- Figgie HE 3rd, Goldberg VM, Figgie MP, Inglis AE, Kelly M, Sobel M. The effect of alignment of the implant on fractures of the patella after condylar total knee arthroplasty. *J Bone Joint Surg Am.* 1989;71(7):1031-9.
- Heim UF. Defining the boundary between diaphysis and metaphysis using quadrant measurement. A contribution to the classification and documentation of fractures of long tubular bones exemplified by the distal tibia. *Unfallchirurg.* 1987;90(6):274-80.
- Skyttä ET, Haapamäki V, Koivikko M, Huhtala H, Remes V. Reliability of the hip-to-ankle radiograph in determining the knee and implant alignment after total knee arthroplasty. *Acta Orthop Belg.* 2011;77(3):329-35.
- Deakin AH, Basanagoudar PL, Nunag P, Johnston AT, Sarungi M. Natural distribution of the femoral mechanical-anatomical angle in an osteoarthritic population and its relevance to total knee arthroplasty. *Knee.* 2012;19(2):120-3.
- Rauh MA, Boyle J, Mihalko WM, Phillips MJ, Bayers-Thering M, Krackow KA. Reliability of measuring long-standing lower extremity radiographs. *Orthopedics.* 2007;30(4):299-303.
- Patel DV, Ferris BD, Aichroth PM. Radiological study of alignment after total knee replacement. Short radiographs or long radiographs? *Int Orthop.* 1991;15(3):209-10.
- Rezende FC, Ferreira MC, Debieux P, Franciozi CE, Luzo MV, Carneiro M. É seguro o corte femoral distal em artroplastia total do joelho com 5° a 6° de valgo empiricamente na população geriátrica brasileira? *Rev Bras Ortop.* 2013;48(5):421-6.
- Akagi M, Oh M, Nonaka T, Tsujimoto H, Asano T, Hamanishi C. An anteroposterior axis of the tibia for total knee arthroplasty. *Clin Orthop Relat Res.* 2004;420:213-9.
- McGrory JE, Trousdale RT, Pagnano MW, Nigbur M. Preoperative hip to ankle radiographs in total knee arthroplasty. *Clin Orthop Relat Res.* 2002;2002(404):196-202.
- Hsu RW, Himeno S, Coventry MB, Chao EY. Normal axial alignment of the lower extremity and load-bearing distribution at the knee. *Clin Orthop Relat Res.* 1990;(255):215-27.
- Tang WM, Zhu YH, Chiu KY. Axial alignment of the lower extremity in Chinese adults. *J Bone Joint Surg Am.* 2000;82(11):1603-8.