



## Original Article

# Communication between the musculocutaneous and median nerves in the arm: an anatomical study and clinical implications



Luis Ernesto Ballesteros\*, Pedro Luis Forero, Edna Rocío Buitrago

Universidad Industrial de Santander (UIS), Bucaramanga, Colombia

## ARTICLE INFO

## Article history:

Received 13 July 2014

Accepted 21 August 2014

Available online 27 December 2014

## Keywords:

Median nerve

Musculocutaneous nerve

Communication

## ABSTRACT

**Objective:** To determine the frequency and features of communication between the musculocutaneous nerve (MCN) and median nerve (MN) in a sample of the Colombian population, and assess its clinical implication.

**Methods:** The arms of 53 cadaver specimens that had been subjected to necropsy at the National Institute of Forensic Medicine, in Bucaramanga, Colombia, were studied. The structures of the anterior compartment of the arm were dissected and characterized regarding the presence of communication between the MCN and MN.

**Results:** A communicating branch was found in 21/106 upper limbs (19.8%), occurring bilaterally in 10 (47.6%) and unilaterally in 11 (52.4%), without significant difference regarding the side of occurrence ( $p=0.30$ ). In 17% of the cases, there was MCN-MN communication in which the communicating branch was seen leaving the MCN after piercing the coracobrachialis muscle (Type I). In 2.8%, the connection was from the MN to the MCN (Type II). The length of the communicating branch was  $57.8 \pm 33.4$  mm. The distances from the proximal and distal points of this branch to the coracoid process were  $138 \pm 39.4$  mm and  $188 \pm 48.3$  mm, respectively. The communicating branch was located mostly in the middle third of the arm.

**Conclusions:** The frequency of MCN-MN communication observed in the present study is in the middle of the range of what was reported in previous studies. MCN-MN connections need to be taken into account in diagnosing and managing peripheral nerve lesions of the upper limbs.

© 2015 Published by Elsevier Editora Ltda. on behalf of Sociedade Brasileira de Ortopedia e Traumatologia.

\* Corresponding author.

E-mail: [lballest56@yahoo.es](mailto:lballest56@yahoo.es) (L.E. Ballesteros).

<http://dx.doi.org/10.1016/j.rboe.2014.08.009>

2255-4971/© 2015 Published by Elsevier Editora Ltda. on behalf of Sociedade Brasileira de Ortopedia e Traumatologia.

## Comunicação entre os nervos musculocutâneo e mediano no braço: estudo anatômico e implicações clínicas

### R E S U M O

*Palavras-chave:*  
Nervo mediano  
Nervo músculo-cutâneo  
Comunicação

**Objetivo:** Determinar a frequência e características da comunicação entre os nervos músculo-cutâneo (MCN) e mediano (MN) em uma amostra da população colombiana, e avaliar sua implicação clínica.

**Métodos:** Os braços de 53 cadáveres foram avaliados em necropsia no National Institute of Forensic Medicine, em Bucaramanga, Colômbia. As estruturas do compartimento anterior do braço foram dissecadas e caracterizadas em relação à presença de comunicação entre MCN e MN.

**Resultados:** Um ramo comunicante foi encontrado em 21/106 membros superiores (19.8%), ocorrendo bilateralmente em 10 (47,6%) e unilateralmente em 11 (52,4%), sem diferença significativa em relação ao lado da ocorrência ( $p=0,30$ ). Em 17% dos casos, havia uma comunicação entre MCN-MN na qual o ramo comunicante era visto emergindo do MCN após perfurar o músculo córacóide-braquial (Tipo I). Em 2,8% dos casos a conexão foi do MN para o MCN (Tipo II). O comprimento do ramo comunicante foi  $57,8 \pm 33,4$  mm. As distâncias entre os pontos proximal e distal deste ramo e o processo coracóide foi  $138 \pm 39,4$  mm e  $188 \pm 48,3$  mm, respectivamente. O ramo comunicante se localizou principalmente no terço médio do braço.

**Conclusão:** A frequência da comunicação entre MCN-MN observada no presente estudo está na média daquela relatada em outros trabalhos. As conexões MCN-MN devem ser levadas em consideração no diagnóstico e no manejo das lesões dos nervos periféricos dos membros superiores.

© 2015 Publicado por Elsevier Editora Ltda. em nome da Sociedade Brasileira de Ortopedia e Traumatologia.

## Introduction

At the infraclavicular level, the lateral fascicle of the brachial plexus usually bifurcates giving origin to the musculocutaneous nerve (MCN) and the lateral root of the median nerve (MN). However, during the embryological development process it is possible that bundles of fibers corresponding to the MN initially run together with bundles of fibers of the MCN. The MN recovers the fibers required to perform its motor and sensorial functions in the upper extremity, only when the bundles of fibers were connected with their nerve of origin (MN) at the proximal or mid-thirds of the arm. Although with low frequency, fibers of the MCN have also been seen to initially run along of the MN and later reestablish their configuration through a communicating branch.<sup>1-5</sup>

The incidence of the MCN-MN communication has been reported in diverse population groups with a wide variability between 2.1 and 63.5%.<sup>5-8</sup> The majority of the studies only report the MCN-MN communication. Maeda et al.<sup>3</sup> and Chiarpattanakom et al.<sup>6</sup> have reported an occurrence of 3–6.8% for the communication from the MN to the MCN. Information about the prevalence of side of MCN-MN communication is low. Few studies report predominance of the left side and of the unilateral expression of this communicating branch.<sup>4,9,10</sup> Several ways to classify this communicating branch have been proposed by the wide variability in its expression.<sup>3,7,8,10,11</sup>

Knowledge of the existence of the MCN-MN communication in the arm is clinically important; it allows an adequate

evaluation and management of upper limb motor disorders caused by peripheral nerve injuries as well as a correct surgical planning and approaches of axilla and arm.<sup>10,12-14</sup> The clinical implications of MCN-MN communications in the arm have not been described in detail for other populations.<sup>1,3,6,7,13,15-19</sup> Taking into account that the ethnic factor is decisive for the emergence of diverse morphological expressions and the absence of this type of information from the Mestizo population, which is predominant in Latin America, makes this study highly relevant in fresh cadaveric material.

## Methods

This descriptive study was designed to determine the frequency and morphologic features of the MCN-MN communication in 106 fresh frozen upper extremities of 53 male adults who were undergoing necropsy at the National Institute of Forensic Medicine. The sample met the following inclusion criteria: Mestizo subjects without evidence of direct trauma or conditions involving the upper extremity and who were not the subjects of forensic analysis.

An extensive dissection of the flexor compartment of the arm was undertaken through a midline incision going from the mid-third of the clavicle to the elbow fold. After releasing laterally the medial and lateral fascial-cutaneous flaps the pectoralis major muscle was released from its clavicular and sternal insertions. This allowed a good visualization of the terminal branches of the brachial plexus in the anterior region of

the arm. Then, the epineural connective tissue was removed and both the MCN and the MN were dissected from their origins to their respective motor points, taking their trajectories in the arm as a reference.

The existence of MCN-MN communicating branches in the arm was verified and their qualitative features were recorded in accordance with the classification proposed by Maeda et al.<sup>3</sup> as follows: Type I when the communication is observed at the mid or distal thirds of the arm. This class was subdivided into 4 subtypes. Subtype Ia: when the communication arose from MCN in its intramuscular via into the coracobrachialis muscle (CbM). Subtype Ib: when the communicating branch exits from MCN before the biceps muscle (BM) branch. Subtype Ic: when the communication is located between the branches going to BM and brachialis muscle (BrM). Subtype Id: when the communicating branch exits after the emergence of BrM branch. Similarly, the occurrence of communicating branches between the MN and the MCN was recorded as Type II with 2 subtypes. Subtype IIa: the branch from MN reached the segment between the origins of BM and BrM branches. Subtype IIb: when the communicating branch was connected with the branch to BrM. The length of the communicating branch as well as the distances from their proximal and distal points to the acromion was measured. The length of the arm from the anterior edge of the acromion to the bi-epicondylar line of the elbow was measured and the segment where the communicating branch was located was recorded.

All morphometric assessments were made with a digital caliper (Mitotuyo®) and the findings were photographed with

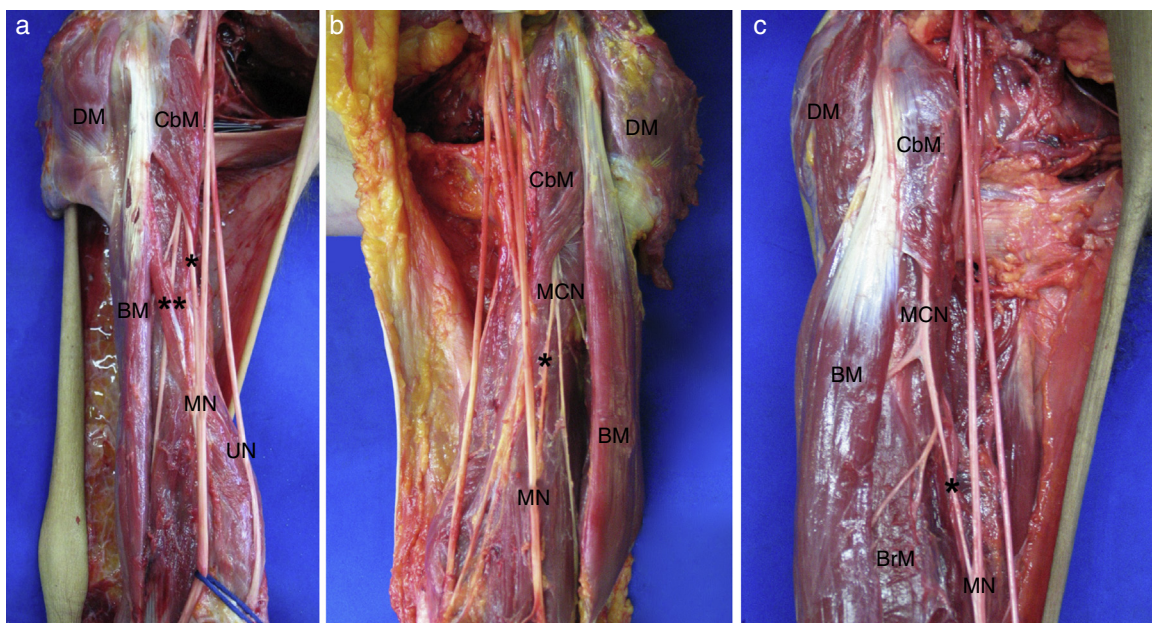
a DSLR camera. All findings were digitized in Excel tables and the statistical analyses were carried out. Nominal variables are described with ratios, while continuous variables are described with means and standard deviations. Statistical evidences were tested with the square chi ( $\chi^2$ ) test and Student t test accepting an alpha error of up to 5%. A  $p$ -value  $<0.05$  was considered as significant.

## Results

The MCN-MN communicating branch was present in 21/106 (19.8%) upper limbs evaluated, occurring bilaterally in 10 (47.6%); unilaterally in 11 (52.4%) without significant difference at the side of occurrence ( $p=0.30$ ). Ten were located at the right and eleven at the left ( $p=0.30$ ).

Type I communication was observed in 18 cases (17%) (Fig. 1), where the MCN-MN communicating branch emerged after MCN pierced CbM and it was connected to the MN in an oblique trajectory. The communication arose from MCN in its intramuscular via into CbM (subtype Ia) in 2 cases (11.1%); from the proximal segment of MCN before the branch to BM (subtype Ib) in 2 cases (11.1%) (Fig. 1A); from the mid-segment of the MCN between the emergence of the branches to BM and BrM (subtype Ic) in 8 specimens (44.5%) (Fig. 1B), and in 6 cases (33.3%) the communicating branch arose from the branch to BrM (subtype Id) (Fig. 1C).

In three specimens (2.8%) the communicating branch was found from MN in an oblique trajectory at the level of the mid-third of the arm and then it was connected with the MCN (Type



**Fig. 1 – Communication between the musculocutaneous and median nerves. (a) MCN – MN communication originated from the proximal segment of musculocutaneous nerve (Subtype Ib). Lateral view of right arm. DM – deltoid muscle, CbM – coracobrachialis muscle, BM – biceps muscle, MN – median nerve, UN – ulnar nerve, (\*) communicating branch, (\*\*) BM additional head; (b) MCN – MN communication, originated after the branch to the biceps muscle (subtype Ic). Lateral view of left arm, DM – deltoid muscle, CbM – coracobrachialis muscle, BM – biceps muscle, BrM – brachialis muscle, MCN – musculocutaneous nerve, MN – median nerve, (\*) communicating branch; (c) MCN – MN communication originated from the branch to the brachialis muscle (subtype Id). Lateral view of right arm. DM – deltoid muscle, CbM – coracobrachialis muscle, BM – biceps muscle, MCN – musculocutaneous nerve, MN – median nerve, (\*) communicating branch.**

**Table 1 – Incidence of musculocutaneous – median nerves communication in diverse population according to several authors.**

Author, year	Population	Incidence n [%]			
		Sample size	MCN-MN	MN-MCN	Total
Kosugi et al., 1992	Japanese	75	54.7	–	54.7
Yang et al., 1995	Singaporean	24	12.5	–	12.5
Eglseder et al., 1997	American	108	36	–	36
Chiarapattanakon et al., 1998	Thai	112	11.6	4.4	16
Venieratos et al., 1998	Greek	158	13.9	–	13.9
Choi et al., 2002	British	276	26.4	–	26.4
Beheiry. 2004	Egyptian	60	5	–	5
Loukas et al., 2005	American	258	46.1	–	46.1
Pacha et al., 2005	Spanish	46	28.3	–	28.3
Chitra, 2007	Indian	50	26	–	26
Krishnamurthy et al., 2007	Indian	44	9.1	6.8	15.9
Bhattarai et al., 2009	Nepalesi	32	6.3	–	6.3
Guerrero-Guttenberg et al., 2009	Argentinean	26	53.6	–	53.6
Maeda et al., 2009	Japanese	453	18.8	12.8	41.5
Uysal et al., 2009	Turkish	140	10	–	10
Budhiraja et al., 2011	Indian	116	20.7	–	20.7
Kervancioglu et al., 2011	Turkish	20	25	–	25
Present study	Colombian	106	17	2.8	19.8

II). Type IIa was found in 2 cases (1.9%) and Type IIb in one case (Fig. 2).

The distance between the acromion and the proximal point of the communicating branch was  $138 \pm 39.4$  mm. The emergence point of the communicating branch was more distal at the right side than at the left side (right side 145.7 mm; left side 1329 mm). The distance from the distal point of the communicating branch to the acromion was  $188 \pm 48.3$  mm. The length of the arm measured from the lateral edge of the acromion

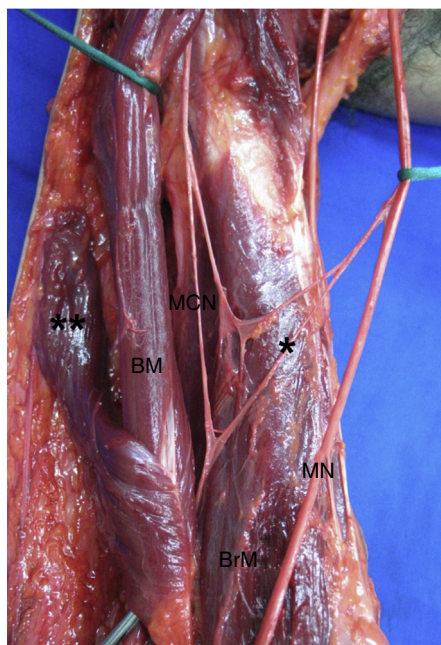
to the bi-epicondylar line of the elbow was  $298 \pm 18.6$  mm. Fifteen (71.4%) communicating branches were seen to be located at the mid third and 6 (28.6%) branches were projected from the inferior aspect of the mid third to the midpoint of the lower third of the arm. The length of the communicating branches was  $57.8 \pm 33.4$  mm, it was longer at the right side (61.9 mm) than at the left side (53.4 mm), but this difference was not statistically significant ( $p = 0.51$ ).

## Discussion

About the frequency of the MCN-MN communication our results (19.8%) are agree with the mid-range (17–36%) reported by some authors.<sup>7,16–18,20,21</sup> The highest incidences have been reported within a range of 37–54.7%.<sup>1,3,8,10</sup> The low incidence of this communication is notorious (range 5–16%) in several studies conducted in diverse populations<sup>5,7,9,15,19,22–24</sup> (Table 1). The wide variability spectrum reported by diverse authors is probably given by multiple factors such as the size of the samples, the methodology used and the ancestral biologic features that determine the variable expression of these structures in the evaluated populations.

Similarly, our findings are consistent with the literature concerning to the predominance of the unilateral occurrence over the bilateral occurrence,<sup>1,7,10,12,17,22</sup> and the predominance of the left side without statistical difference.<sup>5,7</sup> All prior studies establish the significant predominance of the presence of a single communicating branch within the range of 90–93.2% and the presence of two communicating branches with a low frequency (6.8–10.7%).<sup>8,10,17,18,22,25</sup>

Our series describes the presence of Type I MCN-MN communication. This communication is reported by most authors as the most common with an incidence of 45–72%.<sup>3,7,8,22</sup> Similarly, the communicating branch that arose from the mid-segment of the MCN (subtype Ib) indicated by some authors<sup>3,6,15</sup> as the most common one is in agreement with our findings. The communications reported by other stud-



**Fig. 2 – Communication between the median and musculocutaneous nerves. Lateral view of right arm. DM – deltoid muscle, CbM – coracobrachialis muscle, BM – biceps muscle, MCN – musculocutaneous nerve, MN – median nerve, (\*) communicating branch, (\*\*\*) BM additional head.**

ies that are present before the MCN pierces the CbM<sup>7,10,22</sup> were not found in our study. It is probably due to differences of researcher's interpretation about how the lateral and medial fascicles form the MN. Most authors only refer that the communicating branch goes from MCN to MN<sup>5,9,10,15,16,18,22-25</sup> however Type II communication from MN to MCN was found in our study in 2.8% according to reported in other studies with an incidence of 4.4-12.8%,<sup>3,6,23</sup> whereby the communication between MCN and MN may occur both ways.

The distances from the emergence and ending point of the communicating branch to the acromion in our series (138-188 mm) are consistent with the findings of most prior studies as well as the high prevalence of the communicating branch (50-100%) arising after MCN perforates CbM that has reported at the mid-third and at the upper segment of the lower third of the arm.<sup>4-6</sup>

Most researches have made qualitative description about MCN-MN communication, and only few prior studies have reported the length of the communicating branch.<sup>10,17,20</sup> In our series the length of the communication branch (57.8 mm) is relatively higher than reported by Chitra et al.<sup>17</sup> (45 mm) and Loukas et al.<sup>10</sup> (46 mm) whereas Elgseder and Goldman<sup>20</sup> report a considerably shorter length for this communicating branch (18 mm).

The MCN-MN communicating branch was associated to an additional head of the biceps brachii in 23.8% cases in our study (Fig. 2), it has also been highlighted by other authors.<sup>1,3,13</sup> During the planning of surgical procedures in the arm it is important to remember that approximately 1 in 4 upper limbs assessed may present a MCN-MN communication associated with an additional head of the biceps brachii.

The MCN entrapment is rare. It can occur due to an inadequate positioning of the arm during sleep<sup>26,27</sup> because the CbM and BM act as anchor point for MCN. If this situation coexists with a communicating branch where a part of MN passes through CbM, the clinical signs could be similar to those found in MN neuropathy in the hand.<sup>12,14</sup> The diagnosis of MCN-MN communication in this clinical presentation by electromyographic methods could prevent unnecessary releases of the carpal tunnel.

The MCN-MN communication should be considered for clinical examination of nerve injuries at the axilla and the arm, as well as in the surgical procedures to this region like the neuromuscular flaps, peripheral nerve repair or even for the nerve blocks at the upper extremities in anesthetic practice. The MCN or MN injuries proximal or distal to the communicating branches could determine beneficial or deleterious modifications in the function and movement of the upper extremity.<sup>10,15,24</sup> The MCN injury proximal to the MCN-MN communication can lead to an unexpected weakness of the forearm flexor muscles and thenar muscles with clinical signs like seen in a MN injury at the level of the arm. Furthermore, the MN injury proximal to the MN-MCN communication can lead to a clinical presentation characterized by functional preservation of forearm and hand muscles innervated by MN.<sup>12</sup>

In the peripheral nerve surgery, especially in nerve transfers techniques, a good knowledge of the MCN-MN communications is required. The MCN has been successfully

used as a receiver nerve to the recovery of elbow flexion.<sup>28,29</sup> Furthermore, the MCN motor branch to BrM has been used as donor to anterior interosseous nerve and posterior interosseous nerve for the treatment of lower brachial plexus injuries<sup>30,31</sup> as well as in the treatment of tetraplegic patients.<sup>32</sup> Our study is in agreement with previous studies about Type IIc incidence observed in a range of 16.7-33.3%.<sup>3</sup> If the BrM motor branch is used as donor in nerve transfers and Type IIc communication is present, could occur compromise of the forearm pronation, wrist and middle phalanx flexion and/or sensitivity of lateral fingers of the hand.

## Conclusions

Knowledge of the existence of the MCN-MN communication in the arm is clinically important; it allows an adequate evaluation and management of upper limb motor disorders caused by peripheral nerve injuries as well as a correct surgical planning and approaches of axilla and arm.

## Conflicts of interest

The authors declare no conflicts of interest.

## Acknowledgements

We would like to recognize the National Institute of Forensic Medicine, Northeastern Colombian region, for supplying the anatomical pieces used in this study.

## REFERENCES

1. Kosugi K, Shibata S, Yamashita H. Supernumerary head of biceps brachii and branching pattern of the musculocutaneous nerve in Japanese. *Surg Radiol Anat.* 1992;14(2):175-85.
2. Kaus M, Wotowicz Z. Communicating branch between the musculocutaneous and median nerves in human. *Folia Morphol (Warsz).* 1995;54(4):273-7.
3. Maeda S, Kawai K, Koizumi M, Ide J, Tokiyoshi A, Mizuta H, Kodama K. Morphological study of the communication between the musculocutaneous and median nerves. *Anat Sci Int.* 2009;84(1-2):34-40.
4. Mehta V, Yadav Y, Arora J, Kumar H, Suri R, Rath G. A new variant in the brachium musculature with reinforced innervation from a median-musculocutaneous nerve communication. *Morphologie.* 2009;93(301):63-6.
5. Uysal II, Karabulut AK, Büyükmumcu M, Unver Dogan N, Salbacak A. The course and variations of the branches of the musculocutaneous nerve in human fetuses. *Clin Anat.* 2009;22(3):337-45.
6. Chiarapattanakon P, Leechavengvoongs S, Witoonchart K, Verpairojkit C, Thunasethakul P. Anatomy and internal topography of the musculocutaneous nerve The nerves to the biceps and brachialis muscles. *J Hand Surg Am.* 1998;23(2):250-5.
7. Choi D, Rodriguez-Niedenfuhr M, Vazquez T, Parkin I, Sanudo JR. Patterns of connections between the musculocutaneous and median nerves in the axilla and arm. *Clin Anat.* 2002;15(1):11-7.

8. Guerri-Guttenberg RA, Ingolotti M. Classifying musculocutaneous nerve variations. *Clin Anat*. 2009;22(6):671-83.
9. Beheiry EE. Anatomical variations of the median nerve distribution and communication in the arm. *Folia Morphol (Warsz)*. 2004;63(3):313-8.
10. Loukas M, Aqueelah H. Musculocutaneous median nerve connections within proximal and distal to the coracobrachialis muscle. *Folia Morphol (Warsz)*. 2005;64(2):101-8.
11. Le Minor JM. A rare variant of the median and musculocutaneous nerve in man. *Arch Anat Histol Embryol*. 1990;73:33-42.
12. El Falougy H, Selmeçiova P, Kubikova E, Stenova J, Haviarova Z. The variable communicating branches between musculocutaneous and median nerves: a morphological study with clinical implications. *Bratisl Lek Listy*. 2013;114(5):290-4.
13. Ozturk NC, Uzmannel D, Ozturk H. An unreported pattern of musculocutaneous and median nerve communication with multiple variations of biceps brachii: a case report. *Surg Radiol Anat*. 2010;32(9):887-90.
14. Wertsch JJ, Melvin J. Median nerve anatomy and entrapment syndromes: a review. *Arch Phys Med Rehabil*. 1982;63(12):623-7.
15. Bhattarai C, Poudel PP. Unusual variation in musculocutaneous nerves in Nepalese. *Kathmandu Univ Med J*. 2009;7(4):408-10.
16. Budhiraja V, Rastogi R, Asthana AK, Sinha P, Krishna A, Trivedi V. Concurrent variations of median and musculocutaneous nerves and their clinical correlation. A cadaveric study. *Ital J Anat Embryol*. 2011;116(2):67-72.
17. Chitra R. Various types of intercommunications between musculocutaneous and median nerves: an analytical study. *Ann Indian Acad Neurol*. 2007;10(2):100-4.
18. Pacha Vicente D, Forcada- Calvet P, Carrera- Burgaya A, Llusá-Pérez M. Innervation of biceps brachii and brachialis: anatomical and surgical approach. *Clin Anat*. 2005;18(3):186-94.
19. Yang ZX1, Pho RW, Kour AK, Pereira BP. The musculocutaneous nerve and its branches to the biceps and brachialis muscles. *J Hand Surg Am*. 1995;20(4):671-5.
20. Eglseder WA Jr, Goldman M. Anatomic variations of the musculocutaneous nerve in the arm. *Am J Orthop*. 1997;26(11):777-80.
21. Kervancioglu P, Orhan M, Kilinc N. Patterns of motor branching of the musculocutaneous nerve in human fetuses and clinical significance. *Clin Anat*. 2011;24(2):168-78.
22. Venieratos D, Anagnostopoulou S. Classification of communications between the musculocutaneous and median nerves. *Clin Anat*. 1998;11(5):327-31.
23. Krishnamurthy A, Nayak SR, Venkatraya Prabhu L, Hegde RP, Surendran S, Kumar M, et al. The branching pattern and communications of the musculocutaneous nerve. *J Hand Surg Eur*. 2007;32(5):560-2.
24. Laburthe-Tolra Y. Bases anatomiques des lésions opératoires du nerf musculo-cutané dans la chirurgie de l'épaule. *Chirurgie*. 1995;120(3):171-6.
25. Prasada, Rao PV, Chaudhary SC. Communication of the musculocutaneous nerve with the median nerve. *East Afr Med J*. 2000;77(9):498-503.
26. Inaba A, Yokota T. Isolated musculocutaneous nerve palsy during sleep. *Muscle Nerve*. 2003;28(6):773-4.
27. Mautner K, Keel JC. Musculocutaneous nerve injury after simulated freefall in a vertical wind-tunnel: a case report. *Arch Phys Med Rehabil*. 2007;88(3):391-3.
28. Merrell GA, Barrie KA, Katz DL, Wolfe SW. Results of nerve transfer techniques for restoration of shoulder and elbow function in the context of a meta-analysis of the English literature. *J Hand Surg Am*. 2001;26(2):303-14.
29. Yang LJ, Chang KW, Chung KC. A systematic of nerve transfer and nerve repair for the treatment of adult upper brachial plexus injury. *Neurosurgery*. 2012;71(2):417-29.
30. García A, Fernández E, Martínez F. Transfer of brachioradialis motor branch to the anterior interosseous nerve in C8-T1 brachial plexus palsy. An anatomic study. *Microsurgery*. 2013;33(4):297-300.
31. Ray WZ, Yarbrough CK, Yee A, Mackinnon SE. Clinical outcomes following brachialis to anterior interosseous nerve transfers. *J Neurosurg*. 2012;117(3):604-9.
32. Bertelli JA, Ghizoni MF. Brachialis muscle transfer to reconstruct finger flexion or wrist extension in brachial plexus palsy. *J Hand Surg Am*. 2006;31(2):190-6.