



## Original Article

# Use of superficial peroneal nerve graft for treating peripheral nerve injuries<sup>☆</sup>



Samuel Ribak<sup>a,b,\*</sup>, Paulo Roberto Ferreira da Silva Filho<sup>a,b</sup>, Alexandre Tietzmann<sup>a</sup>, Helton Hiroshi Hirata<sup>a,b</sup>, Carlos Augusto de Mattos<sup>a</sup>, Sérgio Augusto Machado da Gama<sup>a</sup>

<sup>a</sup> Pontifícia Universidade Católica de Campinas, Campinas, SP, Brazil

<sup>b</sup> Hospital Nossa Senhora do Pari, São Paulo, SP, Brazil

## ARTICLE INFO

## Article history:

Received 1 March 2015

Accepted 6 April 2015

Available online 13 January 2016

## Keywords:

Peripheral nerve

Nerve/transplantation

Peroneal neuropathies

## ABSTRACT

**Objective:** To evaluate the clinical results from treating chronic peripheral nerve injuries using the superficial peroneal nerve as a graft donor source.

**Methods:** This was a study on eleven patients with peripheral nerve injuries in the upper limbs that were treated with grafts from the sensitive branch of the superficial peroneal nerve. The mean time interval between the dates of the injury and surgery was 93 days. The ulnar nerve was injured in eight cases and the median nerve in six. There were three cases of injury to both nerves. In the surgery, a longitudinal incision was made on the anterolateral face of the ankle, thus viewing the superficial peroneal nerve, which was located anteriorly to the extensor digitorum longus muscle. Proximally, the deep fascia between the extensor digitorum longus and the peroneal longus muscles was dissected. Next, the motor branch of the short peroneal muscle (one of the branches of the superficial peroneal nerve) was identified. The proximal limit of the sensitive branch was found at this point.

**Results:** The average space between the nerve stumps was 3.8 cm. The average length of the grafts was 16.44 cm. The number of segments used was two to four cables. In evaluating the recovery of sensitivity, 27.2% evolved to S2+, 54.5% to S3 and 18.1% to S3+. Regarding motor recovery, 72.7% presented grade 4 and 27.2% grade 3. There was no motor deficit in the donor area. A sensitive deficit in the lateral dorsal region of the ankle and the dorsal region of the foot was observed. None of the patients presented complaints in relation to walking.

**Conclusions:** Use of the superficial peroneal nerve as a graft source for treating peripheral nerve injuries is safe and provides good clinical results similar to those from other nerve graft sources.

© 2016 Sociedade Brasileira de Ortopedia e Traumatologia. Published by Elsevier Editora Ltda. All rights reserved.

<sup>☆</sup> Work developed in the Hand Surgery and Microsurgery Group, Pontifícia Universidade Católica de Campinas, Campinas, SP, Brazil, and Hospital Nossa Senhora do Pari, São Paulo, SP, Brazil.

\* Corresponding author.

E-mail: [ribaksamuel@yahoo.com.br](mailto:ribaksamuel@yahoo.com.br) (S. Ribak).

<http://dx.doi.org/10.1016/j.rboe.2015.04.010>

2255-4971/© 2016 Sociedade Brasileira de Ortopedia e Traumatologia. Published by Elsevier Editora Ltda. All rights reserved.

## Emprego do enxerto do nervo fibular superficial para tratamento de lesões de nervos periféricos

### R E S U M O

#### Palavras-chave:

Nervos periféricos  
Nervo/transplante  
Neuropatias fibulares

**Objetivo:** Avaliar resultados clínicos do tratamento das lesões crônicas de nervos periféricos com o nervo fibular superficial como fonte doadora de enxerto.

**Métodos:** Estudo de 11 pacientes com lesões de nervos periféricos nos membros superiores tratados com enxerto do ramo sensitivo do nervo fibular superficial, com intervalo médio de 93 dias entre a data de registro da lesão e a cirurgia. Foram observadas lesões do nervo ulnar em oito pacientes e do nervo mediano em seis. Em três ambos os nervos foram lesados. Na cirurgia faz-se incisão longitudinal na face anterolateral no tornozelo, visualiza-se o nervo fibular superficial, situado anteriormente ao músculo extensor longo dos artelhos. Proximalmente diseca-se a fáscia profunda entre os músculos extensor longo dos artelhos e o fibular longo. A seguir, identifica-se o ramo motor do músculo fibular curto, um dos ramos do nervo fibular superficial. O limite proximal do ramo sensitivo encontra-se nesse ponto.

**Resultados:** A média do espaço entre os cotos nervosos foi de 3,8 cm, comprimento médio dos enxertos de 16,44 cm, número de segmentos usados de dois a quatro cabos. Na avaliação da recuperação da sensibilidade, 27,2% evoluíram para S2+, 54,5% para S3 e 18,1% para S3+. Quanto à recuperação motora, 72,7% apresentavam grau 4 e 27,2%, grau 3. Não houve déficit motor da área doadora, observou-se déficit sensitivo na região dorso lateral do tornozelo e dorsal do pé. Nenhum paciente apresentou queixas à deambulação.

**Conclusões:** O uso do nervo fibular superficial no tratamento das lesões de nervos periféricos como fonte de enxerto é seguro e proporciona resultados clínicos semelhantes a outras fontes de enxerto de nervos.

© 2016 Sociedade Brasileira de Ortopedia e Traumatologia. Publicado por Elsevier Editora Ltda. Todos os direitos reservados.

## Introduction

In treating peripheral nerve injuries, the objective is to achieve primary repair without tension on the suture. Situations in which there is no possibility of suturing, or in cases of loss of nerve segments, such as late injuries, or in complex cases, the treatment consists of reconstruction of the nerve.<sup>1</sup>

Over recent decades, a variety of experimental studies have been developed to determine the best methods for filling the gap between the stumps of injured nerves.<sup>2</sup>

Although research using autogenous tubes (from muscles or vessels)<sup>3,4</sup> and synthetic (non-autogenous) tubes<sup>5</sup> has been developed, grafts from autogenous nerves are still the material most indicated and used.<sup>1,2</sup>

In choosing the nerve graft, the matters that need to be taken into consideration include whether it is sufficiently long to ensure tension-free anastomosis; whether the number of fasciculi is coincident with those of the receptor nerve; and whether the sequelae in the donor area are minimal.<sup>6</sup>

Given these characteristics, the donor nerves are generally limited to the cutaneous nerves of the extremities.

In the upper limbs, the nerves that are used most are the medial cutaneous nerve of the forearm and the lateral cutaneous nerve of the forearm.<sup>1,2,6</sup> The advantage of these nerves is their location (in the same limb that is to be operated), while their disadvantage is their small diameter and limited length, which is often insufficient to adequately fill the gap.<sup>6</sup>

The sural nerve, in the lower limbs, is considered to be the standard for nerve grafts.<sup>7,8</sup> It is the one most used because of its more suitable diameter and length (up to 30 cm in length). However, despite the above characteristics, even this may not always be sufficient when larger gaps need to be filled or in cases of multiple injuries. It also has the inconvenience of sensory loss on the lateral face of the foot or other complications inherent to the surgical procedure.

In seeking alternatives, the superficial fibular nerve has emerged as an interesting option. This is a lateral branch of the common fibular nerve that innervates the long and short fibular muscles. It supplies sensitivity to the lateral and inferior faces of the skin of the lower leg and dorsum of the foot.<sup>9</sup> In the lower third of the lower leg, it perforates the deep fascia and penetrates into the subcutaneous cellular tissue at the junction of the middle and lower thirds. At this level (i.e. the malleolus of the ankle), it divides into two branches (medial and intermediate dorsal cutaneous branches), which are both responsible for the sensitivity of the dorsal surface of the foot.<sup>10</sup> This is the commonest branching pattern that has been described. In a less common type, these branches pass independently through the deep fascia, which indicates the starting point for branching that is more proximal,<sup>2</sup> but it presents the same area of sensitivity on the foot.

Buntic et al.<sup>6</sup> and Agthong et al.<sup>11</sup> published studies reviewing the limitations of the number of nerve graft sources. They provided deeper knowledge regarding use of the superficial fibular nerve as a possible efficient alternative graft source, although the literature on this remains sparse.

**Table 1 – Data on the 11 patients: patient number, sex, age, time between the original injury and the surgical treatment, and nerve affected.**

Patient	Sex	Age (years)	Time elapsed since original injury (months)	Nerve affected
1	Male	19	9	Median and ulnar
2	Male	58	2	Ulnar
3	Male	39	7	Ulnar
4	Male	35	1	Median and ulnar
5	Male	36	4	Ulnar
6	Male	35	1	Median
7	Male	41	1	Median
8	Male	31	1	Ulnar
9	Male	35	1	Ulnar
10	Male	23	2	Median and ulnar
11	Male	30	3	Median

The objective of the present study was to evaluate the results from clinical use of the superficial fibular nerve as a graft source for treating peripheral nerve injuries.

## Materials and methods

In this retrospective study conducted between June 2011 and January 2013, 11 patients with diagnoses of peripheral nerve injuries underwent operations. Direct repairs to these injuries during the operation were not possible. In all of these cases, the sensory branch of the superficial fibular nerve was used as a graft donor source.

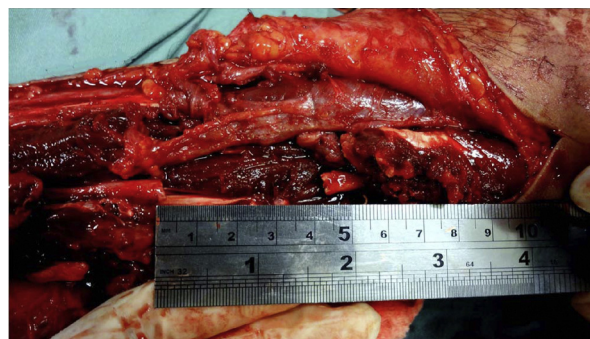All the patients were given explanations and signed a statement of legal responsibility, for the study to be conducted. The study received prior approval from the ethics committee for research on human beings.

All the patients were male, with a mean of 4.7 years (range: 19–58), and the time that had elapsed between the initial injury and the surgical treatment ranged from one to nine months (mean of 2.9). The upper limbs were affected in all cases, with wounds in the volar region of the forearm: seven on the left side and four on the right side, and the dominant side was affected in five cases. The ulnar nerve was injured in eight cases and the median nerve in six cases. In three cases (Table 1), there was concomitant injury to both of these nerves.

## Surgical technique

General anesthesia was used in all the cases. The patient was positioned in supine decubitus, a hand table was used and exsanguination was performed using a pneumatic cuff. The elbow and forearm were kept extended in order to mark out the incision.

After the nerve injury had been identified, the technique consisted of resecting the damaged nerve tissue until healthy tissue was encountered. The fascicles of this tissue were identified. At this point, the gap between the stumps was measured, along with the size of the graft that was to be harvested (Fig. 1).



**Fig. 1 – Measurement in centimeters of the space between the stumps in a case of ulnar nerve injury.**

With the limb positioned, the anterior subcutaneous course of the superficial fibular nerve to the lateral malleolus could be viewed (Fig. 2). The subcutaneous course of this nerve could be viewed in nine patients before the operation.

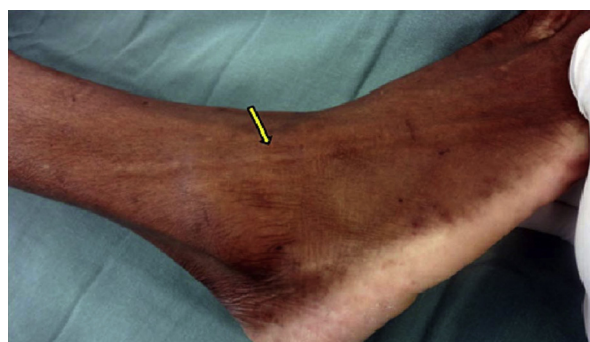With the patient in the same decubitus position and with a tourniquet on the lower limb that was to be operated, a longitudinal incision was made in the lateral face of the ankle, 4 cm anteriorly to the midline of the malleolus.

After the subcutaneous tissue had been opened, the superficial fibular nerve could be viewed. This was located anteriorly to the long extensor muscles of the toes. At this location, proximal dissection was performed by means of longitudinal or continuous incisions, which followed the subcutaneous path of the nerve as far as the lower third of the lower leg, where it perforated the deep fascia (Fig. 3).

Depending on the size of graft required, dissection was then performed in the proximal direction at a deeper level, in which the deep fascia was sectioned along the long axis of the incision and the layer between the long extensor muscle of the toes and the long fibular muscles was separated out laterally (Fig. 4).

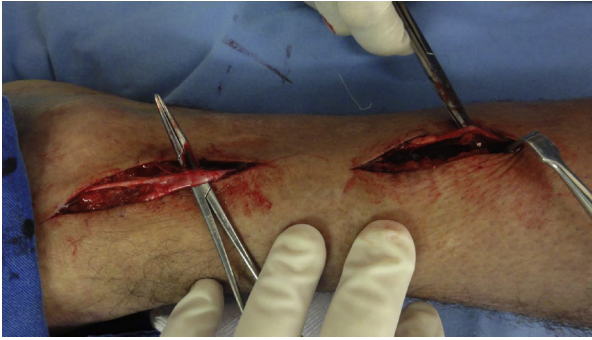Following this, the branch to the short fibular muscle was identified. The proximal limit of the sensitive branch was set at this point. The distal dissection, at the level of the lateral malleolus, followed the medial and intermediate dorsal cutaneous branches (Fig. 5).

To harvest the nerve, sectioning of the proximal portion of the nerve was preferred. Following this, the nerve was raised

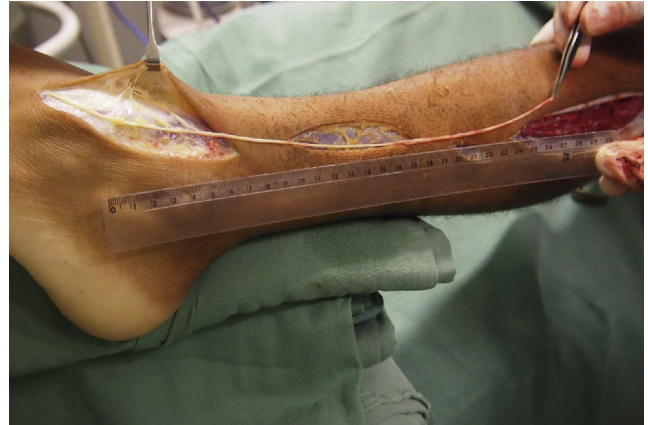


**Fig. 2 – Identification of the course of the superficial fibular nerve under the skin, anteriorly to the lateral malleolus of the ankle (yellow arrow).**

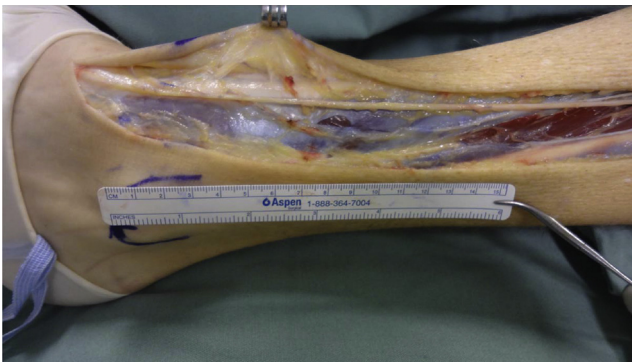




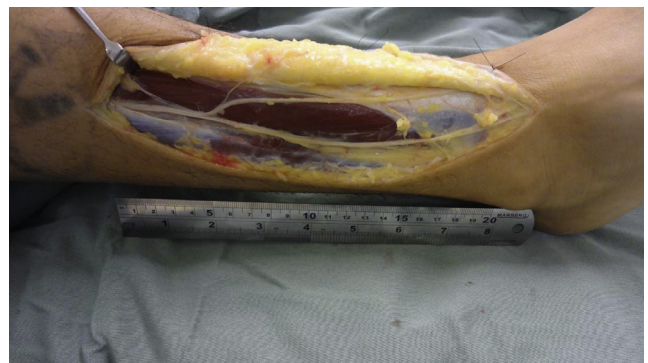
**Fig. 3 – Viewing of the fibular nerve and its anatomical references: 4 cm anteriorly to the lateral malleolus and dissection more proximally along its subcutaneous course.**



**Fig. 6 – View of the proximal harvesting of the nerve and its elevation along its entire course.**



**Fig. 4 – Identification of the superficial fibular nerve in a more proximal dissection, through opening the fascia.**



**Fig. 7 – Identification of the most proximal branching of the sensory fibular nerve.**

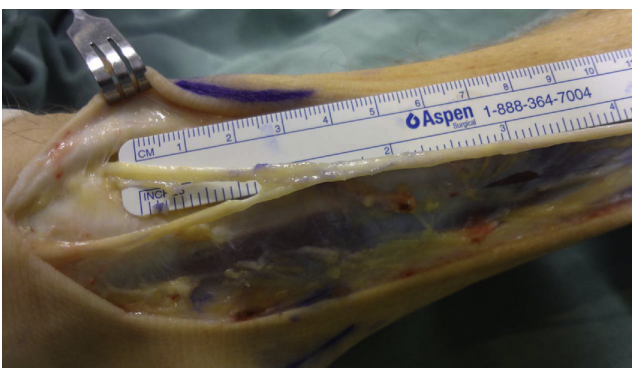
proximally and along its entire length, including the two distal branches (Fig. 6).

Independent of the branching pattern observed, the main trunk of the superficial fibular nerve penetrated into the deep fascia, or the medial and intermediate dorsal cutaneous branches penetrated it separately. The dissection was similar to what was described above, since in identifying the branches, they were followed to the start of the most proximal branching, along the deep fascia (Fig. 7).

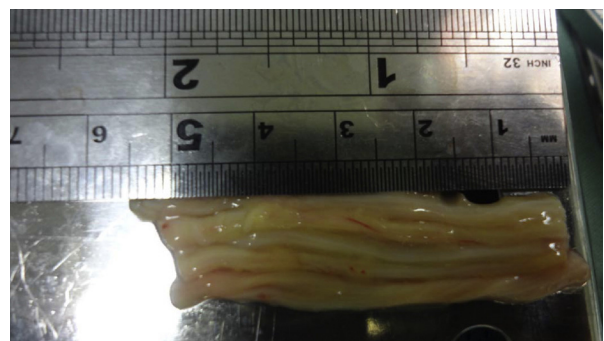
In the receptor area, the length and diameter of the inter-fascicular grafts that would be necessary in order both to

fill the gap between the stumps and to cover the entire cross-sectional area of the injured nerve were ascertained. In preparing the final graft, cables of appropriate size were arranged in parallel and were joined using fibrin glue (Fig. 8).

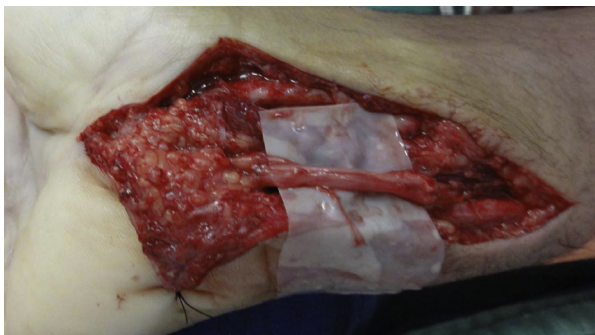Following this, the graft was sutured both proximally and distally (Fig. 9) using fibrin glue together with the suturing (Ethilon 8 or 9-0 nylon thread). In cases in which associated tendon injuries were present, the tendons were sutured first.



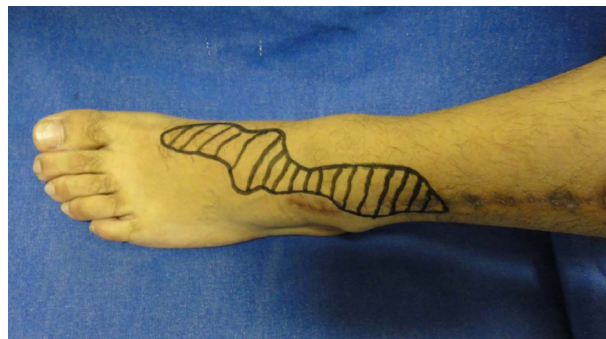**Fig. 5 – Identification of the medial and intermediate dorsal cutaneous branches after distal dissection.**



**Fig. 8 – Graft cables of appropriate size for filling the space between the nerve stumps and covering the diameter of the injured nerve.**



**Fig. 9 – Nerve graft positioned between the nerve stumps in an appropriate position for suturing without tension.**



**Fig. 10 – Area of residual anesthesia, six months after the operation.**

### Criteria for assessing the results

- Measurement of the gap between the nerve stumps after excision of the neuroma, using a ruler with a scale in millimeters, with the joints adjacent to the injury maintained in the neutral position.
- Identification of the anatomical pattern of the branching of the fibular nerve, defined as type 1, when the main trunk of the superficial fibular nerve penetrated into the deep fascia; or type 2, with separate penetration of the medial and intermediate dorsal cutaneous branches into the deep fascia.<sup>11</sup>
- Length of the superficial fibular nerve harvested.
- Number of cables needed to achieve adequate thickness for the cross-sectional area of the injured nerve.
- Evaluation of the recovery of sensitivity (measured using the scale of the British Medical Council System of Assessment), in which S0 represented lack of sensory recovery; S1, recovery regarding deep cutaneous pain; S2, recovery regarding superficial cutaneous pain; S2+, exacerbation of the response; S3, recovery regarding pain and touch without exacerbation and discrimination of two points >15 mm, S3+, good localization of stimuli and discrimination of two points at 7–12 mm; and S4, complete recovery and discrimination of two points at 2–6 mm.
- Evaluation of motor recovery, using the scale of the British Medical Council System of Assessment, in which grade 5 represented normal strength against total resistance; grade 4, muscle strength is reduced, but there is muscle contraction against resistance; grade 3, joint movement is only achieved against gravity and without resistance from the examiner; grade 2, there is muscle strength and joint movement only without resistance from gravity; grade 1, muscle contraction without movement is seen or felt, or fasciculation is observed in the muscle; and grade 0, no movement is observed.
- Sensory and motor deficits in the donor area.
- Complaints about abnormalities of walking.
- Complaints about the healing in the donor area.

### Results

The mean duration of the postoperative follow-up was 11.18 months (range: six to 18).

The mean distance between the nerve stumps after excision of the neuroma was 3.8 cm (range: 3–5.5 cm). In cases of injury only to the ulnar nerve, it was 3.57 cm; and to the median nerve, 4.08 cm. When both nerves were injured, the mean size of the graft needed was 4.13 cm.

Regarding the anatomical pattern of fibular nerve branching, 90.9% (ten cases) presented the type 1 pattern and only one case showed type 2 (9.09%). The maximum length of the graft harvested was 26 cm and the minimum was 9 cm (mean of 16.9 cm).

The mean number of cables used in order to achieve adequate thickness of the cross-sectional area was three to four cables for the median nerve and two to three for the ulnar nerve.

In evaluating the recovery of sensitivity, 27.2% presented S2+ (three cases), 54.5% S3 (six cases) and 18.1% S3+ (two cases). Regarding motor recovery, 72.7% (eight cases) presented grade 4 and 27.2% (three cases), grade 3.

In no case was motor loss in the donor limb observed.

Sensory deficit in the donor area was observed in the dorsolateral region of the ankle and the dorsal region of the foot (Fig. 10). There was no sensory deficit in the plantar region. None of the patients presented complaints in relation to walking. Regarding the donor area, there were no cases on complaints about healing, even in the cases in which a large quantity of graft was necessary, with a greater number of incisions to harvest it.

Only one case presented superficial infectious complications of the skin in the donor area, which was seen one week after the surgery. It was treated with oral antibiotic, with good evolution.

### Discussion

Despite decades of advances in nerve research,<sup>12</sup> treatment of peripheral nerve injuries continues to be a significant challenge.

For filling the space between the nerve stumps, grafts from autogenous nerves remain the gold standard for nerve reconstruction, since they provide support architecture, neural growth guides, neurotrophic factors and Schwann cells.<sup>13</sup>

The number of nerve graft donor sources available is considered to be limited. In the upper limbs, despite the advantage



of the locations of the medial and lateral cutaneous nerves of the forearm, these nerves are of limited thickness and length.<sup>6</sup>

The sural nerve is the one most used, and it is considered to be the standard as a graft donor source.<sup>7,8</sup> However, harvesting this nerve presents some inconveniences in terms of its positioning, the need to change decubitus and the area of loss of sensitivity in the lateral region. This source is limited when a large quantity of graft is needed.

The ideal would be to have an optional graft source for when this is necessary, or even as the first choice to be used. The superficial fibular nerve has been shown to be a good option as a donor source, since it supplies a long graft of good caliber that is anatomically predictable. It can be harvested with the patient in dorsal decubitus and is easily accessible, without the need for changes of decubitus.

In an anatomical study, Buntic et al.<sup>6</sup> reported that in their sample, the mean length harvested was 14.7 cm (range: 3–25 cm), and that 40 cm would be possible. In our study, we achieved a similar mean, of 16.44 cm (range: 9–26 cm), which was comparable to the sizes used when the sural nerve was chosen.<sup>7,13</sup>

Loss of sensitivity in the region supplied by the donor nerve is a form of morbidity common to any graft source. What may differentiate the sources is the extent of the area and its location, which might be close to an inconvenient region. In this regard, use of the lateral cutaneous nerve can be cited, which gives rise to loss of sensitivity along the lateral face of the forearm that may extend over the thenar region, which is undesirable in cases of injuries to the median nerve or finger nerves.

In the case of the radial sensory nerve, compromising the dorsolateral region of the hand is also undesirable.

In the lower limbs, preservation of lateral and plantar sensitivity is extremely important for preventing ulcers and other wounds. In this regard, use of a graft from the superficial fibular nerve has an advantage because only an area of dorsal anesthesia occurs.

In relation to possible complications in the donor area, formation of a painful neuroma would be one of these. Buntic et al.<sup>6</sup> observed the presence of a case of painful neuroma of the superficial fibular nerve that had to be operated. No presence of neuromas was observed in our series. Formation of neuromas upon harvesting the sural nerve has been reported in the literature at rates ranging from 22% to 42% of the cases.<sup>14,15</sup>

In our series, no injuries to motor branches to the fibular muscles were detected in any of our cases.

Knowledge of the anatomical variations of branching of the fibular nerve is of prime importance for surgeons who wish to use this nerve as a graft source, so that injury while raising its distal branches can be avoided. In the present study, the type 1 anatomical pattern of branching was more prevalent. The main trunk of the superficial fibular nerve penetrated the deep fascia, as also seen in other studies in the literature, which confirms the ease of harvesting of this nerve. However, it should be noted that occurrences of type 2 are possible.

The possibility of subcutaneous viewing of the fibular nerve in most patients makes it easier to make the initial identification and to perform the dissection. In the literature, some methods for viewing this nerve have been described, such

as plantar flexion of the ankle combined with inversion. Its course in the distal segment of the lower leg can be marked out before the operation, even if its location may change with different positions of the foot and ankle.<sup>16</sup> This is an advantage in dissecting it.

Accurate and reproducible assessment of the evolution if treatments for nerve injuries is difficult, given that many variables are involved, in relation to both the patient's comorbidities and the surgical technique, type of lesion and postoperative rehabilitation protocols.

The results from this study on clinical use of grafts from the superficial fibular nerve were comparable with those in the literature. Use of this nerve remains low, but the overall results were similar to those from series that used other nerves as graft donor sources.<sup>6,7</sup>

The superficial fibular nerve therefore emerges as a safe and valuable donor nerve source, particularly in cases that require long grafts. Not only does it constitute an optional source, but also it could form the first choice for use as an autologous nerve graft, because of its advantages.

---

## Conclusions

Use of the superficial fibular nerve as a nerve graft source for treating peripheral nerve injuries is safe and provides good clinical results.

---

## Conflicts of interest

The authors declare no conflicts of interest.

---

## REFERENCES

1. Birch R. Nerve repair. In: Wolfe SW, Hotchkiss RN, Pederson WC, Kozin SH, editors. *Green's operative hand surgery*. 6th ed. Philadelphia: Elsevier/Churchill Livingstone; 2011. p. 1035–74.
2. Mafi P, Hindocha S, Dhital M. Advances of peripheral nerve repair techniques to improve hand function: a systematic review of literature. *Open Orthop J*. 2012;6 Suppl 1:M7:60–8.
3. Chiu DT, Strauch B. A prospective clinical evaluation of autogenous vein grafts used as a nerve conduit for distal sensory nerve defects of 3 cm or less. *Plast Reconstr Surg*. 1990;86(5):928–34.
4. Norris RW, Glasby MA, Gattuso JM, Bowden RE. Peripheral nerve repair in humans using muscle autografts. A new technique. *J Bone Jt Surg Br*. 1988;70(4):530–3.
5. Mackinnon SE, Dellon AL, Hudson AR, Hunter DA. Nerve regeneration through a pseudosynovial sheath in a primate model. *Plast Reconstr Surg*. 1985;75(6):833–41.
6. Buntic RF, Buncke HJ, Kind GM, Chin BT, Ruebeck D, Buncke GM. The harvest and clinical application of the superficial peroneal sensory nerve for grafting motor and sensory nerve defects. *Plast Reconstr Surg*. 2002;109(1):145–51.
7. Lee YH, Chung MS, Gong HS, Chung JY, Park JH, Baek GH. Sural nerve autografts for high radial nerve injury with nine centimeter or greater defects. *J Hand Surg Am*. 2008;33(1):83–6.
8. Ortigüela ME, Wood MB, Cahill DR. Anatomy of the sural nerve complex. *J Hand Surg Am*. 1987;12(6):1119–23.

9. Narendiran K, Rao Mohandas KG, Somayaji SN, Koshy S, Rodrigues V. Clinically important anatomical variation of cutaneous branches of superficial peroneal nerve in the foot. *Open Anat J.* 2010;2:1-4.
10. Pacha D, Carrera A, Llusa M. Clinical anatomy of the superficial peroneal nerve in the distal leg. *Eur J Anat.* 2003;7(1):15-20.
11. Agthong S, Huanmanop T, Sasivongsbhakdi T, Ruenkhwan K, Piyawacharapun A, Chentanez V. Anatomy of the superficial peroneal nerve related to the harvesting for nerve graft. *Surg Radiol Anat.* 2008;30(2):145-8.
12. Fornazari AA, de Rezende MR, Mattar Júnior R, Taira RI, Dos Santos GB, Paulos RG. Effect of neuro-trophic factor MDP on rats' nerve regeneration. *Braz J Med Biol Res.* 2011;44(4):327-31.
13. Payne SH Jr. Nerve repair and grafting in the upper extremity. *J South Orthop Assoc.* 2001;10(3):173-89.
14. Staniforth P, Fisher TR. The effects of sural nerve excision in autogenous nerve grafting. *Hand.* 1978;10(2):187-90.
15. Oberle J, Richter HP. Painful paresthesia after removal of the sural nerve for autologous nerve transplantation. *Zentralbl Neurochir.* 1998;59(1):1-3.
16. de Leeuw PA, Golanó P, Sierevelt IN, van Dijk CN. The course of the superficial peroneal nerve in relation to the ankle position: anatomical study with ankle arthroscopic implications. *Knee Surg Sports Traumatol Arthrosc.* 2010;18(5):612-7.