

A Novel Method of Treatment of Small Osteolabral Avulsions Associated with Posterior Fracture-dislocation of the Hip

Um novo método de tratamento de pequenas avulsões osteolabrais associadas a fratura-luxação posterior do quadril

Sandeep Gupta¹  Rajeev Kansay²  Anmol Sharma¹  Naveen Mittal² 

¹Fortis Hospital, Mohali, Punjab, India

²Government Medical College and Hospital, Chandigarh, India

Address for correspondence Anmol Sharma, Fortis Hospital, Mohali, Punjab, India (e-mail: Anmolsharma13@gmail.com).

Rev Bras Ortop 2024;59(3):e467–e470.

Abstract

Small osteolabral avulsions of the hip can be easily missed, and postreduction stress testing and computed tomography (CT) scans of the hip should be performed to look for these injuries. The usual modality of treatment of these unstable osteolabral avulsions is suture anchors, Herbert screws or spring plates. But when the bony avulsion is small, the use of these implants becomes a tedious job. We present a novel technique to fix small osteochondral avulsion fractures not amenable to fixation using screws or spring plates.

We performed a retrospective analysis of 57 cases of patients who underwent open reduction and internal fixation for posterior fracture dislocation of the acetabulum, and we identified 6 cases of small posterior labral osteochondral fragments leading to instability. These injuries were fixed using a novel method. The mean Harris Hip Score at the final follow-up was of 92.5. Fixation of osteochondral avulsions associated with posterior hip fracture dislocation can be a difficult task if the bony fragment is small. Our technique is a simple, cost-effective and reliable way of fixing such avulsions with satisfactory outcomes.

Keywords

- ▶ acetabulum
- ▶ femur head
- ▶ fractures, bone
- ▶ hip dislocation

Resumo

Pequenas avulsões osteolabrais do quadril podem passar despercebidas, e testes de estresse pós-redução e tomografia computadorizada do quadril devem ser realizados para sua detecção. O tratamento dessas avulsões osteolabrais instáveis geralmente é feito com âncoras de sutura, parafusos de Herbert ou placas-molas. Em avulsões ósseas pequenas, porém, o uso desses implantes é um trabalho tedioso. Apresentamos uma nova técnica de fixação de pequenas fraturas com avulsões osteocondrais não passíveis de fixação com parafusos ou placas-molas.

Work developed at the Government Medical College and Hospital, Chandigarh, India.

received
December 28, 2021
accepted after revision
February 18, 2022

DOI <https://doi.org/10.1055/s-0044-1786520>.
ISSN 0102-3616.

© 2024. The Author(s).

This is an open access article published by Thieme under the terms of the Creative Commons Attribution 4.0 International License, permitting copying and reproduction so long as the original work is given appropriate credit (<https://creativecommons.org/licenses/by/4.0/>).

Thieme Revinter Publicações Ltda., Rua do Matoso 170, Rio de Janeiro, RJ, CEP 20270-135, Brazil

Palavras-chave

- ▶ acetábulo
- ▶ cabeça do fêmur
- ▶ fraturas ósseas
- ▶ luxação do quadril

Realizamos uma análise retrospectiva de 57 casos de pacientes submetidos à redução aberta e fixação interna de fratura-luxação posterior do acetábulo, e identificamos 6 casos em que um pequeno fragmento osteocondral labral posterior causava instabilidade. Essas lesões foram corrigidas com um novo método. A pontuação média no Harris Hip Score no último acompanhamento foi de 92,5. A fixação de avulsões osteocondrais associadas a fratura-luxação posterior do quadril pode ser difícil se o fragmento ósseo for pequeno. Nossa técnica é uma maneira simples, econômica e confiável de corrigir tais avulsões com resultados satisfatórios.

Introduction

Posttraumatic posterior hip dislocation is usually caused by high-energy trauma in young individuals involved in road traffic accidents (RTAs). The mechanism of injury is usually a dashboard injury in which there is an axially-directed force from the knee in a flexed hip, and, depending on the magnitude of the force and the position of the hip at the time of the injury, various other associated injuries can occur, such as osteochondral avulsion, posterior wall fracture, and transverse fracture with involvement of the posterior wall.¹ Reduction of a hip dislocation should be performed as an emergency procedure within twelve hours to decrease the risk of avascular necrosis (AVN) of the hip. Non-concentric reduction or persistent instability after reduction is usually caused by intra-articular loose bodies, incarcerated fragments or posterior osteolabral avulsion.² Addressing these injuries is paramount to achieve a stable and concentric reduction and decrease the risk of redislocation of hip, osteoarthritis, and hip AVN and enable early mobilization. Small osteolabral avulsions can be easily missed, and post-reduction stress testing and computed tomography (CT) scans of the hip should be performed to look for these injuries.³ The usual modality of treatment of these unstable osteolabral avulsions is suture anchors, Herbert screws or spring plates.⁴ But when the size of the bony avulsion is small, the use of these implants becomes a tedious job. We present a novel technique to fix small osteochondral avulsion fractures not amenable to fixation using screws or spring plates.

Description of the Method

In the present study, we performed a retrospective analysis of 57 cases of patients who underwent open reduction and internal fixation for posterior fracture dislocation of the acetabulum by a single surgeon at a tertiary-level trauma center in Northern India from 2012 to 2018. We obtained approval from the institutional Ethics Committee, and written informed consent was taken from all patients for inclusion in the study and publication of data in a scientific journal without any disclosure of personal details.

We identified six cases of small posterior labral osteochondral fragments leading to instability, which were fixed

using a novel method. All six patients were male, with a mean age of 36.1 (range: 21 to 54) years, and the right side was involved in 5 patients. The mechanism of injury in every case was motor vehicle accident, and all presented a concurrent posterior dislocation at the time of the injury. Three patients presented a transverse acetabular fracture with associated posterior osteolabral fracture, and the other three, only osteochondral fragments associated with posterior dislocation. In the latter three patients, posterior dislocation was reduced in the emergency department under sedation, but they presented persistent dynamic instability. Therefore, surgery was planned, and dynamic instability was confirmed by stress testing in the operation theater (OT) under C-arm and obturator view of the hip. Open reduction as per the Matta criteria⁵ was planned for the patients with an associated transverse fracture, and the osteochondral fragment was addressed when persistent posterior instability was noted after fixation of the transverse fracture.

All patients were operated using the Kocher Langenbeck approach. Surgical dislocation of the hip was not performed in any of the cases. Trochanteric flip osteotomy was performed in two transverse fractures and one posterior wall injury. In every case, the osteochondral fragments were so small that they could not be fixed using routine methods such as screws or spring plates (▶ **Figs. 1–2**). The fragments were stabilized using Kirschner wires with the lateral ends bent over the retroacetabular area, and a buttress plate (3.5-mm reconstruction plate) was applied over the bent and cut hairpin loop of the Kirschner wires to secure the fixation (▶ **Fig. 3**). Intraoperative movements were assessed immediately after fixation, and the concentricity of the reduction was checked using diagnostic imaging techniques after dynamic stress testing under all views. All six hips were stable and reduced while the osteochondral fragments were also securely fixed throughout the complete range of motion of the hip.

Isometric quadriceps strengthening exercises were started immediately after the procedure. The patients were kept on toe-touch weight-bearing mobilization with a walker frame for about four weeks, followed by gradually-increasing weight-bearing as per tolerance approximately eight to ten weeks after surgery, depending on the degree of radiographic consolidation of the fracture. The clinical outcome was

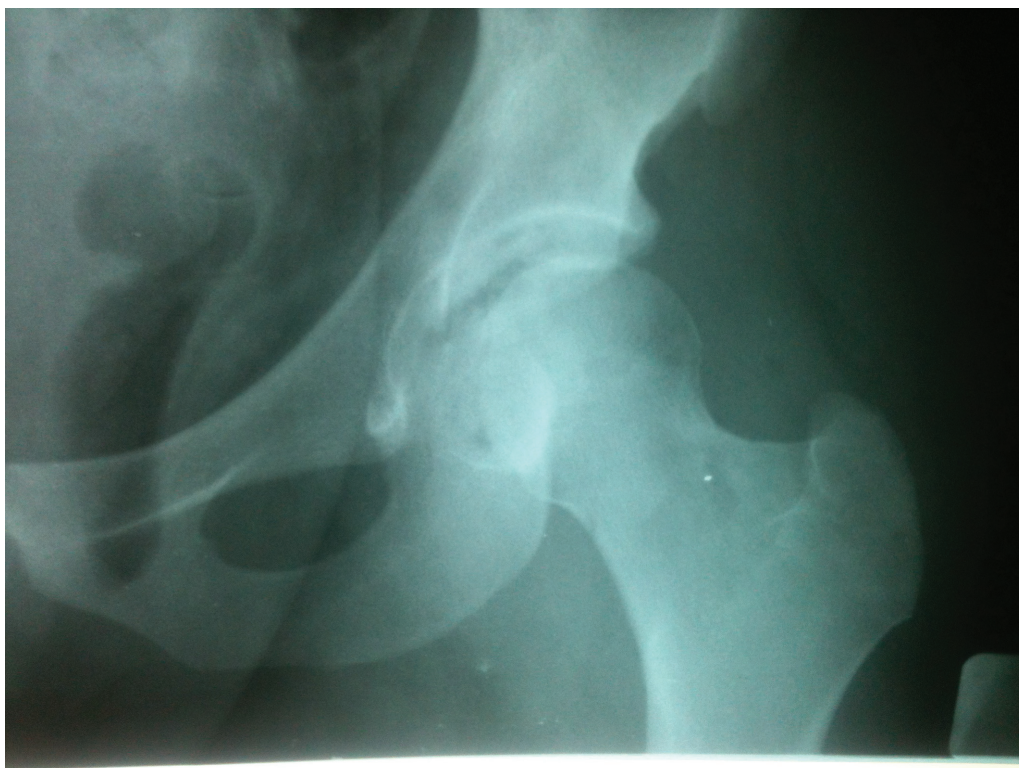

Fig. 1 Preoperative X ray of the left hip in anteroposterior (AP) view of a patient with posterior-wall small osteochondral avulsion after reduction of the hip dislocation.

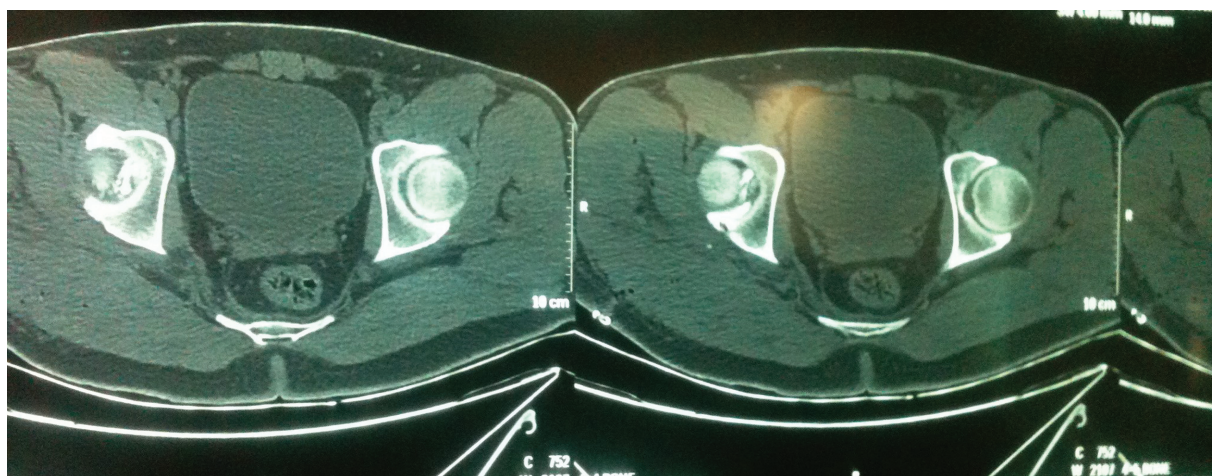


Fig. 2 Axial images of the preoperative computed tomography (CT) scan of the affected hip after reduction.

evaluated through the Harris Hip Score at 6 weeks, 3 months, 6 months, 1 year and at the final follow-up. The quality of the articular reduction and joint congruency were evaluated by postoperative plain radiographs using the Matta⁵ classification (anatomic/imperfect/poor) and supplemented with three-dimensional (3D) CT scans. The radiological evaluation at the final follow-up was performed based on the Matta⁵ criteria: excellent (hip joint with a normal appearance), good (mild changes with minimal sclerosis and joint narrowing < 1 mm), fair (intermediate changes with moderate sclerosis and joint narrowing < 50%), and poor (advanced osteoarthritis changes).

All patients were followed up for a minimum of 2 years (mean: 44 weeks; range: 24 to 66 weeks). There were no cases of surgical site infection, sciatic nerve injury, loss of reduction or non-union at the trochanteric osteotomy site. All acetabular fractures were united at the final follow-up, and the mean time until the union was of 6.4 (range: 4 to 10) months. The mean Harris Hip Score at the final follow-up was of 92.5 (range: 90.4 to 95.8). None of the patients developed features suggestive of hip AVN. The radiological outcome at the final follow-up was deemed excellent in four cases and good in two patients.

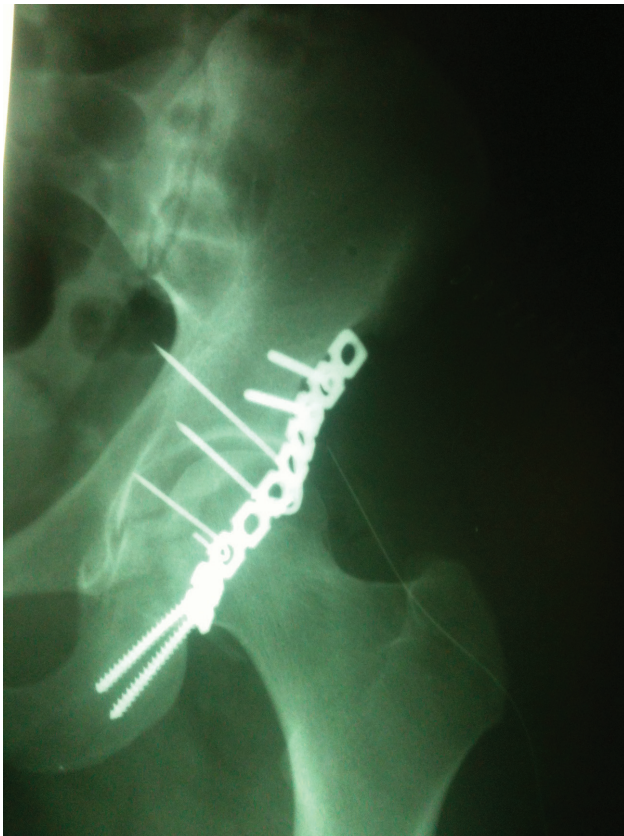


Fig. 3 Immediate postoperative hip X ray in AP view of the same patient.

Final Comments

Posterior dislocation of the hip with associated wall fracture is a common injury in high-energy RTAs. Persistent instability after reduction of the dislocation or fixation of the fracture should prompt physicians to look for any posterior osteolabral tears. Identification of a small acetabular “fleck sign” on hip radiographs in oblique view near the posterior wall, in the absence of any major acetabular fracture, is a marker of posterior labral avulsion, and it should be assessed thoroughly by stress testing using diagnostic imaging techniques to look for dynamic instability.⁶ The choice of method of fixation in avulsions with small bony fragments remains arguable due to the fact that the fragment is not amenable to fixation with anchors, screws or plates, and the lack of stability when fixation is performed with Kirschner wires

alone. In the present study, we described a novel technique to fix small osteochondral labral injuries using Kirschner wires and buttress plates over the bent wire ends. The buttress plates increased the stability of the Kirschner wire fixation and prevented pullout of the wires. The hips remained stable after fixation in the dynamic stress testing in the OT under imaging techniques and at all follow-ups. Our technique is a simple, cost-effective and reliable way to fix such avulsions with satisfactory outcomes.

Authors' Contributions

All authors contributed to the study conception and design. Material preparation, data collection and analysis were performed by AS, SG, and RK. The first draft of the manuscript was written by AS, and all authors commented on previous versions of the manuscript. All authors read and approved the final manuscript.

Financial Support

The authors declare that they have received no funding from agencies in the public, private or non-profit sectors for the conduction of the present study.

Conflict of Interests

The authors have no conflict of interests to declare.

References

- 1 Judet R, Judet J, Letournel E. Fractures of the acetabulum: classification and surgical approaches for open reduction. preliminary report. *J Bone Joint Surg Am* 1964;46:1615–1646
- 2 Brooks RA, Ribbans WJ. Diagnosis and imaging studies of traumatic hip dislocations in the adult. *Clin Orthop Relat Res* 2000; (377):15–23
- 3 Price CT, Pyevich MT, Knapp DR, Phillips JH, Hawker JJ. Traumatic hip dislocation with spontaneous incomplete reduction: a diagnostic trap. *J Orthop Trauma* 2002;16(10):730–735
- 4 Park MS, Yoon SJ, Choi SM. Hip Arthroscopic Management for Femoral Head Fractures and Posterior Acetabular Wall Fractures (Pipkin Type IV). *Arthrosc Tech* 2013;2(03):e221–e225
- 5 Matta JM. Fractures of the acetabulum: accuracy of reduction and clinical results in patients managed operatively within three weeks after the injury. *J Bone Joint Surg Am* 1996;78(11): 1632–1645
- 6 Blanchard C, Kushare I, Boyles A, Mundy A, Beebe AC, Klingele KE. Traumatic, Posterior Pediatric Hip Dislocations With Associated Posterior Labrum Osteochondral Avulsion: Recognizing the Acetabular “Fleck” Sign. *J Pediatr Orthop* 2016;36(06):602–607