



## Original article

Distal clavicle fractures in children<sup>☆</sup>

Pedro José Labronici<sup>a,\*</sup>, Ricardo Rodrigues da Silva Junior<sup>b</sup>,  
 Marcos Vinícius Viana Franco<sup>b</sup>, Gustavo José Labronici<sup>b</sup>,  
 Robinson Esteves Santos Pires<sup>c</sup>, José Sergio Franco<sup>d</sup>

<sup>a</sup> Universidade Federal Fluminense, Niterói, RJ, Brazil

<sup>b</sup> Serviço de Ortopedia e Traumatologia Prof. Dr. Donato D'Ângelo, Hospital Santa Teresa, Petrópolis, RJ, Brazil

<sup>c</sup> Universidade Federal de Minas Gerais, Belo Horizonte, MG, Brazil

<sup>d</sup> Faculdade de Medicina, Universidade Federal do Rio de Janeiro, Rio de Janeiro, RJ, Brazil

## ARTICLE INFO

## Article history:

Received 19 January 2015

Accepted 23 February 2015

Available online 29 December 2015

## Keywords:

Child

Fractures bone

Clavicle

## ABSTRACT

**Objective:** To analyze fractures of the distal clavicle region in pediatric patients.

**Methods:** Ten patients between the ages of five to eleven years (mean of 7.3 years) were observed. Nine patients were treated conservatively and one surgically. All the fractures were classified using the Nenopoulos classification system.

**Results:** All the fractures consolidated without complications. Conservative treatment was used for nine patients, of whom three were in group IIIB, three IIB, two IIA and one IV. The only patient who was treated surgically was a female patient of eleven years of age with a group IV fracture.

**Conclusion:** The treatment indication for distal fractures of the clavicle in children should be based on the patient's age and the displacement of the fragments.

© 2015 Sociedade Brasileira de Ortopedia e Traumatologia. Published by Elsevier Editora Ltda. All rights reserved.

## Fratura da região distal da clavícula em crianças

## RESUMO

**Objetivo:** Analisar as fraturas da região distal da clavícula em pacientes pediátricos.

**Métodos:** Foram observados dez pacientes entre cinco a 11 anos com média de 7,3 anos. Nove pacientes foram tratados conservadoramente e um cirurgicamente. As fraturas foram classificadas segundo a classificação de Nenopoulos.

**Resultados:** Todas as fraturas consolidaram sem complicações. O tratamento conservador foi usado em nove pacientes, três do grupo IIIB; três IIB; dois IIA e um IV. O único paciente

## Palavras-chave:

Crianças

Fraturas ósseas

Clavícula

<sup>☆</sup> Work performed in the Serviço de Ortopedia e Traumatologia Prof. Dr. Donato D'Ângelo, Hospital Santa Teresa and Faculdade de Medicina de Petrópolis, Petrópolis, RJ, Brazil.

\* Corresponding author.

E-mail: [plabronici@globocom](mailto:plabronici@globocom) (P.J. Labronici).

<http://dx.doi.org/10.1016/j.rboe.2015.12.006>

2255-4971/© 2015 Sociedade Brasileira de Ortopedia e Traumatologia. Published by Elsevier Editora Ltda. All rights reserved.

tratado cirurgicamente foi uma paciente do gênero feminino de 11 anos com fratura do grupo IV.

**Conclusão:** A indicação do tratamento para as fraturas distais da clavícula em crianças deve ser baseada na idade do paciente e no desvio dos fragmentos.

© 2015 Sociedade Brasileira de Ortopedia e Traumatologia. Publicado por Elsevier Editora Ltda. Todos os direitos reservados.

## Introduction

Fractures of the clavicle, especially those of the middle third, are very common among patients with an immature skeleton. However, they are rare injuries in the distal region, where they account for only 10–20% of all fractures of the clavicle.<sup>1,2</sup>

There are few studies in the literature with long follow-ups on cases of these injuries.<sup>3,4</sup> Fractures of the distal third of the clavicle are generally caused by direct trauma on the shoulder, and approximately 85% result from injuries during sports or recreational activities.<sup>2</sup> Given that the center of ossification of the distal epiphysis of the clavicle appears after the age of 18 years and the medial fragment of the clavicle may become

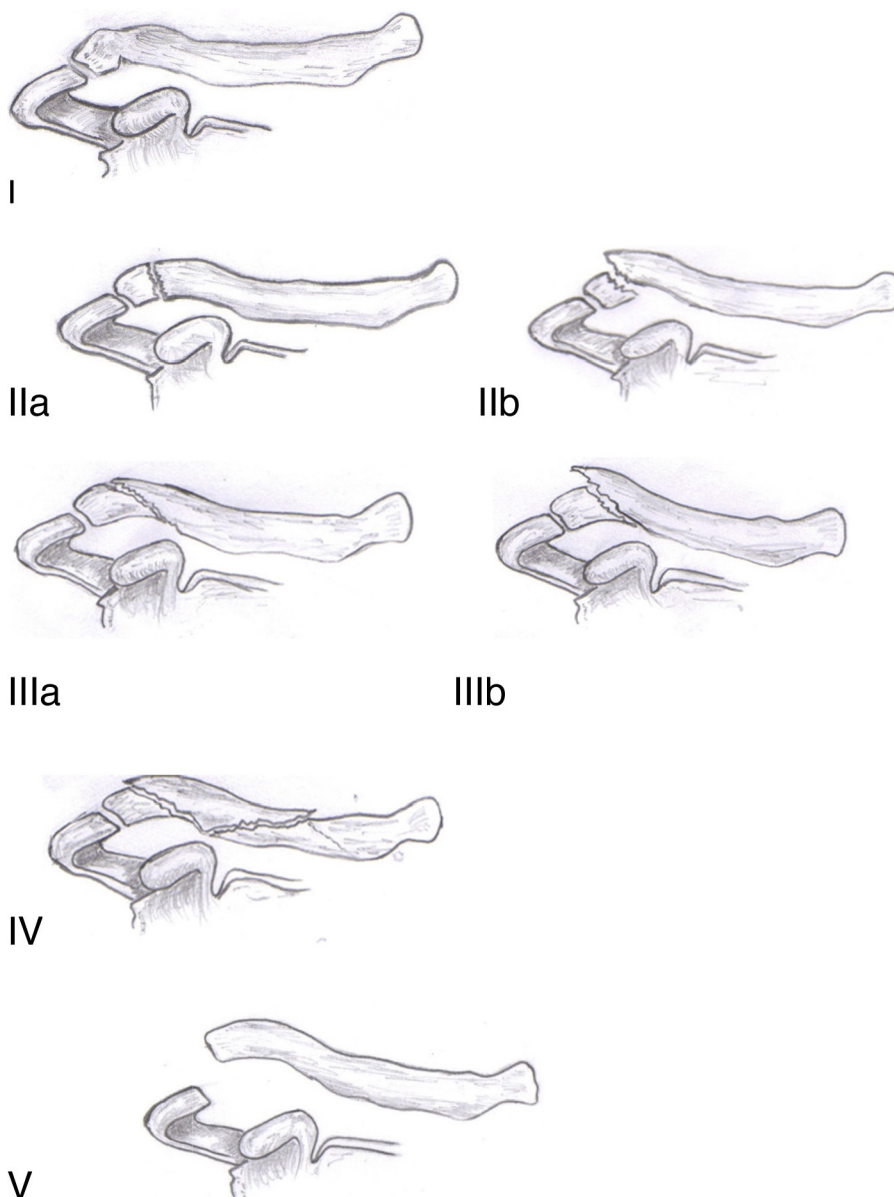


Fig. 1 – Classification scheme of Nenopoulos et al.<sup>5</sup>

avulsed from the periosteum (which both have great potential for remodeling), significant shoulder deformities may develop in children.<sup>3</sup>

Controversy continues to surround treatments for displaced fractures, although conservative treatment remains more commonly indicated at this age.<sup>1</sup> Under exceptional conditions, surgical stabilization may be necessary.

The objective of this study was to retrospectively analyze cases of fracturing of the distal region of the clavicle in pediatric patients.

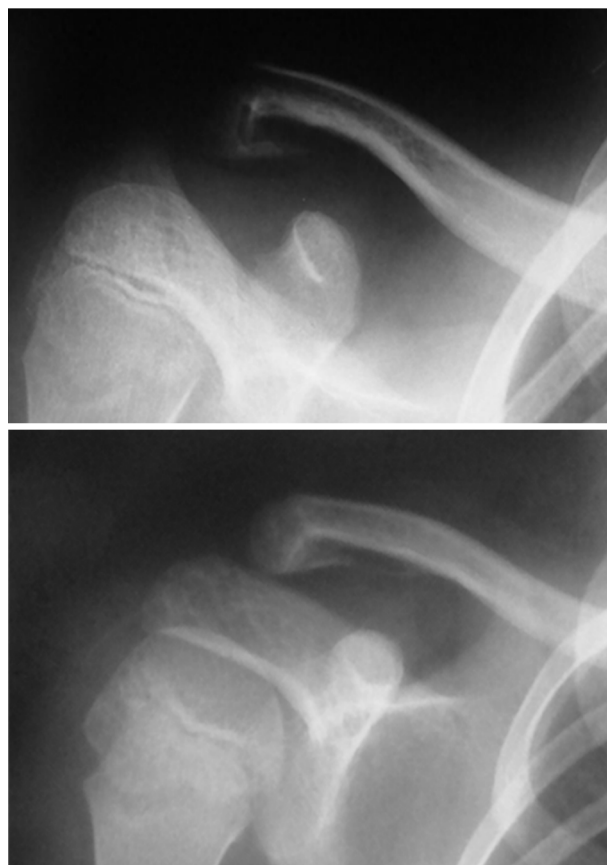## Material and method

The medical records and radiographs of 10 patients with fracturing of the distal region of the clavicle between January 2000 and December 2010 were analyzed. Their ages ranged from 5 to 11 years, with a mean of 7.3. Patients with obstetric trauma, previous fractures of the clavicle, congenital or infectious diseases of the shoulder and mistreatment were excluded. Six patients presented fractures on the right side and four on the left side. Seven patients were male and three were female. The causes of the accidents were: three cases of falling from a bicycle, three cases of simple falls, two cases of falls from a height and two cases of falls on stairs. The patients who were treated conservatively used a plaster cast covering the chest and arm for six weeks. One patient who was treated surgically underwent open reduction using internal fixation by means of a Kirschner wire between the acromion and clavicle, which was sufficient to provide stability, followed by use of a plaster cast covering the chest and arm for six weeks.

The fractures were classified from I to V as described by Nenopoulos et al.<sup>5</sup>: group I – greenstick fractures; group IIa – transverse fractures without displacement; group IIb – displaced transverse fractures; group IIIa – oblique fractures without displacement; group IIIb – displaced oblique fractures; group IV – comminuted fractures; and group V – acromioclavicular dislocation (Fig. 1).

## Results

All the patients were treated in our hospital. Conservative treatment was used in nine patients: three in group IIIb; three in IIb; two in IIa; and one in IV (Fig. 2). The only patient who was treated surgically was an 11-year-old female patient who

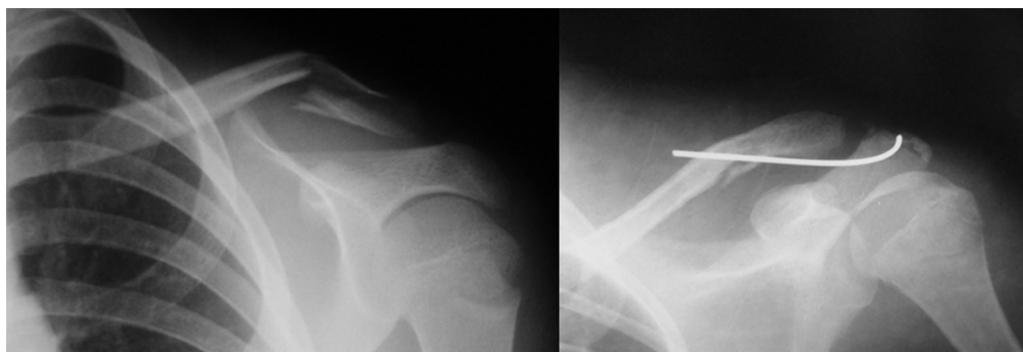


**Fig. 2 – Conservative treatment of distal fractures of the clavicle.**

presented a fracture in group IV and was treated with a Kirschner wire (Fig. 3). All of the fractures consolidated without complications (Table 1).

## Discussion

The worldwide literature relating to injuries to the acromioclavicular joint and fractures of the distal region of the clavicle in pediatric patients is of limited extent, with few cases or case reports.<sup>4,6-12</sup> Thus, we consider that it is of interest to demonstrate our sample with the aim of helping in making the diagnosis and indicating the treatment.



**Fig. 3 – Fracture of the distal third of the clavicle that was treated surgically.**

**Table 1 – Data on patients.**

	Age (years)	Gender	Side	Cause	Classification (group)	Treatment
1	8	Male	L	Fall from bicycle	IIIb	Conservative
2	7	Male	R	Fall from height	Ib	Conservative
3	9	Female	L	Fall	Ib	Conservative
4	7	Male	R	Fall from height	IV	Conservative
5	6	Female	L	Fall	IIIb	Conservative
6	8	Male	R	Fall from bicycle	Ib	Conservative
7	5	Male	R	Fall	Ia	Conservative
8	6	Male	R	Fall on stairs	IIIb	Conservative
9	11	Female	L	Fall from bicycle	IV	Surgical
10	6	Male	R	Fall on stairs	Ia	Conservative

Source: Hospital service files.

When the lateral region of the clavicle is affected, even in cases in which fractures with large displacements occur, the result from conservative treatment is satisfactory in most cases. This treatment may consist of figure-of-eight immobilization or use of a sling, and it provides adequate return of function. This is achieved because the lateral growth plate only closes after the age of 19 years has been reached and because the periosteum, which is thick and tube-shaped, linking to the coracoclavicular and acromioclavicular ligaments, helps in remodeling.<sup>8,12-14</sup>

Surgical treatment is only indicated in rare cases among children. Ogden<sup>12</sup> observed duplication of the clavicle after injuries to the distal epiphysis and suggested conservative treatment for this. However, when this was not possible, open reduction and fixation with Kirschner wires would be indicated, in order to prevent formation of a “double” clavicle. For the same reason, Lietchi<sup>15</sup> indicated open reduction and fixation with Kirschner wires, with periosteal suturing. Havránek<sup>9</sup> described the results from 10 boys with Salter type II injuries in the lateral region of the clavicle, and one of them underwent surgical treatment. Although limb functioning was not affected in any of the treatments indicated, this author observed that seven of these patients presented shoulder deformity and recommended that surgery should be performed for esthetic reasons when large displacements and shortening of the fragments were present. Nenopoulos et al.<sup>5</sup> observed that the functional results were excellent, independent of the treatment indicated and chosen. However, the patient’s age and degree of displacement are factors that should be taken into account in deciding on treatments that aim to achieve good esthetic results. Kubiak and Slongo<sup>11</sup> observed that surgical treatment of distal fractures of the clavicle in children is rare, while it is indicated among older children. The indications were as follows: exposed fractures; impact on soft tissues; risk of skin perforation; severe shortening of the scapular belt with or without intermediate displacement of the fragments; and displaced fractures with a potential risk of injury to structures of the neuromuscular bundle or mediastinum.

We had good functional results in all of our patients. In consonance with the guidance in the literature, only one 11-year-old female patient was treated surgically, comprising open reduction and fixation using Kirschner wires. In this case, there might have been a poor esthetic result because of the short time available for remodeling to take place. We

also believe that in cases of fractures with large displacement, magnetic resonance imaging may assist in indicating the type of treatment, since this makes it possible to assess the degree of detachment of the periosteum in this region.

## Conclusion

Distal fractures of the clavicle in children are rare. Most of these fractures can be treated conservatively. However, although this was a retrospective study with a small number of cases, it can be stated that the indication for treatment should be based on the patient’s age and on the displacement of the fragments.

## Conflicts of interest

The authors declare no conflicts of interest.

## REFERENCES

1. Sarwark JF, King EC, Luhmann SJ. Proximal humerus, scapula and clavicle. In: Rockwood CA Jr, Wilkins KE, editors. *Fractures in children*. 6th ed. Philadelphia: Lippincott, Williams & Wilkins; 2006. p. 724–8.
2. Shah RR, Kinder J, Peelman J, Moen TC, Sarwark J. Paediatric clavicle and acromioclavicular injuries. *J Pediatr Orthop*. 2010;30:S69–72.
3. Ogden JA. Chest and shoulder girdle. In: Ogden JA, editor. *Skeletal injury in the child*. 3rd ed. New York: Springer-Verlag; 2000. p. 438–41.
4. Black GB, McPherson JAM, Reed MH. Traumatic pseudodislocation of the acromioclavicular joint in children. A fifteen year review. *Am J Sports Med*. 1991;19(6):644–6.
5. Nenopoulos SP, Gigin IP, Chytas AA, Beslikas TA, Nenopoulos AS, Christoforidis JE. Outcome of distal clavicular fracture separations and dislocations in immature skeleton. *Injury*. 2011;42(4):376–80.
6. Dartou C, Fenoll B, Paule R, Le Nen D, Colin D, Thoma M. Particularités des fractures des extrémités de la clavicle chez l’enfant. *Acta Orthop Belg*. 1994;60(3):296–9.
7. Eidman DK, Sherwin JS, Tullos HS. Acromioclavicular lesions in children. *Am J Sports Med*. 1981;9(3):150–4.
8. Falstie-Jensen S, Mikkelsen P. Pseudodislocation of the acromioclavicular joint. *J Bone Joint Surg Br*. 1982;64(3):368–9.
9. Havránek P. Injuries of distal clavicular physis in children. *J Pediatr Orthop*. 1989;9(2):213–5.

10. Kirkos JM, Papavasiliou KA, Sarris IK, Kapetanos GA. A rare acromioclavicular joint injury in a twelve-year-old boy. *J Bone Joint Surg Am.* 2007;89(11):2504-7.
11. Kubiak R, Slongo T. Operative treatment of clavicle fractures in children: a review of 21 years. *J Pediatr Orthop.* 2002;22(6):736-9.
12. Ogden JA. Distal clavicular physeal injury. *Clin Orthop Relat Res.* 1984;(188):68-73.
13. Sanders JO, Rockwood CA, Curtis RJ. Fractures and dislocations of the humeral shaft and shoulder. In: Rockwood CA, Wilkins KE, Beaty JH, editors. *Fractures in children.* Philadelphia: Lippincott-Raven; 1996. p. 905-1019.
14. Wilkes JA, Hoffer MM. Clavicle fractures in head-injured children. *J Orthop Trauma.* 1987;1(1):55-8.
15. Liechti R. Frakturen der clavicula und der scapula. In: Weber BG, Brunner C, Freuler F, editors. *Die Frakturbehandlung bei Kindern und Jugendlichen.* Berlin: Springer-Verlag; 1978. p. 87-94.