



## Case Report

# Knee osteoarthritis secondary to ochronosis – clinical case <sup>☆,☆☆</sup>



Andreia Maria da Silva Martins Ferreira <sup>a,\*</sup>, Filipe Lima Santos <sup>a</sup>,  
André Miguel Castro Costa <sup>a</sup>, Bruno Miguel Pereira Barbosa <sup>b</sup>,  
Rui Miguel Reis Rocha <sup>a</sup>, Joaquim Fernando Fontes Lebre <sup>a</sup>

<sup>a</sup> Vila Nova de Gaia Hospital Center/Espinho Hospital, Vila Nova de Gaia and Espinho, Portugal

<sup>b</sup> Trás-os-Montes and Alto Douro Hospital Center, Vila Real, Portugal

### ARTICLE INFO

#### Article history:

Received 5 October 2013

Accepted 11 November 2013

Available online 27 October 2014

#### Keywords:

Alcaptonuria

Ochronosis

Knee

Arthroplasty

### ABSTRACT

Alcaptonuria is a rare metabolic disease in which a deficiency of the enzyme homogentisate dioxygenase causes an accumulation of homogentisic acid. Ochronosis consists of excessive deposition of homogentisic acid in the connective tissue and presents as a chestnut brown or black pigmentation. With aging, the accumulation of pigments from homogentisic acid in the joints causes osteoarthritis. There is no specific treatment for the disease and the approach is symptomatic. Arthroplasty is the solution for severe cases of osteoarthritis caused by this pathological condition and presents results comparable to those from patients with primary osteoarthritis. Here, the case of a 67-year-old patient who underwent several arthroplasty procedures because of osteoarthritis caused by this rare pathological condition is presented. The last surgical intervention consisted of total right knee arthroplasty.

© 2014 Sociedade Brasileira de Ortopedia e Traumatologia. Published by Elsevier Editora Ltda. All rights reserved.

### Palavras-chave:

Alcaptonúria

Ocronose

Joelho

Artroplastia

### Osteoartrose do joelho secundária a ocronose – Caso clínico

#### RESUMO

A alcaptonúria é uma doença metabólica rara em que a deficiência da enzima ácido homogentísico-oxidase provoca uma acumulação de ácido homogentísico. A ocronose consiste na deposição excessiva de ácido homogentísico no tecido conjuntivo e apresenta-se como uma pigmentação acastanhada ou preta. Com o envelhecimento, a acumulação de pigmentos de ácido homogentísico nas articulações provoca osteoartrose. Não existe um tratamento específico para a doença e a abordagem é sintomática. A artroplastia é a solução

\* Please cite this article as: da Silva Martins Ferreira AM, Lima Santos F, Castro Costa AM, Pereira Barbosa BM, Reis Rocha RM, Fontes Lebre JF. Osteoartrose do joelho secundária a ocronose – Caso clínico. Rev Bras Ortop. 2014;49:675-680.

☆☆ Work developed in the Vila Nova de Gaia Hospital Center, Vila Nova de Gaia, Portugal, and Espinho Hospital, Espinho, Portugal.

\* Corresponding author.

E-mail: [andreiamsmf@gmail.com](mailto:andreiamsmf@gmail.com) (A.M. da Silva Martins Ferreira).

<http://dx.doi.org/10.1016/j.rboe.2013.11.001>

2255-4971/© 2014 Sociedade Brasileira de Ortopedia e Traumatologia. Published by Elsevier Editora Ltda. All rights reserved.

para casos graves de osteoartrose causada por essa patologia e apresenta resultados comparáveis aos doentes com osteoartrose primária. Os autores apresentam o caso de um doente de 67 anos submetido a várias artroplastias, em virtude da osteoartrose causada por essa rara patologia. A última intervenção cirúrgica foi uma artroplastia total do joelho direito.

© 2014 Sociedade Brasileira de Ortopedia e Traumatologia. Publicado por Elsevier Editora Ltda. Todos os direitos reservados.

## Introduction

Alkaptonuria is a rare recessive autosomal metabolic disease caused by absence of the enzyme homogentisic oxidase. This enzyme is responsible for degradation of homogentisic acid, which is an intermediate product from metabolism of the amino acids tyrosine and phenylalanine. If this enzyme is defective, this leads to accumulation of homogentisic acid in tissues and blood.

The incidence of alkaptonuria is less than one in one million.<sup>1</sup>

Over time, the deposits of homogentisic acid accumulate in the tissues and present as a dark pigmentation. This condition is called ochronosis and it may affect not only the musculoskeletal system but also the cardiovascular and genitourinary systems, the sclera and the skin.<sup>2,3</sup>

Most of the symptoms of alkaptonuria are only observed starting in the fourth or fifth decade of life,<sup>4</sup> except for the appearance of dark urine, which is detected during childhood, resulting from excretion and oxidation of homogentisic acid.

Alkaptonuria causes progressive ochronotic arthropathy of the major joints that are subject to weight-bearing. The

knee is the joint that is most affected, followed by the hip.<sup>4-6</sup>

The treatment for the disease is symptomatic and total arthroplasty is the preferred treatment in severe cases of osteoarthritis.<sup>7,8</sup>

## Clinical case

The patient was a 67-year-old man whose diagnosis of alkaptonuria had been made at the age of 40 years. The first signs of the disease were darkening of the urine and appearance of dark pigments in the sclera, ears and first interdigital crease of the left hand (Fig. 1A-D). There were no other relevant antecedents or any family history of the disease.

At the age of 60 years, the patient underwent a surgical intervention to extract a bladder stone of large dimensions (Fig. 2).

Joint complaints arose some years later and initially affected the left hip, followed by the left knee and lastly the right knee.

The patient was referred for an orthopedics consultation and the first surgical intervention was total arthroplasty of the

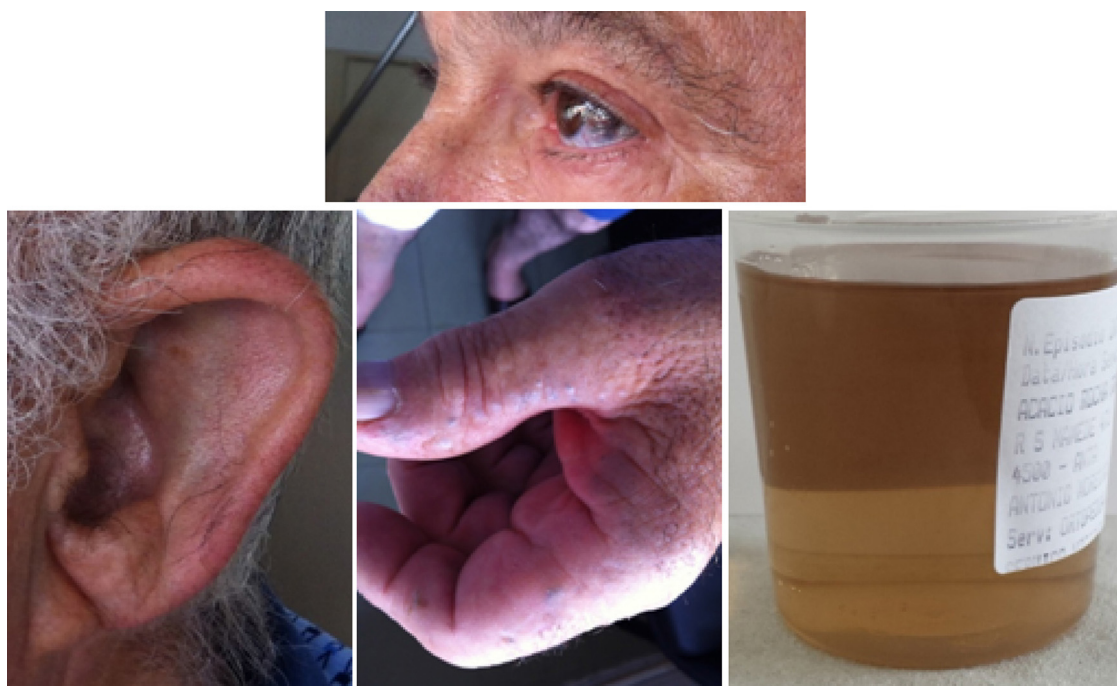

Fig. 1 – Dark pigment in the sclera, ears and first interdigital crease of the left hand. The last figure demonstrates the darkened appearance of the urine.



**Fig. 2 – Bladder stone.**

left hip, performed five years before the present case (Fig. 3A and B).

Twelve months before the present case, the patient underwent total arthroplasty of the left knee (Fig. 4A–C). Both of these surgical procedures were performed at another hospital institution. So far, there have not been any mentions of postoperative complications.

At the consultation of the present case, the patient presented complaints of pain in his right knee, with a varus knee and radiologically observed three-compartment gonarthrosis of Ahlbäck grade IV (Fig. 4A and B).

The patient underwent total arthroplasty of the right knee (Fig. 5A and B) at our hospital. The complaints of pain improved immediately after the operation.

After six months of follow-up, the patient is now asymptomatic and able to walk without gait supports. His mobility is from 0° to 110° in the right knee and 0° to 120° in the left knee. He continues to be followed up as an outpatient.

## Discussion

Alkaptonuria was first described in 1584, in children with dark urine.

At the end of the 1990s, it was observed that the gene for this pathological condition was present at the locus 3q21-23.<sup>9</sup>

Ochronosis consists of deposition of pigments from homogentisic acid in all types of connective tissue and particularly in cartilage. It mainly affects the musculoskeletal system, but can also affect the cardiovascular and genitourinary systems, the sclera and the skin.<sup>2,3</sup>

The first clinical manifestation of alkaptonuria is the appearance of dark urine.<sup>10</sup> Other alterations that are often neglected include changes to the color of the sclera and ears. These signs could also be identified in our patient.

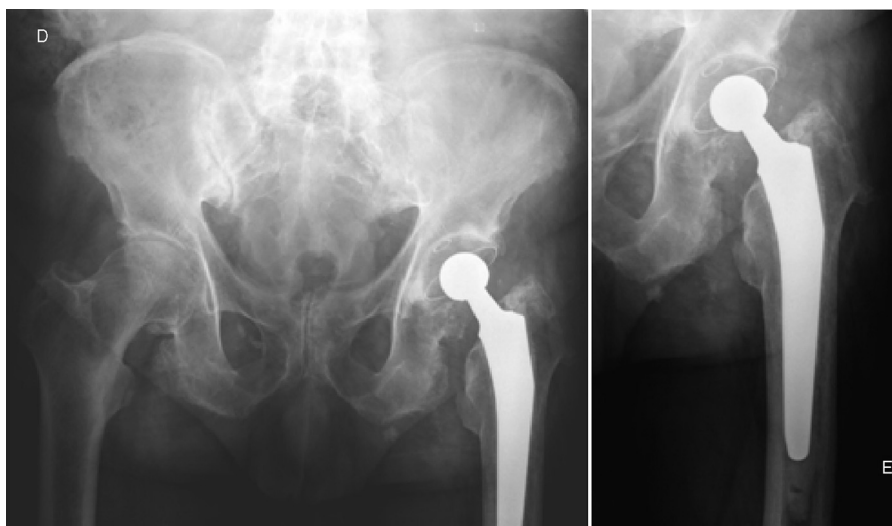
Ochronotic arthropathy fundamentally affects individuals from the age of 40 years onwards, as seen in the case presented here. The pain complaints affect the major joints and especially the knees, followed by the hips, shoulders, spine and even the ribs.<sup>11</sup> In our case, the first joint to be affected was the left hip.

The pigmentation also affects the tendons and ligaments, because of their high collagen content, and it causes inflammatory alterations that may lead to tearing.<sup>7</sup>

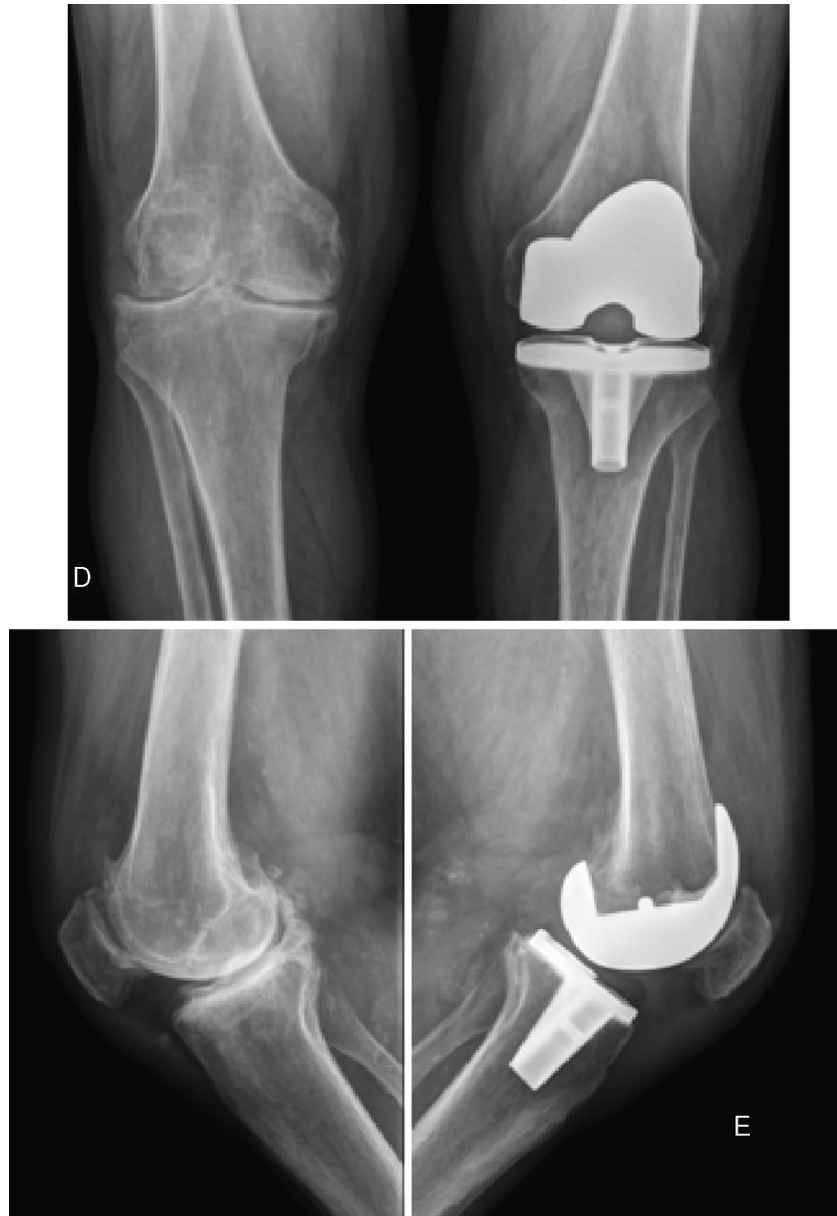Like in patients with primary osteoarthritis, narrowing of the interline and sclerosis of the joint space are frequently seen. However, the radiological alterations may be much less exuberant than the clinical manifestations.

Macroscopically, patients affected by ochronosis present small particles resembling soot, encrusted in the menisci, tendons and ligaments, which confers the typical dark coloration of the joints. This could be seen in the intraoperative images of the present case (Fig. 6A–C). The anatomopathological examination on the operative specimens confirmed the diagnosis.

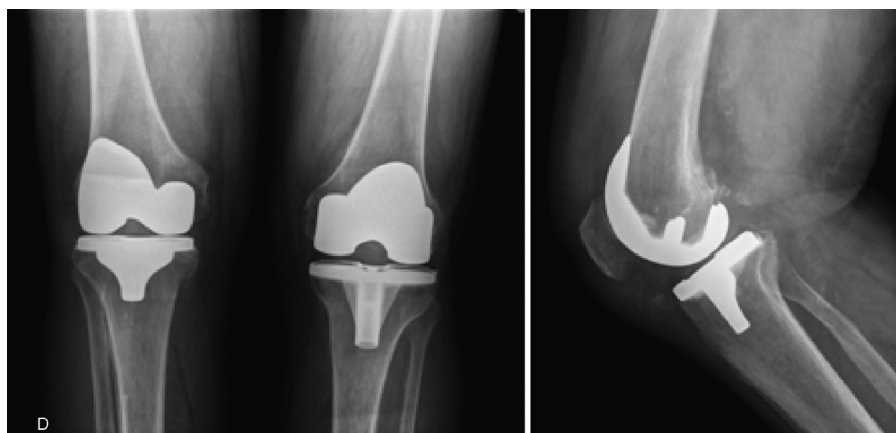
There is no specific medical treatment for alkaptonuria and therefore the therapeutic approach is symptomatic. In



**Fig. 3 – Cemented total hip arthroplasty performed five years before the present case.**

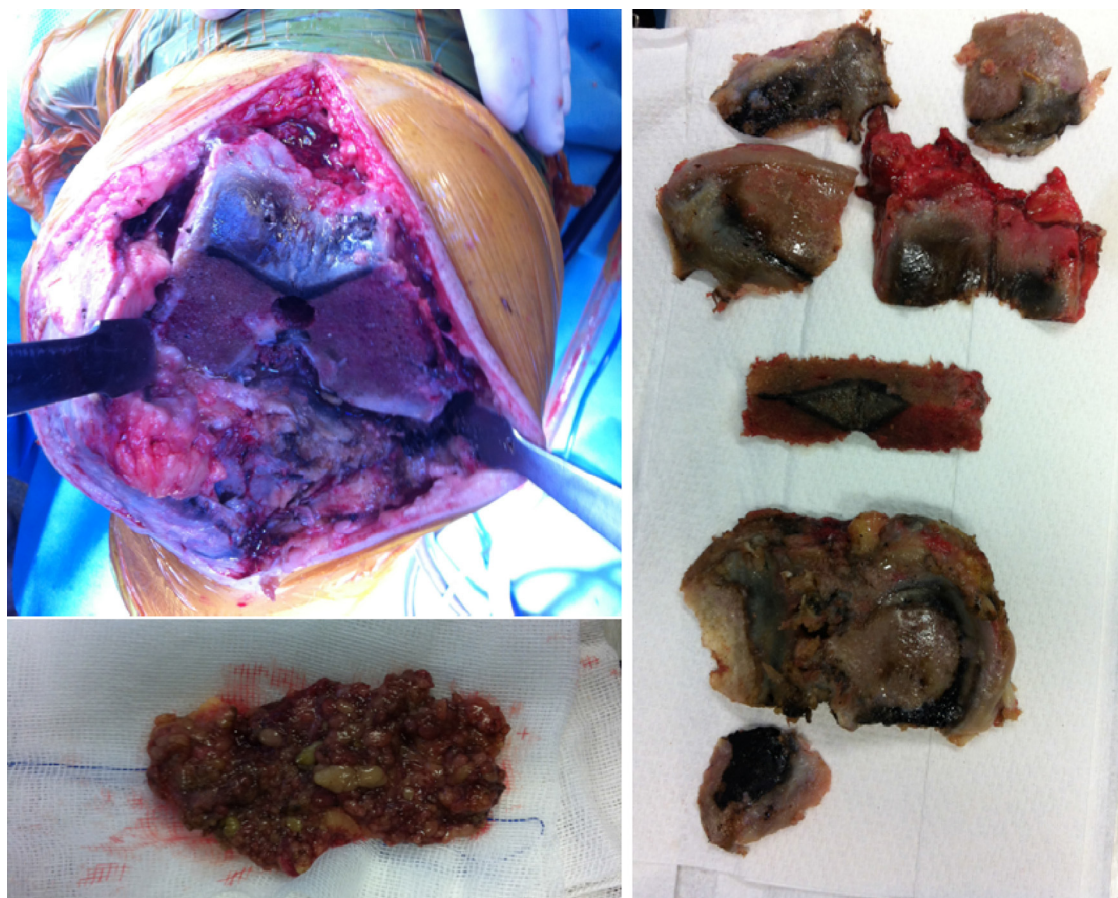


**Fig. 4 – Total arthroplasty of the left knee performed 12 months before the present case. Right knee with three-compartment gonarthrosis of Ahlbäck grade IV.**



**Fig. 5 – Radiograph of the knees with weight-bearing and lateral view of the right knee six months after total arthroplasty.**





**Fig. 6 – Intraoperative images documenting the typical dark coloration of the joint that resulted from deposition of pigments from homogentisic acid in the joint cartilage, menisci, tendons and ligaments.**

severe cases of osteoarthritis, total arthroplasty is the preferred treatment.<sup>7,8</sup>

Few studies have reported the mechanical differences that may occur in the bone and soft tissues of patients who undergo arthroplasty, or the complications during the operation or postoperative follow-up.

In patients undergoing total knee arthroplasty, Spencer et al.<sup>12</sup> were faced with intraoperative difficulties in displacing the patella, because the quadriceps and patellar tendons were extremely hard. Although we did not have this difficulty, we observed during the operation that both the hips presented an unusually hard consistency.

In the same study, no complications relating to implant failure were detected in patients with ochronosis who underwent total arthroplasty on different joints, with 12 years of follow-up. Other studies have presented results compatible with performing arthroplasty in patients with primary osteoarthritis.<sup>13-15</sup>

Early treatment for alkaptonuria may be a challenge, given that the approach is symptomatic.

Cases of ochronotic arthropathy that are more advanced require surgical treatment.

As already reported total knee arthroplasty presents good results in patients with gonarthrosis secondary to this rare pathological condition.

### Conflict of interest

The authors declare no conflicts of interest.

### REFERENCES

1. Smith RJ. Disorders of amino acid metabolism. In: Humes HD, editor. Kelley's textbook of internal medicine. 4th ed. Philadelphia: Lippincott Williams & Wilkins; 2000. p. 2788-93.
2. Nas K, Gür A, Akdeniz S, Cevik R, Harman M, Saraç AJ. Ochronosis: a case of severe ochronotic arthropathy. Clin Rheumatol. 2002;21(2):170-2.
3. Wauthy P, Seghers V, Mathonet P, Deuvaert FE. Cardiac ochronosis: not so benign. Eur J Cardiothorac Surg. 2009;35(4):732-3.
4. Gaines JJ Jr. The pathology of alkaptonuric ochronosis. Hum Pathol. 1989;20(1):40-6.
5. Albers SE, Brozena SJ, Glass LF, Fenske NA. Alkaptonuria and ochronosis: case report and review. J Am Acad Dermatol. 1992;27(4):609-14.
6. La Du BN Jr. Alkaptonuria and ochronotic arthritis. Mol Biol Med. 1991;8(1):31-8.
7. Mannoni A, Selvi E, Lorenzini S, Giorgi M, Airó P, Cammelli D, et al. Alkaptonuria, ochronosis, and ochronotic arthropathy. Semin Arthritis Rheum. 2004;33(4):239-48.

8. Borman P, Bodur H, Ciliz D. Ciliz Ochronoticarthritis. *Rheumatol Int.* 2002;21(5):205-9.
9. Fernández-Cañón JM, Granadino B, Beltrán-Valero de Bernabé D, Renedo M, Fernández-Ruiz E, Peñalva MA, et al. The molecular basis of alkaptonuria. *Nat Genet.* 1996;14(1):19-24.
10. Resnick D. Alkaptonuria. In: Resnick D, Niwayama G, editors. *Diagnosis of bone and joint disorders.* 2nd ed. Philadelphia: Saunders; 1988. p. 1787-803.
11. O'Brien W, La Du BN, Bunim JJ. Biochemical, pathologic and clinical aspects of alcaptonuria, ochronosis, and ochronoticarthritis. *Am J Med.* 1963;34:813-38.
12. Spencer JM, Gibbons CL, Sharp RJ, Carr AJ, Athanasou NA. Arthroplasty for ochronotic arthritis: no failure of 11 replacements in 3 patients followed 6-12 years. *Acta Orthop Scand.* 2004;75(3):355-8.
13. Aydogdu S, Cullu E, Ozsoy MH, Sur H. Cementless total knee arthroplasty in ochronoticarthritis: a case report with a 4-year follow-up. *J Arthroplasty.* 2000;15(4):539-43.
14. Moslavac A, Moslavac S, Cop R. Case report of a patient with ochronosis and arthroplasty of the hip and both knees. *Reumatizam.* 2003;50(1):26-8.
15. Carrier DA, Harris CM. Bilateral hip and bilateral knee arthroplasties in a patient with ochronoticarthritis. *Orthop Rev.* 1990;19(11):1005-9.