

Preoperative Prediction of Gartland IV Supracondylar Fractures of Humerus: Is it Possible?*

Previsão pré-operatória de fraturas supracondilares de úmero Gartland IV: É possível?

Sitanshu Barik¹ Gobinder Singh¹ Subhajit Maji¹ Md Quamar Azam² Vivek Singh¹

¹ Department of Orthopedics, All India Institute of Medical Sciences, Rishikesh, India

² Department of Trauma Surgery, All India Institute of Medical Sciences, Rishikesh, India

Address for correspondence Gobinder Singh, M.B.B.S., Junior Resident, Orthopedics, Room 84219, Building 84, AIIMS Rishikesh, Dehradun, Uttarakhand, India (e-mail: gobindergs@gmail.com).

Rev Bras Ortop 2021;56(2):230–234.

Abstract

Objectives The present study aims to identify preoperative characteristics of the patient, of the injury, as well as of imaging, which would point towards a type IV fracture. The present study shall help the operating team to predict more accurately the type IV pattern preoperatively, leading to improved counselling of the caregivers, planning of surgery, as well as preparedness regarding open reduction, if such situation arises.

Methods A retrospective study was conducted, including patients that met the following criteria: 1) age < 16 years old; 2) Gartland type-III and type-IV supracondylar fractures; and 3) with complete records. Demographic data like age, gender, laterality, mode of injury, hospital duration of the injury, history of previous attempts of closed reduction, open/closed fracture, distal neurovascular status, and radiographic data like angulation, translation, osseous apposition and fracture comminution were collected.

Results Hospital duration of the injury and previous attempts of closed reduction were the factors that had a statistically significant difference among types III and IV fractures ($p < 0.05$). A diagnosis of type IV supracondylar fractures was significantly more likely in the presence of valgus angulation of the distal fragment $\geq 17^\circ$ (odds ratio [OR] = 20.22; 95% confidence interval [CI] = 3.45–118.65). Flexion angulation $\geq 10^\circ$ (OR = 5.32; 95% CI = 0.24–119.88) of the distal fragment predicted Gartland type IV with a sensitivity of 41% and a specificity of 100%.

Conclusion The preoperative evaluation of suspected Gartland IV fractures can help the operating surgeon in predicting such injuries. Nonradiographic factors like increased hospital duration of the injury, attempts at previously closed reduction,

Keywords

- ▶ humeral fractures
- ▶ child
- ▶ elbow joint
- ▶ fracture fixation

* Work developed at All India Institute of Medical Sciences, Rishikesh, India.

received
April 28, 2020
accepted
September 17, 2020

DOI <https://doi.org/10.1055/s-0040-1722578>.
ISSN 0102-3616.

© 2021. Sociedade Brasileira de Ortopedia e Traumatologia. All rights reserved.

This is an open access article published by Thieme under the terms of the Creative Commons Attribution-NonDerivative-NonCommercial-License, permitting copying and reproduction so long as the original work is given appropriate credit. Contents may not be used for commercial purposes, or adapted, remixed, transformed or built upon. (<https://creativecommons.org/licenses/by-nc-nd/4.0/>)

Thieme Revinter Publicações Ltda., Rua do Matoso 170, Rio de Janeiro, RJ, CEP 20270-135, Brazil

and radiographic parameters like valgus and flexion angulation were more likely to be associated with type IV fractures. Level of evidence III.

Resumo

Objetivos O presente estudo tem como objetivo identificar características pré-operatórias do paciente e da lesão, bem como da imagem que apontaria para uma fratura tipo IV. O presente estudo ajudará a equipe operacional a prever com mais precisão o padrão tipo IV pré-operatório, levando a um melhor aconselhamento dos cuidadores e planejamento da cirurgia, bem como a uma melhor preparação em relação à redução aberta, se tal situação surgir.

Métodos Um estudo retrospectivo foi realizado, incluindo pacientes que atendiam os seguintes critérios: 1) idade < 16 anos; 2) fraturas supracondilares Gartland tipos III e IV; e 3) com registros completos. Foram coletados dados demográficos como idade, gênero, lateralidade, modo de lesão, duração hospitalar de lesão, histórico de tentativas anteriores de redução fechada, fratura aberta/fechada, estado neurovascular distal e dados radiográficos como angulação, translação, aposição óssea e cominação de fratura.

Resultados A duração hospitalar de lesões e as tentativas anteriores de redução fechada foram os fatores com diferença estatisticamente significativa entre as fraturas tipo III e IV ($p < 0,05$). O diagnóstico de fraturas supracondilares tipo IV foi significativamente mais provável na presença de angulação em valgo de fragmento distal $\geq 17^\circ$ (odds ratio [OR] = 20,22; intervalo de confiança [IC] 95% = 3,45–118,65). A angulação de flexão $\geq 10^\circ$ (OR = 5,32; IC95% = 0,24–119,88) do fragmento distal previram Gartland tipo IV com sensibilidade de 41% e especificidade de 100%.

Conclusão A avaliação pré-operatória de suspeitas de fraturas de Gartland IV pode ajudar o cirurgião operacional a prever tais lesões. Fatores não radiográficos, como o aumento da duração da lesão hospitalar, tentativas de redução previamente fechada e parâmetros radiográficos como valgo e angulação de flexão foram mais propensos a estarem associados a fraturas tipo IV. Nível de evidência III.

Palavras-chave

- ▶ fraturas do úmero
- ▶ criança
- ▶ articulação do cotovelo
- ▶ fixação de fratura

Introduction

Supracondylar fractures are one of the common fractures around the pediatric elbow. They comprise about two-thirds of all pediatric trauma around the elbow requiring hospitalization, with an estimated incidence of 177.3 per 100000 children.¹ It is commonly noted in boys in the age range between 5 and 8 years old, with the nondominant arm being commonly involved.² The most frequently used system to classify these fractures is the Gartland classification, which has a good interobserver and intraobserver concordance.³ Leitch introduced a type IV to the Gartland classification, in which the anterior and posterior periosteum are completely torn off, leading to instability both in flexion and extension.⁴ These types of fractures are assumed to be diagnosable only intraoperatively.^{1,5}

Although closed reduction and percutaneous pinning (CRPP) is the common modality of treatment for both type III and IV Gartland fractures, reduction in type IV cases may be difficult due to the inherent multidirectional instability. Type IV fractures may need more commonly an open reduction and percutaneous pinning (ORPP) when compared with type III fractures.⁵ There is scant literature regarding the

diagnosis and optimum treatment of type IV fractures. The present study aims to identify preoperative characteristics of the patient, of the injury, as well as of imaging that would point towards a type IV fracture. The present study shall help the operating team to predict more accurately the type IV pattern preoperatively, leading to improved counselling of the caregivers, planning of surgery, as well as preparedness regarding open reduction, if such situation arises.

Material and Methods

After obtaining institutional ethics committee approval for a retrospective observational study, the patient database for cases that presented to the orthopedics department for the treatment of supracondylar fractures was acquired from January 2016 to December 2019. Patients who were included in the study met the following criteria: 1) age < 16 years old; 2) Gartland type-III and type-IV supracondylar fractures; and 3) with complete records. Patients with 1) another concomitant injury in the same limb; 2) history of previous elbow trauma; 3) suspected skeletal dysplasia; and 4) incomplete records were excluded from the study.

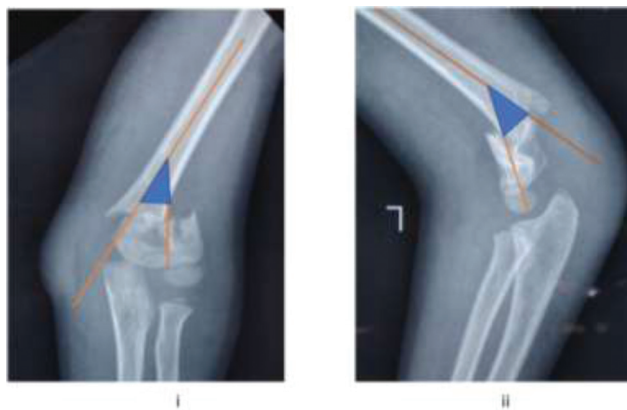

Fig. 1 (i, ii). Depiction of angulation in the coronal (i) and sagittal planes (ii) by lines along the mid diaphysis of the proximal fragment and a line perpendicular to the elbow joint in the distal fragment.

Age, gender, laterality, mode of injury, injury hospital duration, history of previous attempts of closed reduction, open/closed fracture, and distal neurovascular status were determined by reviewing the medical records.

Preoperative radiographs were evaluated to assess the following parameters: 1) angulation of the distal fragment in the sagittal plane; 2) angulation of the distal fragment in the coronal plane (**Fig. 1**); 3) translation of the distal fragment in the coronal plane; 4) translation of the distal fragment in the sagittal plane (**Fig. 2**); 5) osseous apposition between the proximal and distal fragments on the anteroposterior plane; 6) osseous apposition between the proximal and distal fragments on lateral radiographs (**Fig. 2**); and 7) fracture comminution. Operative notes were scrutinized to determine the Gartland type of supracondylar fractures.

Data were analyzed using chi-squared tests or Fisher exact tests for categorical variables and the sample t-test for continuous variables. Odds ratios (ORs) were estimated and reported with associated 95% confidence intervals (CIs). ROC curves were exploited for comparison of the diagnostic performance of various radiographic parameters

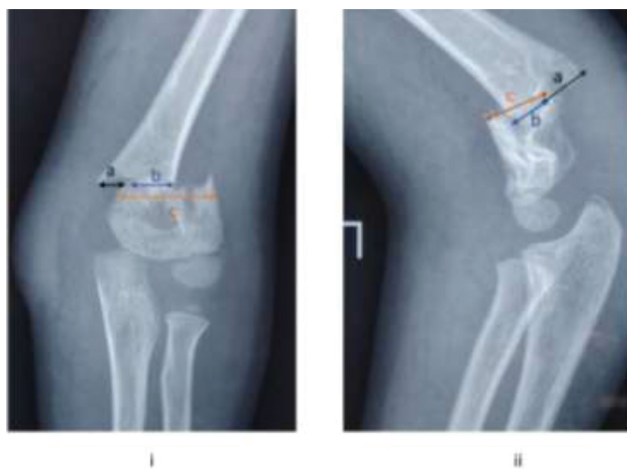

Fig. 2 (i, ii). Depiction of translation and osseous apposition in the coronal (i) and sagittal planes (ii). Translation = a/c . Osseous apposition = b/c .

in predicting Gartland type-IV fractures. Data analysis was performed using IBM SPSS Statistics for Windows, version 24.0 (IBM Corp., Armonk, NY, USA).

Results

Thirty-three patients (25 males, 8 females) who met the study criteria were included in the present study, with a mean age of 8.7 ± 3.1 years old (**Table 1**). Injuries during sports practice and resulting from fall from height were the most common modes of injury. The fracture was closed in 96.9% ($n = 32$) of the cases. Among the patients included in the present study, 16 were Gartland III, and 17 were Gartland type IV.

Injury hospital duration and previous attempts of closed reduction were the factors having a statistically significant difference among types III and IV fractures (**Table 1**). The mean injury hospital duration in type-III supracondylar fracture was 31.25 ± 43.09 hours, whereas in type-IV it was 52.59 ± 45.47 hours. A history of previous attempts of closed reduction was present in 11 patients (64.7%) with type IV supracondylar fractures, whereas it was present in 4 (25%) patients with type III fractures. Other demographic factors like age, gender, laterality, open/closed fracture, and

Table 1 Association between Gartland Type and Parameters

Parameters	Gartland Type		p-value
	Type 3 (n = 16)	Type 4 (n = 17)	
Age (years old)	8.62 ± 2.60	8.88 ± 3.69	0.818 ^a
Gender			1.000 ^b
Male	12 (75.0%)	13 (76.5%)	
Female	4 (25.0%)	4 (23.5%)	
Mode of Injury			0.071 ^b
Fall from height	9 (56.2%)	6 (35.3%)	
Injury While practicing sports	5 (31.2%)	11 (64.7%)	
Road traffic accident	2 (12.5%)	0 (0.0%)	
Injury-Hospital Interval (hours)***	31.25 ± 43.09	52.59 ± 45.47	0.029 ^c
Laterality			0.392 ^d
Right	9 (56.2%)	12 (70.6%)	
Left	7 (43.8%)	5 (29.4%)	
Previous Attempts at Closed Reduction (present)***	4 (25.0%)	11 (64.7%)	0.022 ^d
Type of Fracture			0.485 ^b
Closed	15 (93.8%)	17 (100.0%)	
Open	1 (6.2%)	0 (0.0%)	
DNVS			0.335 ^b
Intact	13 (81.2%)	16 (94.1%)	
Involved	3 (18.8%)	1 (5.9%)	

***Significant at $p < 0.05$, ^a: t-test, ^b: Fisher exact test, ^c: Wilcoxon test, ^d: Chi-squared test. DNVS, Distal neurovascular status.

Table 2 Comparison of the Diagnostic Performance of Various Radiographic parameters in Predicting Gartland Type 4 versus Gartland Type 3

Predictor	Odds ratio (95% CI)	AUROC (95% CI)	p-value	Sn	Sp	PPV	NPV
Angulation (sagittal plane) (degrees of extension)	5.32 (0.24–119.88)	0.557 (0.343–0.771)	0.587	41%	100%	100%	62%
Angulation (coronal plane) (degrees of valgus)	20.22 (3.45–118.65)	0.868 (0.741–0.994)	< 0.001	88%	81%	83%	87%
Translation (coronal plane) (%)	0.94 (0.02–50.32)	0.557 (0.344–0.77)	0.588	71%	69%	71%	69%
Translation (sagittal plane) (%)	3.14 (0.75–13.16)	0.515 (0.316–0.714)	0.897	41%	69%	58%	52%
Osseous apposition (%)	3.14 (0.75–13.16)	0.557 (0.344–0.77)	0.588	71%	69%	71%	69%
Osseous apposition (Lateral) (%)	0.94 (0.02–50.32)	0.515 (0.316–0.714)	0.897	41%	69%	58%	52%

Abbreviations: AUROC, area under ROC curve; CI, confidence interval; DA, diagnostic accuracy; NPV, negative predictive value; PPV, positive predictive value; Sn, sensitivity; Sp, specificity.

distal neurovascular status were not statistically significant in differentiating types III and IV fractures.

A total of 33 preoperative radiographs were analyzed, and a diagnosis of type IV supracondylar fractures was significantly more likely in the presence of valgus angulation of distal fragment $\geq 17^\circ$ (OR = 20.22; 95%CI = 3.45–118.65), with a sensitivity of 88%, and a specificity of 81% (►Table 2, ►Fig. 3). Flexion angulation $\geq 10^\circ$ (OR = 5.32; 95%CI = 0.24–119.88) of the distal fragment predicted Gartland type IV with a sensitivity of 41% and a specificity of 100%. There was no significant association with fracture comminution, translation of the distal fragment over the proximal fragment in both planes and osseous apposition between the fracture fragments in both planes in predicting type IV supracondylar fractures on preoperative radiographs (►Table 2, ►Fig. 3).

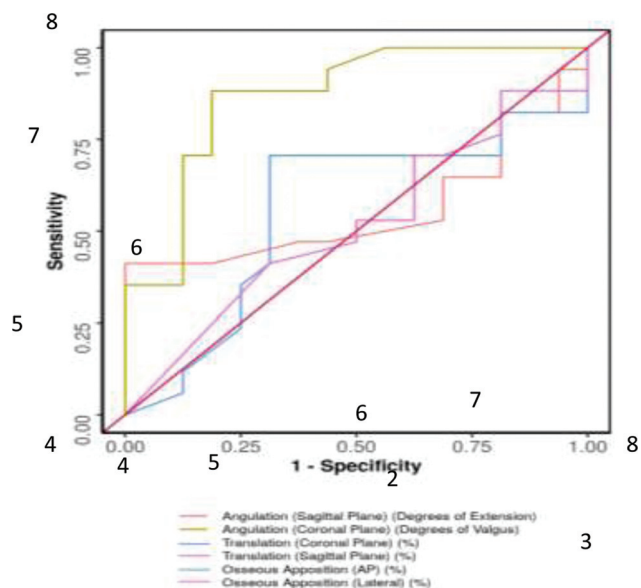
Discussion

The multidirectionally unstable type of supracondylar fracture was first described by Leitch in 2006.⁴ These fractures do

not have any periosteal hinge, and the distal fragment is unstable in both flexion and extension. This type of fracture was renamed as Gartland type IV by the authors. The incidence of these fractures varies from 7 to 10% of all operated supracondylar fractures.⁴ From the pool of unstable operated fractures included in the present study, ~ 50% ($n = 17$) were of type IV. The diagnosis of this type of fracture is possible intraoperatively, and the intrarater and inter-rater reliabilities remain undetermined. This instability may also be exaggerated during reduction attempts, and it further confounds the actual rate of occurrence.⁴ Ultimately, the diagnosis of type IV fracture is extremely subjective and depends on the operating surgeon.

The present study noted a significant difference in injury hospital duration and previous attempts of closed reduction in predicting type IV fracture from type III fracture. The mean injury hospital duration in type-III supracondylar fracture was 31.25 ± 43.09 hours, whereas in type-IV it was 52.59 ± 45.47 hours. A history of previous attempts of closed reduction was present in 11 patients (64.7%) with type IV supracondylar fractures, whereas it was present in 4 (25%) patients with type III fractures. Neurovascular injuries are not uncommon in type IV fractures, and their incidence varies ~ between 0 and 36%.^{4,6} The present study had a single patient with type IV fracture with neurovascular injury. Other demographic factors such as age, gender, laterality, open/closed fracture, and distal neurovascular status were not statistically significant in differentiating types III and IV fractures.

The present study tried to identify preoperative radiographic parameters that would be more likely to be associated with type IV fractures. The most statistically significant factor was valgus angulation of the distal fragment (sensitivity of 88%, specificity of 81%). From the ROC curve, a valgus angulation $\geq 17^\circ$ is more likely to be a type IV fracture. Flexion angulation of the distal fragment, though not statistically significant ($p < 0.05$), had a specificity of 100%. A flexion angulation of $\geq 10^\circ$ is more likely to be a type IV fracture. Mitchell et al., in their study, had determined various preoperative radiological parameters in predicting type IV fractures.⁵ A significant overlap between type IV fractures and the flexion type of supracondylar fractures was noted in the study. It also noted valgus angulation, lateral translation, and osseous

**Fig. 3** ROC curve analysis of various parameters in predicting Gartland type 4 versus Gartland type 3.

apposition as other factors in predicting type IV fractures. The present study could find only valgus angulation as statistically significant. Other factors, such as lateral translation and osseous apposition, were not found to be statistically significant.

The limitations of the present study are its retrospective nature and its sample size. Another inherent limitation of the present study is the lack of a gold standard diagnostic test in diagnosing type IV fractures. Multivariate regression analysis could not be performed due to the sample size. Another important limitation of the present study is that not all cases were operated by the attending pediatric orthopedic surgeon, but by pediatric orthopedic fellows. This factor might have an influence on the classification of the fracture. The strength of the present study is that it is one of the few studies determining predictive factors for type IV fractures. The present study is also the first study to employ ROC curves to determine a cutoff value for types III and IV fractures. Radiographic parameters were determined by two experienced observers (Singh G. and Singh V.), increasing the generalizability compared with a single observer approach.

Conclusion

In conclusion, the present study found several preoperative factors associated with Gartland type IV fractures. Nonradiographic factors such as increased hospital injury duration,

previous attempts at closed reduction, and radiographic parameters such as valgus and flexion angulation were more likely to be associated with type IV fractures.

Conflict of Interests

The authors have no conflict of interests to declare.

References

- 1 Vaquero-Picado A, González-Morán G, Moraleta L. Management of supracondylar fractures of the humerus in children. *EFORT Open Rev* 2018;3(10):526-540
- 2 Cheng JC, Lam TP, Maffulli N. Epidemiological features of supracondylar fractures of the humerus in Chinese children. *J Pediatr Orthop B* 2001;10(01):63-67
- 3 Barton KL, Kaminsky CK, Green DW, Shean CJ, Kautz SM, Skaggs DL. Reliability of a modified Gartland classification of supracondylar humerus fractures. *J Pediatr Orthop* 2001;21(01):27-30
- 4 Leitch KK, Kay RM, Femino JD, Tolo VT, Storer SK, Skaggs DL. Treatment of multidirectionally unstable supracondylar humeral fractures in children. A modified Gartland type-IV fracture. *J Bone Joint Surg Am* 2006;88(05):980-985
- 5 Mitchell SL, Sullivan BT, Ho CA, Abzug JM, Raad M, Sponseller PD. Pediatric Gartland Type-IV Supracondylar Humeral Fractures Have Substantial Overlap with Flexion-Type Fractures. *J Bone Joint Surg Am* 2019;101(15):1351-1356
- 6 Silva M, Cooper SD, Cha A. The Outcome of Surgical Treatment of Multidirectionally Unstable (Type IV) Pediatric Supracondylar Humerus Fractures. *J Pediatr Orthop* 2015;35(06):600-605