



Acromioclavicular, Coracoclavicular and Medial Coracoclavicular Ligaments Assessment in Acromioclavicular Dislocation

Avaliação dos ligamentos acromioclavicular, coracoclaviculares e coracoclavicular medial na luxação acromioclavicular

Rômulo Brasil Filho¹ Marcelo Mamede de Freitas¹  Rafael Henrique Rangel Nunes¹ 
Antonio Carlos Tenor Junior¹ Miguel Pereira da Costa¹ Rodrigo de Araújo Roberto¹

¹ Hospital do Servidor Público Estadual de São Paulo (HSPE), IAMSPE, São Paulo, SP, Brazil

Address for correspondence Marcelo Mamede de Freitas, MD, Hospital do Servidor Público Estadual de São Paulo, Rua Pedro de Toledo, 1800, São Paulo, São Paulo, 04039-901, Brasil (e-mail: marcelomamede@hotmail.com).

Rev Bras Ortop 2021;56(6):777–783.

Abstract

Objective To study the anatomy of the medial coracoclavicular ligament and assess the contribution of the acromioclavicular, coracoclavicular and medial coracoclavicular ligaments to the stability of the acromioclavicular joint.

Methods Twenty-six shoulders from 16 fresh cadavers were dissected after placement in dorsal recumbency with a 15-cm cushion between the shoulder blades. An extended deltopectoral approach was performed proximally and medially, followed by plane dissection and ligament identification. The acromioclavicular and coracoclavicular distances were measured using points previously marked with a millimeter caliper. Six of these specimens were submitted to a biomechanical study. The acromioclavicular ligament, the coracoclavicular ligament and the medial coracoclavicular ligament were sectioned sequentially, and a cephalic force of 20 N was applied to the lateral clavicle. The acromioclavicular and coracoclavicular distances were measured in each of the ligament section stages.

Results The right medial coracoclavicular ligament presented, on average, 48.9 mm in length and 18.3 mm in width. On the left side, its mean length was 48.65 mm, with a mean width of 17.3 mm. Acromioclavicular, coracoclavicular and medial coracoclavicular ligament section resulted in a statistically significant increase in the coracoclavicular distance and posterior scapular displacement.

Conclusion The medial coracoclavicular ligament is a true ligamentous structure found in all dissected shoulders. Our results showed that the scapular protraction

Keywords

- ▶ acromioclavicular joint
- ▶ joint dislocations
- ▶ anatomy
- ▶ dissection

Study developed at Hospital do Servidor Público Estadual de São Paulo, HSPE, IAMSPE, São Paulo, SP, Brazil.

received
January 29, 2020
accepted
September 16, 2020

DOI <https://doi.org/10.1055/s-0040-1719088>.
ISSN 0102-3616.

© 2021. Sociedade Brasileira de Ortopedia e Traumatologia. All rights reserved.

This is an open access article published by Thieme under the terms of the Creative Commons Attribution-NonDerivative-NonCommercial-License, permitting copying and reproduction so long as the original work is given appropriate credit. Contents may not be used for commercial purposes, or adapted, remixed, transformed or built upon. (<https://creativecommons.org/licenses/by-nc-nd/4.0/>)

Thieme Revinter Publicações Ltda., Rua do Matoso 170, Rio de Janeiro, RJ, CEP 20270-135, Brazil

relaxed the medial coracoclavicular ligament, while scapular retraction tensioned it; in addition, our findings demonstrate that this ligament contributes to the vertical and horizontal stability of the acromioclavicular joint.

Resumo

Objetivo Estudar a anatomia do ligamento coracoclavicular medial e avaliar a contribuição do ligamento acromioclavicular, coracoclaviculares e coracoclavicular medial na estabilidade da articulação acromioclavicular.

Métodos Foram dissecados 26 ombros de 16 cadáveres frescos, posicionados em decúbito dorso-horizontal, com um coxim de 15 cm de altura entre as escápulas. Realizou-se uma via deltopeitoral estendida proximal e medialmente. Realizou-se dissecação por planos e identificação dos ligamentos. Realizou a medida da distância acromio-clavicular e coracoclavicular usando pontos previamente demarcados com paquímetro milimetrado. Em seis dessas amostras foi realizado estudo biomecânico. Seccionando, nesta ordem, o ligamento acromioclavicular, os coracoclaviculares e o ligamento coracoclavicular medial com uma força cefálica de 20N foi aplicada na clavícula lateral. Foi medida a distância acromio-clavicular e coracoclavicular em cada uma das etapas de secção dos ligamentos.

Resultados A média de comprimento do ligamento coracoclavicular medial foi de 48,9mm e a média de largura, de 18,3mm no lado direito. No esquerdo, a média de comprimento foi de 48,65mm e a média da largura, 17,3mm. Após a secção dos ligamentos acromioclaviculares, coracoclaviculares, com a secção do ligamento coracoclavicular medial houve aumento estatisticamente significativo da distância córaco-clavicular e um deslocamento posterior da escápula.

Conclusão O ligamento coracoclavicular medial é uma estrutura ligamentar verdadeira, presente em todos os ombros dissecados. Nossos resultados demonstraram que o ligamento coracoclavicular medial encontra-se relaxado com a escápula em protração e tenso com a escápula em retração e segundo nossos resultados participa tanto da estabilidade vertical quanto da estabilidade horizontal da articulação acromioclavicular.

Palavras-chave

- ▶ articulação acromioclavicular
- ▶ luxações articulares
- ▶ anatomia
- ▶ dissecação

Introduction

The literature on the anatomy and ligamentous biomechanics of the acromioclavicular (AC) joint is very rich. Countless studies discuss different types of treatment for traumatic AC joint injuries and the open and arthroscopic surgical approaches to the acromioclavicular and lateral coracoclavicular (conoid and trapezoid) ligaments. However, there are few papers regarding the ligamentous anatomy medial to the coracoid process, notably the medial coracoclavicular ligament (LCCM) and its role in acromioclavicular dislocation, as this anatomical study.

Described as a “bicorne ligament” for presenting two main fascicles by Leopoldo Caldani in 1802,¹ LCCM was once considered a thickened part of the clavipectoral fascia² or a coracocostal ligament;³ its own existence was questioned.⁴⁻⁸

LCCM forms a strip of pearly-yellow fibers arising from the medial border of the coracoid process as two fascicles (an anterior and a posterior fascicles) which merge to form the ligamentous body attached to the medial portion of the clavicle.^{2,9,10} There are divergences regarding its attachment. Some authors¹¹⁻¹³ divide it into two fascicles (a superior fascicle on the anterior border of the clavicle and a lower fascicle on the sternal border of the first rib).¹⁰

Other authors believe its attachment is at the anterior border of the clavicle and divided into three expansions (superior, inferior, and medial expansions).

Recently, LCCM features have been described in magnetic resonance images.¹⁴

This work studied LCCM anatomy to assess its function and contribution to the stability of the acromioclavicular joint in cases of injury.

Materials and Methods

This study was approved by the Research Ethics Committee of our institution (CAAE number 12358919.0.00005463) and performed at the coroner's office from São Paulo, SP (Serviço de Verificação de Óbitos, SVO) from Universidade de São Paulo (USP), Brazil.

Twenty-six shoulders from 16 fresh adult cadavers with no scars or previous deformities were dissected. All dissections were performed by the same group of researchers, consisting of orthopedic specialized in shoulder surgery, and carried out in a standardized way, with the cadaver in dorsal recumbency with a 15-cm cushion at the interscapular region. Dissection started with an extended, proximal

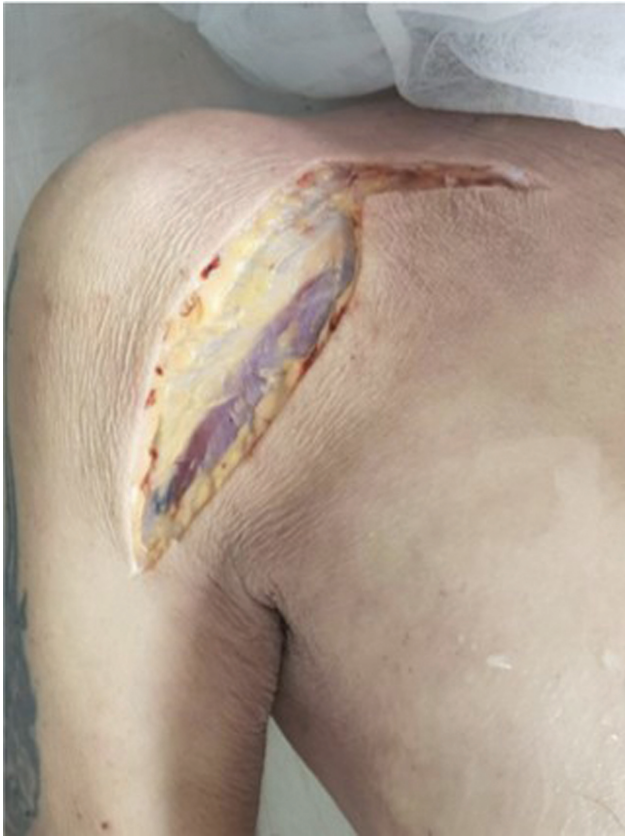

Fig. 1 Extended deltopectoral approach.

deltopectoral approach in “L” shape, following horizontally towards the clavicular sternum joint (► **Figure 1**–Approach).

Dissection was performed in planes. The deltoid and pectoralis major muscles were removed from the anterior aspect of the clavicle, and the LCCM was identified from its attachment to the coracoid process to its attachment to the medial end of the clavicle; its length and width were measured with a millimeter caliper (► **Figures 2** and **3**). Scapular retraction and protraction movements were performed, observing the effect on ligament tension. The acromioclavicular, trapezoid, conoid, and medial coracoclavicular ligaments were sectioned sequentially, and the displacement of the acromioclavicular joint was observed both in cephalic and anteroposterior directions (► **Figure 4**).

At first, an anatomical study was carried out on 20 shoulders of ten cadavers to assess LCCM morphology. Next, a biomechanical study was carried out with six shoulders from six cadavers, which ligaments were sectioned sequentially. The clavicle was submitted to a cephalic traction with a constant force of 20 N, applied at 1 cm from the distal edge and measured with a dynamometer. Newton and kgF units were considered equivalent. Three anatomical points were marked (A, B, C); point A was located 1 cm from the most medial point of the acromion; point B was 1 cm from the most lateral point of the clavicle; and point C was on the lateral edge of the coracoid process. AC joint was

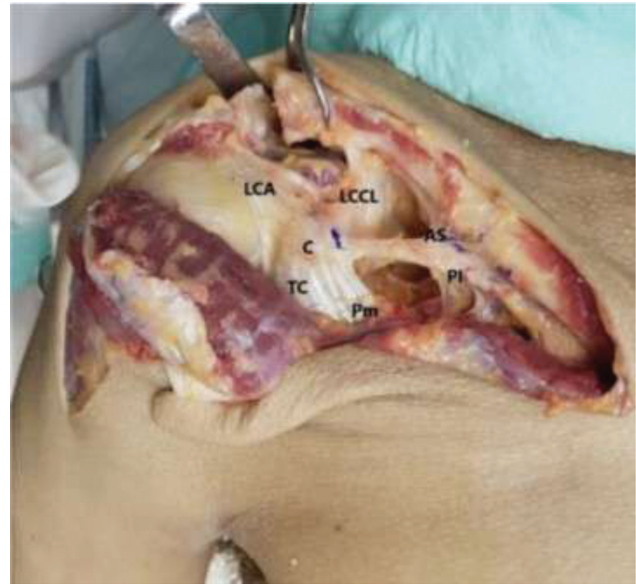

Fig. 2 Dissection, structures identification and medial coracoclavicular ligament (LCCM) measurement; ACL, coracoacromial ligament; C, coracoid; CT, joint tendon; Pm, pectoralis minor; LCCL, lateral coracoclavicular ligaments; AS, anterosuperior band; PI, posteroinferior band.

dissected, and its intrinsic ligaments were sectioned for the first time, followed by the sequential sectioning of the trapezoid and conoid ligaments and LCCM. At each step, a uniform 20 N traction force was applied to the lateral end of the clavicle. In addition, the vertical and horizontal distance between the acromion and the clavicle (from the upper edge of the acromion to the upper edge of the distal clavicle), the vertical distance between the coracoid process and the clavicle (coracoclavicular space), and the distance between

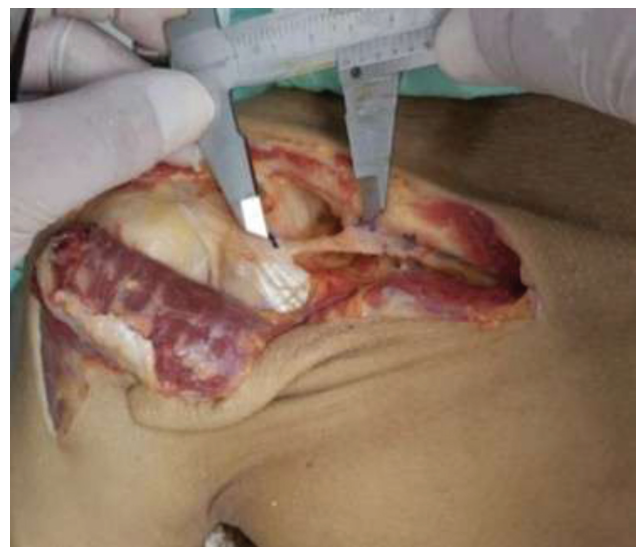

Fig. 3 Dissection, structures identification and medial coracoclavicular ligament (LCCM) measurement; ACL, coracoacromial ligament; C, coracoid; CT, joint tendon; Pm, pectoralis minor; LCCL, lateral coracoclavicular ligaments; AS, anterosuperior band; PI, posteroinferior band.

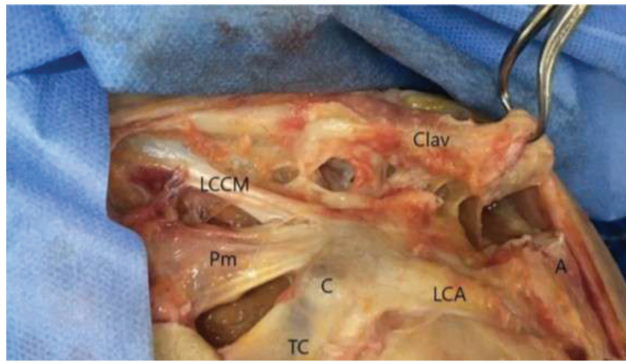


Fig. 4 Dissection and structures identification. Clav, Clavicle; A, acromion; LCCM, medial coracoclavicular ligament; ACL, coracoclavicular ligament; C, coracoid; TC, joint tendon; Pm, pectoralis minor.

the acromion and the clavicle was measured after each section, as described by Moya et al.¹⁵

Data was presented as mean and standard deviation values, and descriptively analyzed. Differences in variances were determined using analysis of variance (ANOVA) with repeated measures. Results were considered statistically significant when *p* value was less than 0.05 considering alternative two-tailed hypotheses. Collected information formed a database developed in Excel[®] for Windows and the statistical analysis was performed using SPSS[®] 16.0 software.

Results

LCCM was identified and measured in all dissected shoulders. On the right shoulder, LCCM presented, on average, 48.9 mm in length (ranging from 46 to 53 mm) and 18.3 mm in width (ranging from 17 to 20 mm). On the left shoulder, LCCM had, an average length of 48.65 mm (ranging from 45.5 to 52.5 mm) and an average width of 17.3 mm (ranging from 16 to 18 mm). ► **Table 1** shows results from the statistical analysis.

LCCM was divided into three segments: origin, body, and attachment. This ligament originates at the medial border of the coracoid process, medial and posterior to the pectoralis

Table 1 Medial coracoclavicular ligament measurements

	Mean	Standard deviation	Variance
Length, right side	48.90 mm	2.438	5.933
Length, left side	48.65 mm	2.7262	7.432
Width, right side	18.30 mm	0.949	0.900
Width, left side	17.30 mm	0.949	0.900

minor muscle attachment and distal to the origin of the conoid and trapezoid ligaments. LCCM bifurcates in its origin, forming two fascicles, an anterior and a posterior one, which merge to form the ligamentous body; this ligamentous body has pearly yellow color and fibroelastic consistency, and runs anteriorly to the subclavian muscle. Its attachment is located at the anteroinferior border of the medial clavicle, at a topography that hinders its isolation due to the large amount of aponeurosis.

Scapular protraction relaxed the LCCM, whereas scapular retraction tensioned it.

Six specimens were submitted to the sequential sectioning of the acromioclavicular, trapezoid, conoid and medial coracoclavicular ligaments. An upper displacement of the AC joint and posterior scapula was observed. A 20 N cephalic force was applied to the lateral clavicle using a portable analog dynamometer, and the distance from the AC, the coracoclavicular space and their variations were recorded. The anteroposterior movement of the clavicle following LCCM section was also evaluated. All (100%) cadavers were males. The right side was evaluated in 66.7% of the cases. The mean body mass index (BMI) was 23.8, with a standard deviation of 5.6, ranging from 12.5 to 32.0. Mean age was 67 years old, with a standard deviation of 9.5, ranging from 58 to 84 years old (► **Table 2**).

Superior displacement was assessed using the AB (acromion-clavicle) and BC (coracoid-clavicle) distances; posterior displacement was determined using the posterior AB (acromion-clavicle) distance. When measuring

Table 2 Measures found during assessment

Cadaver	Height	Age	Side	Acromioclavicular Distance				Acromion- Posterior Clavicle Distance				Coracoid-Clavicular Distance			
				1	2	3	4	1	2	3	4	1	2	3	4
1	1.85	68	Right	0.8	1.6	2.5	3.0	2.0	2.9	3.1	3.2	3.4	4.0	5.2	5.7
2	1.75	70	Right	0.6	1.4	3.0	3.4	2.2	2.3	3.8	4.5	3.0	3.5	4.8	5.5
3	1.65	64.	Right	0.9	1.4	2.2	2.7	2.2	2.5	2.7	3.5	3.3	3.8	4.5	5.0
4	1.87	58	Right	0.6	1.7	2.6	2.9	2.8	4.0	4.5	4.6	3.3	4.3	5.3	5.5
5	1.53	59	Left	1.0	2.1	3.2	3.9	1.8	2.5	3.9	4.3	3.5	4.0	5.0	5.8
6	1.70	84	Left	0.2	1.2	2.1	2.2	3.6	5.1	5.1	5.2	2.8	4.0	5.0	5.4

1, No injury; 2, acromioclavicular injury; 3, coracoclavicular injury; 4, medial coracoclavicular ligament injury.

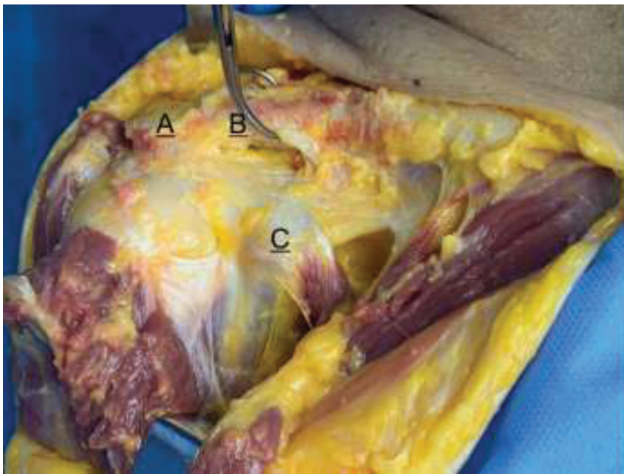


Fig. 5 Points A, B and C.

clavicular displacement at the superior AB point, posterior AB point and BC point at four different moments (with no injury to the acromioclavicular [AC] and coracoclavicular [CC] ligaments), AC injury, AC + CC injuries, and AC + CC + LCCM injuries (→ **Figures 5** and **6**), a statistically significant increase was observed in all points, as shown in → **Table 3**.

Mean acromion-clavicle (AB) distance went from 0.7 cm with no injury to 3.0 cm after sectioning all ligaments, including LCCM. Mean coracoid-clavicle (BC) distance increased from 3.2 cm with no injury to 5.5 cm after sectioning all ligaments, with $p < 0.001$.

Ligament section resulted in a posterior scapular deviation that was exacerbated after LCCM section.

Discussion

LCCM, also called Henle's anterior coracoclavicular ligament and Soulié's horizontal coracoclavicular ligament^{1,10,12-14} is a matter of controversy; some authors even failure to mention it in the coracoid ligament anatomy.¹⁶ Klassen et al.⁸ did not find it in their dissections; Rouvière², Vallois and Thomas¹³ did not consider it a structure of its own, but a thickening of adjacent structures, i.e., a cord from the clavipectoral fascia.¹⁷ For Terra et al.,¹⁸ LCCM is an anatomical variation of the conoid ligament.

Poitevin et al.¹⁰ described the presence of LCCM in 100% of the studied shoulders (15 adults and eight fetuses). These authors reported the LCCM as originating in the coracoid

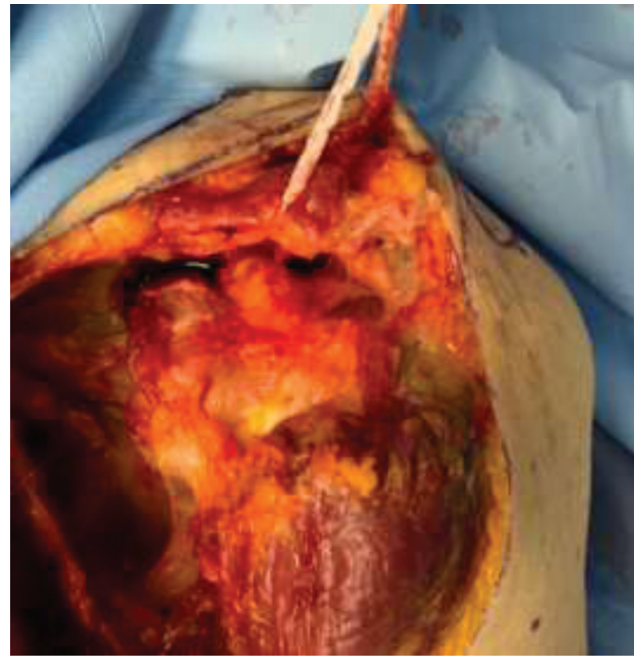

Fig. 6 Traction (20 N) after ligament section.

process, divided into two fascicles, and attaching itself at the medial clavicle, where it is divided into three expansions (superior, lower, and medial expansions).

In addition, the LCCM was studied using magnetic resonance imaging and viewed in its complete extension, from its origin at the coracoid process to its attachment to the medial clavicle, and its anatomical features were described.¹⁴

Stimec et al.¹² described the ligament from the dissection of a 92-year-old female cadaver specimen. The authors resected the ligament for measurement and histological analysis. They confirmed its ligament nature, its structure, and arrangement of collagen fibers, which are paired and surrounded by a thin layer of a richly vascularized connective tissue, similar to the conoid ligament.

Starting our studies in LCCM, we noted that the current literature is scarce, and that Poitevin et al.,¹⁰ Moya et al.¹⁵ and Azulay et al.¹⁴ papers reported recent studies. We tried to use a similar methodology to confront our results, and then discuss them to agree and/or disagree with their conclusions. We described absolute values of ligament lengths which were similar to those found by other authors in their dissections.

Table 3 Mean distance between points and standard deviation

	No Injury	AC Injury	CC Injury	LCCM Injury	p value
	Mean ± SD	Mean ± SD	Mean ± SD	Mean ± SD	
AB Distance	0.7 ± 0.3	1.6 ± 0.3	2.6 ± 0.4	3.0 ± 0.6	<0.001
Posterior AB Distance	2.4 ± 0.7	3.2 ± 1.1	3.9 ± 0.9	4.2 ± 0.7	0.009
BC Distance	3.2 ± 0.3	3.9 ± 0.3	5.0 ± 0.3	5.5 ± 0.3	<0.001

AC, Acromioclavicular; CC, coracoclavicular; LCCM, medial coracoclavicular ligament; SD, standard deviation.

We found the LCCM in all our dissections, bilaterally, as described by other authors. Its attachment to the medial clavicle is located at the anteroinferior portion of the bone, but it is surrounded by aponeuroses that can be confused with ligamentous branches or expansions. In addition, it was observed that the LCCM has intimate contact with the subclavian muscle, a finding that could lead to the conclusion that it would be the result of a scapulothoracic muscle metaplasia, as described by Luk et al.¹⁹ However, we dismiss this hypothesis because this ligament has been described in dissected human fetuses.¹⁰ Moya et al.¹⁵ suggest that the LCCM is a constant structure with mechanical ligamentous features that can act as the last restriction of the coracoclavicular space both in the cephalic and posterior direction, preventing further displacement in the absence of the lateral coracoclavicular ligaments.

Since this study was carried out at SVO on fresh cadavers and not on anatomical pieces as Moya et al.,¹⁵ we opted to position the cadaver in dorsal recumbency with a 15-cm cushion at the interscapular region to free the shoulder and keep it away to the dissection table. This allows for a better evaluation of the involved joints after progressive ligament section.

This study revealed that LCCM is relaxed during ipsilateral scapular protraction and it is tensioned during scapular retraction, raising the hypothesis that LCCM functions as a secondary horizontal stabilizer of the AC joint. This hypothesis reinforces the observation that, after sequential sectioning of AC, trapezoid and conoid ligaments, and keeping the interscapular cushion to suspend the shoulders, LCCM excision at its origin at the coracoid process promotes a statistically significant increase in AC distance.

We also found that, when sectioning all ligaments that join the scapula to the clavicle, the upper limb is totally subject to gravitational forces, i.e., the scapula is inferior to the clavicle, creating an image similar of a patient in orthostasis with Rockwood stage 5 AC dislocation.¹⁶ As such, we assume that LCCM lesion occurs in stages 4 and 5 of the Rockwood classification for AC dislocations.

We understand that the knowledge of the ligament structures medial to the coracoid process can contribute to the understanding of traumatic AC injuries; in addition, it can be of great value to surgical approaches requiring dissection of the soft tissues inserted in the coracoid process, such as muscle transfers, Bristow and Latarjet procedures and decompression in thoracic outlet syndrome.

LCCM existence as an anatomical structure is well established. However, we believe that new biomechanical and imaging studies may further clarify its stabilizing function at the AC joint.

A limitation of our study is the use of cadavers with an elevation of only 15 degrees. It would be ideal to have a greater body flexion for a better evaluation of the AC joint aided by gravitational force and orthostasis. Another limita-

tion is the small number of specimens. However, our findings are important to understand the structures involved in AC dislocation and the role of LCCM in AC joint stability. Further studies are required to clinically assess the importance of this ligament, correlating clinical, radiographic, and magnetic resonance imaging data.

Conclusion

LCCM is a true ligament structure present in all dissected shoulders. It is relaxed with the scapula in protraction and tensioned under scapular retraction. LCCM contributes to the vertical and horizontal stability of the AC joint.

Financial Support

There was no financial support from public, commercial, or non-profit sources.

Conflict of Interests

The authors declare no conflict of interests.

References

- 1 Caldani LMA. *Iconum anatomicarum explicatio*. Ossa 1802;1:244
- 2 Rouvière H. *Anatomie Humaine*. 2nd ed. Paris: Masson; 1927
- 3 Williams PL, Bannister LH, Berry MM, et al. *Gray's Anatomy*. 38th ed. Churchill Edinburgh: Livingstone; 1995
- 4 Ockert B, Braunstein V, Sprecher C, Shinohara Y, Kirchhoff C, Milz S. Attachment sites of the coracoclavicular ligaments are characterized by fibrocartilage differentiation: a study on human cadaveric tissue. *Scand J Med Sci Sports* 2012;22(01): 12–17
- 5 Salzmänn GM, Paul J, Sandmann GH, Imhoff AB, Schöttle PB. The coracoid insertion of the coracoclavicular ligaments: an anatomic study. *Am J Sports Med* 2008;36(12):2392–2397
- 6 Stine IA, Vangsness CT Jr. Analysis of the capsule and ligament insertions about the acromioclavicular joint: a cadaveric study. *Arthroscopy* 2009;25(09):968–974
- 7 Dal Molin DC, Ribeiro FR, Brasil Filho R, et al. Via de acesso cirúrgico posterossuperior para o tratamento das luxações acromioclaviculares: resultados de 84 casos operados. *Rev Bras Ortop* 2012;47(05):563–567
- 8 Klassen JF, Morrey BF, Ann KN. Surgical anatomy and function of the acromioclavicular and coracoclavicular ligaments. *Oper Tech Sports Med* 1997;5(02):60–64
- 9 Stedman TL. *A Practical Medical Dictionary*. New York: W. Wood and Company; 1920
- 10 Poitevin LA, Postan D, Moya D, et al. Anatomía del ligamento córa-co-clavicular medial. Primera parte: investigación anatómica. *Rev Arg Anat* 2014;5(04):119–126
- 11 Souteyrand-Boulanger J. Les formations fibreuses et les ligaments du triangle clavi- coraco- pectoral chez les primates. *Mammalia* 1966;30:645–666
- 12 Stimec BV, Lädermann A, Wohlwend A, Fasel JH. Medial coracoclavicular ligament revisited: an anatomic study and review of the literature. *Arch Orthop Trauma Surg* 2012;132(08): 1071–1075
- 13 Vallois HV, Thomas L. Les formations fibreuses du triangle clavipectoral. *Arch Anat Histol Embryol* 1942;3:363–396
- 14 Azulay G, Mamone A, Moya D, Poitevin L, Postan D. Identificación del ligamento coracoclavicular medial o de Caldani en imágenes de resonancia magnética. Protocolo original y

- aplicaciones clínicas. *Rev Asoc Argent Ortop Traumatol* 2017;82(01):71-77
- 15 Moya D, Poitevin LA, Postan D, et al. The medial coracoclavicular ligament: anatomy, biomechanics, and clinical relevance-a research study. *JSES Open Access* 2018;2(04):183-189
- 16 Rockwood CA Jr, Matsen FA, Wirth MA, Lippitt SB. *The Shoulder*. 4th ed. Philadelphia: W.B. Saunders; 2009
- 17 Martin RM, Vyas NM, Sedlmayr JC, Wisco JJ. Bilateral variation of subclavius muscle resembling subclavius posticus. *Surg Radiol Anat* 2008;30(02):171-174
- 18 Terra BB, Figueiredo EA, Marczk CS, et al. Variação anatômica do ligamento coracoclavicular. *RBM Rev Bras Med* 2010;67(Suppl 6):17-20
- 19 Luk KD, Ho HC, Leong JC. The iliolumbar ligament. A study of its anatomy, development and clinical significance. *J Bone Joint Surg Br* 1986;68(02):197-200