




Obstetric Paralysis: Evaluation of the Sever-L'Episcopo Technique Modified by Hoffer

Paralisia obstétrica: Avaliação da técnica Sever-L'Episcopo modificada por Hoffer

Antonio L. Severo¹  Pedro G. L. Carvalho¹  Marcelo B. Lemos¹  Marcos C. Nunes¹ 
Marjurie Scaranto¹  Fernando K. Barros² 

¹Department of the Institute of Orthopedics and Traumatology, Universidade Federal da Fronteira Sul, Campus Hospital São Vicente de Paulo, Passo Fundo, RS, Brazil

²Hospital da Brigada Militar de Santa Maria, Santa Maria, RS, Brazil

Address for correspondence Antônio Lourenço Severo, PhD, Department of the Institute of Orthopedics and Traumatology, Universidade Federal da Fronteira Sul, Campus do Hospital São Vicente de Paulo, Rua Uruguai, 2050, Passo Fundo, RS, 99010-112, Brazil
(e-mail: antoniolsevero@gmail.com; pesquisa2@hsvp.com.br).

Rev Bras Ortop 2020;55(6):787–795.

Abstract

Evaluate the results of a series of 28 cases of high obstetric paralysis treated with the Sever-L'Episcopo technique modified by Hoffer, between 2003 and 2016. Children (mean age, four years and seven months) with adduction contracture and internal rotation of the shoulder without secondary bone deformities (Mallet class II) underwent lengthening of the pectoralis major muscle and tenotomy of the subscapularis muscle associated with transfer of the latissimus dorsi and teres major muscle to the infraspinatus muscle, moving to the function of external rotators and elevators. The mean follow-up was three years and 10 months. At the end of the study, 24 patients achieved excellent functional assessment scores, mainly of the abduction and external rotation, passing from Mallet class II to class IV. Four patients still demonstrated some degree of global movement limitation, passing from class II to class III. Regardless of the final functional gain, all patients were able to perform tasks that were previously difficult. The data from this study suggest that Hoffer's surgery is an effective method in the treatment of the sequelae of high obstetric paralysis without secondary bone deformities.

Keywords

- ▶ shoulder
- ▶ paralysis obstetric
- ▶ contracture

Resumo

Avaliar os resultados de uma série de 28 casos de paralisia obstétrica alta tratamento com a técnica Sever-L'Episcopo modificada por Hoffer, entre 2003 e 2016. As crianças (idade média, quatro anos e sete meses) com contratura de adução e rotação interna do ombro sem deformidades ósseas secundárias (Mallet classe II) foram submetidas ao alongamento do músculo peitoral e tenotomia do músculo subescapular associada à transferência do latissimus dorsi e músculo teres major para o músculo infraespinhal, movendo-se para a função de rotores externos e elevadores. O seguimento médio foi de 3 anos e 10 meses. Ao

* Study conducted at Department of the Institute of Orthopedics and Traumatology, Universidade Federal da Fronteira Sul, Campus Hospital São Vicente de Paulo, Passo Fundo, RS, Brazil.



Palavras-chave

- ▶ ombro
- ▶ paralisia obstétrica
- ▶ contratura

final do estudo, 24 pacientes obtiveram excelentes escores de avaliação funcional, principalmente de abdução e rotação externa, passando de Mallet classe II para classe IV. Quatro pacientes ainda demonstraram algum grau de limitação de movimento global, passando da classe II para a classe III. Independentemente do ganho funcional final, todos os pacientes foram capazes de realizar tarefas que antes eram difíceis. Os dados deste estudo sugerem que a cirurgia de Hoffer é um método eficaz no tratamento das sequelas de paralisia obstétrica alta sem deformidades ósseas secundárias.

Introduction

Obstetric paralysis (OP) of the brachial plexus is a traumatic disorder caused by the forced stretching of one or more components of the plexus at delivery. The incidence of this condition in industrialized countries is from 0.5 to 3 per 1,000 live births.¹ Obstetric risk factors for plexus injury are high birth weight, prolonged labor, pelvic presentation, and shoulder dystocia.² Although uncommon, the plexus may also be injured during caesarean section or cephalic presentation.

Obstetric paralysis can be classified according to severity, following the Sunderland classification (grades I–V) according to the damaged nerve roots of the plexus.^{2–4} With regard to degree of injury, OP can be grouped into (1) higher paralysis or Erb-Duchenne paralysis, with involvement of the C5 and C6 roots and possible involvement of the C7 root; (2) Klumpke paralysis, affecting the C8 to T1 roots; and (3) paralysis of the whole arm, with involvement of all roots of the plexus.^{2,3} Erb-Duchenne paralysis is the most common type, accounting for around 75% of cases.^{3,5}

Physical examination of a newborn with the Erb-Duchenne variant showed the affected upper limb without movement at the side of the body and the elbow in extension. The Moro reflex was absent on the same side. Edema and ecchymosis in the supraclavicular region may be associated with clavicular or humeral fracture. The deltoid and external rotator muscles are commonly paralyzed, whereas movement of the fingers and wrists is maintained.²

Medial rotation contracture associated with shoulder adduction is the most common deformity in children with chronic plexopathy.² Over time, around 2 years of age, the child develops posterior subluxation/dislocation of the glenohumeral joint and a glenohumeral joint deformity.⁶

Several surgical procedures have been described in the literature for the correction of this deformity and its limitations. Fairbank⁷ recommended the section of the superior portion of the pectoralis major and subscapularis muscles and the anterior capsule of the shoulder. The main complication of this technique is late anterior dislocation.^{2,7} Sever,⁸ in turn, recommended release of the subscapularis muscle without previous capsulotomy, preventing this complication.^{2,3,8} L'Episcopo⁹ associated the transfer of the teres major muscle to a lateral position, turning it into an external rotator muscle.^{2,3,9} Zachary¹⁰ transferred the latissimus dorsi and teres major muscles as external rotators muscles.^{2,3,10} Zancolli¹¹ recommended that the teres major muscle is only transferred after a "Z" tenotomy of the muscle

is performed, with the distal tendon strip passing behind the humerus through the quadrilateral space and being sutured in the proximal tendon strip with the shoulder at 90° of abduction. Moreover, Zancolli¹¹ sectioned the pectoralis major, subscapularis, and coracobrachialis muscles and the short head of the biceps. He also recommended transfer of the pectoralis major to the subscapularis tendon to maintain medial rotation.^{2,3,10} Hoffer et al.¹² recommended transfer of the teres major and latissimus dorsi muscles to the rotator cuff.^{2,3,11} Pichon and Carlioz¹³ advocated resection of the subscapularis muscle origin.^{2,3} Soft-tissue surgeries are indicated in early cases of adduction contraction and medial rotation that have not improved with orthosis and elongations that do not present with bone deformities.^{2,3,12}

Miyazaki et al.¹⁴ suggested arthroscopic anterior joint release associated with transference of pectoralis major with an elongated and reinforced homologous tendon graft (Achilles or patellar tendon) to the posterosuperior portion of the greater tubercle. This procedure was indicated to those with functional deficit of lateral rotation of the shoulder, congruent joint and without glenoidal or humeral deformities, and presented an increase in active and passive lateral rotation, but presented worsening of the medial rotation. Other movements, such as elevation, hand-to-mouth, and hand-to-neck had less consistent evolution.

The main bone surgery is the humeral de-rotation osteotomy, which positions the distal segment in the lateral rotation in cases of posterior dislocation of the glenohumeral joint.^{2,3,12}

The present study aimed to objectively and subjectively evaluate the result and sequelae of the Sever-L'Episcopo technique modified by Hoffer for the treatment of high OP.

Methods

This was a retrospective longitudinal cohort study. The Mallet score (► **Fig. 1**) was used for the objective pre and postsurgical evaluations, whereas the Daily Life Questionnaire was used for the subjective evaluation.

Between January 2003 and October 2016, 28 patients with postoperative sequelae underwent surgery at the Service of Upper Limb Surgery and Microsurgery of the Institute of Orthopedics and Traumatology. The postoperative follow-up period ranged from 1 year and 10 months to 10 years and 10 months, representing a mean of 3 years and 10 months (► **Table 1**).

Seventeen (60.7%) male patients and 11 female patients participated in the study (39.3%). Thirteen of them (46.4%)
















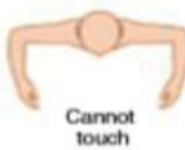


Modified Mallet classification (grade I = no function, Grade V = normal function)						
		Grade I	Grade II	Grade III	Grade IV	Grade V
Global abduction	Not testable	No function	 <30°	 30° to 90°	 >90°	Normal
Global external rotation	Not testable	No function	 <0°	 0° to 20°	 >20°	Normal
Hand to neck	Not testable	No function	 Not possible	 Difficult	 Easy	Normal
Hand on spine	Not testable	No function	 Not possible	 S1	 T12	Normal
Hand to mouth	Not testable	No function	 Marked trumpet sign	 Partial trumpet sign	 <40° of abduction	Normal
Internal rotation	Not testable	No function	 Cannot touch	 Can touch with wrist flexion	 Palm on belly, no wrist flexion	

Fig. 1 Modified Mallet classification (Adapted from Green's operative hand surgery, 2017).

had left-sided involvement and 15 (53.6%) had right-sided involvement, with ages ranging from 1 to 14 years and 8 months (mean of 4 years and 7 months).

All patients met the inclusion criteria of having Erb-Duchenne paralysis with internal rotational contracture and adduction. The abduction of the affected limb was < 30°, while the external rotation was 0°. They were unable to perform tasks with the affected limb, such as bringing the hand to the nape or back. When asked to bring the hand to the mouth, they showed difficulty, simultaneously abducting the shoulder, flexing the elbow, and accentuating lumbar lordosis (trumpet sign), fulfilling the criteria of grade II of the Mallet score (– Fig. 1).

Patients with total and low paralysis, those with high paralysis and glenohumeral dislocation after the radiographic examination, and those who previously underwent neurological surgery were excluded from the study.

All patients were surgically treated using the Hoffer-modified Sever-L'Episcopo technique.

Description of the Technique

A cushion is placed on the upper chest to expose the upper limb (front and back) and the lateral half of the thorax. The anterior incision is extended from the coracoid process to the deltopectoral groove (– Fig. 2A). The cephalic vein is protected and retracted along with the deltoid muscle. The interval between the deltoid and pectoralis major muscles is opened (– Fig. 2B). The short heads of the biceps and coracobrachialis muscles are visualized and detached from the coracoid process and bent downwards for visualization of the teres major and latissimus dorsi muscles (– Fig. 2C). Distally, in the surgical field, the pectoralis major is Z-lengthened; the distal half of its tendon is immediately disinserted from the humeral shaft. The stumps are sutured and elongation is achieved (– Fig. 2D).

The insertions of the latissimus dorsi and teres major muscles are identified, incised, and repaired (– Fig. 2E) after the subscapularis muscle is exposed and dissected on the head of the humerus. The subscapularis tendon is elongated

Table 1 Data of 28 patients who underwent the Sever-L'Episcopo technique modified by Hoffer

Case	Sex	Affected side	Preoperative		Postoperative		
			Age at surgery (y + m)	Functional evaluation (Mallet)	Follow-up length (y + m)	Functional evaluation (Mallet)	Daily Life Questionnaire
1	F	L	6 + 4	II	1 + 10	IV	S
2	M	L	1 + 4	II	1 + 10	IV	S
3	M	R	4 + 8	II	2 + 3	IV	S
4	M	R	9 + 3	II	2 + 6	IV	S
5	M	L	3 + 7	II	2 + 9	IV	S
6	M	L	4 + 6	II	2 + 6	IV	S
7	M	R	5 + 9	II	2 + 2	IV	S
8	F	L	4 + 5	II	3 + 6	IV	S
9	F	R	2 + 4	II	2 + 4	III	S
10	F	R	6 + 8	II	2 + 2	IV	S
11	M	R	9 + 11	II	2 + 4	IV	S
12	F	R	2 + 10	II	2 + 0	III	S
13	F	L	2 + 11	II	2 + 2	IV	S
14	M	R	3 + 6	II	2 + 4	IV	S
15	F	L	2 + 9	II	3 + 2	IV	S
16	F	R	14 + 8	II	7 + 8	III	S
17	F	R	9 + 3	II	4 + 7	IV	S
18	M	L	4 + 5	II	4 + 7	IV	S
19	M	R	3 + 11	II	1 + 10	IV	S
20	M	L	1 + 8	II	3 + 8	IV	S
21	M	R	9 + 6	II	5 + 3	IV	S
22	M	L	2 + 6	II	10 + 10	IV	S
23	M	R	1	II	10	IV	S
24	M	R	4 + 3	II	4 + 9	IV	S
25	M	L	1 + 9	II	3 + 7	III	S
26	M	R	1	II	8 + 8	IV	S
27	M	L	1 + 6	II	3 + 8	IV	S
28	M	L	3 + 3	II	4 + 8	IV	S

Abbreviations: m, months; S, satisfied; y, years.

Source: Serviço de Arquivo Médico e Estatística (SAME)/Ambulatory Service of Surgery of the Upper Limb and Microsurgery, Hospital São Vicente de Paulo campus, Universidade Federal da Fronteira Sul.

horizontally by an oblique cut made using a scalpel to divide the tendon into superficial and deep halves (→ **Fig. 2F**). This allows abduction and external rotation of the shoulder to carefully visualize the insertions of the latissimus dorsi and teres major muscles, since the capsule is not opened.

In the second surgical stage, a posterior incision of 7 to 8 cm is made on the interval between the deltoid and triceps muscles. The deltoid muscle is retracted superiorly and the long head of the triceps is retracted posteriorly to expose the latissimus dorsi and teres major muscles. Care must be taken not to injure the radial and axillary nerves, the posterior circumflex humeral vessels, and the deep brachial artery (→ **Figs. 3A, 3B**). Subsequently, the repaired stumps of the

latissimus dorsi and teres major muscles are identified and passed laterally to the long head of the triceps muscle. The shoulder is placed in abduction and maximal lateral rotation, and the tendons of the latissimus dorsi and teres major muscles—now the posterior muscles—are sutured at the insertion of the infraspinatus muscle and reach the supraspinatus muscle, acting as external rotators and elevators instead of rotators (→ **Figs. 3C, 3D**).

The operated limb is kept in an orthosis with the arm in the so-called “Statue of Liberty” position for 24 hours a day during the 1st month. After this period, in the 2nd month, the device is used 2 hours in the morning, 4 hours in the afternoon, and all night along with physiotherapeutic exercises to

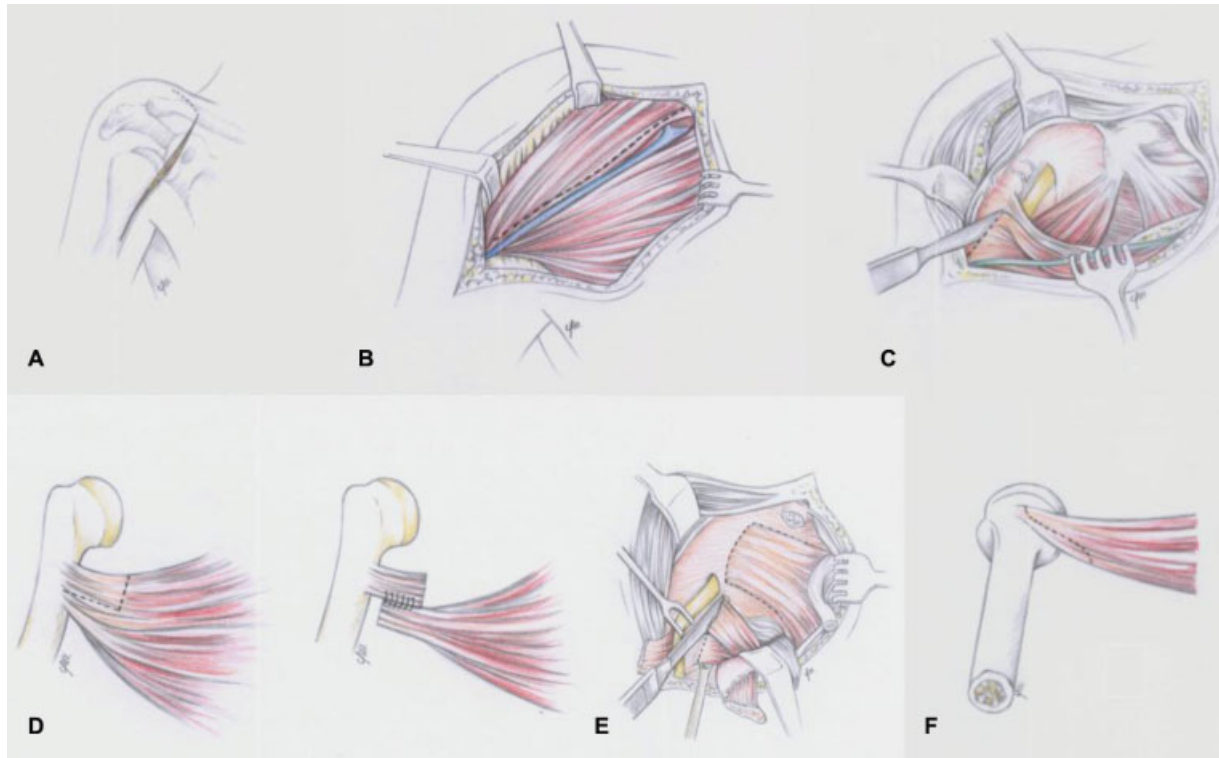


Fig. 2 (A) Anterior deltopectoral incision; (B) Cephalic vein at the center of the field and the opened interval between the deltoid and pectoralis major muscles (dashed line); (C) Deltoid muscle retraction and exposure of the humeral insertion of the pectoralis major muscle (divided using a scalpel); (D) Z-lengthening of the pectoralis major muscle tendon (section in dashed lines) and suturing of the stumps; (E) The subscapularis tendon (most superior dashed line) is divided and elongated; the latissimus dorsi and teres major muscles are divided and the stumps are repaired (lower dashed lines); (F) Location of the division of the subscapularis tendon (horizontally elongated via an oblique cut).

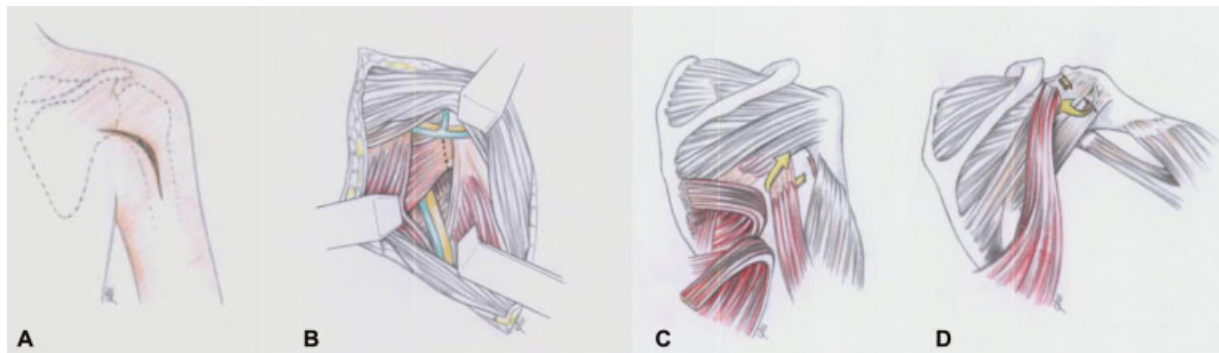


Fig. 3 (A) Posterior incision on the interval between the deltoid and triceps muscles. (B) Posterior visualization of the insertions of the latissimus dorsi and teres major muscles and location of the area including these tendons; (C) Latissimus dorsi and teres major muscles are detached and passed posteriorly to the long head of the triceps muscle; (D) With the shoulder abducted, the stumps are sutured in the rotator cuff.

help the patient gain movement. From the 3rd month onwards, the orthosis is used at night only; its use may be extended until the 6th postoperative month depending on the child's motor development (→ Fig. 4).

All patients (minimum age, 1 year and 10 months; maximum age, 10 years and 10 months) were subjectively reassessed postoperatively using a questionnaire answered by their guardians and objectively reassessed by physical examination.

The Daily Life Questionnaire contained questions related to the degree of parental satisfaction and the child's ability to perform previously impossible tasks, such as dressing alone, brushing their hair, and engaging in recreational activities. In

the objective evaluation, the degrees of abduction and active external and internal rotations as well as the ability to bring the hand to the mouth and the nape were evaluated. Due to great inter-observer discrepancies, we chose to classify each patient according to their range of motion expressed as Mallet¹⁵ score (→ Fig. 1).

Results

Our patients were followed up for a mean 3 years and 10 months. At the end of the follow-up period, 24 patients had excellent movement gains, passing from Mallet scores of grade II to grade IV, with 20 having such results in the 3rd

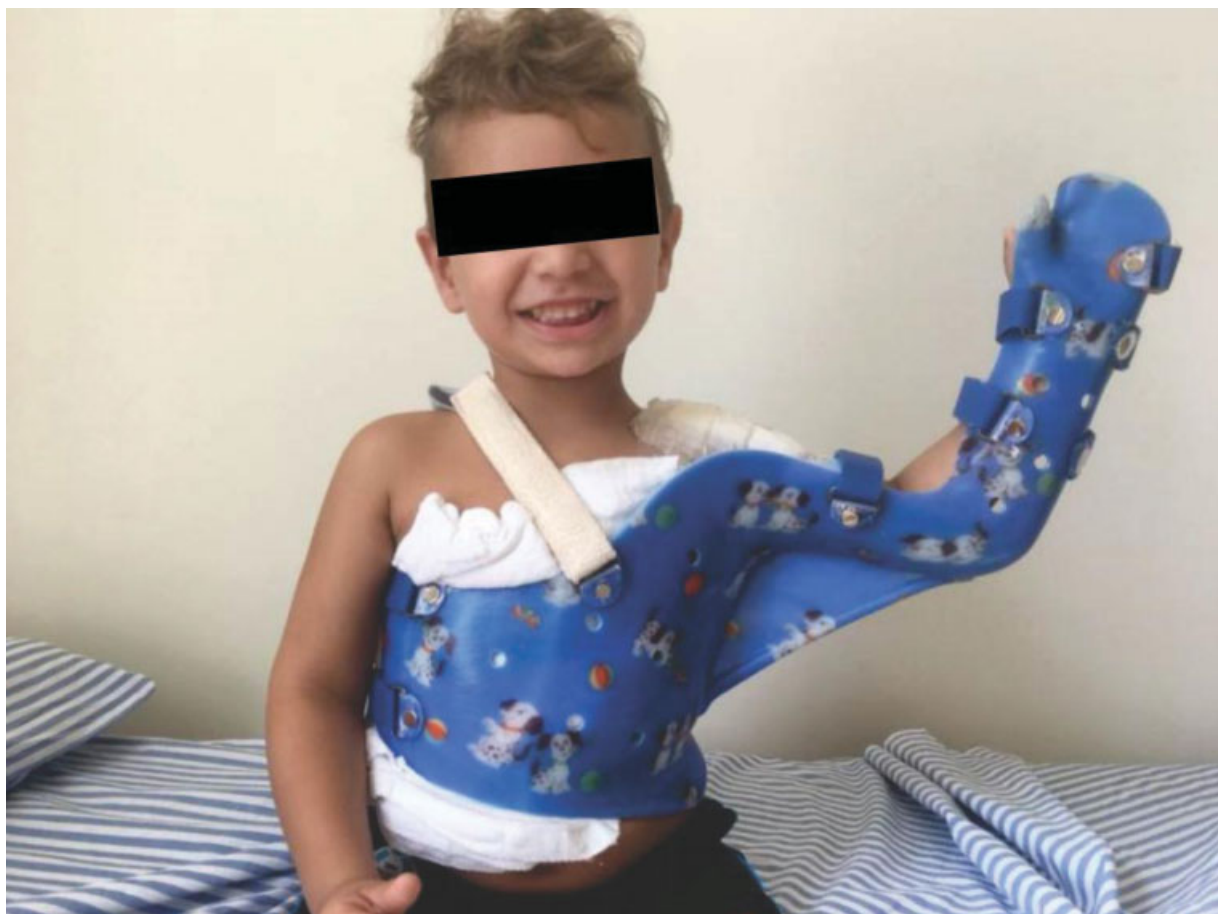

Fig. 4 Orthosis used to keep the patient in the “Statue of Liberty” position postoperatively.

postoperative month when physical therapy was intensified. At the end of the 6th postoperative month, 25 patients had achieved Mallet grade IV. Although one patient's status regressed to grade III during follow-up, it was still clinically better than that prior to surgery. Thus, at the end of the follow-up, 4 patients (follow-up length: 2 years and 4 months, 2 years, 3 years and 7 months, and 7 years and 8 months) were classified as grade III. Therefore, at the end of follow-up, 85% were classified as grade IV and 15% were classified as grade III.

Of all patients, four evolved with partial loss of internal rotation of the shoulder, achieving, during the examination, hand touch just above the gluteal region, even after physical therapy treatment, which is somewhat expected in some cases due to transposition of internal to external rotators.

Regardless of the results, all family members were satisfied with the results and all of the children started performing tasks that were previously impossible for them, such as dressing alone, brushing their hair, and participating in sports (► Figs. 5, 6).

Discussion

The study patients had a mean age of four years and seven months (minimum, one year; maximum, fourteen years and eight months). This is an age group in which complications

rarely result from muscle contraction. The consensus in the literature is that tenotomy and muscle transfer surgeries are the first option in the treatment of the sequelae of OP in younger patients who have not yet developed dislocation and joint incongruity. Osteotomies are strictly recommended for older cases, usually children ten to fourteen years of age, in which chronic dislocation has already led to partial impairment of the humeral head or glenoid.^{2-5,8,11}

Giostri et al.¹⁶ compared 20 patients. Thirteen of their patients were assigned to Group A, had a mean age of 6 years and 3 months, and underwent surgery using the L'Episcopo technique modified by Tachdjian. Of them, five were classified as grade II, six as grade III, and two as grade IV on Mallet's classification. The other 7 were assigned to Group B, had a mean age of 7 years and 11 months, and underwent humerus osteotomy. Of them, five were classified as grade IV and two were classified as grade III. The authors concluded that the osteotomy results were statistically superior to those of tendon transfer.¹⁶ In contrast, the present study had satisfactory results with 24 (85%) patients classified as grade IV and 4 (15%) classified as grade III only with muscle transfer, excluding cases of osteotomy. We suggest that the favorable results can be explained by the lower mean age of 4 years and 7 months and the use of a technique that elevates the latissimus dorsi and teres major muscles to the infraspinatus muscle.

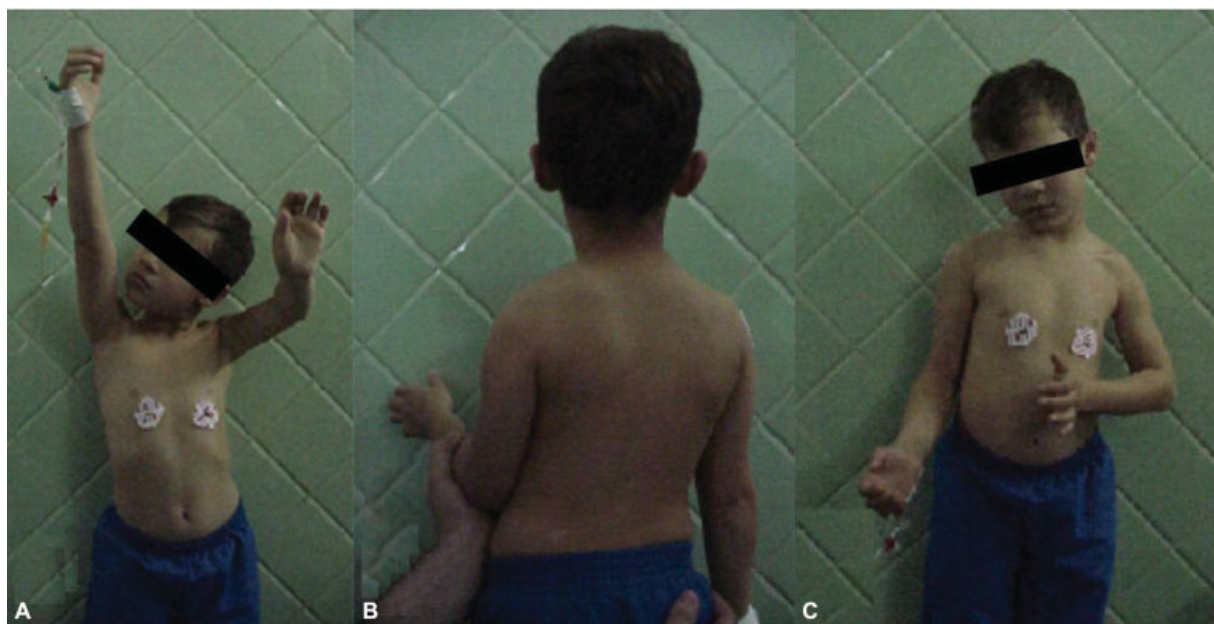

Fig. 5 (A, B, and C) I.D.S., 5 years old, preoperative, with sequelae of obstetric paralysis as well as limitations in elevation/abduction and external and internal rotations (Mallet grade II).

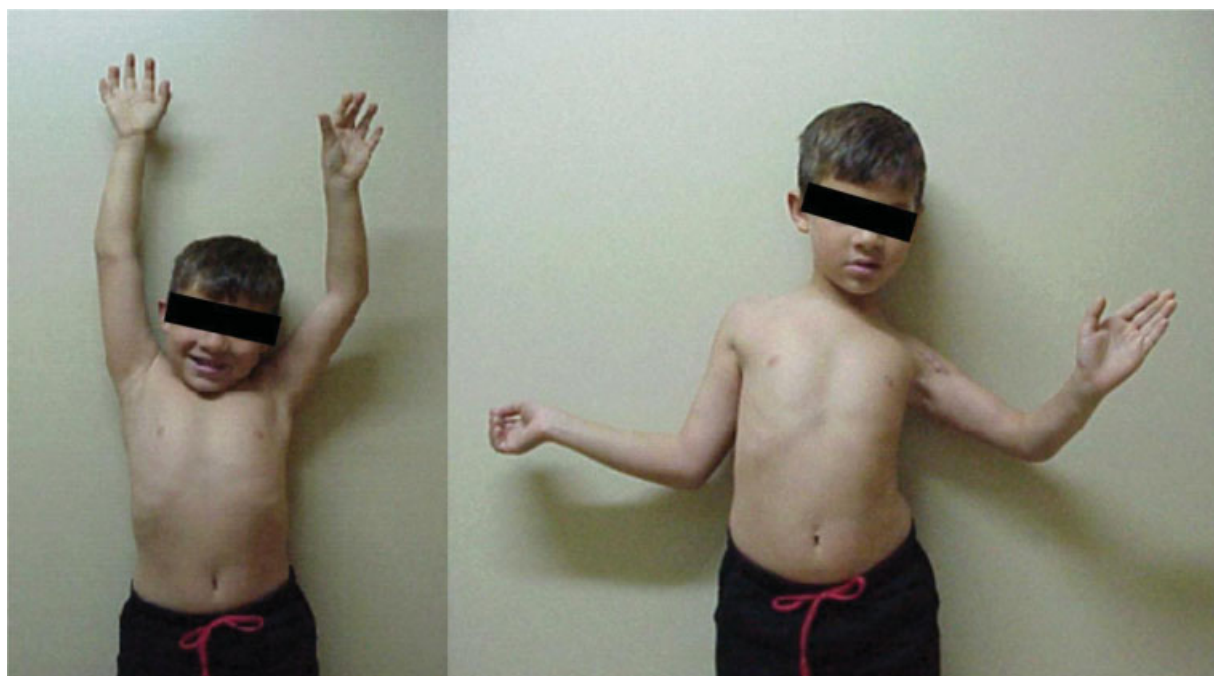

Fig. 6 Same patient shown in ►Fig. 5 at 4 months postsurgery. An elevation greater than 90° and external rotation greater than 20° are evident (Mallet grade IV).

Lopes et al.¹⁷ evaluated the results obtained in 7 patients with a mean age of 14 years and 10 months who presented with a subluxated and/or deformed humeral head and underwent osteotomy of external rotation of the humerus. The authors considered good results as those consisting of the achievement of active external rotation > 20° and the ability to bring the hand to the mouth and head.¹⁷ They observed improvement with surgery in five patients. Although this study excluded all cases of posterior humeral head dislocation or glenohumeral deformities, there is agreement in the literature that osteotomy is recommended for such cases.

Vieira et al.⁶ in turn evaluated sixteen patients aged between 1 year and 6 months and five years and ten months with sequelae of OP, adduction contracture, internal rotation, and posterior dislocation of the shoulder who underwent surgical procedure of centralization of the humeral head by internal de-rotation osteotomy possibly associated with soft-tissue procedures (surgery using the Sever-L'Episcopo technique). The authors concluded that the technique should be used in patients without important bone deformities in whom joint reduction with congruence is possible and performed between 2 and 8 years of age due to the large

potential for bone remodelling.⁶ In cases of osteotomies for glenohumeral deformity with or without posterior dislocation of the humeral head identified on computed tomography or magnetic resonance imaging, it is important to emphasize the importance of the use of the Waters classification.⁴ This classification consists of seven types: type I, normal glenohumeral joint; Type II, minimal hypoplasia of the glenoid cavity (increase of retroversion $> 5^\circ$); Type III, posterior subluxation of the humeral head; Type IV, development of a false glenoid cavity; Type V, posterior retroversion of the humeral head; Type VI, posterior dislocation of the humeral head; and Type VII, interruption of growth of the humeral head. Based on this classification, we agree with Viera et al.⁶ that when there is the potential for bone remodeling, internal de-rotation osteotomy is recommended for Types I to III, while external de-rotation osteotomy, as described by Giostri et al.¹⁶ and Lopes et al.¹⁷ is recommended for Types IV to VII.

Pichon and Carliz¹³ and Lopes Filho³ suggested that the release of contracted structures and tendon transfer be performed in different surgeries due to the need for early mobilization after the release and that the patient remain immobilized after the transfer.³ Gilbert et al.¹⁸ recommended disinsertion of the subscapularis in the first surgery because most of their patients under 2 years of age benefitted from the use of this procedure only with minimal risks of contraction recurrence. For these authors, age was an important factor in indicating the association of tendon transfer.¹⁸ The results of the present study agree that early age is a determining factor for the accomplishment and success of tendon release and transfer. However, in the present study, the tendon was released in the first surgery, according to the surgical preference of the authors.

The present study agrees with Chung and Nissenbaum¹⁹ and Narakas,²⁰ who recommend that tendon transfer occurs at the same time as the contracted structure release. We suggest that performing the two procedures jointly promotes muscle balance restoration and prevents deformity recurrence. In the current study, Z-lengthening of the pectoralis major muscle in addition to tenotomy of the subscapularis muscle require postoperative immobilization regardless of tendon transfer.

The transfer of the latissimus dorsi and teres major muscles to the posterior portion of the greater tubercle, where the infraspinatus muscle is inserted, potentiates active external rotation.^{21,22} Comtet et al.²¹ analyzing the biomechanics of tendon transfer, concluded that the muscles inserted into the tuberosities are more efficient than those inserted into the humeral shaft, as stated by Zachary.¹⁰ The gain of abduction is the result of a deltoid acting more efficiently due to the stabilizing effect of the rotator cuff on the glenohumeral joint enhanced by the transfer of the latissimus dorsi. Phipps and Hoffer²² called the phenomenon of dynamic stabilization of the humeral head the "force couple."

Hoffer,¹² in the original article, presented 11 patients with sequelae of OP who underwent surgery using the modified Sever-L'Episcopo technique. Follow-up ranged from 2 years

to 6 years and 8 months. All 11 children showed improved external rotation and abduction. Nine patients went from grade II to grade IV. Two cases had an external rotation $< 20^\circ$, passing from grade II to grade III. In one case, the author attributed the poor result to failure to release the subscapularis muscle. All patients had abduction $> 90^\circ$ (grade IV).¹² The present study reproduced the results of Hoffer et al.¹² with a follow-up period ranging from January 2003 to August 2018. Twenty patients had an important gain in the abduction and external and internal rotations in the 3rd postoperative month, being classified as Mallet IV, while 4 patients still had a certain limitation in the internal rotation movement, remaining in class III. Physical therapy was then intensified for functional gain; at the end of the 6th postoperative month, these patients went from grade III to grade IV classification. Thus, 24 of 28 (85%) patients went from grade II to grade IV after muscle release and transfer.

Terzis and Kokkalis²³ performed a study after evaluating 68 cases with different surgeries (soft tissues and osteotomies) for the treatment of obstetric paralysis. As a result of surgeries with transfer of latissimus dorsi with or without the release of major teres, $\sim 28\%$ of patients had difficulty performing activities of dressing in the midline of the body, but affirmed that this loss was supplanted by the improvement of limb function with the gain of external rotation. Likewise, Pearl et al.²⁴ describes that loss of internal rotation should be expected when performing any procedure that promotes movement in the opposite direction. In his study, he performed arthroscopic release of the anterior capsule and subscapularis tendon, with transference of the latissimus dorsi to the rotator cuff and maintenance of major teres in the anatomic site. Obtained partial loss of internal rotation, but the improvement in the range of motion of external rotation and limb function is much more important and significant gain.

Cabral et al.²⁵ performed a prospective study with 16 patients after modified Sever-L'Episcopo surgery. The patients obtained good results, with improvement of at least 1 stage in Mallet scale. The authors reported that although an important improvement in external rotation was seen, they had the impression that patients presented some difficulty in activities that depended on internal rotation of the shoulder, such as buttoning shirts. However, only 2 patients had restriction in positioning the hand on the back, which hypothesized the existence of possible adaptation over time.

In a long-term follow-up of 10 OP cases treated with the Hoffer technique, Suenaga et al.²⁶ reported that two patients had no satisfactory final functional gains; rather, they remained in grade II. The mean postoperative time in this study was 11 years. The poor result in one case was attributed to severe atrophy of the latissimus dorsi muscle; in the other case, it was attributed to the fact that the latissimus dorsi muscle was not transferred during surgery. Nonetheless, the authors consider the Hoffer surgical technique adequate for the long-term reconstruction and maintenance of the active function of the affected shoulder.²⁶

Several authors agree that, regardless of the functional gain in the operated limb, the maintenance of the humeral

head in the glenoid prevents marked joint deformities that would lead to shoulder instability and a lack of function.^{2-5,8,11}

Conclusion

The surgical technique of lengthening the pectoralis major muscle using tenotomy of the subscapularis muscle associated with transfer of the latissimus dorsi and teres major muscles to the rotator cuff, as described by Hoffer, is effective for the treatment of sequelae of Erb-Duchenne OP. The procedure is recommended for all children with high OP, adduction contracture, and internal rotation without secondary bone deformities. The technique aims to achieve functional gain, mainly of the abduction and external rotation, and allow the child to perform activities that were previously impossible.

Conflict of Interests

The authors have no conflict of interests to declare.

References

- de Luna Cabral JR, Crepaldi BE, Sambuy MT, da Costa AC, Abdouni YA, Chakkour I. Avaliação da função do membro superior nos pacientes com paralisia obstétrica após cirurgia de Sever-L'Episcopo modificada. *Rev Bras Ortop* 2010;47(04):451-454
- Tachdjian MO. Distúrbios traumáticos: paralisia obstétrica do plexo braquial. In: Mihran O, Tachdjian MO, editores. *Ortopedia pediátrica*. 2ª ed. São Paulo: Manole; 1995:2009-2020
- Lopes Filho JD. Tratamento cirúrgico das seqüelas da paralisia obstétrica no ombro [dissertação]. São Paulo: Faculdade de Ciências Médicas da Santa Casa de São Paulo; 2001
- Waters PM, Smith GR, Jaramillo D. Glenohumeral deformity secondary to brachial plexus birth palsy. *J Bone Joint Surg Am* 1998;80(05):668-677
- Galbiatti JA, Faloppa F. Paralisia obstétrica. In: Hebert S, Xavier R, Pardini AG Jr, Barros Filho TEP. *Ortopedia e traumatologia: princípios e prática*. 3a. ed. Porto Alegre: Artmed; 2003:830-838
- Vieira LA, Poderoso MA, Gonçalves MCK, et al. A osteotomia de centralização da cabeça umeral, na luxação posterior do ombro, seqüela de paralisia obstétrica. *Rev Bras Ortop* 2004;39(11/12):661-669
- Fairbank HAT. A lecture on Birth Palsy: Subluxation of the shoulder-joint in infants and young children. *Lancet* 1913;181(4679):1217-1223
- Sever JW. Obstetrical paralysis. *Surg Gynecol Obstet* 1927;44:547-549
- L'Episcopo JB. Tendon transplantation in obstetrical paralysis. *Am Surg* 1934;25:122-125
- Zachary RB. Transplantation of teres major and latissimus dorsi for loss of external rotation at shoulder. *Lancet* 1947;2(6482):757
- Zancolli EA. Classification and management of the shoulder in birth palsy. *Orthop Clin North Am* 1981;12(02):433-457
- Hoffer MM, Wickenden R, Roper B. Brachial plexus birth palsies. Results of tendon transfers to the rotator cuff. *J Bone Joint Surg Am* 1978;60(05):691-695
- Pichon F, Carlioz H. [Disinsertion of the subscapularis muscle in the treatment of obstetric paralysis of the upper limb (author's transl)]. *Chir Pediatr* 1979;20(02):135-141
- Miyazaki AN, Checchia CS, Checchia SL, Fregoneze M, Santos PD, Sella GV. Paralisia obstétrica: liberação artroscópica anterior do ombro e transferência do grande dorsal com enxerto homólogo. *Rev Bras Ortop* 2016;51(03):319-328
- Mallet J. Paralyse obstétricale du plexus brachial. Traitement des sequelles. *Rev Chir Orthop Repar Appar Mot* 1972;58(Suppl 1):166-168
- Giostrì GS, Machezini EJ, Pasin AP. Rotação interna na paralisia obstétrica: comparação dos resultados dos procedimentos de Sever-L'Episcopo e osteotomia derrotadora do úmero. *Rev Bras Ortop* 1996;31(01):33-35
- Lopes EI, Chackour I, Gomes MD, Cauchioli CA, Ramirez JF, Lopes Filho JD. Osteotomia de rotação externa do úmero no tratamento das deformidades em rotação interna do ombro nas sequelas de paralisia obstétrica. *Rev Bras Ortop* 1996;31(04):322-326
- Gilbert A, Romana C, Ayatti R. Tendon transfers for shoulder paralysis in children. *Hand Clin* 1988;4(04):633-642
- Chung SM, Nissenbaum MM. Obstetrical paralysis. *Orthop Clin North Am* 1975;6(02):393-400
- Narakas AO. Muscle transpositions in the shoulder and upper arm for sequelae of brachial plexus palsy. *Clin Neurol Neurosurg* 1993;95(Suppl):S89-S91
- Comtet JJ, Herzberg G, Naasan IA. Biomechanical basis of transfers for shoulder paralysis. *Hand Clin* 1989;5(01):1-14
- Phipps GJ, Hoffer MM. Latissimus dorsi and teres major transfer to rotator cuff for Erb's palsy. *J Shoulder Elbow Surg* 1995;4(02):124-129
- Terzis JK, Kokkalis ZT. Outcomes of secondary shoulder reconstruction in obstetrical brachial plexus palsy. *Plast Reconstr Surg* 2008;122(06):1812-1822
- Pearl ML, Edgerton BW, Kazimiroff PA, Burchette RJ, Wong K. Arthroscopic release and latissimus dorsi transfer for shoulder internal rotation contractures and glenohumeral deformity secondary to brachial plexus birth palsy. *J Bone Joint Surg Am* 2006;88(03):564-574
- de Luna Cabral JR, Crepaldi BE, de Sambuy MT, da Costa AC, Abdouni YA, Chakkour I. Evaluation of upper-limb function in patients with obstetric palsy after modified Sever-L'Episcopo procedure. *Rev Bras Ortop* 2015;47(04):451-454
- Suenaga N, Minami A, Kaneda K. Long-term results of multiple muscle transfer to reconstruct shoulder function in patients with birth palsy: eleven-year follow-up. *J Pediatr Orthop* 1999;19(05):669-671