


# Mirror Foot: Surgical Approach for Esthetic and Functional Improvement

## *Pé em espelho: Abordagem cirúrgica para melhora estética e funcional*

Lucas Almeida Guerra<sup>1</sup>  Jefferson Soares Martins<sup>2,3</sup> Igor Matsuy Pacheco Lehnen<sup>1</sup>  
Gabriella de Figueiredo Rodrigues<sup>1</sup> Luiz Fernando Batista Santana<sup>1</sup>

<sup>1</sup>Department of Orthopedics and Traumatology, Hospital das Clínicas, Universidade Federal de Goiás/EBSERH, Goiânia, GO, Brazil

<sup>2</sup>Musculoskeletal System Unit, Hospital das Clínicas, Universidade Federal de Goiás/EBSERH, Goiânia, GO, Brazil

<sup>3</sup>Foot and Ankle Group, Hospital das Clínicas, Universidade Federal de Goiás/EBSERH, Goiânia, GO, Brazil

Address for correspondence Lucas Almeida Guerra, Universidade Federal de Goiás, 1ª Avenida, s/n, Setor Leste Universitário, Goiânia – GO, 74605-020, Brasil (e-mail: lucasguerra100@gmail.com).

Rev Bras Ortop 2024;59(3):e462–e466.

### Abstract

Mirror foot is a rare congenital anomaly within the spectrum of complex polydactyly of the foot. It can occur alone or with other malformations or genetic syndromes. It is a little described topic in the literature, with few publications on its treatment. We report the case of a 4-year-old female patient who presented eight fingers on her left foot and no other associated deformities. Her complaints included the impossibility of wearing closed shoes and social stigma. Radiography revealed eight metatarsals with their respective phalanges, five cuneiform bones, and the absence of bone deformities in the hindfoot. We opted for a surgical approach aiming at functional and esthetic improvement, in addition to better adaptation to closed shoes, as desired by the patient and her family. We performed a dorsal and plantar “V” incision and resected three supernumerary rays, including three central metatarsals with their nine corresponding phalanges, two cuneiform bones, tendons, and excess digital nerves. Next, we sutured the intermetatarsal ligaments, preserving the fingers with a normal appearance, reducing the width of the foot, and preserving adequate support. Kirschner wires maintained the reduction by transmetatarsal fixation. During the postoperative period, the patient wore a boot splint with zero load with no complications. We removed the Kirschner wires and allowed load on the limb after 12 weeks.

### Keywords

- congenital foot deformities
- bone wires
- polydactyly

*Work developed at the Hospital das Clínicas, Universidade Federal de Goiás/Empresa Brasileira de Serviços Hospitalares (EBSERH), Goiânia, GO, Brazil.*

received  
June 28, 2021  
accepted  
October 14, 2021

DOI <https://doi.org/10.1055/s-0044-1786549>.  
ISSN 0102-3616.

© 2024. The Author(s).

This is an open access article published by Thieme under the terms of the Creative Commons Attribution 4.0 International License, permitting copying and reproduction so long as the original work is given appropriate credit (<https://creativecommons.org/licenses/by/4.0/>).

Thieme Revinter Publicações Ltda., Rua do Matoso 170, Rio de Janeiro, RJ, CEP 20270-135, Brazil

## Resumo

O pé em espelho é uma anomalia congênita rara, pertencente ao espectro das polidactilias complexas dos pés. Pode ocorrer isoladamente ou associado a outras malformações ou síndromes genéticas. Trata-se de um tema pouco descrito na literatura, com escassas publicações acerca do seu tratamento. Relatamos o caso de uma paciente do sexo feminino, de 4 anos de idade, que apresentava pé esquerdo com 8 dedos, sem outras deformidades associadas, cuja queixa incluía impossibilidade do uso de calçados fechados e estigma social. Radiograficamente, verificou-se a presença de oito metatarsos com suas respectivas falanges, cinco ossos cuneiformes e ausência de deformidades ósseas no retropé. Optou-se pela abordagem cirúrgica visando uma melhoria funcional e estética, bem como melhor adaptação ao uso de calçados fechados, conforme desejo da paciente e de sua família. Foi realizada incisão em “V” dorsal e plantar com ressecção de três raios supranumerários, incluindo três metatarsos centrais com suas nove falanges correspondentes, dois ossos cuneiformes, tendões e nervos digitais excedentes, seguida da sutura dos ligamentos intermetatarsais, com preservação dos dedos com aparência normal, diminuição da largura do pé e manutenção do seu apoio adequado. A redução foi mantida por fixação transmetatarsal com fios de Kirschner. O pós-operatório seguiu com o uso de tala bota e carga zero, sem intercorrências; os fios de Kirschner foram retirados, e a carga no membro foi liberada após 12 semanas.

### Palavras-chave

- ▶ deformidades congênitas do pé
- ▶ fios ortopédicos
- ▶ polidactilia

## Introduction

Polydactyly is the most common congenital anomaly of the toes, with an incidence of 1.7 per every one thousand live births and a positive family history in around 30% of cases; in addition, it is up to 10 times more common among black people.<sup>1</sup> Polydactyly is postaxial when the extraneous ray is on the lateral (peroneal) foot surface and pre-axial when located on the medial (tibial) region. Polydactyly is complex when there is a mirror, central, dorsal, or Haas-type duplication, and all fingers present cutaneous fusion, with an extraneous ray that is either pre- or postaxial.<sup>2</sup>

Mirror foot is a rare subtype of polydactyly, and the literature has few reports on the best approach for the surgical treatment.<sup>3,4</sup> Patients with this complex deformity usually present seven to eight digits and duplication of the tarsal bones, but hindfoot bone involvement is rare.<sup>3,5</sup> Mirror foot can occur alone or with other malformations, commonly fibular hemimelia, tibial hypoplasia, mirror hand, and genetic syndromes, such as Laurin-Sandrow syndrome and Martin syndrome.<sup>3,5</sup>

There is no standardization to treat these patients. Planning of the surgical technique is tailored to improve gait function and provide adaptation to closed shoes and an esthetic appearance of the foot, which result from the excision of supernumerary rays, tendon transfers, and skin flap placement.<sup>3,5</sup> The more normal-looking digits are usually preserved. In the central type of mirror foot, resection of the middle rays results in very functional feet with a good cosmetic appearance.<sup>5</sup>

The current paper presents the surgical treatment technique used in a patient with a central mirror foot treated at

the Foot and Ankle Outpatient Clinic of the Musculoskeletal System Unit of our institution, and the postoperative outcomes. The study was submitted to and approved by the institutional Ethics Committee.

## Case Report

A 4-year-old female patient treated at the Foot and Ankle Surgery Outpatient Clinic of our hospital presented a deformity in her left foot, resulting in pain and the impossibility of wearing closed shoes. She had no pain when wearing open sandals or walking barefoot. Her neuropsychomotor development was age-appropriate. There were no other malformations or similar cases in the family. Her mother was healthy, a non-smoker, and had no complications during pregnancy. The parents had no consanguinity.

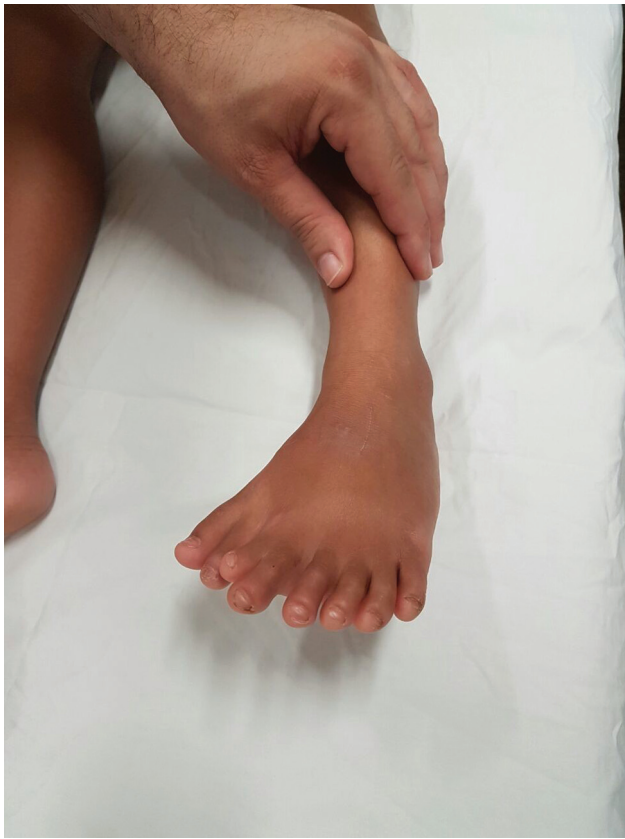The physical examination revealed eight fingers with a medialized hallux and central syndactyly (► Fig. 1), as well as the absence of tibial or fibular deformity or left lower limb shortening. Her gait was atypical, but with no limping.

Radiology showed the presence of eight rays, with hypoplasia of the third and hypertrophy of the fourth metatarsal, five cuneiform bones, and no bone fusions in the phalanges or hindfoot deformities (► Fig. 2).

## Therapeutic Planning

After diagnosing the mirror foot, we decided on surgical correction with the family and the patient, considering the social repercussions and stigmas, the possibility of using closed shoes, and the esthetic improvement of the foot.

The surgical planning included the removal of three central supernumerary rays, including three metatarsals



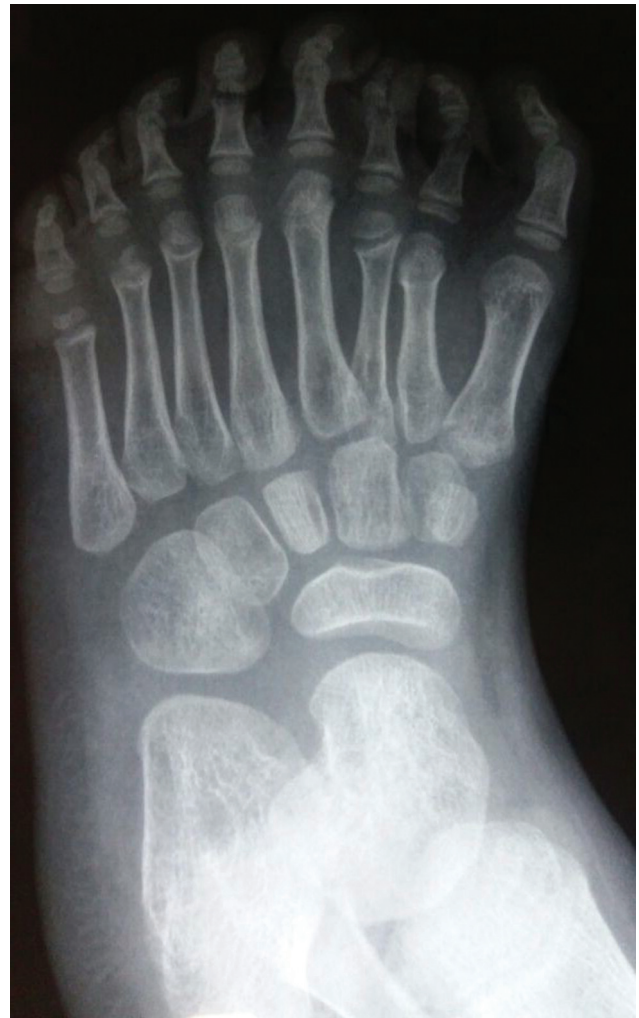**Fig. 1** Preoperative clinical appearance of the mirror foot.

with the nine corresponding phalanges, two cuneiform bones, and the corresponding tendons and digital nerves, preserving the fingers with an appearance closest to normal.

### Technical Description

The procedure occurred in a surgical center, with the patient in the supine position, under spinal anesthesia, a lateral cushion, and a pneumatic tourniquet at the thigh level inflated to 300 mmHg. We performed a “V”-shaped dorsal and plantar skin incision centered on the middle of the foot (→ **Fig. 3**), followed by dissection in planes and resection of the second, third, and fourth metatarsals and their phalanges, and the second and third cuneiforms. Next, we placed a wedge flap. Removal of the second toe on the medial side led to an inevitable rupture of the Lisfranc ligament. After hemostasis, we reduced the width of the forefoot by approximating the metatarsal bones and fixation with 2 parallel 1.5-mm Kirschner wires inserted 90° degrees from the first metatarsal bone, avoiding transfixing the growth plate. We checked the positioning of the Kirschner wires (→ **Fig. 4**) and sutured the intermetatarsal ligaments with absorbable thread. We placed a suction drain and performed synthesis in layers using absorbable sutures in the subcutaneous tissue and 4.0 mononylon for skin closure (→ **Fig. 5**). We removed the drain after 12 hours, with a blood flow of 50 mL.

Intraoperatively, cuneiform bone duplication is a challenge, as it requires deciding how many cuneiform bones to remove and the influence of the number of metatarsal bones.



**Fig. 2** Preoperative radiological appearance of the mirror foot.

This bone wedge removal must occur à la carte and forefoot closure, with the resulting width reduction, must be the main reference parameter for the number of cuneiform bones to be removed.

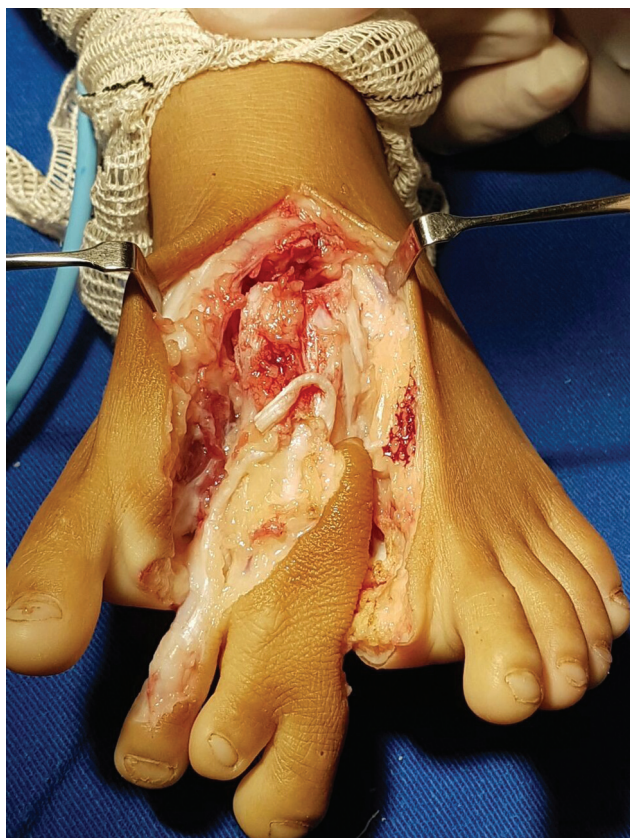The postoperative period was uneventful, and the patient wore a boot splint with zero load. Suture removal occurred after 18 days, and Kirschner wire removal happened after 3 months, when we allowed full load on the limb.

### Discussion

In a literature survey from 2017, Lalé et al.<sup>6</sup> found 78 patients, totaling 118 mirror feet, including only 3 cases with a normal talus. These studies reported few cases, some undergoing surgical treatment but with no standardized approaches. The strategies adopted in most cases aimed at a functional foot with a satisfactory esthetic presentation.

The central mirror foot is the most uncommon form of this rare deformity, comprising only 6% of the cases.<sup>4</sup> To date, we have not found case reports or descriptions of published treatments for this malformation in the Brazilian literature.

Papamerkiouriou et al.<sup>4</sup> described the surgical treatment of a central mirror foot with a dorsal and plantar “V” incision



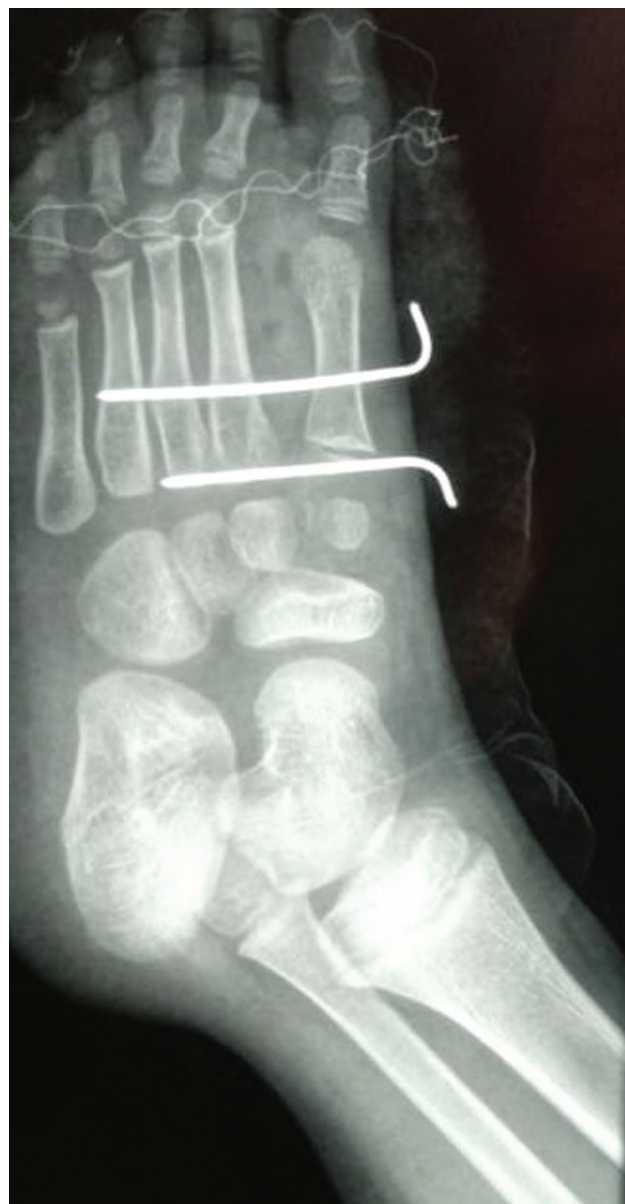**Fig. 3** Wedge resection of supernumerary rays and bones.

in the center of the foot, removing excessive skin, three central rays, and extra tendons and digital nerves, consistent with the case herein reported.

Shahcheraghi et al.<sup>5</sup> reported treating two cases of central mirror foot by removing the central rays and excessive skin. In one of these cases, the approximation of the other metatarsals used cerclage with 1.0 steel wire and suture with absorbable thread. In the other case, ray approximation relied on a metal pin inserted with the lateral and medial ends bent to contain the enlargement of the forefoot. In the present study, after resecting the three central rays and the two excess wedges, we opted for transmetatarsal fixation of the first to fourth rays with Kirschner wires to stabilize them and heal the soft tissues.

Vlahovic et al.<sup>8</sup> described the surgical treatment of a patient with central polydactyly with nine fingers who underwent resection of the four supernumerary rays. They closed the space generated by fixing the first ray adjacent to the other rays with Kirchner wires, with no complications. However, after approximately 7.5 years, the patient required a new intervention due to progressive adduction of the tarsal bones and hallux abnormality. This new procedure removed the supernumerary cuneiform and corrected the alignment of the first metatarsal and the hallux varus with Kirschner wires.

All of these cases in the literature evolved with satisfactory functional and esthetic outcomes, which is consistent with the present study. Allen (1997, apud Osborn et al.<sup>7</sup>) described another central ray resection technique associated



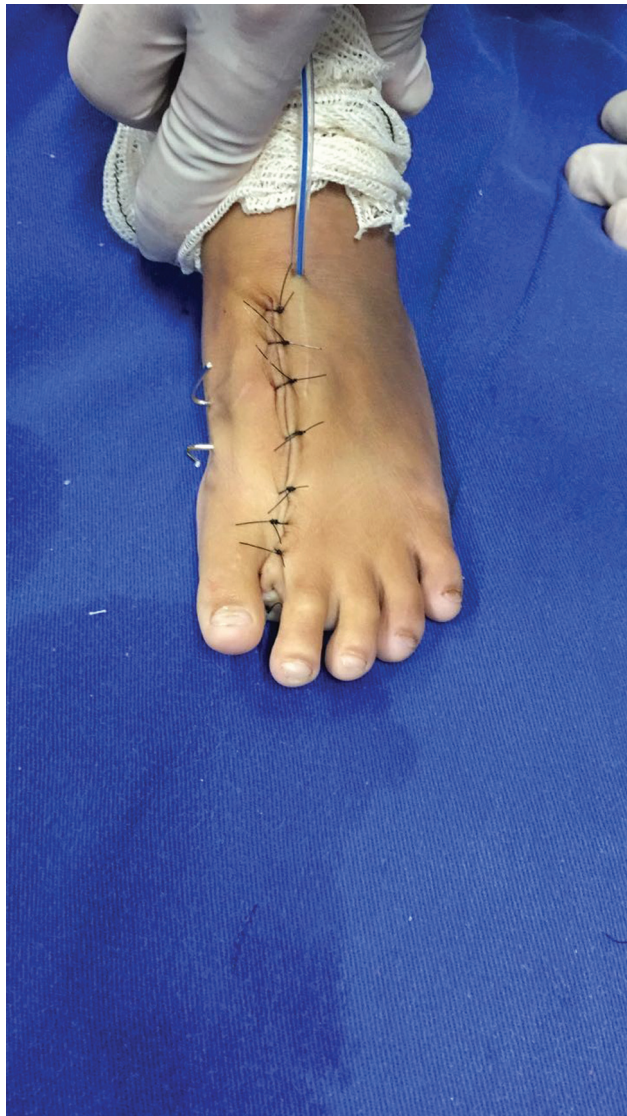**Fig. 4** Immediate postoperative radiological appearance.

with dorsal and plantar advancement flaps to maintain the width of the foot, which demonstrated excellent radiographic and functional outcomes in a case series of cases with 22 patients and 27 feet with central polydactyly.

The technique used in the present case encompasses strategies described by these different authors, including wedge resection of the excess skin and supernumerary bones, closure of the resulting space, and alignment of the remaining rays, aiming for anatomy close to normal, which were fixed with Kirschner wires to maintain the intermetatarsal space reduction, and good esthetic and functional outcomes were achieved.<sup>4,5,8</sup>

## Final Comments

Despite being a rare condition with scarce literature, the existing studies have shown good outcomes from the



**Fig. 5** Postoperative clinical appearance.

surgical treatment of these patients, promoting better quality of life and resulting in patient satisfaction. Standardizing the most appropriate type of treatment is challenging due to

the rarity and variability in the clinical presentation of mirror foot. Nevertheless, the need to master anatomy, knowledge of foot biomechanics, and concepts of operative technique for individualized planning is evident in the search for the functional and esthetic restoration of feet affected by this deformity. As a limitation of the present study, the patient was lost to follow-up, as she did not return to the outpatient clinic after we allowed the full load and could not be reached by telephone or the address registered in the medical record at the beginning of the follow-up.

#### Financial Support

The authors declare that they have received no financial support from agencies in the public, private, or non-profit sectors for the conduction of the present study.

#### Conflict of Interests

The authors have no conflict of interests to declare.

#### References

- 1 Skoll PJ, Silfen R, Hudson DA, Bloch CE. Mirror foot. *Plast Reconstr Surg* 2000;105(06):2086–2088
- 2 Lee HS, Park SS, Yoon JO, Kim JS, Youm YS. Classification of postaxial polydactyly of the foot. *Foot Ankle Int* 2006;27(05):356–362
- 3 Sudesh P, Kumar V, Jain M, Patel S. Mirror foot and our surgical experience: a case report and literature review. *Foot* 2010;20(01):44–45
- 4 Papamerkouriou YM, Antoniou G, Krallis P, Anastasopoulos J. Central Mirror Foot: Treatment and review of the literature. *Cureus* 2020;12(06):e8448
- 5 Shahcheraghi GHMD, Javid M. Treatment of the Mirror Foot with Central Ray Resection: Report of 2 Cases. *Iran J Med Sci* 2018;43(05):550–553
- 6 Lalé SA, Burger EB, Bessems JHJM, Pollet V, van Nieuwenhoven CA. Long term follow-up and development of foot complaints in a surgically treated mirror foot-A case report and review of literature. *Foot Ankle Surg* 2017;23(04):e9–e13
- 7 Osborn EJ, Davids JR, Leffler LC, Gibson TW, Pugh LI. Central polydactyly of the foot: surgical management with plantar and dorsal advancement flaps. *J Pediatr Orthop* 2014;34(03):346–351
- 8 Vlahovic AM, Pistignjat BS, Vlahovic NS. Nine toes; Mirror Foot Deformity. *Indian J Orthop* 2015;49(04):478–481