

Arthroscopic Bristow: Assessments of Safety and Effectiveness, 12 Years of Experience*

Bristow artroscópico: Avaliação da segurança e da eficácia, 12 anos de experiência

Jose Carlos Garcia Júnior¹ 

¹ Shoulder Group, Núcleo Avançado de Estudos em Ortopedia e Neurocirurgia (NAEON), São Paulo, São Paulo, Brazil

Rev Bras Ortop 2021;56(2):205–212.

Address for correspondence Jose Carlos Garcia Júnior, PhD, Núcleo Avançado de Estudos em Ortopedia e Neurocirurgia, Avenida Ibirapuera 2.144, Moema, São Paulo, SP, 04028-001, Brazil (e-mail: josecarlos@naeon.org.br).

Abstract

Objective The open Bristow procedure is a long established and effective method for treating anterior shoulder instability. Following the trends of minimally-invasive surgeries, these procedures were performed arthroscopically, and their outcomes were evaluated.

Methods A total of 43 shoulders of patients submitted to Bristow procedures by arthroscopy, using a graft positioned horizontally and a screw, with at least two years of postoperative follow-up, were evaluated regarding quality of life, de novo dislocation index, and loss of lateral rotation.

Results The mean follow-up time was of 76 months (range: 129 to 24 months). The University of California at Los Angeles (UCLA) score varied from 25.56 ± 0.50 (standard deviation [SD] = 3.25) to 33.23 ± 0.44 (SD = 2.91) ($p < 0.0001$). Two or more years after surgery, the mean Rowe score was of 94.25 ± 1.52 (SD = 1.34), whereas the good results standard is 75 ($p < 0.0001$). The mean value for the simple shoulder test was of 11.35 ± 0.21 (SD = 1.34), while the mean value of the lateral rotation loss was of $10.37^\circ \pm 1.36^\circ$ (SD = 8.58°). There were no de novo dislocations.

In total, there were 12 complications, 8 of which had no clinical repercussions. The clinically-significant complications included an infection six months after surgery with a potential hematogenous origin, a coracoid fracture that required an intraoperatively procedure change, and two patients with previous impingement who required synthesis material removal more than six months after surgery.

Conclusion Although the arthroscopic Bristow procedure was effective in treating anterior shoulder instability, it is not a complication-free surgery.

Keywords

- ▶ orthopedic procedures
- ▶ shoulder instability
- ▶ shoulder dislocation
- ▶ arthroscopy

* Work developed at the Shoulder Group, Núcleo Avançado de Estudos em Ortopedia e Neurocirurgia (NAEON), São Paulo, São Paulo, Brazil.

received
January 21, 2019
accepted
July 18, 2019
published online
December 13, 2019

DOI <https://doi.org/10.1055/s-0039-1697972>.
ISSN 0102-3616.

© 2019. Sociedade Brasileira de Ortopedia e Traumatologia. All rights reserved.
This is an open access article published by Thieme under the terms of the Creative Commons Attribution-NonDerivative-NonCommercial-License, permitting copying and reproduction so long as the original work is given appropriate credit. Contents may not be used for commercial purposes, or adapted, remixed, transformed or built upon. (<https://creativecommons.org/licenses/by-nc-nd/4.0/>)
Thieme Revinter Publicações Ltda., Rua do Matoso 170, Rio de Janeiro, RJ, CEP 20270-135, Brazil

Resumo

Objetivo O procedimento de Bristow aberto é um método há muito estabelecido e eficaz no tratamento da instabilidade anterior do ombro. Seguindo as tendências das cirurgias minimamente invasivas, essa cirurgia foi realizada por artroscopia, e seus resultados foram avaliados.

Métodos Foram avaliados 43 ombros de pacientes submetidos ao procedimento de Bristow por artroscopia, com o enxerto em posição horizontal e uso de um parafuso, com pelo menos dois anos de seguimento pós-cirúrgico, por meio de escores qualidade de vida, índice de relaxação e perda de rotação lateral.

Resultados A média de seguimento foi de 76 meses (variando de 129 a 24 meses), o escore da University of California at Los Angeles (UCLA) variou de $25,56 \pm 0,50$ (desvio padrão [DP] = 3,25) para $33,23 \pm 0,44$ (DP = 2,91) ($p < 0,0001$). A média com 2 anos ou mais de cirurgia para o escore de Rowe foi de $94,25 \pm 1,52$ (DP = 1,34), sendo que o padrão de bons resultados é de 75 pontos ($p < 0,0001$). A média do teste simples de ombro foi de $11,35 \pm 0,21$ (DP = 1,34), e, para perda de rotação lateral, foi de $10,37^\circ \pm 1,36^\circ$ (DP = 8,58°). Não houve relaxações.

Entre os 43 pacientes operados, ocorreram um total de 12 complicações, das quais 8 não apresentaram qualquer repercussão clínica. As complicações com repercussão clínica foram uma infecção de possível origem hematogênica seis meses após a cirurgia, uma fratura do coracoide que fez com que o paciente precisasse mudar o procedimento no intraoperatório, e dois pacientes com impacto anterior, que necessitaram de retirada de material de síntese mais de seis meses após a cirurgia.

Conclusão O procedimento de Bristow artroscópico mostrou eficácia no tratamento da instabilidade anterior do ombro, embora não seja livre de complicações.

Palavras-chave

- ▶ procedimentos ortopédicos
- ▶ instabilidade do ombro
- ▶ luxação do ombro
- ▶ artroscopia

Introduction

Anterior instability is one of the most common orthopedic conditions in shoulder surgery, with up to 23.9 cases per 100,000 people per year at the United States.¹

Among the surgical techniques to treat this condition, one of the most effective and well-established is the coracoid process and conjoined tendon transfer to the anterior glenoid border.²

It is speculated that this procedure was performed by Bristow before 1929;³ however, greater technical details were only reported in 1958 by Helfet,⁴ who described in length the technique he had learned in 1939 from Bristow himself. In 1954, Michel Latarjet⁵ established the modern concepts of this surgery using a screw to fix the coracoid process and the possible subscapularis opening. Patte et al⁶ disseminated this technique in continental Europe in the 1980s using two 4.5-mm screws for graft fixation in a vertical position.

The technique of coracoid process and conjoined tendon transfer to the anteroinferior border of the glenoid cavity was modified many times, but all alterations respected the basic principles of triple blockade: bone block by the coracoid process, increased tension at the inferior portion of the subscapularis muscle, and direct block by the conjoined tendon.⁷ Several of these modifications were successful, but also had known complications, including loss of lateral rotation, osteoarthritis, pain, musculocutaneous nerve damage and pseudarthrosis.⁸

These complications resulted in many surgeons abandoning this procedure in favor of labral reconstruction, especially with the technological evolution of arthroscopy.

Recently, the continuous evolution of minimally-invasive methods allowed this procedure to be performed consistently by arthroscopy with arthroscopic Latarjet.⁷ The intra-articular view allows the surgeon to better position the graft, minimizing complications such as osteoarthritis and instability. Insertion under intra-articular view also ensures the presence of the medullary cavity in contact areas, improving osteointegration.^{7,9,10}

However, this approach required new instruments with increased surgical costs.

In 2009, a new arthroscopic surgical technique that enabled the coracoid process and conjoined tendon graft transfer through a minimally-invasive approach, with no costs resulting from the use of new special materials, was published. In this technique, the graft is inserted horizontally into the anterior border of the glenoid cavity using common arthroscopy materials, a small malleolar screw and a washer, a technique known as the Bristow procedure.¹¹

The present study describes the outcomes of at least two years of follow-up of 43 patients submitted to the Bristow procedure to treat anterior shoulder instability.

Methods

From September 2007 to December 2016, 48 patients underwent surgical procedures for anterior shoulder instability

treatment using the arthroscopic Bristow technique with horizontal graft. All procedures were performed by the same surgeon. This is a retrospective study, and the preoperative evaluation is considered as the baseline.

The first three patients were not submitted to preoperative or postoperative score determination with a follow-up period longer than two years; data from two other patients were lost.

The remaining 43 patients met the following inclusion criteria, and were evaluated in the present study.

Inclusion Criteria

The inclusion criteria were: patients over 18 years old; with follow-up period of at least two years; with Bankart bone lesion with glenoid loss greater than 20% (assessed by magnetic resonance imaging [MRI] or computed tomography [CT] according to the percentage loss of circumference diameter of the lower glenoid cavity toward its largest axis of bone loss); humeral avulsion of the glenohumeral ligament (HAGHL); failure of previous arthroscopic Bankart surgery; instability severity index greater than 6; and competitive, contact sport athletes with any bone loss.¹²

Exclusion Criteria

The exclusion criteria were: patients without baseline assessment data; patients whose preoperative data were lost or who were followed up for less than two years after surgery; those who did not agree with the evaluation; patients under 18 years old or from vulnerable populations; and patients submitted to other previous surgeries, except for arthroscopic Bankart procedures.

Scores and Measurements

The following scores and measurements were assessed:

Modified University of California at Los Angeles (UCLA) score: although initially designed to assess shoulder arthroplasty outcomes, it was modified for use in other orthopedic shoulder conditions.¹³

Simple shoulder test (SST): one of the most recognized tests in the functional evaluation of the shoulder.

Rowe score: created only for postoperative evaluation, its results must be compared with cutoff values of 75 and 90, indicating good and optimal results respectively.

Loss of lateral rotation with adducted arm: the baseline was determined at the preoperative evaluation. Goniometry was performed manually; data were recorded at 5° intervals, and differences were reported.

Elevation: losses greater than 10° were reported.

Evaluations

The patients were assessed at baseline by lateral rotation measurement and the UCLA score. Two years or more after surgery, the patients were evaluated regarding lateral rotation, elevation, UCLA, SST and Rowe values.

The postoperative evaluations included radiographic examinations in every patient. Postoperative CT scans were restricted to those patients with suspected complications.

Statistical Analysis

The statistical analysis was performed using the Stata 15 (StataCorp., College Station, TX, US) software for Mac.

Data were tested for normality and evaluated according to their statistical nature using two-tailed curves and values of $p < 0.05$. Data were evaluated regarding intention-to-treat (ITT) whenever possible.¹⁴ The interim sample size analysis was performed by verifying its statistical power.

The causes for patient withdrawal from the study were reported.

Surgical Technique

The patients are placed in the beach chair position under general anesthesia, and a standardized four-portal surgical technique is used. These portals are a posterior portal, an anterolateral portal, a portal just above the coracoid process, and an anteromedial trans-subscapular portal; the placement of the last two portals is aided by an intravenous catheter measuring 2.1 × 45 mm to ensure the best position (►Fig. 1).¹¹

With the optics at the posterior portal, the subscapularis muscle tendon is open broadly following fiber direction with a strong Kelly forceps, electrocautery, and shaver through the anteromedial trans-scapular portal (►Fig. 2). The rotator interval and the origin of the coracoacromial ligament at the superolateral border of the coracoid process are removed with electrocautery and shaver. The glenoid cavity is enlarged by inserting the shaver through the anterolateral portal. Then, using the anteromedial trans-scapular portal, the drill passes through the open space in the subscapularis tendon and touches the border of the anteroinferior glenoid cavity. The optics is moved to the anterolateral portal for better viewing, and a hole is made 5 to 6 mm medial to the anterior edge of the glenoid cavity.¹⁵ The size of this hole is measured. The optics is removed from the intra-articular space and placed at the anterior subdeltoid; then, the pectoralis minor tendon is released by electrocauterization through the portal located above the coracoid process, and the osteotomy of the coracoid process is performed with a microsaw and osteotomes. The use of the Kocher forceps previously inserted into the conjoined

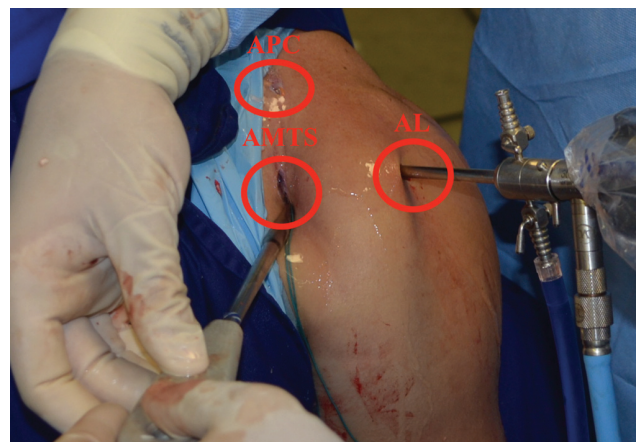

Fig. 1 Portals: APC, portal above the coracoid process; AMTS, anteromedial trans-subscapular portal; AL, anterolateral portal.

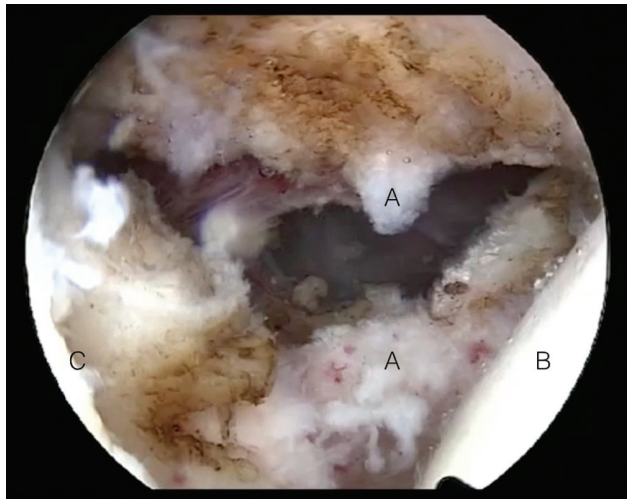


Fig. 2 Arthroscopic image of the shoulder showing the opening of the subscapularis tendon. A) subscapular B) humerus C) glenoid cavity.

tendon through the anteromedial portal can facilitate its exteriorization (►Figs. 3 and 4). The size of the 3.5 mm malleolar screw must be the sum of the glenoid cavity depth and the measured graft size after exteriorization through the anteromedial portal. A washer must always be used in this procedure.

Then, a #5 multifilament nylon suture or a #2 high-strength suture is placed between the washer and the screw head to pull it against the key, preventing the screw from coming off the key, and securing the graft in the glenoid cavity through the opening made in the subscapularis tendon (►Figs. 5 and 6). A Kocher forceps is inserted through the portal located above the coracoid process, with a slight compression, to control graft rotation during fixation.

If the graft has an articular step, the bone shaver can be used to even it.

Increasing screw torque does not necessarily mean that the graft is properly secured; to test screw tightness, a probe must be used to verify whether the washer is loose or secure.

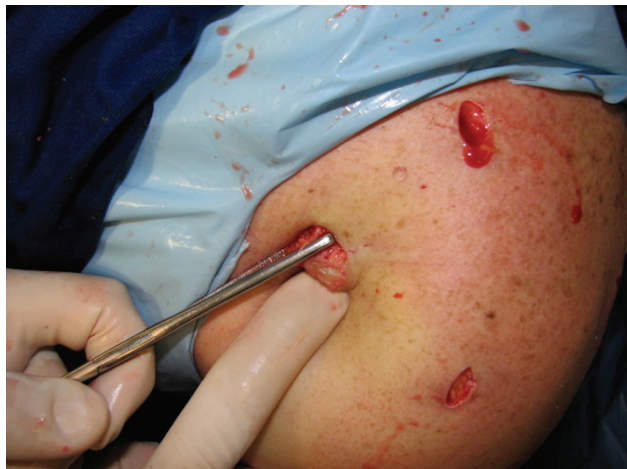

Fig. 3 Image of the left shoulder with the coracoid process externalized with the aid of a Kocher forceps.

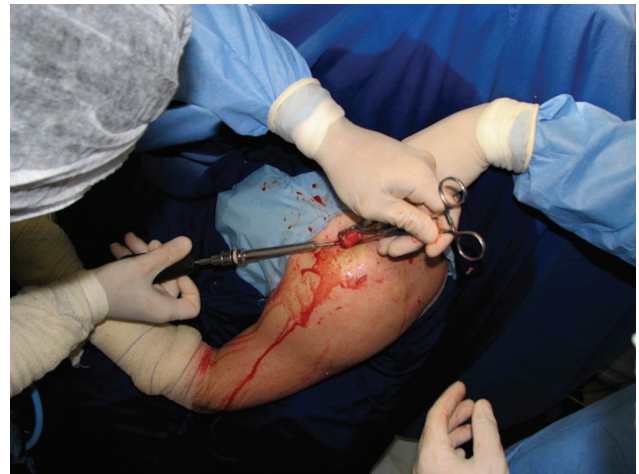

Fig. 4 Screw passing through the externalized coracoid process graft.

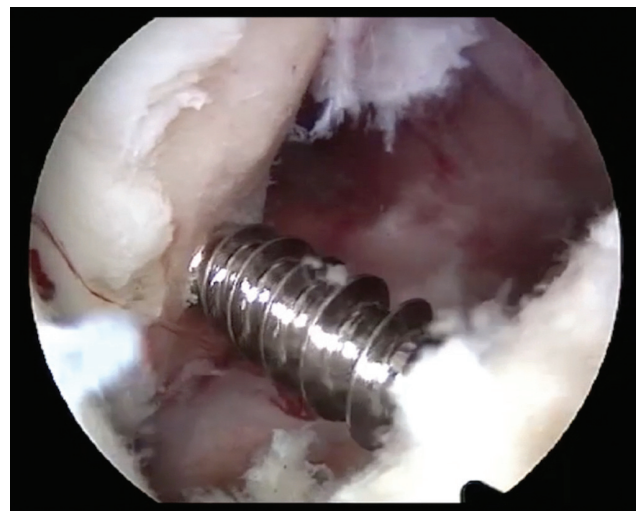

Fig. 5 Arthroscopic image of the shoulder showing the fixation in the anterior glenoid cavity; the arthroscope is in the anterolateral portal.

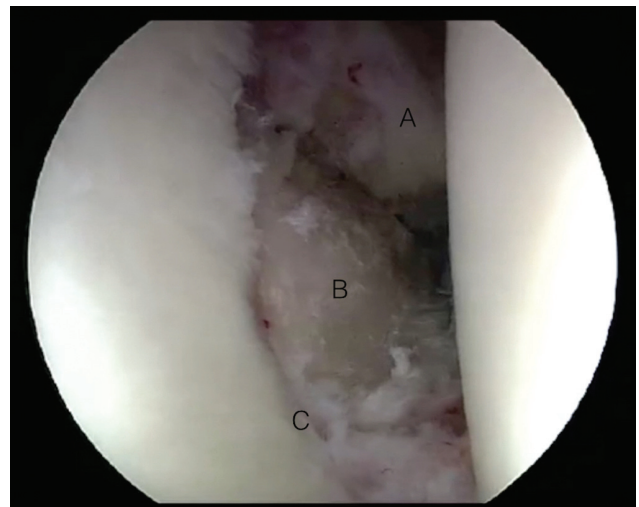


Fig. 6 Arthroscopic image of the shoulder showing the final fixation of the coracoid process graft in the anterior glenoid cavity; the arthroscope is in the posterior portal. A) subscapular B) inserted coracoid process C) glenoid cavity.

Results

Out of 43 patients evaluated at baseline, 3 could not be assessed postoperatively. With the baseline data, these patients were maintained in the sample, and their scores were copied from the baseline to the two-year assessment (ITT) to avoid any bias that might favor the procedure.

The evaluated group consisted of 42 men and 1 woman with a mean age of 32.88 years (18–60 years); the left side was affected in 15 patients, whereas the right side was affected in 28 patients. The median follow-up time was 76 months (range: 129–24 months).

The causes for these procedures were the following: 28 patients had Bankart bone lesions with at least 20% of bone loss; 1 individual had HAGHL; 9 patients had a history of previous failed Bankart procedures; and 5 patients presented an instability severity index greater than 6.

The mean UCLA, Rowe, lateral rotation loss and TSO values for these 43 patients (ITT) are summarized in ►Table 1.

The data presented statistically consistent results.¹⁶

There were no elevation differences greater than 10° regarding the contralateral side, except for 2 cases.

The medial rotation was not evaluated; however, 10 out of 40 patients had discomfort and disability during the extremes of this movement (SST, question 11).

Intraoperative Complications (43 Patients)

There were two coracoid process fractures, including an incomplete lesion submitted to coracoid process cerclage with #5 multifilament nylon and an arthroscopic Bristow procedure. The other fracture was complete and multifragmented, so we opted for an arthroscopic conjoined tendon tenodesis in the anterior portion of the trans-scapular glenoid cavity, with excellent long-term functional outcome. This last patient was one of the three who could not be evaluated postoperatively, since he was not submitted to the procedure under study.

No paresis, paresthesia or nerve damage occurred in either case.

Postsurgical Complications (40 Patients)

There were three pseudarthroses without clinical repercussions.

An 8.84° screw twist occurred in the medial direction of the axial plane without clinical repercussions, since the graft consolidated even after twisting.

There were four osteolyses, three without clinical repercussions and one requiring screw removal. Osteoarthritis was present in three patients; in two of them, the condition was moderate, and in one, it was deemed initial according to the classification by Samilson and Prieto.¹⁷ Two of these patients already had moderate osteoarthritis before the surgical procedure.

One patient had an infection with a potential hematogenous origin six months after the procedure. Anterior impingement was observed in two patients, including one with associated graft osteolysis, and both required synthesis material removal. There were no subdislocations or de novo dislocations after the procedure.

Concomitant lesions were treated in four patients, including three superior labral anterior and posterior (SLAP) lesions and one cuff injury.

In total, there were 12 complications, 8 of which had no clinical repercussions. Complications with repercussions included infection six months after surgery with potential hematogenous origin, a coracoid fracture requiring an intra-operatively procedural change, and two patients with previous impingement who required synthesis material removal more than six months after surgery. These four patients with complications presented good responses to the instituted treatments, with clinical improvement, except for the patient with infection, who presented the worst functional outcomes in this series.

The interim analysis of the sample size showed an adequate size considering a significance level of 0.001, with 99% of statistical power.^{18,19}

Discussion

Recent changes in coracoid process transfer procedures have been reported, enabling its performance by arthroscopy.^{7,9,10}

The advantages of the arthroscopic method include the following: better visualization of the graft insertion site; possibility of correction of articular steps under visualization; intra-articular visualization of the graft to ascertain its correct location; the ability to test lateral rotation under articular visualization; possible concomitant treatment of other injuries; reduced adhesions; and improved cosmesis.^{1,7} The disadvantages are the increased costs related to arthroscopy, the lengthy learning curve, and the need for specific training.⁷

Table 1 Comparison of the values of the UCLA score, the Rowe score, the simple shoulder test and loss of lateral rotation

	Baseline (\pm standard deviation or cutoff values for good/excellent results)	> 2 years postsurgery (\pm standard deviation)	p-value	n
UCLA	25.56 \pm 0.50	33.23 \pm 0.44	< 0.0001	43
Rowe	75 (good results)	94.25 \pm 1.52	< 0.0001	40
Rowe	90 (excellent results)	94.25 \pm 1.52	0.0082	40
SST	—————	11.35 \pm 0.21	—	40
Loss of lateral rotation	—————	10.37 \pm 1.36	—	40

Abbreviations: SST, simple shoulder test; UCLA, University of California at Los Angeles.

Coracoid process fractures were the worst complication from this procedure (three cases). Edwards and Walch²⁰ suggest a two-finger technique, in which the screw torque is performed with only the thumb and the index finger, avoiding excessive screw torque over the graft. Washer visualization and test, in which the probe is run over the washer to make sure it is fixed, can also increase the safety of the procedure, as in some cases the increased torque felt on the key may not be due to graft compression, but to the fixation in the contralateral cortex. As for size, a 3.5-mm non-cannulated screw and washer appear to be the most suitable option. The aforementioned precautions ended coracoid process fractures in the present series. In cases of fracture in which cerclage is not possible or feasible, the author suggests a conjoined tendon tenodesis in the anterior portion of the glenoid cavity with anchors.

Cadaveric studies have not found significant biomechanical differences between conjoined tendon tenodesis and coracoid process and conjoined tendon osteosynthesis, suggesting that there is no need for bone block to achieve shoulder stability in surgical procedures.^{21,22} It is reported that shoulder stability may be more closely linked to soft tissue passive and active mechanisms that are difficult to measure.²³

In fact, neither the Bristow nor the Latarjet procedures, as originally described, have enough bone to produce the bone-blocking effect. In the Bristow procedure described by Helfet, the coracoid process is sutured to the anterior portion of the glenoid, whereas in the Latarjet procedure, the coracoid process is osteotomized before the insertion of the pectoralis minor, completely preserving this muscle attachment, and the graft is very small.^{4,5}

Although the bone-blocking effect certainly added stability to the procedure in the modern Bristow and Latarjet variations, this benefit may only be perceived in patients with Hill-Sachs lesions in a region located at a distance from the cuff attachment that is greater to or equal than the original diameter of the glenoid cavity minus the bone loss times 0.83.²⁴

The literature discusses the ideal screw diameter for coracoid transfers. Walsh and Boileau use 4.5-mm screws²⁵; Burkhart et al²⁶ and Di Giacomo et al²⁷ use 3.75-mm cannulated screws; and Lafosse et al⁷ use 3.5-mm screws. All of these authors use vertically-oriented grafts. In the technique presented in the present study, the screw diameter will depend on the physical characteristics of the patient, but there is a clear preference for non-cannulated 3.5-mm screws with washers.

Walsh and Boileau²⁵ do not recommend using washers because of the large size of the screws and the proximity to the washer when the graft is left upright. In this procedure, which is performed with a smaller screw, the use of a washer resulted in mechanical benefits, and it is recommended for two reasons: for load distribution and because it is a test option in case of doubt whether the screw tightness comes from the torque against the contralateral cortex or actual graft compression.

In the arthroscopic Bristow procedure, graft osteolysis was only observed in three cases, and none in the last 15 patients. Since osteolysis can be associated with compression

forces imposed on the graft, perhaps the two-finger fixation methods and the washer testing have been instrumental in these outcomes.²⁷ However, there is a potential bias because postoperative evaluations were performed by radiographs alone, leaving CT scans for cases in which possible complications were suspected.

A case of impinged osteolysis required screw excision.²⁸

Even with only 1 case of synthesis material removal, 11 out of 40 patients answered “no” or “discomfort” to question 11 of the SST. As such, some impingement may be underestimated by this series. The author accepts that there may be an impingement, with no or low clinical repercussions, on 27.5% patients. Screw removal was required in 2 of the 11 patients with impingement. The impingement may be associated with the graft angle, which must be perpendicular to the fracture line and preferably not greater than the continuity angle of the glenoid cavity circumference. Direct and dynamic visualization through the intra-articular space gives the surgeon a greater control for graft positioning, avoiding articular steps. The author suggests that graft size and obliquity are determining factors in both impingement and effective glenoid depth.²⁹

In the present study, the reoperation rate was of 5%, which is similar to the one previously reported for open procedures.⁸

Two patients already had osteoarthritis before the procedure, and only one case presented new radiographic signs. This low rate of osteoarthritis may be associated with the direct visualization that enables intraoperative corrections to prevent articular steps.

The absence of an articular step reduces the load on the graft because there is no mechanical stress point, resulting in no significant changes in the pressure over the superior-posterior glenoid quadrant.¹⁰ It has been shown that not only graft lateralization, but also its medialization, are associated with postoperative complications. Medialization greater than 5 mm is associated with higher recurrence rates of shoulder instability.³⁰ The better intra-articular evaluation of the arthroscopic fixation region may be a positive factor to avoid this complication.

So far, since there are no recurrences of instability and the follow-up of quality of life shows statistically significant results, it is possible to affirm the effectiveness of the technique.

In the present study, three pseudarthroses were observed, but none had clinical repercussions, which is consistent with the literature. The amount of pseudarthroses may be underestimated because the follow-up was mostly performed with conventional radiographs, which can make this diagnosis difficult.

The author suggests that the use of a single screw is sufficient to fix the coracoid process. Hovelius et al³⁰ reported 11 de novo dislocations in 319 shoulders, that is, a 3% rate, after the open Bristow procedure. Of these patients, 13% had pseudarthrosis; however, the fibrous union was enough to prevent recurrences. De novo dislocations were more associated with graft medialization than with pseudarthroses.³⁰

The absence of de novo dislocations in the present study may be associated with a better graft positioning, improving

the contact of the scarified area of the anterior glenoid cavity with the graft cancellous bone in horizontal position; however, the sample is too small to suggest such conclusions. Low recurrence rates, close to 1%, in more than 2,346 open surgical procedures, are cited in the literature; the results of the present study suggest this same trend of good results for the arthroscopic procedure.³¹

Lower de novo dislocation rates are not associated with the use of two screws in similar techniques.^{26,32}

The postsurgical alteration of the musculocutaneous nerve has not been observed, despite its 0.7% incidence in the literature.¹⁰ Even with no neurological impairment, the author suggests larger series in order to draw any conclusions regarding the superiority of the neurological safety of the procedure.

The procedure resulted in the same length of hospital stay as other similar arthroscopic surgeries, with a significant economic advantage due to the exclusive use of basic arthroscopy materials, a small fragment screw and a washer.

Conclusion

The arthroscopic Bristow procedure showed extremely significant effectiveness in the treatment of anterior shoulder instability; however, it is not a complication-free procedure, with a 9% complication rate in the present series.

Conflicts of Interest

The author is a consultant for Zimmer-Biomet.

References

- Zacchilli MA, Owens BD. Epidemiology of shoulder dislocations presenting to emergency departments in the United States. *J Bone Joint Surg Am* 2010;92(03):542–549
- Boileau P, Villalba M, Héry JY, et al. Risk factors for recurrence of shoulder instability after arthroscopic Bankart repair. *J Bone Joint Surg Am* 2006;88(08):1755–1763
- Page CM, Bristow WR. The treatment of fractures and dislocations in general practice. 3rd ed. Oxford: Oxford Medical Publications; 1929
- Helfet AJ. Coracoid transplantation for recurring dislocation of the shoulder. *J Bone Joint Surg Br* 1958;40-B(02):198–202
- Latarjet M. A propos du traitement des luxations récidivantes de l'épaule. *Lyon Chir* 1954;49(08):994–997
- Patte D, Bernageau J, Rodineau J, et al. [Unstable painful shoulders (author's transl)]. *Rev Chir Orthop Repar Appar Mot* 1980;66(03):157–165
- Lafosse L, Lejeune E, Bouchard A, et al. The arthroscopic Latarjet procedure for the treatment of anterior shoulder instability. *Arthroscopy* 2007;23(11):1242.e1–1242.e5
- Griesser MJ, Harris JD, McCoy BW, et al. Complications and re-operations after Bristow-Latarjet shoulder stabilization: a systematic review. *J Shoulder Elbow Surg* 2013;22(02):286–292
- Boileau P, Bicknell RT, El Fegoun AB, et al. Arthroscopic Bristow procedure for anterior instability in shoulders with a stretched or deficient capsule: the "belt-and-suspenders" operative technique and preliminary results. *Arthroscopy* 2007;23(06):593–601
- Nourissat G, Nedellec G, O'Sullivan NA, et al. Mini-open arthroscopically assisted Bristow-Latarjet procedure for the treatment of patients with anterior shoulder instability: a cadaver study. *Arthroscopy* 2006;22(10):1113–1118
- Garcia JC, Garcia JPM, Mattos CA, et al. Arthroscopic Bristow-Latarjet-Like procedure: Surgical technique. *Tech Shoulder Elbow Surg* 2009;10:94–98
- Balg F, Boileau P. The instability severity index score. A simple pre-operative score to select patients for arthroscopic or open shoulder stabilisation. *J Bone Joint Surg Br* 2007;89(11):1470–1477
- Romeo AA, Bach BR Jr, O'Halloran KL. Scoring systems for shoulder conditions. *Am J Sports Med* 1996;24(04):472–476
- Streiner D, Geddes J. Intention to treat analysis in clinical trials when there are missing data. *Evid Based Ment Health* 2001;4(03):70–71
- Young AA, Baba M, Neyton L, et al. Coracoid graft dimensions after harvesting for the open Latarjet procedure. *J Shoulder Elbow Surg* 2013;22(04):485–488
- Pocock SJ. When to stop a clinical trial. *BMJ* 1992;305(6847):235–240
- Samilson RL, Prieto V. Dislocation arthropathy of the shoulder. *J Bone Joint Surg Am* 1983;65(04):456–460
- Harmonised Tripartite Guideline ICH. Statistical principles for clinical trials (E9). 1998. Available at: http://www.ich.org/fileadmin/Public_Web_Site/ICH_Products/Guidelines/Efficacy/E9/Step4/E9_Guideline.pdf
- Peacock JL, Peacock PJ. Sample size for comparative studies: means. In: Peacock JL, Peacock PJ, editors. *Oxford handbook of medical statistics*. 3rd ed. Oxford: Oxford University Press; 2011
- Edwards TB, Walch G. The Latarjet procedure for recurrent anterior shoulder instability: rationale and technique. *Oper Tech Sports Med* 2002;10(01):25–32
- Thomas PR, Parks BG, Douoguih WA. Anterior shoulder instability with Bristow procedure versus conjoined tendon transfer alone in a simple soft-tissue model. *Arthroscopy* 2010;26(09):1189–1194
- Yamamoto N, Muraki T, An KN, et al. The stabilizing mechanism of the Latarjet procedure: a cadaveric study. *J Bone Joint Surg Am* 2013;95(15):1390–1397
- Panchal AP, Osbahr DC, Douoguih W, et al. Conjoined tendon transfer vs modified Bristow in a glenoid bone loss model: A biomechanical study. *Orthop J Sports Med* 2013;1(4 Suppl):2325967113S00012
- Yamamoto N, Itoi E, Abe H, et al. Contact between the glenoid and the humeral head in abduction, external rotation, and horizontal extension: a new concept of glenoid track. *J Shoulder Elbow Surg* 2007;16(05):649–656
- Walsh G, Boileau P. Latarjet-Bristow procedure for recurrent anterior instability. *Tech Shoulder Elbow Surg* 2000;1:256–261
- Burkhart SS, De Beer JF, Barth JR, et al. Results of modified Latarjet reconstruction in patients with anteroinferior instability and significant bone loss. *Arthroscopy* 2007;23(10):1033–1041
- Giacomo GD, Costantini A, de Gasperis N, et al. Coracoid bone graft osteolysis after Latarjet procedure: A comparison study between two screws standard technique vs mini-plate fixation. *Int J Shoulder Surg* 2013;7(01):1–6
- Ghodadra N, Gupta A, Romeo AA, et al. Normalization of glenohumeral articular contact pressures after Latarjet or iliac crest bone-grafting. *J Bone Joint Surg Am* 2010;92(06):1478–1489
- Lippitt SB, Vanderhooft JE, Harris SL, et al. Glenohumeral stability from concavity-compression: A quantitative analysis. *J Shoulder Elbow Surg* 1993;2(01):27–35
- Hovellius L, Sandström B, Olofsson A, et al. The effect of capsular repair, bone block healing, and position on the results of the Bristow-Latarjet procedure (study III): long-term follow-up in 319 shoulders. *J Shoulder Elbow Surg* 2012;21(05):647–660

- 31 Garcia JC Jr, do Amaral FM, Belchior RJ, et al. Comparative Systematic Review of Fixation Methods of the Coracoid and Conjoined Tendon in the Anterior Glenoid to Treat Anterior Shoulder Instability. *Orthop J Sports Med* 2019;7(01):2325967118820539
- 32 Collin P, Rochcongar P, Thomazeau H. [Treatment of chronic anterior shoulder instability using a coracoid bone block (Latarjet procedure): 74 cases]. *Rev Chir Orthop Repar Appar Mot* 2007;93(02):126-132