



Original Article

Treatment of chronic patellar ligament lesion with autograft and v-y quadricepsplasty

Marco Túlio Lopes Caldas,^{1,*} Tiago Jacques Gonçalves,² Gustavo Henrique Silva Bárbara,³ Rafael Alves Rodrigues,⁴ Victor Rocha Figueiredo,⁴ Jaider Parreiras de Paulo⁵

¹Coordinator of the Medical Residency Service in Orthopedics and Traumatology, Hospital Maria Amélia Lins, da Fundação Hospitalar do Estado de Minas Gerais (FHEMIG), Belo Horizonte, MG, Brazil.

²Preceptor of the Medical Residency in Orthopedics and Traumatology, Hospital Maria Amélia Lins (FHEMIG), Belo Horizonte, MG, Brazil.

³Resident Physician (R4) in Knee, Hospital Maria Amélia Lins (FHEMIG), Belo Horizonte, MG, Brazil.

⁴Resident Physician (R4) in Knee, Clínica Ortolife, Belo Horizonte, MG, Brazil.

⁵Resident Physician (R2) in the Orthopedics and Traumatology Service, Hospital Maria Amélia Lins (FHEMIG), Belo Horizonte, MG, Brazil. Research carried out in the Hospital Maria Amélia Lins, which belongs to the Fundação Hospitalar do Estado de Minas Gerais (FHEMIG), Belo Horizonte, MG, Brazil.

ARTICLE INFO

Article history:

Received on July 1, 2012

Accepted on August 14, 2012

Keywords:

Knee/therapy

Knee/surgery

Patellar ligament

A B S T R A C T

Objective: Review of the literature concerning the subject and to compare the results of the technique we have been using with the ones reported on the literature. **Methods:** This is a retrospective, cross-sectional and observational study. We evaluated the records of patients treated surgically at the Hospital from Hospital Maria Amélia Lins January 1997 to January 2011. The following variables were considered: age, gender, side, degree of injury, mechanism of trauma, associated injuries, time elapsed between injury and surgical procedure, complications, range of motion and muscle strength. **Results:** Five patients underwent surgical treatment with the use of autograft semitendinosus and gracilis tendons and V-Y quadricepsplasty. Regarding gender, there was a male predominance (80%). The average age was 35.2 years old. The right side was the most affected (60%). The predominant mechanism of injury was motorcycle accident (80%). All patients had a complete tendon lesion. Time between injury and surgery averaged 10.4 months. Four patients (80%) had had associated injuries. In all patients muscle strength was satisfactory (M4/M5). Wound dehiscence was observed in 01 patient. Average postoperative range of motion was 110°. **Conclusions:** These are rare lesions. Stretching the quadriceps is essential to decrease the tension to the reconstructed patellar ligament and patellofemoral joint. Use of a quadriceps transtendon tunnel is an option to prevent fractures. Hypotrophy of the quadriceps is inevitable, however, the resulting force is sufficient for daily living activities.

© 2013 Sociedade Brasileira de Ortopedia e Traumatologia. Published by Elsevier Editora Ltda. All rights reserved.

*Corresponding author at: Rua Flavita Bretas, 29/901, Luxemburgo, Belo Horizonte, MG, Brazil. CEP: 30380-410.

E-mail: mtuliolc@gmail.com

Introduction

Although rarely mentioned in the literature (there is no registry of the lesion before 1933), patellar ligament rupture is frequently associated with trauma following total knee arthroplasty, patellar tendinitis and a series of diseases, such as systemic lupus erythematosus, osteomalacia, secondary hyperthyroidism and Osgood Schlatter disease.¹⁻⁶ There are also reports of ruptures following local steroid injection.⁷

Acute lesions are not difficult to diagnosis clinically. Usually, the patient complains of intense pain and being unable to walk. Local swelling occurs, usually located at the inferior pole of the patella, as well as the high-riding patella, and is painful during palpation. Patient generally cannot straighten their legs, but if they can, this is a sign of partial rupture.⁸ Only occasionally are the lesions not noticed. There are few reports about the treatment of chronic lesions in the literature.⁹

Treating chronic ruptures is difficult due to the inadequate soft tissues resulting from retraction and reabsorption.⁸ Kelikian et al.¹⁰ used a semitendinosus tendon as a neoligament, by transferring it through the patella and the anterior tibial tuberosity (ATT). Ecker et al.⁹ transferred the semitendinosus and gracilis muscles through the patella and ATT supplemented with a reinforcement using metal threads.

Scott et al.¹¹ reported the use of calcaneal tendon allograft, still attached to a little bone block, which is inserted in the ATT. Marczyk et al.¹² described the reconstruction of the patellar ligament using an artificial ligament.

Zekcer et al.¹³ described the reinsertion of the patellar ligament through trans-bone points in the patella; this technique uses a semitendinosus tendon graft, which passes through the patella and the ATT.

For our medical service, we use tendons of the semitendinosus and gracilis muscles to reconstruct the chronic lesions of the patellar ligament. The semitendinosus tendon passes through the patella, and the gracilis tendon through the quadriceps tendon. Both are attached to the anterior tibial tuberosity. We associate the stretching of the V-Y quadricepsplasty with it.

This study of chronic lesions of the patellar ligament is motivated by the lack of published research. In addition, we aim to compare the results of our technique with those described in the literature.

Material and Methods

This is a retrospective, cross-sectional and observational study. All patients with a chronic lesion of the patellar ligament were treated surgically at the Hospital Maria Amélia Lins from January 1997 to January 2011.

Data were obtained by analyzing the patients' records and transferred to the research protocols by the researchers in charge.

The following variables were considered: age, gender, side, degree of injury (partial or total), trauma mechanism, associated injuries, elapsed time between injury and surgical procedure, complications, range of motion and muscle strength of the

quadriceps. The motor classification of patients created by Lucas and Ducker¹⁴ was used to evaluate muscle strength (Chart 1).

Statistical analyses were performed with the use of the Epi-Info 8.0 and SPSS 12.0 software. We used a significance level of 5%. However, it was not possible to calculate these statistics due to the sample size and because there was not another group available to compare results with. Another solution would be to use statistics to compare means, which was also not possible, as the variables of the study are discrete. Therefore, the best solution was to classify this study as a descriptive one.

The study was approved by the Research Ethics Committee of the institution.

Chart 1 - Lucas and Ducker index to assess muscular strength.

- 0 - Absence of contraction
- 1 - There is fasciculation but no motion
- 2 - There is motion in the horizontal plane, but it does not defeat gravity
- 3 - There is motion in the horizontal plane, it defeats gravity, but it does not defeat any type of resistance
- 4 - There is motion, and it defeats any type of resistance
- 5 - Normal muscle strength

Surgical Technique

The patient is placed on a surgical table in the supine position with a pneumatic tourniquet on the root of the thigh. The longitudinal incision is made in the anterior region of the knee, about 10 cm from the superior pole of the patella and to about 3 cm below the ATT. Dissection continues until the whole tendon of the rectus anterior muscle of the patella and that of the ATT are visible.

A longitudinal and medial surgical approach to the ATT was undertaken. Using a tenotomy procedure, we cut the semitendinosus and gracilis tendons (Fig. 1). Then, we stretched the quadriceps by using the V-Y technique (Fig. 2) and left the final suture for the period after the confirmation of the patellar height (with the aid of image intensifier or profile radiography). In the profile image of a knee with 30° degrees of flexion, the inferior pole of the patella should be located in the Blumensaat line.

Two transverse bone tunnels are made, one on the third of the region distal to the patella (5 mm in diameter) and the other at the level of the posterior ridge of the ATT (7 or 8 mm in diameter) (Figs. 3A e 3B). In addition, we make a transtendon tunnel in the suprapatellar region (Fig. 2).

The semitendinosus tendon is inserted in the patellar bone tunnel, and the gracilis tendon is inserted in the suprapatellar transtendon tunnel. We cross the gracilis tendon to fill in the central region of the future patellar ligament (Fig. 4). Both are inserted in the tibial bone tunnel and attached with an interference screw, after confirmation of the patellar height.

Finally, we use a 'protection handle' with non-absorbable threads (Ethibond® n. 5), and we trans-attach the patellar and

tibial tunnels (Fig. 5). We perform flexion-extension tests to confirm the stability of this reconstruction, and we place the suction drain and suture by planes. The knee in extension is immobilized with an aluminum splint and foam.

Patients begin to do isometric exercises on the second day after surgery and start to use crutches. Flexion begins at the end of the first week through exercises with the heel on the floor. Extension exercises begin on the 4th or 5th week and continue during the specialized rehabilitation. Immobilization is maintained for two to three weeks, and the splint is removed so that the patient can do the exercises.

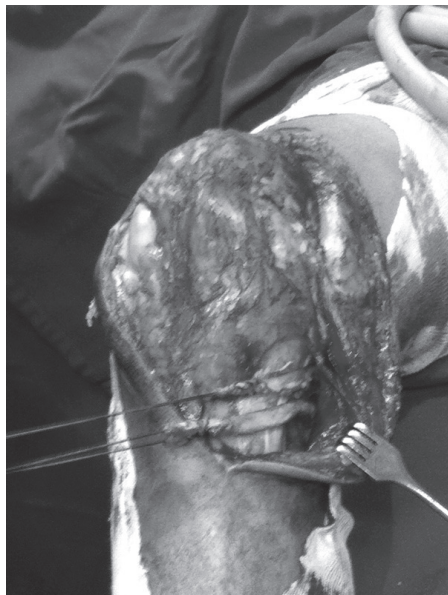

Fig. 1 - Ample anterior incision showing the semitendinosus and gracilis tendons repaired.

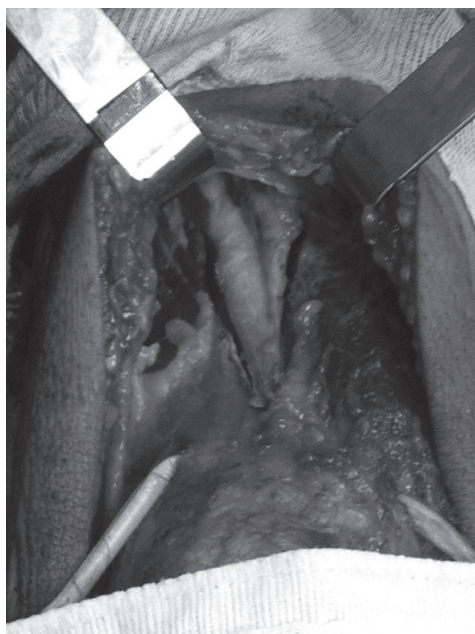


Fig. 2 - V-Y Quadricepsplasty. Below, we notice the tendon of the gracilis muscle passing through the transtendon tunnel.

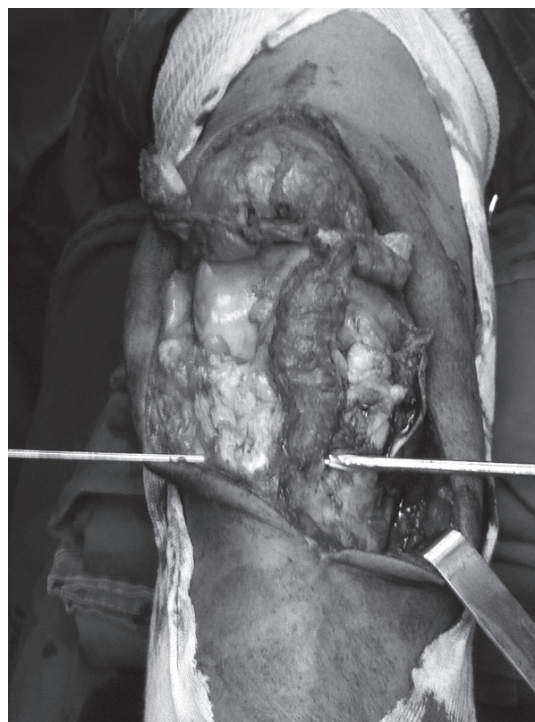
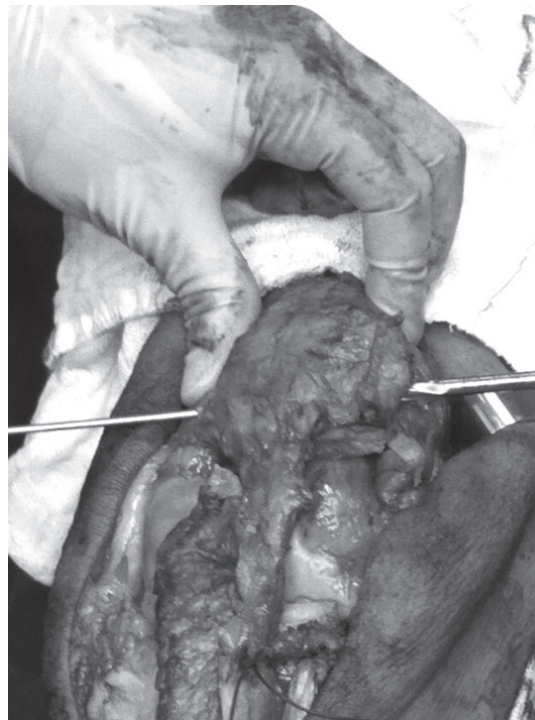
Fig. 3 - (A) Producing the patellar bone tunnel. (B) Producing the tibial bone tunnel.

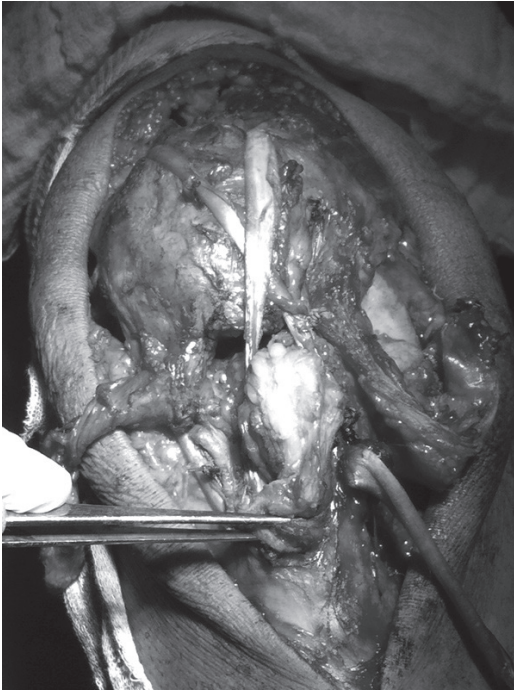

Fig. 4 - It should be noted that the tendon of the gracilis muscle is crossed to fill in the central region of the future patellar ligament.

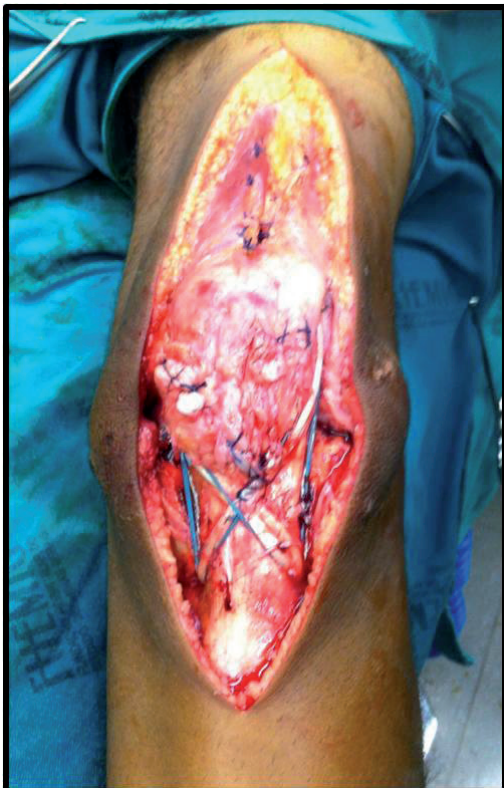

Fig. 5 - Final aspect of reconstruction.

Results

Five reports of patients with chronic lesion of the patellar ligament treated in our institution from January 1997 to January 2011 were evaluated. Of these patients, all of them underwent surgery with the use of semitendinosus and gracilis tendon autograft associated with V-Y quadricepsplasty.

Our results show a higher prevalence of males (80%). The mean age was 35.2 years (24 to 64). The most impaired side was the right one in 60% of the cases.

The most common lesion mechanism was motorcycle accident (80%). All patients presented with a total lesion of the patellar ligament.

Time between injury and surgery averaged 10.4 months (between six and 16 months). Four patients (80%) presented with associated injuries (Chart 2).

In all patients, muscle strength was considered satisfactory (m4/m5), despite the residual hypotrophy of the quadriceps. Wound dehiscence was observed in one patient (20%).

Extension limitation was not observed in any of the patients; however, three of them (60%) showed limited last flexion degrees. Average postoperative range of motion was 110°.

Chart 2 - Associated lesions in patients with chronic lesions of the patellar ligament.

Patient	Mechanism	Associated lesion
1	Motorcycle accident	Open fraction of leg bones
2	Fall on the same level	None
3	Motorcycle accident	Femur fracture, brachial lesion, thoracic, splenic and hepatic trauma
4	Motorcycle accident	Acetabular fracture and distal radio
5	Motorcycle accident	Diaphyseal femur fracture

Source: AOTP 1997/2011.

Discussion

Chronic lesions of the patellar ligament are rare and infrequently reported in the literature. Most of the researches consist of reports of one or two cases.⁹ From January 1997 to January 2011, five patients were surgically treated by our medical service. This may be explained by the fact that our medical service is a reference center for orthopedic trauma, and patients from all over the state are treated there.

Most of the patients were young men, who were polytraumatized. To our knowledge, this may be the main cause for a late diagnosis, as priority is given to the treatment of potentially fatal lesions in the emergency department. Rougraff et al.¹⁵ reported that the greatest factor contributing to a poor

prognosis for treating lesions of the extensor mechanisms was late surgical repair. According to the authors, week long delays jeopardize the quality of repair, yielding worse functional results. In our study, the average time between injury and surgery was 10.4 months.

A female patient with diabetes mellitus type II presented with a rupture after low energy trauma (a fall from the same level). Although the diagnosis was performed in the acute phase, the patient refused to undergo a surgical procedure and presented again 13 months after the lesion. According to Seijas et al.¹⁶, some metabolic changes cause microscopic damages to the vascular supply of the tendon and to its architecture. Diabetes mellitus is responsible for atherosclerotic changes in the tendinous vascularization, which would predispose the individual to a spontaneous rupture.

Various techniques to treat chronic lesions of the patellar ligament, including direct repair with trans-bone points associated with cerclage with steel thread and the use of allografts, autografts or even synthetic grafts, are described in the literature. Regardless of the technique, it is important to carefully maintain the normal patellar tracking in the trochlea, its height and its rotation.¹⁷

Ecker et al.⁹ used semitendinosus and gracilis tendon autografts, both of which passed by two trans-bone points through the patella. In our medical service, we made only one trans-bone point in the patella, where we introduced the semitendinosus. The gracilis is placed in a suprapatellar transtendon tunnel. We believe that by doing this, we reduce the chances of axial fracture of the patella while the bone tunnels are created, as most of the patients presented with patellar osteopenia.

One of the main problems of the chronic lesions of the patellar ligament is the retraction of the quadriceps, with the proximal migration of the patella.¹⁷ Thompson¹⁸ recommended lateral, medial and subquadriceps liberation; however, there is an increased risk of avascular necrosis of the patella, especially with medial liberation.

Shelbondy¹⁹ evaluated the patella height during surgery. During flexion with the knee at 30 degrees of flexion, the inferior pole should be at the level of the Blumensaat line. Otherwise, V-Y quadriceps stretching or a z-plasty would be performed. In the present study, all patients underwent V-Y quadriceps stretching with trans-operative radiological control. We believe that by doing this, we decrease the tension on the reconstructed patellar ligament and on the patellofemoral joint.

Loss of knee flexion and the reduction of the quadriceps strength are possible complications.¹⁹ Average postoperative range of motion was 110°. None of the patients presented an extension deficit. A similar result was found by Casey and Tietjens²⁰ in a series of four patients with a chronic lesion of the patellar ligament, in which the average range of motion was 112° with no extension deficit. These authors used multiple strands of strong cerclage wire, in a figure 8 pattern with three wires of 1.5 mm, between the quadriceps tendon and the ATT. In addition, according to the authors, this technique allows the use of autografts, which do not require muscular stretching.

Operative wound dehiscence was observed in one patient. According to Seidenstein et al.¹⁷, wound complications are

more common after the repair of the quadriceps tendons because the skin is less thick at the ATT level. Thus, it is recommended that the cutaneous incision be adjacent to and not directly over the ATT.

Conclusions

Chronic lesions of the patellar ligament are rare and are scarcely mentioned in the literature. We believe that quadriceps stretching is essential to decrease the tension on the reconstructed patellar ligament and on the patellofemoral joint. Using a quadriceps transtendon tunnel is an option to prevent axial fractures in patellas that are usually osteopenic. Hypotrophy of the quadriceps is inevitable; however, the resulting force is sufficient for daily living activities.

Conflict of Interest

The authors have no conflict of interest to declare associated with this paper.

REFERENCES

1. Bowers KD Jr. Patellar tendon avulsion as a complication of Osgood-Schlatter's disease. *Am J Sports Med.* 1981;9(6):356-9.
2. Emerson RH Jr, Head WC, Malinin TI. Reconstruction of patellar tendon rupture after total knee arthroplasty with an extensor mechanism allograft. *Clin Orthop Relat Res.* 1990;(260):154-61.
3. Kricun R, Kricun ME, Arangio GA, Salzman GS, Berman AT. Patellar tendon rupture with underlying systemic disease. *AJR Am J Roentgenol.* 1980;135(4):803-7.
4. Lynch AF, Rorabeck CH, Bourne RB. Extensor mechanism complications following total knee arthroplasty. *J Arthroplasty.* 1987;2(2):135-40.
5. Rand JA, Morrey BF, Bryan RS. Patellar tendon rupture after total knee arthroplasty. *Clin Orthop Relat Res.* 1989;(244):233-8.
6. Wener JA, Schein AJ. Simultaneous bilateral rupture of the patellar tendon and quadriceps expansions in systemic lupus erythematosus. A case report. *J Bone Joint Surg Am.* 1974;56(4):823-4.
7. Alexeef M. Ligamentum patellae rupture following local steroid injection. *Aust N Z J Surg.* 1986;56(9):681-3.
8. Schenck RC Jr. Lesões do joelho. In: Bucholz RW, Heckman JD. *Fraaturas em adultos.* 5a ed. São Paulo:Manole; 2001. p. 1843-938.
9. Ecker ML, Lotke PA, Glazer RM. Late reconstruction of the patellar tendon. *J Bone Joint Surg Am.* 1979;61(6A):884-6.
10. Kelikian H, Riashi E, Gleason J. Restoration of quadriceps function in neglected tear of the patellar tendon. *Surg Gynecol Obstet.* 1957;104(2):200-4.
11. Scott WN, Scuderi GR, Insall JN. Injuries of the knee. In: Rockwood CA, Green DP, Bucholz DP, editors. *Rockwood and Green's fractures in adults.* 4th ed. Philadelphia: Lippincott-Raven; 1996. p. 2001-127.
12. Marczyk LRS, Gomes JLE, Worn Júnior D, Karl WEG. Reconstrução do tendão patelar com ligamento artificial. *Ver Bras Ortop.* 1995;25(1):39-42.

13. Zekcer A, Carneiro ACI, Minervini S, Navarro R. Re-ruptura do ligamento patelar: uma proposta para o tratamento cirúrgico. *Rev Bras Ortop.* 2001;36(1/2):41-3.
14. Lucas JT, Ducker TB. Motor classification of spinal cord injuries with mobility, morbidity, and recovery indices. *Am Surg.* 1979;45(3):151-8.
15. Rougraff BT, Reeck CC, Essenmacher J. Complete quadriceps tendon ruptures. *Orthopedics.* 1996;19(6):509-14.
16. Seijas R, Steinbacher G, Rius M, Cugat R. Quadriceps and patellar tendon ruptures. In: *Techniques in knee surgery.* Philadelphia: Lippincott Williams & Wilkins; 2010. p. 145-9.
17. Seidenstein AD, Farrel CM, Scuderi GR, Easley ME. Quadriceps and patellar tendon disruption. In: *Scott WN. Insall & Scott surgery of the knee.* New York: Churchill Livingstone; 2012. p. 696-710.
18. Thompson TC. Quadricepsplasty to improve knee function. *J Bone Joint Surg Am.* 1944;36:366.
19. Sherbondy PS. Primary repair of an elongated patellar tendon secondary to chronic rupture. In: *Techniques in knee surgery.* Philadelphia: Lippincott Williams & Wilkins; 2010. p. 239-41.
20. Casey MT Jr, Tietjens BR. Neglected ruptures of the patellar tendon. A case series of four patients. *Am J Sports Med.* 2001;29(4):457-60.