

Thick Graft Versus Double-Bundle Technique on Posterior Cruciate Ligament Reconstruction: Experimental Biomechanical Study with Cadavers*

Enxerto espesso versus técnica de duplo feixe na reconstrução do ligamento cruzado posterior: estudo experimental biomecânico com cadáveres

João Alberto Ramos Maradei-Pereira^{1,2,3}  Alexandre Estevão Vamos Kokron³
César Augusto Martins Pereira³ Marco Martins Amatuzzi³

¹ Faculdade de Medicina, Universidade Federal do Pará, Belém, PA, Brazil

² Clínica dos Acidentados, Hospital Maradei, Belém, PA, Brazil

³ Medical Research Laboratory (LIM-41), Instituto de Ortopedia e Traumatologia, Hospital das Clínicas, Faculdade de Medicina, Universidade de São Paulo, São Paulo, SP, Brazil

Address for correspondence João Alberto Ramos Maradei-Pereira, MD, MSc, Faculdade de Medicina, Universidade Federal do Pará, Praça Camilo Salgado, 01, Umarizal, Belém, PA, 66050-060 Brazil (e-mail: jamaradei@ufpa.br).

Rev Bras Ortop 2019;54:531–539.

Abstract

Objective To evaluate the biomechanical effect of graft thickness compared with the double-bundle technique on posterior cruciate ligament (PCL) reconstruction in human cadaveric knees.

Methods A total of 9 human cadaveric knees were tested in 5 conditions: intact knee (INT); single-bundle reconstruction with a 10-mm quadriceps tendon (SB); double-bundle reconstruction with a 10 mm-quadriceps tendon for the anterolateral bundle and a 7-mm doubled semitendinosus tendon for the posteromedial bundle (DB); single-bundle reconstruction with a 10-mm quadriceps tendon plus a 7-mm doubled semitendinosus tendon (SBT); and PCL-deficient (NoPCL). The posterior tibial translation (PTT) was measured in response to a 134-N posterior tibial load at 0°, 30°, 60° e 90° of knee flexion.

Results The PTT values of the DB and SBT techniques were always significantly lower (better stability) than those of the SB technique. The PTT values of the SBT technique were significantly lower than those of the DB technique at 60° ($p = 0.005$) and 90° ($p = 0.001$).

Conclusions Graft enlargement improves knee stability in isolated PCL reconstructions, whereas the graft division in the two-bundle technique worsens this stability at 60° and 90° of knee flexion. The findings of the present study suggest that knee

Keywords

- ▶ knee injuries
- ▶ posterior cruciate
- ▶ biomechanical phenomena
- ▶ cadaver
- ▶ posterior cruciate ligament reconstruction

* Study conducted at the Medical Research Laboratory (LIM-41), Instituto de Ortopedia e Traumatologia, Hospital das Clínicas, Faculdade de Medicina, Universidade de São Paulo, São Paulo, SP, Brazil. Originally published by Elsevier.



Resumo

Palavras-chave

- ▶ traumatismos do joelho
- ▶ ligamento cruzado posterior
- ▶ fenômenos biomecânicos
- ▶ cadáver
- ▶ reconstrução do ligamento cruzado posterior

stability in PCL reconstructions may be improved with the use of thicker grafts in the SB technique rather than performing the DB technique.

Objetivo Avaliar o efeito biomecânico da espessura do enxerto em comparação com a técnica do duplo feixe na reconstrução do ligamento cruzado posterior (LCP) em joelhos de cadáveres humanos.

Métodos Um total de 9 joelhos de cadáveres humanos foram testados em 5 condições: joelho intacto (INT); reconstrução com um único feixe com tendão de quadríceps de 10 mm (Rec 1); reconstrução com dois feixes com um tendão de quadríceps de 10 mm para o feixe anterolateral e um tendão duplo do semitendíneo de 7 mm para o feixe póstero-medial (Rec 2); reconstrução com um único feixe mais espesso, usando um tendão de quadríceps de 10 mm mais o tendão duplo do semitendíneo de 7 mm (Rec M); e joelho com lesão isolada do LCP (Lesionado). O limite do deslocamento posterior da tíbia (LDPT) foi medido em resposta a uma carga tibial posterior de 134 N a 0°, 30°, 60° e 90° de flexão do joelho.

Resultados O LDPT das técnicas Rec 2 e Rec M foi sempre significativamente menor (melhor estabilidade) do que o LDPT da Rec 1. O LDPT da Rec M foi significativamente menor do que o da Rec 2 a 60° ($p = 0,005$) e a 90° ($p = 0,001$).

Conclusões O aumento da espessura do enxerto na reconstrução das lesões isoladas do LCP melhora significativamente a estabilidade, enquanto que a divisão do enxerto para reconstruir os dois feixes piora a estabilidade da reconstrução a 60° e 90° de flexão do joelho. As descobertas do presente estudo sugerem que a estabilidade da reconstrução do LCP pode ser melhorada com o uso de enxertos mais espessos em uma técnica de feixe único, em lugar da reconstrução de duplo feixe.

Introduction

The optimal treatment of the injured posterior cruciate ligament (PCL) has not yet been defined. Although there is consensus in the literature regarding the need for surgical treatment in the presence of other knee ligament injuries,^{1,2} controversy remains in isolated lesions of the PCL. Some authors advocate the conservative treatment in these cases.^{3,4} Others, however, emphasize that the knee with a PCL injury develops degenerative changes that worsen over time.^{5,6} The better understanding of the anatomy and biomechanics of the ligament enabled improvements in the results of PCL reconstructions, but to date no ideal technique has been described.^{7,8}

Based on anatomical and biomechanical studies, some authors suggest that reconstruction with two bundles and two femoral tunnels better mimics the anatomy and function of the normal knee.^{1,9} However, laboratory tests that show the superiority of these double-bundle reconstructions^{10,11} are biased by the lack of uniformity in the thickness of the grafts used in the two compared groups. In these studies, the authors use a larger volume of graft in the two-bundle reconstruction than in the technique with one bundle. When using grafts of the same thickness in both groups, other authors observed no significant difference between the techniques.^{12,13} Upon this, the question that motivated the present work was formulated: the successful restoration of knee laxity achieved with the double-bundle technique is due to the construction of the second bundle or to the greater volume of graft? The objective of the present study was,

therefore, to evaluate the biomechanical effect of graft thickness compared with the double-bundle technique in PCL reconstruction in human cadaveric knees.

Methods

The present study was approved by the Ethics in Research Committee of the institution responsible for the study (procedure number 391/02).

The knees used were obtained from nine fresh cadavers from the necropsy service of a large university hospital in Brazil. The average age of the cadavers was 52 years, ranging from 43 to 70 years. A total of seven cadavers were male.

At the necropsy service, a medial arthrotomy along with a vertical posterior arthrotomy were performed for joint inspection, to exclude any specimen presenting ligament injuries or degenerative joint disease. Once the specimens were deemed eligible for the study, the arthrotomies were closed with a 2-0 nylon. The knee was then removed from the cadaver and frozen at -15°C .

Specimen Preparation

The knee was thawed overnight at room temperature. Then, it was dissected, had the skin removed, sparing all knee ligaments, including those of the proximal tibiofibular joint, the popliteus tendon and the muscle, the interosseous membrane, the joint capsule and the extensor mechanism. The fibula was stabilized to the tibia with a 4.5-mm cortical

screw, as recommended,^{10,12,14} and sectioned at a distance of 2 cm distally from the screw.

The grafts obtained from the knee to be tested were a 10-mm quadriceps tendon and a doubled-strand semitendinosus tendon. They were subjected to a constant tension of 20 N for 20 minutes and used in reconstructions after that period.

Testing Protocol

The mechanical tests were performed using the Kratos K5002 (Kratos Equipamentos Industriais, Cotia, SP, Brazil) electromechanical testing machine with an electronic load cell of 100 kgf connected to a computer equipped with an ADS 2000 (Lynx Tecnologia Eletrônica Ltda., São Paulo, SP, Brazil) data acquisition system. To begin testing, a metal clamp was fixated to the metaphysis and diaphysis of the femur, and another one, to the proximal tibial diaphysis. The clamps remained in this position, firmly fixated, during every test, and even during the surgical procedures. The knee with the clamps was fixated to the testing machine (►Fig. 1), which was connected to the computer. For each evaluation, the knee was tested in extension, and at 30°, 60° and 90° of flexion.

During the tests, the femur movements in the upper and lower direction in relation to the tibia were made using the Kratos machine at a constant speed of 20 mm/min, corresponding to anterior and posterior drawers. The load point was located at the distal femoral metaphysis. The results of the tests (force applied to the tibia and its translation since the beginning of the test) were immediately transferred to the computer. For each evaluation condition, the specimen was submitted to three consecutive cycles of force application by the testing machine. Initially, the load was applied in the direction of the femur to achieve an anterior tibial translation of 2 mm. Then, it was applied in the reverse direction (posterior drawer) with a force equivalent to 134 N, as described by some authors.^{11,15,16}

The laxity of each knee was initially tested with intact (INT) ligaments. Then, the PCL was removed, and each knee was successively subjected to three different types of reconstruction, which are described in detail in the next section. The laxity was tested after each reconstruction. Finally, tests were performed on the knee without the original PCL and without reconstruction (NoPCL) (►Fig. 2).

Surgical Techniques

Single-Bundle Reconstruction with One 10-mm Quadriceps Tendon (SB)

After the test with the INT PCL, the knee was removed from the testing machine. All surgical techniques were performed through a medial parapatellar arthrotomy and also by a small posterior longitudinal arthrotomy. Thus, the PCL was completely removed, including the meniscomfemoral ligaments, when present, but sparing the other knee ligaments. The tibial tunnel was made with a 10-mm diameter, from the antero-medial tibia surface to the center of the removed PCL tibial insertion. The 10-mm anterolateral (AL) femoral tunnel was drilled centered 7 mm from the cartilage edge at the 1-o'clock position, in a direction parallel to the notch roof. The quadriceps tendon graft was inserted into the tibial and femoral tunnels, with the bone block located in the femoral tunnel. It was then fixated to the femur by tying it around a 4.5-mm cortical screw with a washer.

After suturing the articular capsule, the knee was repositioned in the testing machine at 90° of flexion, and subjected to an anterior drawer of 134 N. At this moment, the graft was tensioned (digital tensioner, LIM-41, São Paulo, SP, Brazil) (►Fig. 3). When the desired tension (88 N) was achieved, the graft was fixated to the tibia, locking the two threads of polyester no. 5 between two metallic platelets and a screw (►Fig. 4).




Fig. 1 Knee positioned at 90° of flexion, fixated to the testing machine. The tibia remained horizontal, with the anterior margin facing the ground. The machine performed the elevation or descent of the femur in relation to the tibia, which corresponded, respectively, to the movement of the anterior and posterior drawers.

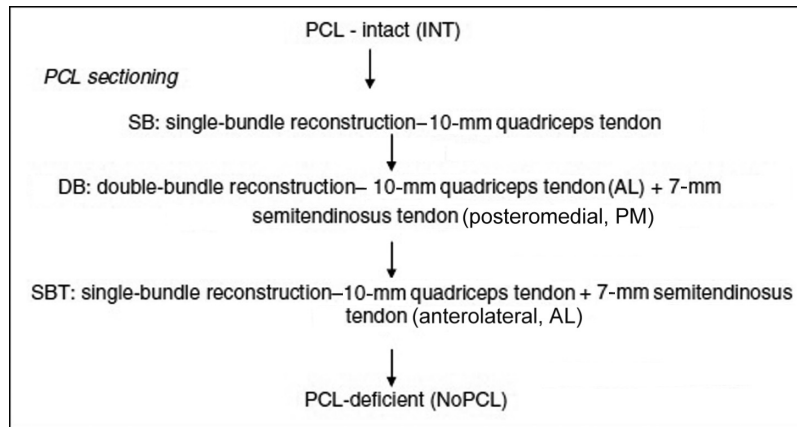


Fig. 2 Sequence of testing conditions.




Fig. 3 Graft tensioning monitored by the dynamometer.




Fig. 4 Tibial fixation device. The polyester threads from the graft were locked between two platelets.

Double-Bundle Reconstruction with One 10-mm Quadriceps Tendon and a 7-mm Semitendinosus Tendon (DB)

After testing the single-bundle reconstruction (SB), the knee was removed from the testing machine. The sutures were removed from the arthrotomies, as was the graft from the tibial tunnel. This tunnel was extended in thickness with a 12-mm diameter drill.

The graft was kept in the AL femoral tunnel while the second (posteromedial, PM) tunnel was made. The PM tunnel was centered at the 2:30-o'clock position, 14 mm from the cartilage edge (distal-proximal direction) and 9 mm posteriorly to the center of the AL tunnel (anterior-posterior direction).

This PM femoral tunnel was made with a 7-mm diameter drill. The doubled semitendinosus tendon graft was inserted into the tibial and PM femoral tunnels and fixated to the femur by tying it around a second cortical screw with a washer (4.5 mm in diameter). Then, the quadriceps graft was again inserted into the tibial tunnel in a position anterior to the semitendinosus tendon.

After the arthrotomies were sutured, the knee was repositioned in the testing machine at 90° of flexion, and subjected to an anterior drawer of 134 N. The quadriceps graft was fixated with 88 N of tension. The knee was returned to position 0 and positioned at 0° of flexion. It was again subjected to a 134-N anterior drawer, and the semitendinosus graft was tensioned to 67 N and fixated with a second tibial device (similar to the one used for the quadriceps, ►Figs. 3 and 4). The knee was then returned to position 0 and submitted to laxity tests at 0°, 30°, 60° and 90° of flexion.

Single-bundle reconstruction with quadriceps plus semitendinosus grafts (SBT)

After testing the double-bundle reconstruction (DB), both grafts were released from the femur and removed from their respective tunnels, except from the tibial tunnel.

The AL femoral tunnel was enlarged in thickness with a 12-mm drill. Both grafts were then inserted into this tunnel and fixated to the femur by tying them to the same bicortical screw previously used to fixate only the quadriceps graft. The cortical screw fixating the semitendinosus tendon in the posteromedial femoral tunnel was then removed.

The tibial insertion of the grafts was loosened, the medial arthrotomy was closed, and the knee was repositioned in the testing machine at 90° of flexion. The specimen was subjected to a 134-N anterior drawer, the grafts were tensioned, both at 90°, the quadriceps with 88 N, and the doubled semitendinosus tendon with 67 N, and fixated to the tibia, each in its own tibial fixation device (as previously described). The knee was then returned to position 0 and tested at 0°, 30°, 60° and 90° of flexion.

Sample Size Calculation

A very similar study¹³ evaluated the value of the posterior tibial translation and obtained an approximate difference of 7.5 mm between the knees comparing the reconstructed and the injured situations at the intermediate flexion angulation. The greatest variability found during all angles of flexion was

of ~5.66 mm (standard deviation [SD] = 5.66). Based on this study and aiming to find a similar result, with 80% power and a 95% confidence interval (95%CI), the sample required for the present study was calculated as 9 knees submitted to all 5 situations (INT, SB, DB, SBT, and NoPCL).

Data Collection and Statistical Analysis

The data were represented by the following descriptive measures: mean, SD, and the upper and lower limits of the 95%CI. A statistical significance level (*p*) of 0.05 (5%) was adopted. Descriptive levels below this value were considered significant. Based on the graph of the force applied by the translation of the tibia from every angle measured, the maximum posterior tibial translation (PTT) was determined. It was measured in millimeters and defined as the largest posterior translation of the tibia.

The analysis of variance (ANOVA) for repeated measures was used, with two factors: testing the conditions in the 5 situations (INT, SB, DB, SBT, and NoPCL) and the degree of knee flexion with 4 levels (0°, 30°, 60° and 90°). The Newman-Keuls multiple comparison test was used to find differences among techniques and among degrees of knee flexion.

Results

Posterior Tibial Translation (PTT)

The data regarding the PTT values (mean, SD, and lower and upper limits of the 95%CIs) of the 5 testing conditions in each of the 4 angles tested are shown in ►Table 1, and their graphic representation, in ►Fig. 5. The comparison among the 5 testing conditions at each angle of knee flexion is shown in ►Tables 2–5.

The PTT of the SB technique was statistically higher (worse laxity) than that for the INT knee at all angles tested (*p* = 0.022 at 0°; and *p* < 0.001 at 30°, 60° and 90°). The DB technique showed values of PTT that were statistically similar to those of the INT knee at 0° (*p* = 0.18) and 30° (*p* = 0.085). The SBT technique was similar to the INT knee at 0° (*p* = 0.803), 30° (*p* = 0.98) and 60° (*p* = 0.116) of flexion.

The SB with a thicker graft (SBT) presented lower PTT values (better laxity) than the DB at 60° (*p* = 0.005) and 90° (*p* = 0.001). At 90°, all of the PCL reconstructions showed values of PTT that were statistically different from the INT knee.

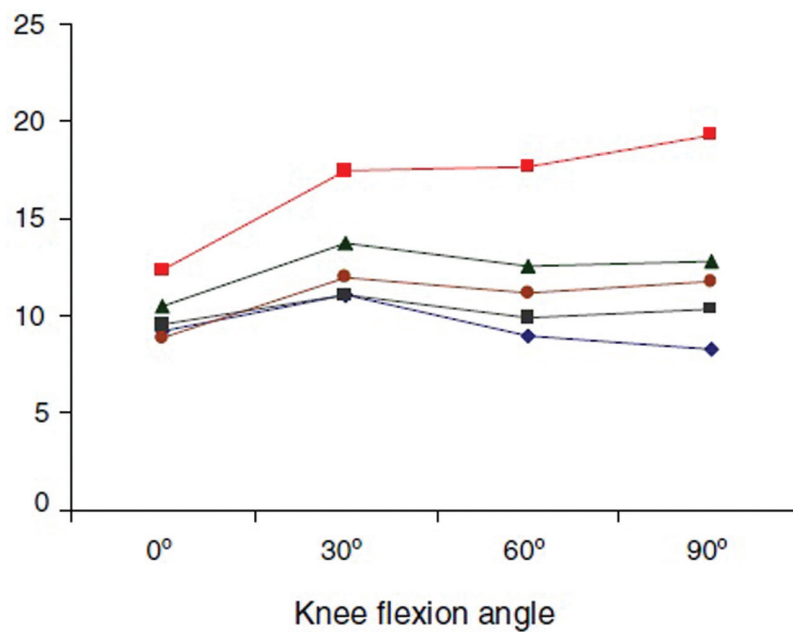
Discussion

A recent systematic review¹⁷ of the literature analyzed the results of studies comparing the use of one or two bundles in PCL reconstruction.¹⁷ The review was only able to find 11 clinical studies so far, which shows that there is still a gap in the literature regarding this subject. Some authors report more physiological results and better laxity with the DB.^{2,10,11,18–25} Others, however, could not demonstrate the superiority of one technique over the other (one versus two bundles).^{12,13,26–29} This scenario made us wonder if the comparison should be made between one and two bundles or if, rather, there is a problem with graft volume that would be better solved with a thicker bundle (and not with several

Table 1 Posterior tibial translation, in millimeters, by testing conditions and angle of knee flexion. Mean, standard deviation (in parentheses) and 95% confidence intervals (in brackets)

Flexion angle	PTT (mm)				
	Intact	Injured	SB	DB	SBT
0°	9.48 (1.81) [8.08-10.86]	12.30 (2.72) [10.21-14.40]	10.46 (2.12) [8.83-12.08]	8.83 (1.60) [7.61-10.06]	9.55 (1.76) [8.19-10.90]
30°	10.98 (1.93) [9.49-12.46]	17.36 (3.24) [14.87-19.85]	13.70 (2.35) [11.89-15.51]	12.00 (1.97) [10.49-13.52]	10.96 (2.63) [8.93-12.98]
60°	8.92 (1.24) [7.97-8.87]	17.87 (3.01) [15.55-20.18]	12.60 (1.97) [11.09-14.12]	11.18 (1.82) [9.78-12.58]	9.87 (2.06) [8.29-11.46]
90°	8.31 (1.26) [7.34-9.28]	19.28 (2.33) [17.49-21.07]	12.83 (2.16) [11.17-14.49]	11.67 (2.22) [9.96-13.37]	10.27 (2.43) [8.40-12.14]

Abbreviations: DB, double-bundle reconstruction with a 10-mm quadriceps tendon and a 7-mm semitendinosus tendon; Injured, injured posterior cruciate ligament; Intact, intact posterior cruciate ligament; PTT, posterior tibial translation; SB, single-bundle reconstruction with a 10-mm quadriceps tendon; SBT, single-bundle reconstruction with a 10-mm quadriceps tendon plus a 7-mm doubled semitendinosus tendon

**Fig. 5** Posterior tibial translation (PTT) of all testing conditions at each flexion angle: intact posterior cruciate ligament (PCL) (blue line); injured PCL (red line); single-bundle reconstruction with a 10-mm quadriceps tendon (green line); double-bundle reconstruction with a 10-mm quadriceps tendon for the anterolateral bundle and a 7-mm doubled semitendinosus tendon for the posteromedial bundle (brown line); single-bundle reconstruction with a 10-mm quadriceps tendon plus a 7-mm doubled semitendinosus tendon (black line).

bundles). We then identified two key points to study in depth: the thickness of the graft and the second femoral tunnel. The influence of these two factors on reconstruction laxity was tested.

Increasing the graft thickness (by adding the 7-mm double semitendinosus tendon to the 10-mm quadriceps graft) in our SBs significantly reduced ($p < 0.05$) the PTT values at all angles tested. We chose the AL, which is not isometric, positioning for the femoral insertion in our SBs, since the AL bundle of the PCL has more fibers and greater ultimate strength than the PM. The choice was also made because the reconstruction with the femoral tunnel in this position results in greater stability than that achieved with other techniques (PM or isometric reconstructions).^{10,30} We reproduced the position of the AL tunnel as performed in the study by Kokron et al¹², which also

corresponds to the shallow 1 tunnel in the study by Mannor et al.,³¹ and to the AL tunnel in the studies by Harner et al¹¹ and Bergfeld et al.¹³ The value of 88 N of graft tensioning at 90° of flexion, with an anterior drawer of 134 N, was recommended by Harner et al.¹¹

The SB technique was unable to restore knee laxity at every measured angle. The same result was achieved by Kokron et al¹² with the same graft, and by Harner et al¹¹ with an Achilles tendon graft of 10 mm. In both studies, the same AL bundle failed to restore laxity to the knee at every angle. Different results were obtained by other authors, but with other tensioning and fixation methods.^{10,11,13,15}

Using a thicker graft (SBT), the PTT values were not significantly higher than in the INT knee at 0°, 30° and 60° of flexion. At 90°, however, this value was statistically higher.

Table 2 Comparison of the descriptive levels of the posterior tibial translation at 0° of flexion among the testing conditions

	Intact	Injured	SB	DB	SBT
Intact	–	x	x	x	x
Injured	$p=0.001$	–	x	x	x
SB	$p=0.022$	$p=0.003$	–	x	x
DB	$p=0.180$	$p<0.001$	$p=0.001$	–	x
SBT	$p=0.803$	$p=0.006$	$p=0.036$	$p=0.183$	–

Abbreviations: DB, double-bundle reconstruction with a 10-mm quadriceps tendon and a 7-mm semitendinosus tendon; Injured, injured posterior cruciate ligament; Intact, intact posterior cruciate ligament; SB, single-bundle reconstruction with a 10-mm quadriceps tendon; SBT, single-bundle reconstruction with a 10-mm quadriceps tendon plus a 7-mm doubled semitendinosus tendon.

Table 3 Comparison of the descriptive levels of the posterior tibial translation at 30° of flexion among the testing conditions

	Intact	Injured	SB	DB	SBT
Intact	–	x	x	x	x
Injured	$p<0.001$	–	x	x	x
SB	$p<0.001$	$p=0.001$	–	x	x
DB	$p=0.085$	$p<0.001$	$p=0.001$	–	x
SBT	$p=0.980$	$p=0.001$	$p=0.002$	$p=0.140$	–

Abbreviations: DB, double-bundle reconstruction with a 10-mm quadriceps tendon and a 7-mm semitendinosus tendon; Injured, injured posterior cruciate ligament; Intact, intact posterior cruciate ligament; SB, single-bundle reconstruction with a 10-mm quadriceps tendon; SBT, single-bundle reconstruction with a 10-mm quadriceps tendon plus a 7-mm doubled semitendinosus tendon.

Table 4 Comparison of the descriptive levels of the posterior tibial translation at 60° of flexion among the testing conditions

	Intact	Injured	SB	DB	SBT
Intact	–	x	x	x	x
Injured	$p<0.001$	–	x	x	x
SB	$p<0.001$	$p<0.001$	–	x	x
DB	$p=0.001$	$p<0.001$	$p=0.003$	–	x
SBT	$p=0.116$	$p<0.001$	$p=0.001$	$p=0.005$	–

Abbreviations: DB, double-bundle reconstruction with a 10-mm quadriceps tendon and a 7-mm semitendinosus tendon; Injured, injured posterior cruciate ligament; Intact, intact posterior cruciate ligament; SB, single-bundle reconstruction with a 10-mm quadriceps tendon; SBT, single-bundle reconstruction with a 10-mm quadriceps tendon plus a 7-mm doubled semitendinosus tendon.

Once the insertion of the PCL into the femur is broad, corresponding to 150% of the femoral insertion area of the anterior cruciate ligament (ACL), and covering ~32 mm in the femur,³⁰ it seems reasonable that the graft used to reconstruct it should also be thicker than in the ACL reconstruction. We believe the improvement with a thicker graft is due to the greater amount of fibers opposing the tibial posteriorization, which is closer to the normal anatomy. In our opinion, the SBT results would improve if we could fill the

Table 5 Comparison of the descriptive levels of the posterior tibial translation at 90° of flexion among the testing conditions

	Intact	Injured	SB	DB	SBT
Intact	–	x	x	x	x
Injured	$p<0.001$	–	x	x	x
SB	$p<0.001$	$p<0.001$	–	x	x
DB	$p<0.001$	$p<0.001$	$p=0.014$	–	x
SBT	$p=0.011$	$p<0.001$	$p=0.001$	$p=0.001$	–

Abbreviations: DB, double-bundle reconstruction with a 10-mm quadriceps tendon and a 7-mm semitendinosus tendon; Injured, injured posterior cruciate ligament; Intact, intact posterior cruciate ligament; SB, single-bundle reconstruction with a 10-mm quadriceps tendon; SBT, single-bundle reconstruction with a 10-mm quadriceps tendon plus a 7-mm doubled semitendinosus tendon.

entire native PCL femoral footprint with a graft. However, this cannot be accomplished with cylindrical tunnels. We also believe a femoral inlay fixation, which would better reproduce the anatomical femoral insertion of the PCL, could be a good option to obtain an even better laxity.

Regarding the influence of the second femoral tunnel, we observed that it also improved the reconstruction laxity at every tested angle compared with our SB with a thinner graft (quadriceps tendon of 10 mm). With the DB, the PTT showed no statistical differences in relation to the PCL INT knee at 0° and 30° of flexion. At angles of 60° and 90°, however, the PTT values in the DB were significantly higher than those of the PCL INT knee. As the femoral tunnel of our second bundle was positioned in a more posterior region of the anatomical insertion of the PCL, even more posteriorly than the second bundle (PM) described by Harner et al¹¹ and Race and Amis,¹⁰ and the deep tunnel described by Mannor et al,³¹ we believe it offered little resistance to the PTT at these higher angles of flexion. In our view, at these angles, the key role was played by the AL bundle, which was represented by the quadriceps graft of 10 mm, which, as in the SB, was unable to, alone, keep PTT close to the INT status.

As observed in other studies, adding more graft through a second femoral tunnel also decreased tibial posteriorization in our tests.^{2,10,11,18,20,22,23,26} We agree, however, with Bergfeld et al,¹³ that this does not enable us to infer the superiority of the DB, since we are comparing techniques with different amounts of graft. Bergfeld et al¹³ and Kokron et al¹² also found no statistical differences between the SB and DB when using grafts with the same thickness in cadaveric isolated PCL injuries.

At this point, the question to be made is: since increasing the thickness of the graft improves the quality of the reconstruction, is it better to operate using a thicker single bundle or to increase the volume of the graft through a second femoral tunnel? To answer this question, we compared the SBT technique with the DB technique. In both situations, we used the same amount of graft (10-mm quadriceps tendon, plus doubled 7-mm semitendinosus tendon).

The site where the semitendinosus graft was added made no difference in terms of PTT with the knee in extension or at

30° of flexion. However, at 60° ($p = 0.005$) and 90° ($p = 0.001$), placing the graft in a second extra femoral tunnel significantly increased the PTT values when compared with adding it via the same AL femoral tunnel. In other words, the division of the graft into 2 bundles worsened the reconstruction laxity at 60° and 90° of knee flexion.

In the clinical field, three studies^{32–34} corroborate our experimental findings, reporting better results with thicker grafts. This improvement was observed both in the SB and DB techniques. Zhao and Huangfu,³² in a retrospective study comparing the techniques of single bundle reconstructions, concluded that the seven-bundle graft offers more stability than the quadruple graft in isolated PCL lesions. In DBs, Zhao et al³³ published results of 88.9% of normal and 11.1% of nearly normal International Knee Documentation Committee (IKDC) scores, using a thicker (8-fold) graft (quadruple semitendinosus tendon for the AL bundle and quadruple gracilis for the PM bundle). Chen and Gao³⁴ also published results with 8-fold grafts, with 78.9% of normal and 15.8% of nearly normal IKDC scores. Therefore, in our view, there is no reason to perform the DB, which is technically more complex and lengthy, in isolated PCL lesions, since better results can be obtained by adding the graft, not through a second femoral tunnel, but through the AL femoral tunnel, that is, through a reconstruction with a single thicker bundle.

The method used in the present study enabled the performance of all evaluations in each knee. Thus, the results of each technique could be compared among each other and with the biomechanical behavior of the same knee with an INT PCL, excluding any possible bias imposed by the effect of variation among specimens. However, to make it possible, the sequence of the tests could not be randomized, and this might be considered a limitation of the present study.

Conclusions

The results of the present biomechanical study enabled us to conclude that:

1. Increasing the graft thickness significantly improves the laxity of the PCL reconstruction;
2. The division of the graft for the production of two bundles worsens the laxity of the PCL reconstruction at 60° and 90° of knee flexion;
3. There is no justification to perform the DB in isolated PCL lesions, since the restoration of knee laxity achieved with this technique is due to the increased amount of graft.

Conflicts of Interest

The authors have none to declare.

References

- 1 Harner CD, Höher J. Evaluation and treatment of posterior cruciate ligament injuries. *Am J Sports Med* 1998;26(03):471–482
- 2 Wiley WB, Askew MJ, Melby A III, Noe DA. Kinematics of the posterior cruciate ligament/posterolateral corner-injured knee after reconstruction by single- and double-bundle intra-articular grafts. *Am J Sports Med* 2006;34(05):741–748
- 3 Kannus P, Bergfeld J, Järvinen M, et al. Injuries to the posterior cruciate ligament of the knee. *Sports Med* 1991;12(02):110–131
- 4 Parolie JM, Bergfeld JA. Long-term results of nonoperative treatment of isolated posterior cruciate ligament injuries in the athlete. *Am J Sports Med* 1986;14(01):35–38
- 5 Dejour H, Walch G, Peyrot J, Eberhard P. Histoire naturelle de la rupture du ligament croisé postérieur. [The natural history of rupture of the posterior cruciate ligament]. *Rev Chir Orthop Reparat Appar Mot* 1988;74(01):35–43
- 6 Geissler WB, Whipple TL. Intraarticular abnormalities in association with posterior cruciate ligament injuries. *Am J Sports Med* 1993;21(06):846–849
- 7 Kohen RB, Sekiya JK. Single-bundle versus double-bundle posterior cruciate ligament reconstruction. *Arthroscopy* 2009;25(12):1470–1477
- 8 Hammoud S, Reinhardt KR, Marx RG. Outcomes of posterior cruciate ligament treatment: a review of the evidence. *Sports Med Arthrosc Rev* 2010;18(04):280–291
- 9 Ahmad CS, Cohen ZA, Levine WN, Gardner TR, Ateshian GA, Mow VC. Codominance of the individual posterior cruciate ligament bundles. An analysis of bundle lengths and orientation. *Am J Sports Med* 2003;31(02):221–225
- 10 Race A, Amis AA. PCL reconstruction. In vitro biomechanical comparison of ‘isometric’ versus single and double-bundled ‘anatomic’ grafts. *J Bone Joint Surg Br* 1998;80(01):173–179
- 11 Harner CD, Janaushek MA, Kanamori A, Yagi M, Vogrin TM, Woo SL. Biomechanical analysis of a double-bundle posterior cruciate ligament reconstruction. *Am J Sports Med* 2000;28(02):144–151
- 12 Kokron AWV, Hernandez AJ, Camanho GL, Amatuzzi MM. Biomechanical evaluation of reconstruction laxity with one and two bundles of graft in isolated posterior cruciate ligament injury. In: 2001 International Society of Arthroscopy, Knee Surgery and Orthopedic Sports Medicine – Isakos, 2001. Presentation outlines & Abstracts. 2001. p. 4–11.
- 13 Bergfeld JA, Graham SM, Parker RD, Valdevit AD, Kambic HE. A biomechanical comparison of posterior cruciate ligament reconstructions using single- and double-bundle tibial inlay techniques. *Am J Sports Med* 2005;33(07):976–981
- 14 Beynon BD, Amis AA. In vitro testing protocols for the cruciate ligaments and ligament reconstructions. *Knee Surg Sports Traumatol Arthrosc* 1998;6(Suppl 1):S70–S76
- 15 Harner CD, Janaushek MA, Ma CB, Kanamori A, Vogrin TM, Woo SL. The effect of knee flexion angle and application of an anterior tibial load at the time of graft fixation on the biomechanics of a posterior cruciate ligament-reconstructed knee. *Am J Sports Med* 2000;28(04):460–465
- 16 Ma CB, Kanamori A, Vogrin TM, Woo SL, Harner CD. Measurement of posterior tibial translation in the posterior cruciate ligament-reconstructed knee: significance of the shift in the reference position. *Am J Sports Med* 2003;31(06):843–848
- 17 Chahla J, Moatshe G, Cinque ME, et al. Single-bundle and double-bundle posterior cruciate ligament reconstructions: a systematic review and meta-analysis of 441 patients at a minimum 2 years’ follow-up. *Arthroscopy* 2017;33(11):2066–2080
- 18 Whiddon DR, Zehms CT, Miller MD, Quinby JS, Montgomery SL, Sekiya JK. Double compared with single-bundle open inlay posterior cruciate ligament reconstruction in a cadaver model. *J Bone Joint Surg Am* 2008;90(09):1820–1829
- 19 Nuelle CW, Milles JL, Pfeiffer FM, et al. Biomechanical Comparison of Five Posterior Cruciate Ligament Reconstruction Techniques. *J Knee Surg* 2017;30(06):523–531
- 20 Milles JL, Nuelle CW, Pfeiffer F, et al. Biomechanical comparison: single-bundle versus double-bundle posterior cruciate ligament reconstruction techniques. *J Knee Surg* 2017;30(04):347–351
- 21 Jain V, Goyal A, Mohindra M, Kumar R, Joshi D, Chaudhary D. A comparative analysis of arthroscopic double-bundle versus single-bundle posterior cruciate ligament reconstruction using hamstring

- tendon autograft. *Arch Orthop Trauma Surg* 2016;136(11):1555–1561
- 22 Wijdicks CA, Kennedy NI, Goldsmith MT, et al. Kinematic analysis of the posterior cruciate ligament, part 2: a comparison of anatomic single- versus double-bundle reconstruction. *Am J Sports Med* 2013;41(12):2839–2848
 - 23 Li Y, Li J, Wang J, Gao S, Zhang Y. Comparison of single-bundle and double-bundle isolated posterior cruciate ligament reconstruction with allograft: a prospective, randomized study. *Arthroscopy* 2014;30(06):695–700
 - 24 Xu Y, Yin Y, Wang JQ, Ao YF. [Comparison of single and double bundle isolate posterior cruciate ligament reconstruction with hamstring autograft]. *Zhonghua Wai Ke Za Zhi* 2013;51(03):247–251
 - 25 Yoon KH, Bae DK, Song SJ, Cho HJ, Lee JH. A prospective randomized study comparing arthroscopic single-bundle and double-bundle posterior cruciate ligament reconstructions preserving remnant fibers. *Am J Sports Med* 2011;39(03):474–480
 - 26 Markolf KL, Feeley BT, Jackson SR, McAllister DR. Biomechanical studies of double-bundle posterior cruciate ligament reconstructions. *J Bone Joint Surg Am* 2006;88(08):1788–1794
 - 27 Apsingi S, Nguyen T, Bull AM, Unwin A, Deehan DJ, Amis AA. Control of laxity in knees with combined posterior cruciate ligament and posterolateral corner deficiency: comparison of single-bundle versus double-bundle posterior cruciate ligament reconstruction combined with modified Larson posterolateral corner reconstruction. *Am J Sports Med* 2008;36(03):487–494
 - 28 Deie M, Adachi N, Nakamae A, Takazawa K, Ochi M. Evaluation of single-bundle versus double-bundle PCL reconstructions with more than 10-year follow-up. *ScientificWorldJournal* 2015;2015:751465
 - 29 Fanelli GC, Beck JD, Edson CJ. Single compared to double-bundle PCL reconstruction using allograft tissue. *J Knee Surg* 2012;25(01):59–64
 - 30 Harner CD, Xerogeanes JW, Livesay GA, et al. The human posterior cruciate ligament complex: an interdisciplinary study. Ligament morphology and biomechanical evaluation. *Am J Sports Med* 1995;23(06):736–745
 - 31 Mannor DA, Shearn JT, Grood ES, Noyes FR, Levy MS. Two-bundle posterior cruciate ligament reconstruction. An in vitro analysis of graft placement and tension. *Am J Sports Med* 2000;28(06):833–845
 - 32 Zhao J, Huangfu X. Arthroscopic single-bundle posterior cruciate ligament reconstruction: Retrospective review of 4- versus 7-strand hamstring tendon graft. *Knee* 2007;14(04):301–305
 - 33 Zhao J, Xiaoqiao H, He Y, Yang X, Liu C, Lu Z. Sandwich-style posterior cruciate ligament reconstruction. *Arthroscopy* 2008;24(06):650–659
 - 34 Chen B, Gao S. Double-bundle posterior cruciate ligament reconstruction using a non-hardware suspension fixation technique and 8 strands of autogenous hamstring tendons. *Arthroscopy* 2009;25(07):777–782