



## Original Article

# Evaluation of the results from non-arthroplastic treatment (arthroscopy) for shoulder arthrosis<sup>☆</sup>



Alberto Naoki Miyazaki, Marcelo Fregoneze, Luciana Andrade da Silva\*, Guilherme do Val Sella, José Eduardo Rosseto Garotti, Sergio Luiz Checchia

Department of Orthopedics and Traumatology, Faculdade de Ciências Médicas, Santa Casa de São Paulo, São Paulo, SP, Brazil

## ARTICLE INFO

## Article history:

Received 31 March 2014

Accepted 19 June 2014

Available online 6 July 2015

## Keywords:

Shoulder

Arthroscopy

Osteoarthritis

## ABSTRACT

**Objectives:** To evaluate the functional results from patients with arthrosis who underwent an arthroscopic procedure, in an attempt to correlate these results with the patients' epidemiological profile, surgical technique used, possible complications and postoperative protocol. **Methods:** Between 1998 and 2011, 31 patients (32 shoulders) with shoulder arthrosis underwent arthroscopic treatment performed by the Shoulder and Elbow Group of the Department of Orthopedics and Traumatology of Santa Casa de São Paulo. Primary or secondary cases of shoulder arthrosis under the age of 70 years, in which the rotator cuff was intact, were included. Furthermore, cases in which, despite an indication for an arthroplastic procedure, an attempt to perform an alternative procedure had been chosen, were also included. The following were evaluated: sex, age, dominance, comorbidities, length of time with complaint, associated lesions, etiology, previous treatment, operation performed, postoperative protocol and pre and postoperative active ranges of motion. The functional evaluation was conducted using the UCLA criteria, before and after the operation. The joint cartilage alterations were classified in accordance with Outerbridge and the arthrosis by means of Walch. **Results:** There were statistically significant mean differences in the values for elevation, lateral rotation and medial rotation from before to after the operation ( $p < 0.001$ ) and there was a tendency ( $p = 0.057$ ) toward poor results with greater length of time with complaints before the surgery. The total gain in UCLA score did not have any statistically significant relationship with any of the other variables analyzed.

**Conclusion:** Arthroscopic treatment of glenohumeral arthrosis provided functional improvement of the glenohumeral joint, with significant gains in elevation and lateral and medial rotation, and improvements in function and pain. Greater length of time with complaints was a factor strongly suggestive of worse results.

© 2015 Sociedade Brasileira de Ortopedia e Traumatologia. Published by Elsevier Editora Ltda. All rights reserved.

<sup>☆</sup> Work developed in the Shoulder and Elbow Group, Department of Orthopedics and Traumatology, Faculdade de Ciências Médicas da Santa Casa de São Paulo, Fernandinho Simonsen Wing (DOT – FCMSCSP), São Paulo, SP, Brazil.

\* Corresponding author.

E-mail: [lucalu01@me.com](mailto:lucalu01@me.com) (L.A. da Silva).

<http://dx.doi.org/10.1016/j.rboe.2015.06.008>

2255-4971/© 2015 Sociedade Brasileira de Ortopedia e Traumatologia. Published by Elsevier Editora Ltda. All rights reserved.

## Avaliação dos resultados do tratamento não artroplástico (artroscópico) da artrose do ombro

### R E S U M O

#### Palavras-chave:

Ombro  
Artroscopia  
Osteoartrite

**Objetivos:** Avaliar os resultados funcionais obtidos dos pacientes com artrose submetidos ao procedimento artroscópico e tentar correlacioná-los com o perfil epidemiológico do doente, a técnica cirúrgica usada, as eventuais complicações e o protocolo pós-operatório.

**Métodos:** Entre 1998 e 2011, 31 pacientes (32 ombros) com artrose do ombro foram submetidos ao tratamento artroscópico pelo Grupo de Ombro e Cotovelo do Departamento de Ortopedia e Traumatologia da Santa Casa de São Paulo. Foram incluídos os casos de artrose de ombro primária ou secundária, abaixo dos 70 anos, com manguito rotatório íntegro, e ainda aqueles que, apesar de indicado o procedimento artroplástico, decidiram tentar uma opção. Foram avaliados: sexo, idade, dominância, comorbidades, tempo de queixa, lesões associadas, etiologia, tratamento prévio, operação feita, protocolo pós-operatório e arco de movimento ativo, pré e pós-operatório. A avaliação funcional foi feita pelos critérios da UCLA pré e pós-operatoriamente. As alterações da cartilagem articular foram classificadas por Outerbridge e a artrose por Walch.

**Resultados:** Houve diferença média estatisticamente significativa entre os valores para elevação, rotação lateral e medial pré e pós-operatória ( $p < 0,001$ ) e uma tendência ( $p = 0,057$ ) de maus resultados com o maior tempo de queixa pré-cirúrgica. O ganho total da UCLA não tem relação estatisticamente significativa com todas as outras variáveis analisadas.

**Conclusão:** O tratamento artroscópico da artrose glenoumeral propicia melhoria funcional da articulação glenoumeral, com ganhos significativos de elevação, rotação lateral e medial e melhoria da função e da dor, e o maior tempo de queixa é fator fortemente sugestivo para piores resultados.

© 2015 Sociedade Brasileira de Ortopedia e Traumatologia. Publicado por Elsevier Editora Ltda. Todos os direitos reservados.

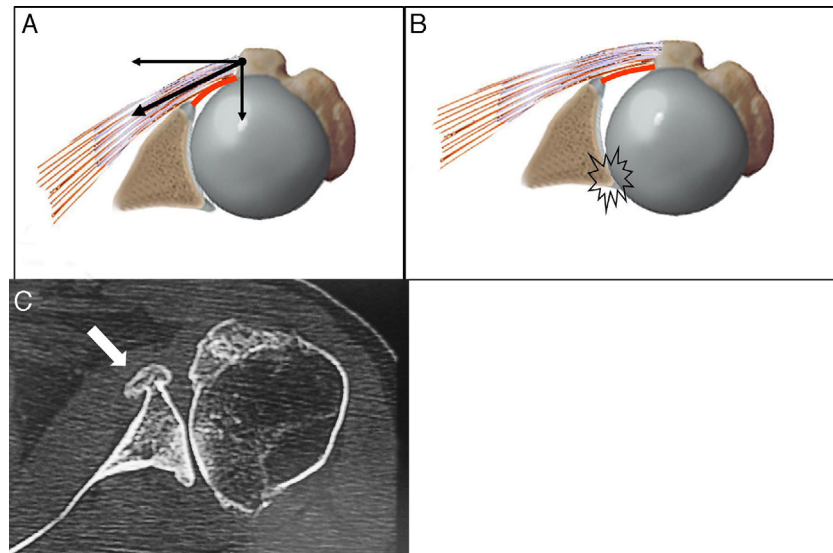
## Introduction

Shoulder arthrosis affects around 20% of the population, with greatest frequency in the sixth and seventh decades of life, and it may occasionally affect younger patients. This disease may follow a course with painful conditions that are generally accompanied by diminished range of motion, especially regarding lateral rotation. Loss of this rotation is associated with contracture of the anterior joint capsule and of the tendon of the subscapularis, which causes a force directed from anterior to posterior and leads to progressive eccentric joint incongruence<sup>1</sup> (Fig. 1A-C).

In advanced cases of arthrosis, or in situations of failure of conservative treatment, surgery is indicated. This consists of arthroplasty to make a partial or total replacement and is considered to be the treatment of choice for elderly patients (over the age of 65 years) and/or individuals with states of disease that are more advanced.<sup>2</sup> Among patients who are younger and more active, with high functional demands on the shoulder joint, this option has not been found to be satisfactory, because of the wear on the components of the prosthesis and because of the need for surgical revision.<sup>2</sup> Among younger patients, the literature cites various complications of this procedure, such as loosening of the implant, dislocation of the prosthesis, periprosthetic fractures and persistent pain.<sup>3-5</sup> Levy et al.<sup>6</sup> observed early appearance of radiolucent areas on radiographic examinations performed on young patients

who had been treated using total shoulder prostheses. Sperling et al.<sup>7</sup> reported that 65% of the prostheses implanted in patients under the age of 50 years produced poor results after 15 years of follow-up, and noted high incidence of erosion of the glenoid in hemiarthroplasty. Thus, at the same time that recent studies have affirmed that the long-term results from treating shoulder arthrosis by means of arthroplasty are encouraging among patients of more advanced age, treatment of younger patients is still considered by many authors to be a challenge.<sup>5,8,9</sup>

The literature shows that surgical procedures that involve shoulder arthroscopy, such as joint debridement, capsulotomy, microfracturing of the glenoid, removal of free bodies and resection of osteophytes, have been shown to be useful for postponing prosthetic replacement of the joint.<sup>8,10</sup> Some authors have obtained satisfactory results over the short term through these procedures, in around 70-88% of the patients.<sup>8,10,11</sup> Simpson and Kelly<sup>12</sup> stated that the association between synovectomy and subacromial decompression and debridement gave rise to a satisfaction rate of 82% among their patients. Richards and Burkhart,<sup>13</sup> and also Millet and Gaskill,<sup>14</sup> concluded that capsulotomy did not prevent the natural evolution of joint degeneration, but it enabled improvement of function and symptoms to the point at which the joint deterioration justified larger-scale surgery. Bishop and Flatow<sup>15</sup> reported that synovectomy is a valuable tool when the initial symptoms of both pain and loss of function do not respond well to conservative treatment. However, they



**Fig. 1 – Drawing of the left shoulder from axial slice, showing: (A) the muscle forces that act on the glenohumeral joint (arrows) and the anterior capsule (in red) and which lead (B) to subsequent subluxation. Axial slice from computed tomography (C) on the left shoulder, showing formation of osteophytes (arrow) and subsequent subluxation.**

concluded that the indications for each procedure still present gaps. Godinho et al.<sup>8</sup> stated that few scientific articles have shown long-term results, even though clinical experience corroborating the hypothesis that this procedure might prolong joint survival already exists.

The aims of this study were to evaluate the functional results obtained from patients with arthrosis who underwent an arthroscopic procedure and to attempt to correlate these results with the patients' epidemiological profile, degree of joint involvement, procedures performed and postoperative protocol.

## Sample and methods

Between January 1998 and December 2011, 31 patients (32 shoulders) with a diagnosis of shoulder osteoarthritis underwent arthroscopic treatment performed by the Shoulder and Elbow Group of the Department of Orthopedics and Traumatology of Santa Casa de São Paulo.

The inclusion criteria were taken to be that the patients should present shoulder arthrosis of primary or secondary etiology, be under the age of 70 years, have an intact rotator cuff and have been followed up postoperatively for a minimum of 12 months. Furthermore, cases in which, despite an indication for an arthroplastic procedure, an attempt to perform an alternative procedure had been chosen, were also included. Patients with secondary diagnoses that made it difficult to evaluate the therapeutic method in question, especially cases in which complete tearing of the rotator cuff had occurred, were excluded.

The patients evaluated comprised 17 males and 14 females, of mean age 54 years (range: 24–67 years), among whom 11 were over the age of 60 years. It was observed that the dominant shoulder was affected in 15 cases.

The mean length of time with a clinical complaint relating to the shoulder was five years (range: two months to 15 years). The most prevalent etiology was idiopathic arthrosis, which was found in 25 cases, followed by post-traumatic arthrosis in six cases and rheumatoid arthritis in one case. The preoperative imaging findings were based on radiographs and magnetic resonance imaging (when done), which pointed toward glenohumeral arthrosis. It was only possible to classify the degree of arthrosis in 14 shoulders and, when this was done, we used the classification of Walch et al.<sup>16</sup> We had three cases of type A1, six A2, three B1, three B2 and only one case that was considered to be type C. The degree of joint impairment was evaluated during the arthroscopic surgical procedure and was classified in accordance with Outerbridge.<sup>17</sup> All the patients were considered to present grade IV, i.e. presenting a lesion extending across the entire thickness of the cartilage, thereby presenting subchondral bone exposure.

The range of motion (ROM) was measured in accordance with the manual of the American Academy of Orthopaedic Surgeons, as described by Hawkins and Bokor.<sup>18</sup> The mean arcs of elevation and lateral and medial rotation before and after the operation can be observed in Table 1. The functional evaluation was made using the UCLA criteria (University of

**Table 1 – Mean change in the range of motion (flexion and external rotation) from before to after the operation.**

Movement	Before operation	After operation	p-Value
Elevation (degrees)	116	140	<0.001
External rotation (degrees)	23	50	<0.001
Internal rotation (vertebral level)	L4	T11	<0.001

Source: Hospital files (SAME).

California, Los Angeles, Shoulder Rating Scale), as proposed by Ellman et al.,<sup>19</sup> both before and after the operation. The length of follow-up among the patients ranged from 1 to 13 years, with a mean of five years and nine months.

The patients underwent arthroscopic surgery in lateral decubitus in order to enable adequate access to the posterior and posteroinferior portions of the capsule. The following stages were performed in a sequential manner: debridement, removal of free bodies, opening of the rotator interval, release of the coracohumeral ligament, anterior capsulotomy, change of portal, posterior capsulotomy, inferior capsulotomy and, finally, anteroinferior capsulotomy with the aid of surgical basket tweezers, in order to avoid injuring the axillary nerve. Some of these steps can be seen in Fig. 2A–D. In three patients, these procedures were considered sufficient. In the other patients, other procedures were added, on a case-by-case basis, and these are described and quantified in Table 2.

After the surgical procedure, the patients underwent a rehabilitation protocol, which consisted of physiotherapy with early mobility. However, two groups were delineated: the first group, composed of 20 patients, had an interscalene catheter for continuous administration of analgesia in the hospital, which was used for four to five days; and the second group, composed of 11 patients, did not have a catheter because it was impossible to use catheters in the older cases.

A significance level of 0.05 (5%) was defined for this study. We used the paired Student's *t* test for statistical analysis on the quantitative ROM and UCLA values,<sup>19</sup> both before and after the operation. The ANOVA test was used to compare the total gain in UCLA score<sup>19</sup> in relation to age groups, dominance, bilaterality and postoperative protocol. The data were tabulated and evaluated using the SPSS V17, Minitab 16 and Excel Office 2010 software.

## Results

In relation to range of motion, there were statistically significant mean differences ( $p < 0.001$ ) between the values for elevation (increase of 24°), lateral rotation (increase of 27°) and medial rotation (increase of five vertebral levels), from before to after the operation, as can be seen in Table 1.

Regarding the type of arthrosis, the patients were classified as described by Walch et al.<sup>16</sup> Type A1 achieved an excellent result (mean of 34 points; range: 32–35). Type A2 (Mean: 28; range: 12–35), type B1 (mean: 33; range: 31–35) and type C (31)

**Table 2 – Description of additional procedures and number of times that they were performed.**

Procedure	Number of cases
Tenotomy of the long head of the biceps	10
Microfractures in the glenoid	2
Resection of osteophytes	4
Acromioplasty	8
Mumford procedure	10
Total	32

Source: Files (SAME) of the Department of Orthopedics and Traumatology of Santa Casa de São Paulo.

**Table 3 – Change in UCLA parameters from before to after the operation.**

Parameter (UCLA)	Before operation <sup>a</sup>	After operation <sup>a</sup>	p-Value
Function	4.83	8.21	<0.001
Active flexion	3.10	4.17	<0.001
Muscle flexion strength	4.90	4.83	0.326
Satisfaction	0.00	3.59	<0.001
Pain	3.21	7.21	<0.001
Total	16.2	28.0	<0.001

Source: Hospital files (SAME).  
<sup>a</sup> Mean score.

were all considered to have achieved good results. However, the type B2 patient scored 12 points, which was a poor result according to the UCLA criteria.<sup>19</sup>

Taking into consideration the UCLA score,<sup>19</sup> the parameters of active flexion, satisfaction, pain and function presented statistically significant increases ( $p < 0.001$ ). Only in relation to muscle strength was there no difference ( $p = 0.326$ ). These findings are presented in Table 3.

From qualitative comparisons, i.e. by means of the percentage relative frequency distribution, it was noted that according to the total UCLA parameter<sup>19</sup> (sum of the scores for each item), there was a decrease in the number of cases classified as poor (0–20 points) and an increase in the numbers of good cases (28–33 points) and excellent cases (34–35 points) with statistical significance ( $p < 0.001$ ). These data are demonstrated in Table 4.

The total gain in UCLA<sup>19</sup> did not have any statistically significant relationship ( $p < 0.001$ ) with age, length of time with the complaint, dominance, duration of postoperative follow-up or postoperative protocol. Longer time with a complaint was a factor strongly suggestive of worse results, with  $p = 0.057$ .

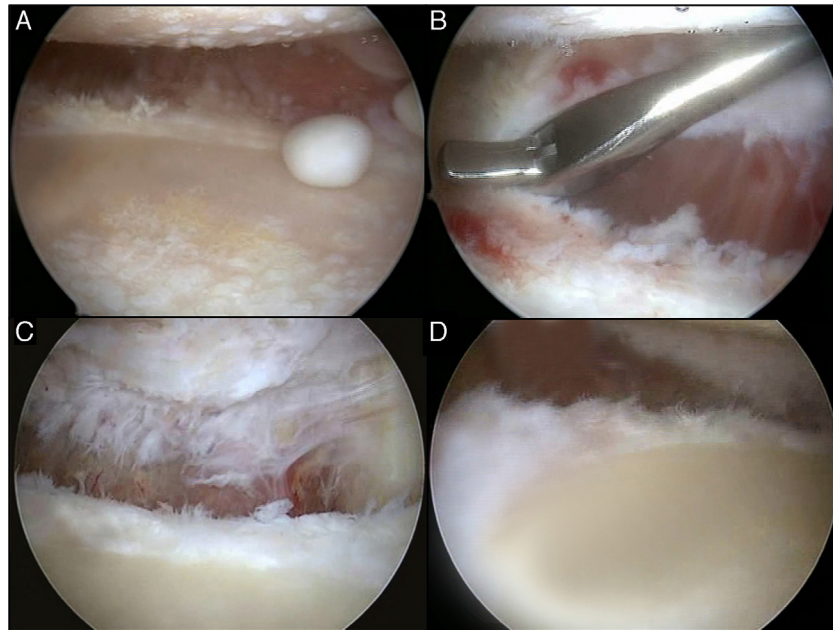
## Discussion

Glenohumeral arthrosis is a chronic degenerative disease that results in significant functional deficits.<sup>8</sup> Replacement with either a total or partial prosthetic provides significant relief from painful conditions and functional improvement.<sup>7,8</sup> However, when this therapy is applied to patients under the age of 50 years, the results presented are unsatisfactory, which suggests that other approaches should be used.<sup>7</sup> The

**Table 4 – Change in frequency of UCLA classification scores from before to after the operation.**

UCLA classification	Before operation (%)	After operation (%)	p-Value
Poor	89.7%	17.2%	<0.001
Fair	10.3%	20.7%	0.277
Good	0	37.9%	<0.001
Excellent	0	24.2%	<0.001
Total	100%	100%	

Source: Hospital files (SAME).



**Fig. 2 – Intraoperative view of left shoulder, with camera positioned in the lateral portal of the left shoulder, showing: (A) arthrosis with loss of all of the cartilage from the humeral head; (B) anterior capsulotomy in progress using basket tweezers; (C) view of inferior capsulotomy; (D) view of posteroinferior capsulotomy.**

literature shows that there have been encouraging results from arthroscopic treatment of glenohumeral osteoarthritis.<sup>8,10-15</sup>

In relation to ROM and UCLA scores,<sup>19</sup> we found that there was a significant difference in the range of motion and UCLA score<sup>19</sup> from before to after the operation ( $p < 0.001$ ). This was also found by Richards and Burkhart<sup>13</sup> and Van Thiel et al.,<sup>20</sup> who showed that there was a significant increase in mobility in their patients after the operation. The detailed UCLA evaluation<sup>19</sup> showed significant differences in the fields of pain, function, active flexion and satisfaction ( $p < 0.001$ ). Godinho et al.<sup>8</sup> also evaluated the UCLA parameters<sup>19</sup> separately and found similar results.

No statistical differences were noted in relation to age, dominance, postoperative protocol used (with or without use of a catheter for administering analgesia) or length of postoperative follow-up. Attention needs to be drawn to the finding that the statistical analysis indicated the suggestion ( $p = 0.057$ ) that the longer the time spent with the complaint was, the worse the results regarding gains in UCLA would be<sup>19</sup> (from before to after the operation). We would need a larger number of patients to be able to confirm this tendency.

Among the procedures performed during arthroscopic treatment, Richards and Burkhart<sup>13</sup> highlighted capsulotomy and removal of joint debris as factors that predisposed toward gains in elevation and lateral and medial rotation and reductions in painful conditions, within treatments for glenohumeral osteoarthritis, which was also found in the present study, with statistical significance ( $p < 0.001$ ) in relation to improvement of both the range of motion and patients' satisfaction with the procedure, although it was not noted which procedure would be more influential for the final result.

All the patients were classified as Outerbridge grade IV<sup>17</sup> and 62.1% of the results were classified as satisfactory, according to the UCLA criteria.<sup>19</sup> Cameron et al.<sup>3</sup> published a satisfaction rate of 87% among 61 patients who underwent an arthroscopic procedure with the same classification. These authors believed that the size of the lesion would influence the surgical results. In their view, lesions larger than 2 cm would have a worse prognosis. On the other hand, Kerr and McCarty<sup>4</sup> believed that the location of the lesion was more important than its severity. They showed that patients with grade II and III lesions had the same results as those with grade IV. However, patients in whom the alteration occurred on both sides of the joint (humeral head and glenoid) had a worse prognosis than that of patients who were only affected on one side. The size of the lesion was not a factor that we observed in this study and, for this reason, can be considered to be a limiting factor. Likewise, the impossibility of classifying the degree of arthrosis using the preoperative radiographic images in 18 cases is a limiting factor. Unfortunately, these patients were operated at a time when magnetic resonance image was not yet performed routinely and/or shoulder radiography presented dubious quality. Out of the 14 patients who could be classified, we had one classified as type C of Walch et al.<sup>16</sup> Despite evident erosion of the glenoid, this patient achieved a result that was considered good (31 points) according to the UCLA score.<sup>19</sup> On the other hand, one patient classified as type A2, i.e. with a concentric joint, and one of type B2, with some posterior subluxation, had poor results, with 12 points in total. Ogilvie-Harris and Willey<sup>21</sup> evaluated 54 patients who underwent arthroscopic surgery due to glenohumeral arthrosis, of whom 29 presented associated diseases. Satisfactory results were achieved both in patients with mild conditions and in

those with severe conditions, i.e. independently of the degree of arthrosis.

In the literature, several authors have believed that certain factors such as presence of joint space on preoperative radiographs, small loss of movement (in which there would still be at least 20° of lateral rotation) and the absence of large osteophytes and/or concentric joint or at most mild subluxation (which could be corrected by means of joint release with or without glenoplasty), would lead to better results.<sup>20,22,23</sup>

What we can state is that after a mean length of follow-up of approximately six years, only five patients (15.6%) had undergone arthroplasty. This finding is consonant with the data in the literature. From following up 71 patients who underwent arthroscopic treatment for glenohumeral arthrosis, Van Thiel et al.<sup>20</sup> found that 22% of their cases with a mean follow-up of 10 months had undergone arthroplasty.

In relation to the other 28 patients, these continue not to have any clinical need for new surgery, i.e. replacement of the prosthesis. Nine patients have been followed up since the operation for more than eight years, and this corroborates the proposition that arthroscopic treatment in cases of glenohumeral arthrosis extends the survival of the joint.<sup>8</sup>

## Conclusion

Arthroscopic treatment of glenohumeral arthrosis provides functional improvement of the glenohumeral joint, with significant gains ( $p < 0.001$ ) in elevation and in lateral and medial rotation, and improvements in function and pain. Longer time spent with a complaint was a factor strongly suggestive of worse results ( $p = 0.057$ ).

## Conflicts of interest

The authors declare no conflicts of interest.

## REFERENCES

- Nakagawa Y, Hyakuna K, Otani S, Hishitani M, Nakamura T. Epidemiologic study of glenohumeral osteoarthritis with plain radiography. *J Shoulder Elbow Surg.* 1999;8:580-4.
- Jain NB, Hocker S, Pietrobon R, Guller U, Bathia N, Higgins LD. Total arthroplasty versus hemiarthroplasty for glenohumeral osteoarthritis: role of provider volume. *J Shoulder Elbow Surg.* 2005;14(4):361-7.
- Cameron BD, Galatz LM, Ramsey ML, Williams GR, Iannotti JP. Non-prosthetic management of grade IV osteochondral lesions of the glenohumeral joint. *J Shoulder Elbow Surg.* 2002;11:25-32.
- Kerr BJ, McCarty EC. Outcome of arthroscopic debridement is worse for patients with glenohumeral arthritis of both sides of the joint. *Clin Orthop Relat Res.* 2008;466:634-8.
- Denard PJ, Wirth MA, Orfaly RM. Management of glenohumeral arthritis in the young adult. *J Bone Surg Am.* 2011;93(9):885-92.
- Levy JC, Virani NA, Frankle MA, Cuff D, Pupello DR, Hamelin JA. Young patients with shoulder chondrolysis following arthroscopic shoulder surgery treated with total shoulder arthroplasty. *J Shoulder Elbow Surg.* 2008;17:380-8.
- Sperling JW, Cofield RH, Rowland CM. Minimum fifteen-year follow-up Neer hemiarthroplasty and total shoulder arthroplasty in patients aged fifty years or younger. *J Shoulder Elbow Surg.* 2004;13(6):604-13.
- Godinho GG, Santos FML, Freitas MAF. Tratamento videoartroscópico da osteoartrite glenoumeral. *Rev Bras Ortop.* 2013;48(1):69-79.
- Deshmukh AV, Koris M, Zurakowski D, Thornhill TS. Total shoulder arthroplasty: long-term survivorship, functional outcome, and quality of life. *J Shoulder Elbow Surg.* 2005;14(5):471-9.
- Van der Meijden OA, Gaskil TR, Millett PJ. Glenohumeral joint preservation: a review of management options for young, active patients with osteoarthritis. *Adv Orthop.* 2012;2012:160923. <http://dx.doi.org/10.1155/2012/160923>.
- Cole BJ, Yanke A, Provencher MT. Nonarthroplasty alternatives for the treatment of glenohumeral arthritis. *J Shoulder Elbow Surg.* 2007;16 Suppl. 5:S231-40.
- Simpson NS, Kelly IG. Extra-glenohumeral joint shoulder surgery in rheumatoid arthritis: the role for bursectomy, acromioplasty, and distal clavicle excision. *J Shoulder Elbow Surg.* 1994;3:66-9.
- Richards DP, Burkhart SS. Arthroscopic debridement and capsular release for glenoumeral osteoarthritis. *Arthroscopy.* 2007;23(9):1019-22.
- Millett PJ, Gaskil TR. Arthroscopic management of glenohumeral arthrosis: humeral osteoplasty, capsular release, and arthroscopic axillary nerve release as a joint-preserving approach. *Arthroscopy.* 2011;27(9):1296-303.
- Bishop JY, Flatow MD. Management of glenohumeral arthritis: a role for arthroscopy? *Orthop Clin North Am.* 2003;34:559-66.
- Walch G, Badet R, Boulahia A, Khoury A. Morphologic study of the glenoid in primary glenohumeral osteoarthritis. *J Arthroplasty.* 1999;14(6):756-60.
- Outerbridge RE. The etiology of chondromalacia patellae. *J Bone Joint Surg Br.* 1961;43:752-7.
- Hawkins RJ, Bokor DJ. Clinical evaluation of shoulder problems. In: Rockwood CA Jr, Matsen FA 3rd, editors. *The shoulder.* 2nd ed. Saint Louis: Saunders; 1998. p. 164-98.
- Ellman H, Hunker G, Bayer M. Repair of the rotator cuff. Endresult study of factors influencing reconstruction. *J Bone Joint Surg Am.* 1986;68(8):1136-44.
- Van Thiel GS, Sheehan S, Frank RM, Slabaugh M, Cole BJ, Nicholson GP, et al. Retrospective analysis of arthroscopic management of glenohumeral degenerative disease. *Arthroscopy.* 2010;26(110):1451-5.
- Ogilvie-Harris DJ, Willey AM. Arthroscopic surgery of the shoulder. *J Bone Joint Surg Br.* 1986;68(2):201-7.
- Weinstein DM, Bucchieri JS, Pollock RG, Flatow EL, Bigliani LU. Arthroscopic debridement of the shoulder for osteoarthritis. *Arthroscopy.* 2000;16(5):471-6.
- Porcellini G, Merolla G, Campi F, Pellegrini A, Bodanki CS, Paladini P. Arthroscopic treatment of early glenohumeral arthritis. *J Orthop Traumatol.* 2013;14(1):23-9.