





# Updating on Bone and Soft Tissue Sarcomas Staging\*

## Atualização no estadiamento dos sarcomas ósseos e das partes moles

Alex Guedes<sup>1</sup> Marcelo Bragança dos Reis Oliveira<sup>2</sup> Flávia Martins Costa<sup>3</sup>  
Adelina Sanches de Melo<sup>4</sup>

<sup>1</sup>Oncologic Orthopedics Group, Orthopedics Service, Santa Izabel Hospital, Santa Casa de Misericórdia da Bahia, Salvador, BA, Brazil

<sup>2</sup>Traumatology and Orthopedics Service, Hospital Universitário Clementino Fraga Filho, Universidade Federal do Rio de Janeiro, Rio de Janeiro, RJ, Brazil

<sup>3</sup>Department of Radiology, Universidade Federal Fluminense, Niterói, RJ, Brazil

**Address for correspondence** Alex Guedes, PhD, Rua Padre Feijó 139, Apartamento 203, Canela, Salvador, BA, 40110-170, Brazil (e-mail: alexguedes2003@yahoo.com.br).

<sup>4</sup>Nuclear Medicine Service, Hospital Santa Izabel, Santa Casa da Misericórdia da Bahia, Salvador, BA, Brazil

Rev Bras Ortop 2021;56(4):411–418.

### Abstract

#### Keywords

- ▶ neoplasm staging
- ▶ sarcoma
- ▶ neoplasms, connective tissue
- ▶ neoplasms, bone tissue
- ▶ diagnostic imaging
- ▶ pathology, surgical

Bone and soft tissue sarcomas consist of a heterogeneous group of malignant tumors of mesenchymal origin that can affect patients from any age. The precise staging of these lesions determines the best therapeutic strategies and prognosis estimates. Two staging systems are the most frequently used: the system proposed by the University of Florida group, led by Dr. William F. Enneking (1980) and adopted by the Musculoskeletal Tumor Society (MSTS), and the system developed by the American Joint Committee on Cancer (AJCC) (1977), currently in its 8<sup>th</sup> edition (2017). This paper updates the reader on the staging of bone and soft tissue sarcomas affecting the musculoskeletal system.

### Resumo

#### Palavras-chave

- ▶ estadiamento de neoplasias
- ▶ sarcoma
- ▶ neoplasias de tecido conjuntivo
- ▶ neoplasias de tecido ósseo
- ▶ diagnóstico por imagem
- ▶ patologia cirúrgica

Os sarcomas ósseos e das partes moles consistem em grupo heterogêneo de neoplasias malignas de origem mesenquimal que podem ocorrer em qualquer faixa etária. O estadiamento preciso destas lesões determina as melhores estratégias terapêuticas e estimativas de prognóstico. Dois sistemas de estadiamento são os mais frequentemente empregados no manejo destas neoplasias: o sistema proposto pelo grupo da Universidade da Flórida, liderado pelo Dr. William F. Enneking (1980), adotado pela *Musculoskeletal Tumor Society* (MSTS) e o sistema desenvolvido pela *American Joint Committee on Cancer* (AJCC) (1977) que se encontra em sua 8<sup>a</sup> edição (2017). O presente artigo busca atualizar o leitor a respeito do estadiamento dos sarcomas ósseos e das partes moles que acometem o sistema musculoesquelético.

\* Study performed at Oncologic Orthopedic Group, Orthopedic Service, Santa Izabel Hospital, Santa Casa de Misericórdia da Bahia, Salvador, BA, Brazil, and at the Traumatology and Orthopedics Service, Hospital Clementino Fraga Filho, Universidade Federal do Rio de Janeiro, Rio de Janeiro, RJ, Brazil.

received  
September 25, 2019  
accepted  
February 20, 2020  
published online  
September 30, 2020

DOI <https://doi.org/10.1055/s-0040-1710331>.  
ISSN 0102-3616.

© 2020. Sociedade Brasileira de Ortopedia e Traumatologia. All rights reserved.

This is an open access article published by Thieme under the terms of the Creative Commons Attribution-NonDerivative-NonCommercial-License, permitting copying and reproduction so long as the original work is given appropriate credit. Contents may not be used for commercial purposes, or adapted, remixed, transformed or built upon. (<https://creativecommons.org/licenses/by-nc-nd/4.0/>)

Thieme Revinter Publicações Ltda., Rua do Matoso 170, Rio de Janeiro, RJ, CEP 20270-135, Brazil

## Introduction

Bone and soft tissue sarcomas affect, respectively, 1 and 5 subjects per 100,000 people/year. Together, they account for ~ 1% of all malignancies in humans.<sup>1</sup>

Since the most frequent clinical manifestations of bone and soft tissue sarcomas are pain and a mass at the affected segment, respectively, orthopedic surgeons often are the first specialists to evaluate affected patients. In case of clinical suspicion, specialized management, through appropriate imaging tests for staging and planning, in addition to a biopsy, will allow accurate and timely diagnosis and fast start of an adequate treatment, which is critical to preserve the affected limb and cure the disease.

By definition, sarcomas potentially develop metastases,<sup>2</sup> which impact the prognosis.

Staging consists in approaching the patient from the initial examination to the histological diagnosis and definitive classification of a tumor.<sup>2</sup>

For decades, staging has been a critical tool to estimate prognosis, support therapy-related decisions and stratify patients into risk categories for clinical trials.<sup>2,3</sup> The Union for International Cancer Control (UICC) defined the main goals of staging: guide therapeutic planning; estimate prognosis; help evaluate treatment outcomes; make interinstitutional communication effective; and contribute to scientific research.<sup>4</sup>

Cancer staging is considered essential for disease control.<sup>5</sup> Several systems have been described to stage primary malignant tumors of musculoskeletal system.<sup>3-12</sup> However, the system proposed by William F. Enneking et al. and adopted by the Musculoskeletal Tumor Society (MSTS)<sup>6</sup> and the system developed by the American Joint Committee on Cancer (AJCC)<sup>8,9</sup> are the most used in the clinical practice. The present paper aims to update the reader on bone and soft tissue sarcomas staging, using the Enneking/MSTS system<sup>6</sup> and the TNM classification (AJCC), in its 8<sup>th</sup> edition (2017).<sup>8,9</sup>

## Role of Imaging and Pathology in Evaluating Bone and Soft Tissue Sarcomas

Musculoskeletal tumors are diagnosed in at least one of the following clinical scenarios: pain, bony prominence, palpable soft tissue mass, pathological fracture, or incidental finding on imaging studies.<sup>12</sup>

Clinical history and physical examination are often sufficient to raise suspicion on a musculoskeletal tumor, although radiographic examination is the most common test to reveal it.<sup>13,14</sup>

Imaging is used for detection, diagnosis and differential diagnosis, as well as evaluation (staging) of primary malignant musculoskeletal tumors.<sup>13</sup>

Conventional, orthogonal radiographs provide information regarding appearance, intraosseous extension, tumor matrix, and margins between the tumor and host bone. Cortical destruction and periosteal reaction are associated with invasive bone tumors.<sup>14,15</sup> In soft tissue tumors, radiographs allow the detection and definition of the mineraliza-

tion pattern of a lesion, aiding the diagnosis/differential diagnosis with other tumors or pseudotumoral lesions (ossifying myositis, tumor calcinosis, vascular malformations, gout, extraskeletal mesenchymal chondrosarcoma, extraskeletal osteosarcoma, liposarcoma and synovial sarcoma); in addition, they reveal valuable information on tumor density (adipocytic tumors) and possible underlying bone involvement.<sup>14,16</sup>

In view of a bone or soft tissue lesion with clinical and radiographic characteristics denoting biological aggressiveness, additional imaging tests are required<sup>12</sup> to determine local extension, distant spread (metastases) and histological diagnosis (►Figure 1).

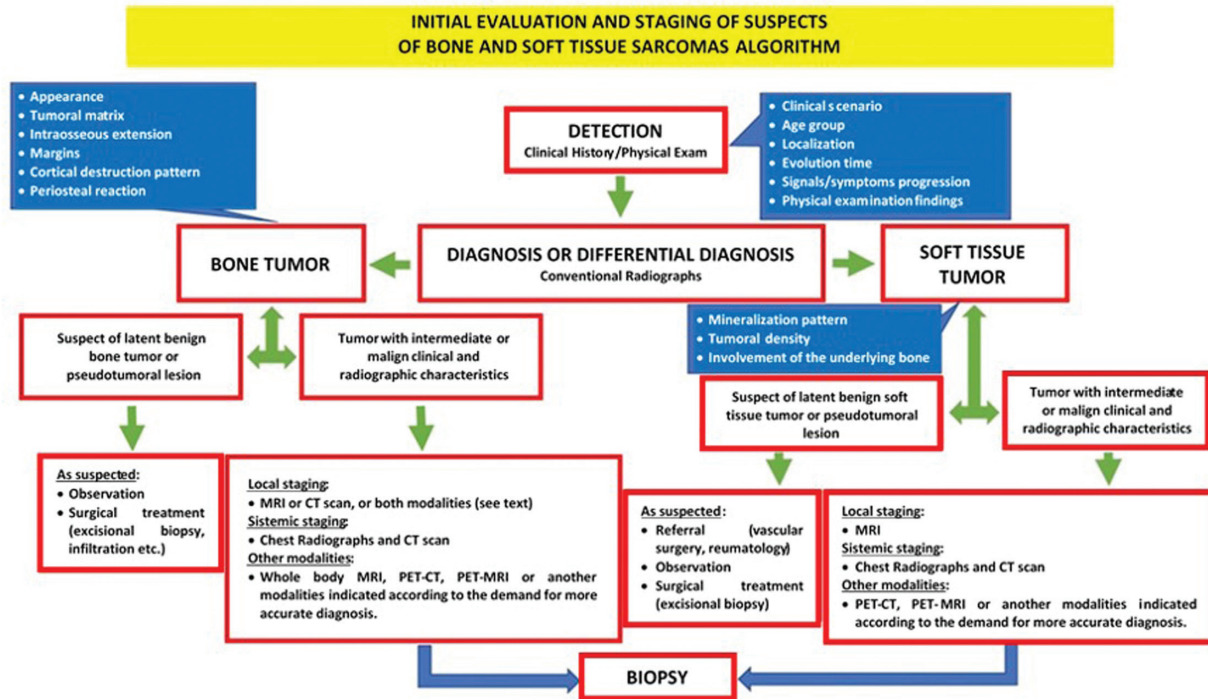
### Local Staging

Local extension of a sarcoma is defined by the involved anatomical spaces. Understanding the relevant topographic anatomy is crucial to define the best therapeutic approach to each clinical situation.<sup>17</sup>

In appendicular segments, joint capsule and cartilage, cortex, periosteum fascial septa, muscle origins and attachments act as natural barriers to tumoral dissemination, defining compartments; a tumor confined to a compartment is considered intracompartmental, which is a stage below to a lesion surpassing such barriers to become extracompartmental. Sarcomas grow centrifugally through lower resistance areas and they are partially contained by a pseudocapsule, in which they can remain confined. Malignant cells, however, tend to extend themselves beyond these limits; if this occurs, but the tumor remains confined to a given anatomical compartment, the lesion is deemed extracapsular and intracompartmental; if the lesion invades an adjacent compartment, it is classified as extracompartmental.<sup>18</sup>

The multiplanar assessment and soft tissue enhancement provided by magnetic resonance imaging (MRI) or, if this modality is contraindicated or unavailable,<sup>8,11</sup> computed tomography (CT) with contrast media, made these imaging tests indispensable to local staging<sup>19</sup>; occasionally, MRI and CT can be requested together, as they provide additional information that helps delineating the lesions under study.<sup>17</sup> It is worth mentioning that these tests must be performed before biopsy to avoid artifacts interfering with image interpretation.<sup>20</sup>

Magnetic resonance imaging is considered superior to CT for the local staging of bone sarcomas and constitutes the mainstay in imaging evaluation of soft tissue sarcomas.<sup>20</sup> Regarding lesion morphology, the main factors for staging are size and local extension,<sup>21</sup> which are best assessed by gadolinium-enhanced MRI using advanced perfusion and diffusion techniques<sup>19</sup> to determine lesion configuration, location, depth, size and local extension, as well as its relationship with adjacent muscles, muscle compartments, fascial planes, neurovascular structures, joints and organs (►Figures 2 and 3).<sup>15,18</sup> It is mandatory to image the entire affected anatomical segment (whole bone) to define intramedullary involvement extension and identify eventual discontinuous bone tumors (skip metastasis), which presence has important prognostic implications.<sup>6,11,14,15,20</sup>



**Fig. 1** Algorithm for initial evaluation and imaging staging of suspected bone and soft tissue sarcomas.

The choice for MRI or CT in bone sarcoma evaluation may be based on radiographic findings. In cases with cortical destruction and extracompartmental tumor, MRI is the preferred modality because it provides excellent soft tissue enhancement and it is better in determining extraosseous tumoral extension compared with CT.<sup>19</sup> Magnetic resonance imaging allows more accurate staging due to its multiplanar (sagittal, coronal, axial and oblique) imaging ability and the lack of CT-associated beam hardening artifacts from cortical bone.<sup>19</sup> Although rarely useful in specific diagnoses, CT is indicated when there is no radiographic evidence of tumor extension to soft tissues, as it improves calcification visualization, periosteal reaction detection, cortical subtle invasion or destruction and intraosseous extension determination.<sup>3,19</sup> Computed tomography is also useful to delineate tumors in complex anatomical structures such as the axial skeleton and the pelvic and scapular girdles, in addition to allow a better and more understandable demonstration of surface bone sarcomas, such

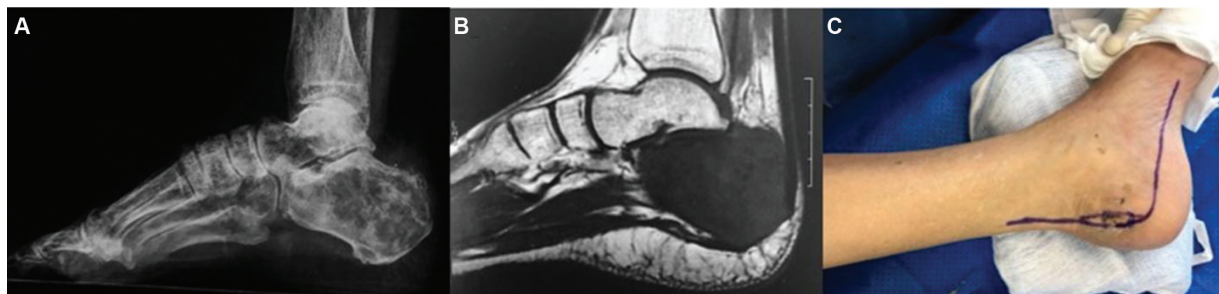
as parosteal osteosarcoma or juxtacortical chondrosarcoma, through three-dimensional reconstruction.<sup>19</sup>

**Systemic Staging**

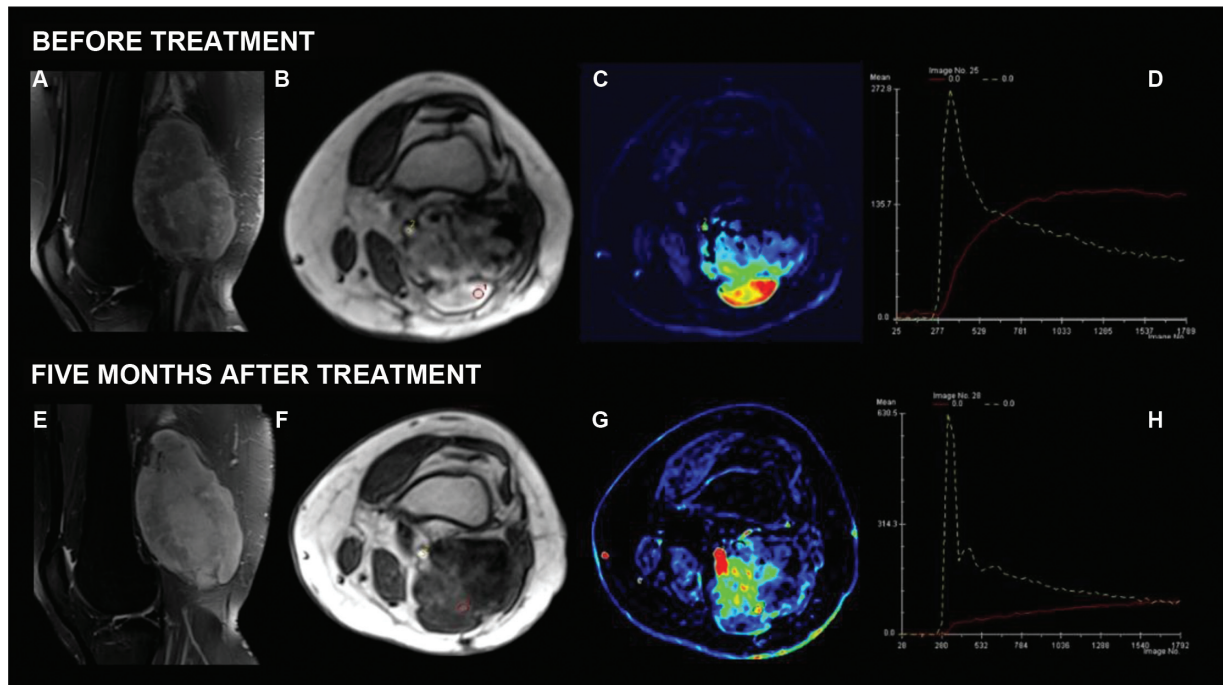
Distant spread is the main prognostic factor for bone and soft tissue sarcomas. Sarcomas have preferential hematogenous diffusion pathways, and the lungs and the skeleton are the most frequent sites for metastatic development. Although less frequent, lymphatic involvement has prognostic importance, and some histological subtypes of soft tissue sarcomas (such as synovial sarcoma, epithelioid sarcoma, clear cell sarcoma and angiosarcoma) usually affect locoregional lymph nodes.<sup>14,22</sup>

Lung evaluation uses chest X-rays in two views, and/or, preferably,<sup>8</sup> high-resolution chest CT, which is more sensitive for lesion detection.<sup>2,11,14</sup>

The National Comprehensive Cancer Network (NCCN) recommends abdominal and pelvic CT for staging some soft tissue sarcomas which tend to metastasize to those



**Fig. 2** Conventional calcaneal osteosarcoma. (A) Lateral radiography showing calcaneal lytic and sclerotic areas. (B) Sagittal magnetic resonance imaging in T1-weighted sequence showing diffuse hyposignal in the calcaneus with no extracompartmental tumor. (C) Surgical approach for calcaneus resection. Musculoskeletal Tumor Society (MSTS) staging, IA; American Joint Committee on Cancer (AJCC) staging, IIA.



**Fig. 3** High-grade pleomorphic sarcoma at the right knee. Proton density sequences with fat suppression in the sagittal plane before treatment (A) showing a heterogeneous lesion in the posterior compartment. Axial dynamic study (B) and color map (C) showing early enhancement in the posterior and superficial portion of the lesion (red line in D). Five months after treatment, a conventional magnetic resonance imaging does not show a significant change in lesion signal intensity (E). However, the dynamic axial study (F) and color map (G) show a change in the pattern of lesion enhancement (red line in H), indicating good therapeutic response. Histological analysis showed more than 90% of tumor necrosis. American Joint Committee on Cancer (AJCC) staging, IIIA.

sites, including myxoid liposarcoma, epithelioid sarcoma, leiomyosarcoma and angiosarcoma.<sup>14,23,24</sup>

Bone scintigraphy must be included in bone sarcoma staging to scan the skeleton for similar lesions or metastatic bone disease.<sup>2,8</sup> Bone scanning is not routinely indicated in the initial staging of soft tissue sarcomas.<sup>14</sup>

The routine indication of full body MR,<sup>2</sup> PET-CT<sup>2,8</sup> or PET-MR<sup>2</sup> it is still under scrutiny for bone and soft tissue sarcomas staging. However, when necessary, additional imaging modalities can be used to assess suspicious sites since the exact staging of the disease impacts the treatment and clinical outcome.<sup>2</sup>

### Histological Diagnosis

Biopsy completes the clinical staging process,<sup>8</sup> confirming the diagnosis and determining the histological grade of the sarcoma through anatomopathological examination, complemented by immunohistochemistry and molecular biology when required.

In patients with suspected sarcoma, biopsy must be performed preferably at a referral center with expertise in treating this tumor.<sup>8</sup> Imaging evaluation must precede the biopsy.<sup>8,20</sup>

A tumor sample must be obtained through percutaneous biopsy with a core needle guided by the appropriate imaging method (ultrasound, CT, fluoroscopy, etc.), or incisional biopsy. Biopsy location must be carefully planned to allow resection of the entire path along with the surgical specimen at the time of definitive tumor resection.<sup>8</sup>

Subtype and histological grade may predict the tumor biological behavior, a variable with greatest impact on the risk for metastatic dissemination and overall survival.<sup>11</sup> The histological grade correlates with tumor cell proliferation pattern, mitotic activity and metastatic potential.

Histologically, sarcomas are classified as high or low grade according to cell atypia, number of mitosis figures, necrosis degree and vascularization.<sup>22</sup> Low-grade lesions often present lower biological activity, minimal metastatic potential, require less radical surgical treatment, and are not indicated for adjuvant chemotherapy and/or radiotherapy, since these treatments are usually ineffective due to reduced cell proliferation. On the other hand, high-grade lesions often require more radical local and systemic treatment due to their aggressive biological behavior.<sup>22</sup>

### Musculoskeletal Tumor Society (MSTS) Staging System

In 1980, the MSTS adopted the surgical staging system for musculoskeletal system sarcomas created in Gainesville, 1977, by the University of Florida group led by Dr. William F. Enneking, from data collected between 1968 and 1976.<sup>5,6</sup> This system is based on the definition of tumor extension in relation to anatomical limits and histological grading, bringing together the most important prognostic factors in a concise classification to estimate survival, guide surgical treatment and indicate potential adjuvant therapies.<sup>5,6</sup> Since it is based on surgical observations, MSTS parameters are intuitive, facilitating operative planning. The MSTS staging

system is the most used system by orthopedic oncologists, but it is less employed in soft tissue sarcomas staging, especially by clinical oncologists, oncologic surgeons and other specialists.<sup>11</sup>

This system combines three variables: histopathological grade (I = low grade, II = high grade), local extension beyond the original compartment (A = intracompartmental, B = extracompartmental) and the presence of distant metastases (III) (– **Table 1**).<sup>5,6</sup> Low-grade (I) lesions correspond to Broder class 1 or 2 (low mitotic rate, low nucleus/cytoplasm ratio, limited pleomorphism, low risk [ $<25\%$ ] for metastases). High-grade lesions (II) correspond to Broder class 3 and 4 (mitotic figures, prominent nuclei, pleomorphism, higher incidence of metastases). Subcategories A (intracompartmental) and B (extracompartmental) are defined by imaging of the affected segment. Stage III represents any tumor with distant metastasis at imaging modalities.<sup>5,6</sup>

Staging determines surgical resection extension, considering the feasibility of obtaining adequate oncological margins. A high-grade lesion usually is more biologically aggressive and, therefore, it is more likely to invade surrounding tissues, increasing the risk for local recurrence and metastasis; in such cases, adjuvant therapies are recommended to eradicate tumor cells that would remain after surgical resection.<sup>6</sup>

The main disadvantages of the MSTS system are: 1. it does not include tumor size, implicated as an important prognostic factor for several subtypes of soft tissue sarcomas (larger lesions tend to have greater metastatic potential and may benefit from neoadjuvant chemotherapy)<sup>5</sup>; 2. it has limited discriminatory prognostic power for the intermediate strata due to its simplified variable dichotomization (histological degree, local and distant extension), tending to group most osteosarcomas and Ewing sarcomas at the same stage; osteosarcomas are usually classified as stage IIB; for Ewing sarcomas, the limitation is more evident because this is a high-grade malignancy and the histological grade is not a variable, preventing their classification as IA<sup>10</sup>; 3. skull-originated lesions have different clinical behavior and cannot be classified using this system<sup>5</sup>; 4. it does not consider the presence of a continuous epidural compartment in spinal tumors, a variable with neurological implications (possible spinal cord and spinal roots sacrifice and need for stabilization).<sup>5</sup>

## American Joint Committee (AJCC) on Cancer Staging System

The staging system proposed by the AJCC for musculoskeletal sarcomas, since its original description as the Manual for Staging of Cancer (MSC) in 1977,<sup>25</sup> was updated and refined based on the evolution of scientific evidence on the prognosis and survival associated with such tumors.

### Primary Malignant Bone Tumors Staging (AJCC)

The MSC, on its 1<sup>st</sup> edition (1977),<sup>25</sup> recommended a protocol for primary malignant bone tumors developed by the Task Force On Primary Malignant Bone Tumor to record patient identification, history, clinical data, imaging (radiographs), pathological reports, histological (World Health Organization [WHO] classification of primary bone tumors and pseudotumor lesions) and recurrences or metastases during follow-up. It did not indicate a specific system for sarcoma staging, but it suggested that prospective clinical studies, with a greater number of cases, would allow the creation of a satisfactory clinical classification for staging and outcomes recording in the future.

Starting at its 2<sup>nd</sup> edition<sup>26</sup> (1983), the MSC included a system for staging such tumors based on the TGNM method: tumor size (T), histological grade (G), presence or not of regional lymph node metastasis (N) and presence or not of distant metastasis (M). At this point, stages were already defined (IA, IB, IIA, IIB, III, IVA, IVB), and a prognostic grading was attributed based on the combined evaluation of these variables.

Up to its 6<sup>th</sup> edition (2002),<sup>21</sup> the MSC defined tumor extension as contained or not in the host bone, like the Enneking/MSTS system. The size of eight centimeters became the cutoff point between the T1 and T2 designations, replacing tumor extension classification as intra- or extracompartmental. The choice was controversial<sup>27</sup> because it was based on the literature regarding Ewing sarcoma, limited to osteosarcoma. Later studies confirmed its value in Ewing sarcoma staging<sup>28</sup> and, to date, the MSC recommends that the size of nine centimeters is the best prognostic indicator for osteosarcoma. The addition of the T3 designation for skip metastasis<sup>9,16</sup> was another modification – Wuisman et al.<sup>29</sup> compared 224 patients without skip metastasis at diagnosis with 23 patients who presented such lesions. Twenty two of these 23 individuals had local recurrence or distant

**Table 1** Staging system adopted by the Musculoskeletal Tumor Society for malignant musculoskeletal tumors based on the surgical degree, local extension and the presence or not of metastases

| Stage | Grade     | Site                    | Metastasis                     |
|-------|-----------|-------------------------|--------------------------------|
| IA    | Low (G1)  | Intracompartmental (T1) | M0                             |
| IB    | Low (G1)  | Extracompartmental (T2) | M0                             |
| IIA   | High (G2) | Intracompartmental (T1) | M0                             |
| IIB   | High (G2) | Extracompartmental (T2) | M0                             |
| III   | Any G     | Any T                   | Regional or distant metastasis |

Source: Enneking et al.<sup>6</sup>

metastasis and died; adjuvant chemotherapy did not improve their prognosis. The 3<sup>rd</sup> update consisted of differentiating metastases according to location, distinguishing between pulmonary (IVA) and extrapulmonary (IVB) lesions based on evidence that bone sarcomas with pulmonary metastases had better prognostic compared to those with metastases at other sites<sup>30,31</sup>—multiple lung metastases were associated with a worse prognosis, although this variable was not included in any staging system.<sup>11,30</sup>

In its 7<sup>th</sup> edition (2010), the MSC<sup>32</sup> restricted the definition of stage III only to grade 3 (poorly differentiated) and grade 4 (undifferentiated) tumors. The same staging was employed, regardless of the primary site, for bone and soft tissue sarcomas.

The 8<sup>th</sup> (current) MSC edition,<sup>9</sup> published in 2017, brought new changes. The main one was the inclusion of defined axial skeleton segments as part of the (T) classification, with three sites for bone sarcomas: (i) appendicular skeleton, trunk, skull and facial bones; (ii) spine and (iii) pelvis. Although it does not affect tumor staging, this inclusion allowed the determination of a structure for future research to improve the system – studies have shown evidence that bone sarcomas with axial location have markedly worse prognosis.<sup>33</sup>

Bone and soft tissue sarcomas have been described separately, according to primary sites, mainly due to differences in prognosis and treatment strategy (► **Table 2**). The histopathological grade (G) was also changed, from four to three levels, with stage III reserved for G2-G3 (high grade tumors) and eliminating the G4 designation, as recommended by the American College of Pathologists, which uses the system from the *Fédération Nationale des Centres de Lutte Contre le Cancer* (FNCLCC) to classify soft tissue sarcomas.<sup>9</sup> This change provided uniformity to bone and soft tissue sarcomas classification.<sup>11</sup>

### Soft Tissue Sarcoma Staging (AJCC)

The AJCC staging system for soft tissue sarcomas is the most used to stratify prognoses and define the approach to these

tumors. It considers additional factors to estimate prognosis and enables better interdisciplinary communication. In contrast to bone sarcomas, which have few histological subtypes, the numerous subtypes of soft tissue sarcomas require a more complex staging.<sup>11</sup>

Since its 1<sup>st</sup> edition (1977),<sup>25</sup> the MSC included the TGNM system for staging these tumors; based on the combined assessment of these variables, stages IA, IB, IIA, IIB, IIIA, IIIB, IIIC, IVA and IVB were defined, each with an assigned prognostic score. This classification remained in its 2<sup>nd</sup> edition (1983)<sup>26</sup> and presents gradual changes since the 3<sup>rd</sup> edition (1988)<sup>34</sup> to reflect new clinical evidence.

The AJCC manual, in its 6<sup>th</sup> edition,<sup>21</sup> considered angiosarcoma and malignant mesenchymoma as exceptions and removed them, while gastrointestinal stromal tumor (GIST) and Ewing soft tissue sarcoma were added. Moreover, G1-2, T2b, N0 M0 tumors were reclassified as stage I instead of stage II.

In its 7<sup>th</sup> edition, the AJCC manual<sup>32</sup> removed fibromatosis, Kaposi sarcoma, infantile fibrosarcoma and GIST from the system. N1 disease was reclassified as stage IIIB instead of stage IV based on level IV evidence – the classic study by Fong et al.<sup>35</sup> demonstrated that patients with soft tissue sarcomas and positive lymph nodes have a survival rate similar to those with locally advanced disease, but better than those with distant metastases.<sup>35-37</sup> The histological grading system was also changed to three levels, as recommended by the College of American Pathologists, based on level II evidence that the FNCLCC system predicts survival with significant accuracy.<sup>38</sup> The tumor depth variable was also removed from the classification for staging and prognosis determination<sup>11</sup>; the recommendations for describing tumors as superficial or deep to the fascia were maintained, but considered irrelevant in staging. Rydholm et al.<sup>39</sup> showed that depth was a prognostic factor when analyzed regardless of tumor size. Since other studies suggested worse survival with deeper tumors, it remained part of the staging process for soft tissue sarcoma for decades; however, when more detailed analyzes were performed, depth proved to be a variable of confusion,

**Table 2** American Joint Committee on Cancer (AJCC) classification for bone sarcomas. Prognostic stage groups for bone sarcomas in the appendicular skeleton, trunk, skull and facial bones (there are no AJCC prognostic stage groups for spinal and pelvic tumors)

| Stage | Primary tumor (T) | Regional lymph node (N) | Distant metastasis (M) | Histological grade (G) |
|-------|-------------------|-------------------------|------------------------|------------------------|
| IA    | T1                | N0                      | M0                     | G1 or GX               |
| IB    | T2 or T3          | N0                      | M0                     | G1 or GX               |
| IIA   | T1                | N0                      | M0                     | G2 or G3               |
| IIB   | T2                | N0                      | M0                     | G2 or G3               |
| III   | T3                | N0                      | M0                     | G2 or G3               |
| IVA   | Any T             | N0                      | M1a                    | Any G                  |
| IVB   | Any T             | N1                      | Any M                  | Any G                  |
|       | Any T             | Any N                   | M1b                    | Any G                  |

Abbreviations: G1, Well-differentiated, low-grade tumor; G2, moderately differentiated, high-grade tumor; G3, poorly differentiated, high-grade tumor; GX, the grade cannot be determined; M0, without distant metastases; M1a, distant metastases (lung); M1b, distant metastases (bones or other distant sites); N0, without regional lymph node metastases; N1, regional lymph node metastases; T0, there is no evidence of a primary tumor; T1, tumor ≤ 8 cm; T2, tumor > 8 cm; T3, discontinuous tumors at the primary bone site; TX, the primary tumor cannot be accessed.

Source: Amin MB, Edge S, Greene F, Byrd DR, Brookland RK, Washington MK, et al., eds. AJCC Cancer Staging Manual. 8th ed. Switzerland: Springer; 2017.<sup>8</sup>

**Table 3** American Joint Committee on Cancer classification for soft tissue sarcomas located on the trunk and extremities. Prognostic stage groups

| Stage | Primary tumor (T) | Regional lymph node (N) | Distant metastasis (M) | Histological grade (G) |
|-------|-------------------|-------------------------|------------------------|------------------------|
| IA    | T1                | N0                      | M0                     | G1, GX                 |
| IB    | T2, T3, T4        | N0                      | M0                     | G1, GX                 |
| II    | T1                | N0                      | M0                     | G2, G3                 |
| IIIA  | T2                | N0                      | M0                     | G2, G3                 |
| IIIB  | T3, T4            | N0                      | M0                     | G2, G3                 |
| IV    | Any T             | N1                      | M0                     | Any G                  |
|       | Any T             | Any N                   | M1                     | Any G                  |

Abbreviations: G1, total differentiation, mitotic count and necrosis score 2 or 3; G2, total differentiation, mitotic count and necrosis score 4 or 5; G3, total differentiation, mitotic count and necrosis score 6, 7 or 8; GX, the grade cannot be determined; M0, without distant metastases; M1, distant metastases; N0, without regional lymph node metastases or unknown lymph node status; N1, regional lymph node metastases; T0, there is no evidence of a primary tumor; T1, tumor  $\leq 5$  cm in its largest dimension; T2, tumor  $> 5$  cm and  $\leq 10$  cm in its largest dimension; T3, tumor  $> 10$  cm and  $\leq 15$  cm in its largest dimension; T4, tumor  $> 15$  cm in its largest dimension; TX, the primary tumor cannot be accessed.

Source: Amin MB, Edge S, Greene F, Byrd DR, Brookland RK, Washington MK, et al., eds. AJCC Cancer Staging Manual. 8th ed. Switzerland: Springer; 2017.<sup>8</sup>

because size is the true independent factor associated with worst prognosis.<sup>33</sup>

The 8<sup>th</sup> MSC edition (2017)<sup>9</sup> describes four tumor sites for soft tissue sarcomas: (i) extremities and trunk; (ii) retroperitoneum; (iii) head and neck and (iv) visceral sites. All references to lesion depth were removed<sup>6</sup> due to level II evidence published by Maki et al<sup>23</sup> confirming that this variable was not an independent risk factor after multivariate analysis. Another modification was to increase the number of tumor size categories from two ( $\leq 5$  cm or  $> 5$  cm) to four ( $\leq 5$  cm,  $> 5/\leq 10$  cm,  $> 10/\leq 15$  cm,  $> 15$  cm). The decision to group T3 and T4 ( $> 10/\leq 15$  cm and  $> 15$  cm) in stage IIIB was corroborated by level II evidence from a study involving 1,091 patients that showed that tumors sized  $\leq 5$  cm,  $> 5/\leq 10$  cm and  $> 15$  cm have markedly different mortality rates; this study showed no significant difference in survival between categories  $> 5/\leq 10$  cm and  $> 10/\leq 15$ <sup>40,41</sup>; nevertheless, a size categorization in four levels was included according to data published by Maki et al,<sup>23</sup> who demonstrated significant differences in local recurrence free global survival between the four groups and a survival plateau in 10 cm tumors. This finding was supported by a recent study, in which nomograms were used to predict overall survival; for any unit change in tumor size  $> 10$  cm, there was a markedly lesser effect on survival when compared with the effect on tumor survival  $< 10$  cm.<sup>24</sup> In this same edition, N1 disease associated with trunk and extremities tumors was reclassified as stage IV, probably because their prognosis is closer to any TNOM1 metastatic disease than any TNOM0; these cases, however, remain as IIIB for tumors located at other sites<sup>41</sup> (► **Table 3**).

## Final Considerations

The domain of knowledge about the staging systems for bone and soft tissue sarcomas, as well as imaging, diagnostic methods and histological grading for classifying such tumors, is critical not only for specialists directly involved in the

treatment of affected patients, but also for orthopedic surgeons who are often responsible for their first care, which quality has the potential to interfere with the clinical outcome.

### Conflict of Interests

The authors have no conflict of interests to declare.

## References

- American Cancer Society. Cancer facts and figures 2017. Atlanta: American Cancer Society. Disponível em: <https://www.cancer.org/research/cancer-facts-statistics/all-cancer-facts-figures/-cancer-facts-figures-2017.html>. [Acessado em 24 de Julho, 2019]
- Mavrogenis AF, Angelini A, Vottis C, et al. State-of-the-art approach for bone sarcomas. *Eur J Orthop Surg Traumatol* 2015;25(01):5–15
- Cates JM. Comparison of the AJCC, MSTS, and Modified Spanier Systems for Clinical and Pathologic Staging of Osteosarcoma. *Am J Surg Pathol* 2017;41(03):405–413
- Brierley JD, Gospodarowicz MK, Wittekind CW, Eds. International Union Against Cancer: TNM Classification of Malignant Tumors. 8th ed. New Jersey, NY: Wiley-Blackwell; 2017
- Jawad MU, Scully SP. In brief: classifications in brief: enneking classification: benign and malignant tumors of the musculoskeletal system. *Clin Orthop Relat Res* 2010;468(07):2000–2002
- Enneking WF, Spanier SS, Goodman MA. A system for the surgical staging of musculoskeletal sarcoma. *Clin Orthop Relat Res* 1980; (153):106–120
- Garcia Filho RJ. Estadiamento de Enneking dos tumores músculo-esqueléticos. *Rev Bras Ortop* 1991;27(08):275–278
- Kneisl JS, Rosenberg AE, Anderson PM, Antonescu CR, Bruland OS, Cooper K. Bone. In: Amin MB, Edge S, Greene F, Byrd DR, Brookland RK, Washington MK, et al, editors. AJCC Cancer Staging Manual. 8th ed. Switzerland: Springer; 2017:469–486
- Pollock RE, Maki RG, Brookland RK, Agulnik M, Asare EA, Baldini EH. Soft Tissue Sarcoma. In: Amin MB, Edge S, Greene F, Byrd DR, Brookland RK, Washington MK, et al, eds. AJCC Cancer Staging Manual. 8th ed. Switzerland: Springer; 2017:487–545
- Cates JMM. Simple staging system for osteosarcoma performs equivalently to the AJCC and MSTS systems. *J Orthop Res* 2018;36(10):2802–2808
- Steffner RJ, Jang ES. Staging of Bone and Soft-tissue Sarcomas. *J Am Acad Orthop Surg* 2018;26(13):e269–e278

- 12 Stacy GS, Mahal RS, Peabody TD. Staging of bone tumors: a review with illustrative examples. *AJR Am J Roentgenol* 2006;186(04):967–976
- 13 Greenspan A, Jundt G, Remagen W. *Differential diagnosis in orthopaedic oncology*. 2nd ed. Philadelphia, PA: Lippincott Williams & Wilkins; 2006
- 14 Caracciolo JT, Letson GD. *Radiologic Approach to Bone and Soft Tissue Sarcomas*. *Surg Clin North Am* 2016;96(05):963–976
- 15 Peabody TD, Gibbs CP Jr, Simon MA. Evaluation and staging of musculoskeletal neoplasms. *J Bone Joint Surg Am* 1998;80(08):1204–1218
- 16 Patel DB, Matcuk GR Jr. Imaging of soft tissue sarcomas. *Linchiung Zhongliuxue Zazhi* 2018;7(04):35
- 17 Liu PT, Valadez SD, Chivers FS, Roberts CC, Beauchamp CP. Anatomically based guidelines for core needle biopsy of bone tumors: implications for limb-sparing surgery. *Radiographics* 2007;27(01):189–205, discussion 206
- 18 Anderson MW, Temple HT, Dussault RG, Kaplan PA. Compartmental anatomy: relevance to staging and biopsy of musculoskeletal tumors. *AJR Am J Roentgenol* 1999;173(06):1663–1671
- 19 Costa FM, Canella C, Gasparetto E. Advanced magnetic resonance imaging techniques in the evaluation of musculoskeletal tumors. *Radiol Clin North Am* 2011;49(06):1325–1358, vii–viii vii–viii
- 20 Sajadi KR, Heck RK, Neel MD, et al. The incidence and prognosis of osteosarcoma skip metastases. *Clin Orthop Relat Res* 2004;(426):92–96
- 21 Greene FL, Page DL, Fleming ID, et al. *AJCC Manual for Staging of Cancer*. 6th ed. Switzerland: Springer; 2002
- 22 Ferrari A, Dirksen U, Bielack S. Sarcomas of Soft Tissue and Bone. *Prog Tumor Res* 2016;43:128–141
- 23 Maki RG, Moraco N, Antonescu CR, et al. Toward better soft tissue sarcoma staging: building on american joint committee on cancer staging systems versions 6 and 7. *Ann Surg Oncol* 2013;20(11):3377–3383
- 24 Callegaro D, Miceli R, Bonvalot S, et al. Development and external validation of two nomograms to predict overall survival and occurrence of distant metastases in adults after surgical resection of localised soft-tissue sarcomas of the extremities: a retrospective analysis. *Lancet Oncol* 2016;17(05):671–680
- 25 Beahrs OH, Carr DT, Rubin P, Eds. *AJCC Manual for Staging of Cancer*. Chicago, IL: American Joint Committee; 1977
- 26 Beahrs OH, Myers MH, Eds. *AJCC Manual for Staging of Cancer*. 2nd ed. Philadelphia, PA: Lippincott; 1983
- 27 Kim MS, Lee SY, Cho WH, et al. An examination of the efficacy of the 8 cm maximal tumor diameter cutoff for the subdivision of AJCC stage II osteosarcoma patients. *J Surg Oncol* 2008;98(06):427–431
- 28 Lee J, Hoang BH, Ziogas A, Zell JA. Analysis of prognostic factors in Ewing sarcoma using a population-based cancer registry. *Cancer* 2010;116(08):1964–1973
- 29 Wuisman P, Enneking WF. Prognosis for patients who have osteosarcoma with skip metastasis. *J Bone Joint Surg Am* 1990;72(01):60–68
- 30 Ward WG, Mikaelian K, Dorey F, et al. Pulmonary metastases of stage IIB extremity osteosarcoma and subsequent pulmonary metastases. *J Clin Oncol* 1994;12(09):1849–1858
- 31 Cotterill SJ, Ahrens S, Paulussen M, et al. Prognostic factors in Ewing's tumor of bone: analysis of 975 patients from the European Intergroup Cooperative Ewing's Sarcoma Study Group. *J Clin Oncol* 2000;18(17):3108–3114
- 32 Edge SB, Byrd DR, Compton CC, Fritz AG, Greene FL, Trotti A III. *AJCC Manual for Staging of Cancer*. 7th ed. New York, NY: Springer; 2010
- 33 Bielack SS, Kempf-Bielack B, Delling G, et al. Prognostic factors in high-grade osteosarcoma of the extremities or trunk: an analysis of 1,702 patients treated on neoadjuvant cooperative osteosarcoma study group protocols. *J Clin Oncol* 2002;20(03):776–790
- 34 Beahrs OH, Henson DE, Hutter RVP, Myers MH, Eds. *AJCC Manual for Staging of Cancer*. 3rd ed. Philadelphia, PA: Lippincott; 1988
- 35 Fong Y, Coit DG, Woodruff JM, Brennan MF. Lymph node metastasis from soft tissue sarcoma in adults. Analysis of data from a prospective database of 1772 sarcoma patients. *Ann Surg* 1993;217(01):72–77
- 36 Riad S, Griffin AM, Liberman B, et al. Lymph node metastasis in soft tissue sarcoma in an extremity. *Clin Orthop Relat Res* 2004;(426):129–134
- 37 Behranwala KA, A'Hern R, Omar AM, Thomas JM. Prognosis of lymph node metastasis in soft tissue sarcoma. *Ann Surg Oncol* 2004;11(07):714–719
- 38 Mariani L, Miceli R, Kattan MW, et al. Validation and adaptation of a nomogram for predicting the survival of patients with extremity soft tissue sarcoma using a three-grade system. *Cancer* 2005;103(02):402–408
- 39 Rydholm A, Gustafson P. Should tumor depth be included in prognostication of soft tissue sarcoma? *BMC Cancer* 2003;3:17
- 40 Lahat G, Tuvin D, Wei C, et al. New perspectives for staging and prognosis in soft tissue sarcoma. *Ann Surg Oncol* 2008;15(10):2739–2748
- 41 Tanaka K, Ozaki T. New TNM classification (AJCC eighth edition) of bone and soft tissue sarcomas: JCOG Bone and Soft Tissue Tumor Study Group. *Jpn J Clin Oncol* 2019;49(02):103–107