



Original Article

Radiographic evaluation of cementation technique using polished, conical, triple-tapered femoral stem in hip arthroplasty[☆]



Ademir Antônio Schuroff, Mark Deeke, Marco Antônio Pedroni, Fernando Silva Lupselo*, Rodrigo Ernesto Kunz, Alexandre Matos Lima

Hospital Universitário Cajuru, Curitiba, PR, Brazil

ARTICLE INFO

Article history:

Received 23 November 2016

Accepted 26 January 2017

Available online 5 September 2017

Keywords:

Hip arthroplasty

Bone cement

Cementation/methods

Hip prosthesis

ABSTRACT

Objective: To radiographically evaluate the quality of cementation and implantation technique using a polished, triple-tapered femoral stem in total hip arthroplasty (THA).

Method: Retrospective study with radiographic evaluation of 86 hips in 83 patients who underwent to primary THA with the triple-tapered cemented femoral stem C-Stem (DePuy Orthopedics, Warsaw, Indiana). Cases with at least one-year of follow-up were included, and data related to preoperative, immediate postoperative, and late postoperative radiographic evolution were recorded. This study analyzed, among others, the proximal femoral anatomy, the quality of cementation as described by Barrack, and the implant positioning. Cementation was also evaluated and quantified in the Gruen zones with one-year of follow-up.

Results: The mean age was 62.85 years. Proximal femoral anatomical conformation was Dorr type A in 34 (39.53%) cases, type B in 52 (60.46%), and no type C cases were found. Five (5.81%) cases were defined as type A by Barrack's cementation classification system, 46 (56.49%) type B, 27 (31.40%) type C, and eight (9.30%) type D. The greatest cement mantle thickness was observed in zones four (15.53 mm) and 11 (15.64 mm), and the smallest in zone nine (3.51 mm). Positioning in varus was observed in eight (9.3%) cases, valgus in 25 (29%), forward deviation in two (5%), and backward deviation in 55 (63.95%).

Conclusions: The C-Stem femoral system presented satisfactory results related to cementation pattern, positioning, osteolysis, and stress shielding with regard to literature referring to double-tapered or triple-tapered models, demonstrating to be a safe method, with a predictable and reliable cementing pattern.

© 2017 Published by Elsevier Editora Ltda. on behalf of Sociedade Brasileira de Ortopedia e Traumatologia. This is an open access article under the CC BY-NC-ND license (<http://creativecommons.org/licenses/by-nc-nd/4.0/>).

[☆] Study conducted at Hospital Universitário Cajuru, Curitiba, PR, Brazil.

* Corresponding author.

E-mail: grupoquadrilhuc@hotmail.com (F.S. Lupselo).

<http://dx.doi.org/10.1016/j.rboe.2017.08.019>

2255-4971/© 2017 Published by Elsevier Editora Ltda. on behalf of Sociedade Brasileira de Ortopedia e Traumatologia. This is an open access article under the CC BY-NC-ND license (<http://creativecommons.org/licenses/by-nc-nd/4.0/>).

Avaliação radiográfica da técnica de cimentação com haste femoral cônica polida e tripla cunha em artroplastia do quadril

R E S U M O

Palavras-chave:

Artroplastia de quadril
Cimento ósseo
Cimentação/métodos
Próteses de quadril

Objetivo: Avaliar radiograficamente a qualidade da técnica de cimentação e implantação de hastas femorais polidas e tripla cunha em artroplastias totais do quadril (ATQ).

Método: Estudo retrospectivo com avaliação de radiografias de 86 quadris em 83 pacientes submetidos à ATQ com componente femoral cimentado polido em tripla cunha C-Stem (DePuy Orthopaedics, Varsóvia, Ind.). Incluímos casos com pelo menos um ano de seguimento, foram registrados dados relacionados à evolução radiográfica pré-operatória, pós-operatória imediata e pós-operatória tardia. Avaliamos, entre outros dados, a anatomia do fêmur, a qualidade da cimentação segundo descrito por Barrack e o posicionamento da haste. A cimentação também foi avaliada e quantificada em cada zona de Gruen com um ano de seguimento.

Resultados: A idade média foi de 62,85 anos. A conformação do fêmur proximal foi do tipo A de Dorr em 34 (39,53%) casos, tipo B em 52 (60,46%) e não foram observados casos do tipo C. Cinco (5,81%) casos foram definidos como tipo A segundo a classificação de cimentação de Barrack, 46 (56,49%) tipo B, 27 (31,40%) tipo C e oito (9,30%) tipo D. A maior espessura média do manto foi observada nas zonas 4 (15,53 mm) e 11 (15,64 mm), a menor foi na zona 9 (3,51 mm). Foi observado posicionamento em varo em oito (9,3%) casos e em valgo em 25 (29%).

Conclusão: A haste femoral C-Stem apresentou resultados satisfatórios quanto ao padrão de cimentação, posicionamento, à presença de osteólise e *stress shielding*, tanto em relação à literatura referente aos modelos em dupla cunha quanto referente ao mesmo modelo de implante, mostrou-se um método seguro e com padrão de cimentação previsível e confiável.

© 2017 Publicado por Elsevier Editora Ltda. em nome de Sociedade Brasileira de Ortopedia e Traumatologia. Este é um artigo Open Access sob uma licença CC BY-NC-ND (<http://creativecommons.org/licenses/by-nc-nd/4.0/>).

Introduction

John Charnley was responsible for the success in the evolution of cemented total hip arthroplasty (THA). During years of study, changes in prosthetic models have been made to decrease the incidence of failures such as loosening, wear, stem ruptures, and stress shielding. Single-plane simple-shaped femoral stems have been replaced by biconic or triconic forms, and porous stems by polished versions; these changes allow better distribution of axial load and better adaptation or accommodation within the cement mantle.¹

The concept of conical and polished rods is based on the theory that smooth surfaces with double (two-way) or triple (three-way) tapering maintain a less rigid relationship between implant and cement, allowing secondary migration and stabilization, without creating excessive stress.²

Cemented femoral components present some advantages in relation to the cementless ones, such as better transmission of loads in the proximal femur (greater similarity between the cement and the bone elasticity coefficient),^{3,4} which allows its remodeling. Bone resorption secondary to stress shielding leads to a decrease in cementless prosthesis survival,^{5,6} particularly at the calcar level.⁷ Although it occurs more commonly in cementless implants, bone resorption has also been demonstrated in cemented stems,^{8,9} with greater loss in Gruen et al. zones 1 and 7 of.¹⁰ Another advantage is the low rate of femoral fractures during surgery (around 1% in cemented and 6.6%

in non-cemented reconstructions).¹¹ Nonetheless, the rate of satisfactory results is directly proportional to the quality of the cementing technique, such as the maintenance of a mean cement mantle thickness between 2 and 4 mm, which avoids both brittleness and excessive stress.¹²

This study aimed to evaluate the quality of the cementation and implantation techniques of the C-Stem femoral stem (DePuy Orthopaedics, Warsaw, Indiana). It is a conical, polished stem with a wedge shape, made of nitrogenated stainless steel, in which the distal migration within the cement mantle is predicted, with secondary stability.¹³

Material and methods

This was a retrospective study that assessed radiographs of 86 hips in 83 patients who underwent total hip arthroplasty with the C-Stem cemented femoral component. The sample was selected by six orthopedic surgeons specializing in hip surgery during their training stage. Consecutive patients who attended outpatient follow-up visits from January 2010 to March 2015 were included, provided they had a minimum one year follow-up.

The exclusion criteria comprised patients without records of preoperative and/or postoperative radiographs, imaging with inadequate technique, previous surgery on the same hip, and cases where manual cementation techniques were used. The radiographs were evaluated in two views: anteroposterior, centered in the pubic symphysis and with the hips at

Table 1 – Surgical and radiographic data.

Operated side
Type of arthroplasty (cemented/hybrid)
Stem size
Type of cement restrictor (bone/synthetic)
Anatomy of the proximal femur
Thickness of the cement mantle
Femoral osteotomy level
Alignment of the femoral component
Cementation quality in the immediate postoperative period
Radiographic findings of cementation with at least one post-operative year

15° internal rotation, and lateral, with disclosing of the entire femoral stem.

A total of 907 THAs were performed; in 437, the C-Stem cemented femoral component was used. Of the patients, 98 were excluded due to inadequate radiographic examination, 113 due to previous surgery in the assessed hip, 130 due to inadequate outpatient follow-up, and 10 due to manual cementation. Data such as gender, age, preoperative diagnosis, and follow-up period were collected by reviewing the medical charts. The radiographic analysis was performed with the Agfa HealthCare Viewer imaging system, where data related to the surgery and the preoperative, immediate postoperative (up to two postoperative days), and late postoperative (one year of follow-up) periods were collected (Table 1).

In the preoperative radiography, the proximal femoral anatomy was evaluated using the Dorr et al. classification.¹⁴ In the immediate postoperative period, the quality of the cementation was assessed according to the method described by Barrack et al.¹⁵ After one year of follow-up, the quality of the cementation was evaluated and quantified in each zone described by Gruen et al.¹⁰ Concomitantly, the ratio between cortex, cement, and stem thickness in zones 2 and 6 on the frontal radiography were calculated, as well as the ratios in zones 9 and 13 on the lateral radiography. Aspects such as cement mantle thickness, presence of radiolucency (defined as the presence of a radiolucent line adjacent to the sclerotic line evaluated in the Gruen zones).¹⁰ Bone resorption, cement fractures and bubbles, and stem fracture or migration were also recorded. Another relevant variable measured in the study was the alignment degree of the femoral component, in order to observe the presence of varus/valgus or antecurvatum/recurvatum positioning.

Surgical technique

The posterolateral surgical approach (Kocher-Langenbeck) was used in all cases, with the patient placed in lateral decubitus position using anterior and posterior positioners. Medium-viscosity Smartset bone cement (Endurance MV, DePuy International, Blackpool, England) was introduced in a retrograde fashion with a pistol, pressurized and restricted by a synthetic or a bone plug in the canal. The femoral stems were inserted using a distal centralizer. Pulse lavage or vacuum mixing were not used.

Results

A total of 86 radiographs of primary THAs in 83 patients with C-Stem femoral component were reviewed; 31 hips (36.05%) were from male patients and 55 (63.95%), from female patients. The mean age was 62.85 (23–86) years.

Based on the classification by Dorr et al.,¹⁴ 34 (39.53%) conformations of the proximal femur were of the normal type (type A); 52 (60.46%) of the conical type (type B); no conformations were classified as the cylindrical type (Type C). According to the classification by Barrack et al.,¹⁵ five (5.81%) cases were classified as type A; 46 (56.49%), as type B; 27 (31.40%), as type C; and eight (9.30%), as type D.

The thickest cement mantle mean was observed in zones 4 and 11, 15.53 mm (0–74) and 15.64 mm (0–73), respectively, while the lowest mean was observed in zone 9, 3.51 mm (0–10; Fig. 1). A higher radiolucency index was observed in zones 2 and 10 in 52 (60.47%) cases and 50 (58.14%) cases, respectively; the lowest index was observed in zone 14, in 16 cases (18.60%; Fig. 2). Among the areas where stress shielding was observed, the incidence was higher in zones 1 and 14, with 23 hips (26.74%) and 12 hips (13.95%), respectively, and a lower incidence was found in zones 2 and 13, with only two hips

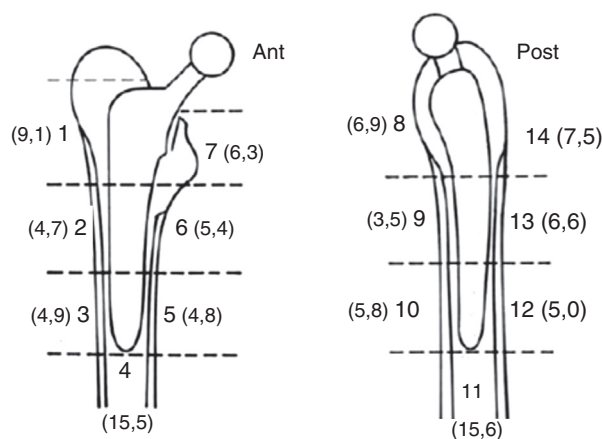


Fig. 1 – Mean thickness of the cement mantle in each Gruen zone (mm).

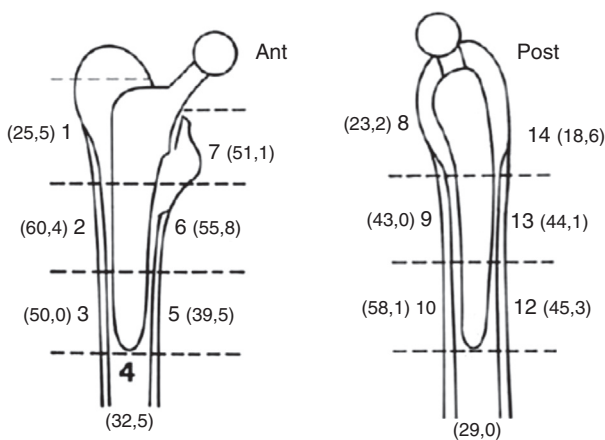


Fig. 2 – Presence of radiolucency lines in each Gruen zone (%).

Table 2 – Evaluation of cement quality in each Gruen zone.

Zones	Mean thickness (mm)	Radiolucence Bone (%)	Bone resorption (%)	Bubbles (%)
1	9.1 (0-30)	25.5	26.7	22
2	4.7 (0-10)	60.4	1.1	37.2
3	4.9 (1-13)	50	0	44.1
4	15.5 (0-74)	32.5	0	33.7
5	4.8 (2-10)	39.5	0	12.7
6	5.4 (0-12)	55.8	0	15.1
7	6.3 (0-15)	51.1	11.6	5.8
8	6.9 (0-23)	23.2	12.7	10.4
9	3.5 (0-10)	43	0	36
10	5.8 (1-10)	58.1	0	36
11	15.6 (0-73)	29	0	32.5
12	5.0 (2-10)	45.3	0	27.9
13	6.6 (2-11)	44.1	1.1	11.6
14	7.5 (1-15)	18.6	13.9	1.1

(2.32%). Moreover, signs of decreased bone density were also found in zones 7 and 8. Bubbles were observed more frequently in zone 3 (38 cases; 44.19%) and in zone 14 (one case). No case of cement and/or stem fracture was observed (Table 2).

An improvement in the assessment of cement mantle quality was made by calculating its proportion in relation to the cortical and stem thicknesses in the central zones in the anteroposterior (zones 2 and 6) and lateral (zones 9 and 13) views. The mean cortical and cement thicknesses in zone 2 were 5.88 mm and 4.73 mm, respectively; in zone 6, these values were 6.23 mm and 5.34 mm, respectively. A mean stem thickness of 13.6 mm was observed in the frontal view. In the lateral radiographs, the mean cortical and cement thicknesses in zone 9 were 4.41 mm and 3.43 mm respectively, while in zone 13 these values were 5.31 mm and 6.70 mm respectively. In the same view, the mean stem thickness was 9.93 mm. Thus, when considering the sequential measurements between cortex–cement–stem–cement–cortex thickness, the proportion of 1.2:1:2.8:1.1:1.3 was recorded from lateral to medial in the anteroposterior view; the proportion of 1.2:1:2.8:1.9:1.5 was recorded from anterior to posterior in the lateral view (Table 3).

In the assessment of stem alignment in the coronal plane, varus positioning was observed in eight (9.3%) cases, with a mean value of 3.5° (2–8°); valgus positioning was observed in 25 (29%), with a mean of 2.5° (1–8°). In the sagittal plane, ante-curvatum was observed in two (5%) cases, with a mean value of 3.5° (2–5), while recurvatum was observed in 55 (63.95%) cases, with a mean of 4.2° (1–10°). In all cases, some degree

of distal displacement of the stem (subsidence) was observed; the mean displacement was 0.8 mm (0–5 mm).

Discussion

Five decades after it was first postulated in 1962, Charnley's original concept of a conical, polished and cemented shaft still represents the gold standard.¹⁶ The problem of proximal bone loss observed from the 1960s to 1990s required changes in the stem shape.¹⁷ Double-wedge femoral stem designs, such as the Exeter (Stryker Howmedica Orthopedics, Mahwah, New Jersey) and the CPT (Zimmer Ltd., Swindon, England) present craniocaudal and anteroposterior tapering. In triple wedge implants, a third taper is added in the lateral to medial direction, aiming to increase the load on the proximal femur, especially on the calcar, which decreases bone resorption.¹⁸ Buckland et al.¹⁹ made an interesting observation, in which after an initial reduction of bone mass in the calcar region, physically active patients presented an increase in bone density in this region during the first two years. Purbach et al.¹⁶ showed a bone stock improvement in 78.2% of the patients in the medial region in a 13-year follow-up. In the present study, a decrease in proximal metaphyseal bone density in the femur was observed in zones 1 and 7 (26.74% and 11.63%, respectively). Therefore, there was greater preservation of the stock in the calcar region, a factor considered important because it is an area subjected to greater axial load (Fig. 3A).

Charnley and Kettlewell²⁰ had calculated the relative movement between the stem and the mantle when reporting the function of the implant in a closed system on acrylic cement in their monograph: "Despite the lack of adhesion between the polished surface of the prosthesis and the cement, the tapered shape of the prosthesis is very suitable for weight transmission, as it will become tighter under load (backtranslation)."²¹ When comparing femoral triple wedge and double wedge components, no differences in clinical scores, complications, or subsidence were observed.²² Sundberg et al.,²³ when assessing C-Stem stem movement patterns in 33 THAs with a two-year follow-up, observed a mean distal migration of 1.35 mm in all femoral components; most of this movement occurred in the first three months. Eugene et al.,²² in a comparative analysis with a five-year follow-up between double wedge and triple wedge stems, observed a mean subsidence of 0.82 mm and 0.77 mm respectively. In the present study, the levels of distal migration of the C-Stem were lower than those observed by Sundberg et al.²³ and higher than the study by Eugene et al.,²² with a mean distal migration of 0.8 mm. Therefore, no significant differences

Table 3 – Proportion between cortex, cement, and stem thicknesses.

Front	Cortical zone 2 (mm)	Cement zone 2 (mm)	Stem (mm)	Cement zone 6 (mm)	Cortical zone 6 (mm)
Mean	4.73	5.34	5.88	6.23	13.6
Standard deviation	1.92	1.79	1.69	1.79	1.93
Proportion	1.2	1	2.8	1.1	1.3
Profile	Cortical zone 9 (mm)	Cement zone 9 (mm)	Stem (mm)	Cement zone 13 (mm)	Cortical zone 13 (mm)
Mean	3.43	6.7	4.41	5.31	9.93
Standard deviation	1.66	1.87	1.39	1.8	2.87
Proportion	1.2	1	2.8	1.9	1.5

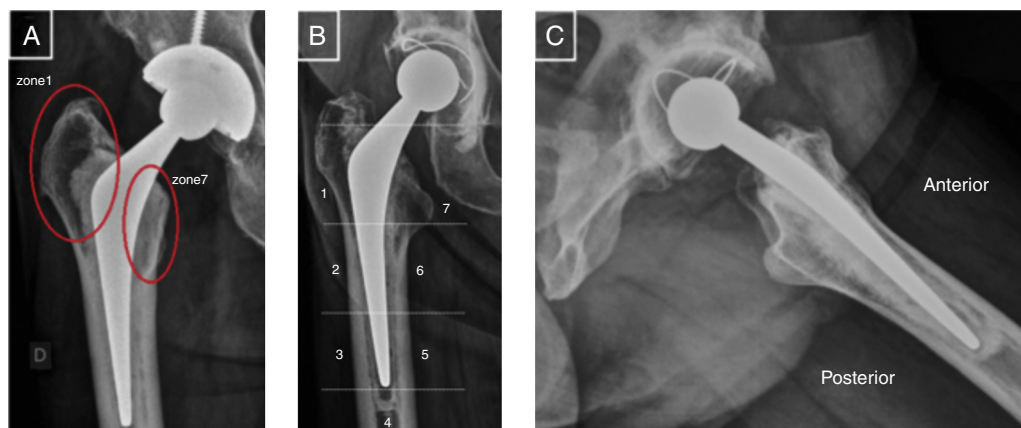


Fig. 3 – Decreased bone density in zone 1 and preservation in zone 7/calcar (A). Presence of radiolucency in zones 2, 3, 4, and 5, and presence of bubbles in zones 4, 5, and 6 (B). Lateral view radiograph disclosing the recurvatum stem positioning (C).

were observed regarding subsidence, i.e., this parameter was within the mean displacement presented in the literature. Excessive subsidence is an indirect indicator of early implant loosening, because it may be related to the movement of the cement mantle relative to the bone.²⁴

The classification of cement mantle quality in the immediate postoperative period proposed by Barrack et al.¹⁵ in 1992 is important to assess the effect of the best femoral cementation methods on the risk of increase in loosening rates or earlier failure. In the present study, this classification was used to assess radiographs immediately after surgery. Five cases (5.81%) of type A, 46 (53.49%) of type B, 27 (31.4%) of type C, and eight (9.30%) of type D were observed.

Ek and Choong²² radiographically classified 192 cement mantles on C-Stem femoral components and also observed a higher frequency of type B (46.3%), followed by type A in 45.7%, and C in 8%. In the same study, when comparing the quality of the cementation with the Exeter stem in 189 radiographs, those authors observed that type B was also the most prevalent in 56.6%, followed by type A in 36.5% and type C in 6.9%. When comparing the Berstock et al.²⁵ evaluation in 2014 with the present study, a higher prevalence of type A (60%) was observed; 38% presented type B, 2% presented type C, and 6.9% presented type D.

Sundberg et al.²³ also reported a higher frequency of type A (84.8%); type B was observed in 15.15% of their sample. An important factor to consider is that in these last two studies, the operative technique used third-generation cementation with pulse lavage, which was not performed in the present study. A higher frequency of radiolucency was observed in zones 2 (60.47%) and 10 (58.14%), followed by zones 6 (55.81%) and 7 (51.16%), while zones 1, 8, and 14 had the lowest prevalence, with 25.58%, 23.26%, and 18.60% respectively (Fig. 3B).

Comparing triple and double wedge stems, Ek and Choong²² observed divergent results; radiolucent lines were more frequently observed in zone 1 when using C-Stem components and in zones 1 and 7 when using Exeter components. Those authors emphasized the hypothesis that radiolucency may arise early due to stem subsidence and, therefore, do not necessarily indicate implant loosening. This theory may explain the presence of radiolucent lines greater than 1 mm

observed in 32 of 33 (96.9%) hips evaluated by Sundberg et al.²³ in their study, Berstock et al.²⁵ also observed a high frequency of radiolucent lines in their analysis, which corresponded to 61% of the hips evaluated; radiolucency was also more prevalent in zones 1 (55%) and 7 (35%).

In lateral view images assessment, a higher frequency of recurvatum was observed (mean of 4.2°) in 55 hips, which corresponded to 63.95% of the cases, whereas antecurvatum was observed in two hips (5%), with mean of 3.5° (Fig. 3C). In the analysis of anteroposterior radiographs, valgus positioning was more frequent (25 cases [29%], mean of 2.5°). Varus positioning was observed in eight hips (9.3%), with a mean of 3.5°. The present authors believe that these deviations can be explained by the process of progressive stem migration relative to the initial axis, as demonstrated by Sundberg et al.²³ These authors observed displacements that occurred more frequently in the mean period of three months postoperatively; in the anteroposterior radiographs, they also observed valgus misalignment in most cases, with a prevalence of 63.3%, while 15.1% of the hips presented varus positioning.

In their comparative evaluation between triple- and double-wedge stems, Ek and Choong²² observed lower indices of stem deviation. In the C-Stem components, these authors observed greater misalignment in varus, with a frequency of 3.7%, compared with 2.5% of valgus positioning. In the Exeter stems, varus positioning was recorded in 5.9% of cases, vs. no cases of valgus. It should be noted that this lower frequency of misalignments is due to the fact that those authors only considered deviations angles greater than 5°.

The proportion of cortical, cement mantle, and stem thickness was calculated to indirectly assess the quality of cementation. In the present study, in the anteroposterior view, the lateromedial ratio between cortex–cement–stem–cement–cortex was 1.2:1:2.8:1.1:1.3. Thus, a similarity was observed between lateral and medial cementation. The same ratio was 1.2:1:2.8:1.9:1.5 in the lateral view, i.e., there was a discrepancy between the anterior and posterior cementations. A probable hypothesis for this variation between the two views is the greater frequency of good alignment in varus/valgus and a greater prevalence of

recurvatum of the femoral stem. No studies calculating the ratio between cortical, cement mantle, and stem thickness were retrieved in the literature.

Conclusion

The C-Stem triple wedge cemented femoral stem presented satisfactory results regarding cementation pattern and quality, implant placement, secondary accommodation pattern, and the presence of osteolysis and stress shielding, both in relation to literature data regarding double wedge models and to data on this same implant by other authors. It was proven to be a safe, predictable, and reliable cementation method.

Conflicts of interest

The authors declare no conflicts of interest.

REFERENCES

- Shah N, Porter M. Evolution of cemented stems. *Orthopedics*. 2005;28 8 Suppl:S819-25.
- Scheerlinck T, Casteleyn PP. The design features of cemented femoral hip implants. *J Bone Joint Surg Br*. 2006;88(11):1409-18.
- Callaghan JJ, Templeton JE, Liu SS, Pedersen DR, Goetz DD, Sullivan PM, et al. Results of Charnley total hip arthroplasty at a minimum of thirty years. A concise follow-up of a previous report. *J Bone Joint Surg Am*. 2004;86(4):690-5.
- Hartofilakidis G, Karachalios T, Karachalios G. The 20-year outcome of the Charnley arthroplasty in younger and older patients. *Clin Orthop Relat Res*. 2005;(434):177-82.
- Malchau H, Herberts P, Ahnfeldt L. Prognosis of total hip-replacement in Sweden - follow-up of 92,675 operations performed 1978-1990. *Acta Orthop Scand*. 1993;64(5):497-506.
- Kobayashi S, Saito N, Horiuchi H, Iorio R, Takaoka K. Poor bone quality or hip structure as risk factors affecting survival of total-hip arthroplasty. *Lancet*. 2000;355(9214):1499-504.
- Carlsson AS, Gentz CF. Mechanical loosening of the femoral-head prosthesis in the Charnley total hip-arthroplasty. *Clin Clin Orthop Relat Res*. 1980;(147):262-70.
- Damborg F, Nissen N, Jørgensen HR, Abrahamsen B, Brixen K. Changes in bone mineral density (BMD) around the cemented Exeter stem: a prospective study in 18 women with 5 years follow-up. *Acta Orthop*. 2008;79(4):494-8.
- Kroger H, Miettinen H, Arnala I, Koski E, Rushton N, Suomalainen O. Evaluation of periprosthetic bone using dual-energy X-ray absorptiometry: precision of the method and effect of operation on bone mineral density. *J Bone Miner Res*. 1996;11:1526-30.
- Gruen TA, McNeice GM, Amstutz HC. 'Modes of failure' of cemented stem-type femoral components: a radiographic analysis of loosening. *Clin Orthop Relat Res*. 1979;(141):17-27.
- Schwartzmann CR, Telokén MA, Lompa PA, Oliveira RK, Boschin LC, Catharina GS, et al. Fratura ipsilateral do femur durante artroplastia total do quadril. *Rev Bras Ortop*. 2002;37(4):114-21.
- Ayers D, Mann K. The importance of proximal cement filling of the calcar region: a biomechanical justification. *J Arthroplasty*. 2003;18 7 Suppl 1:103-9.
- Fowler JL, Gie GA, Lee AJ, Ling RS. Experience with the Exeter total hip replacement since 1970. *Orthop Clin N Am*. 1988;19(3):477-89.
- Dorr LD, Faugere MC, Mackel AM, Gruen TA, Bognar B, Malluche HH. Structural and cellular assessment of bone quality of proximal femur. *Bone*. 1993;14(3):231-42.
- Barrack RL, Mulroy RD Jr, Harris WH. Improved cementing techniques and femoral component loosening in young patients with hip arthroplasty. A 12-year radiographic review. *J Bone Joint Surg Br*. 1992;74(3):385-9.
- Purbach B, Kay PR, Siney PD, Fleming PA, Wroblewski BM. The C-stem in clinical practice: fifteen-year follow-up of a triple tapered polished cemented stem. *J Arthroplasty*. 2013;28(8):1367-71.
- Wroblewski BM. Revision surgery in total hip arthroplasty. Berlin: Springer-Verlag London; 1990.
- Wroblewski BM, Siney PD, Fleming PA. Triple taper polished cemented stem in total hip arthroplasty: rationale for the design, surgical technique, and 7 years of clinical experience. *J Arthroplasty*. 2001;16 8 Suppl 1:37-41.
- Buckland AJ, Dowsey MM, Stoney JD, Hardidge AJ, Ng KW, Choong PF. Periprosthetic bone remodeling using a triple-taper polished cemented stem in total hip arthroplasty. *J Arthroplasty*. 2010;25(7):1083-90.
- Charnley J, Kettlewell J. The elimination of slip between prosthesis and femur. *J Bone Joint Surg Br*. 1965;47:56-60.
- Charnley J. Acrylic cement in orthopaedic surgery. Edinburgh: Livingstone; 1970.
- Ek ET, Choong PF. Comparison between triple-tapered and double-tapered cemented femoral stems in total hip arthroplasty: a prospective study comparing the C-Stem versus the Exeter Universal early results after 5 years of clinical experience. *J Arthroplasty*. 2005;20(1):94-100.
- Sundberg M, Besjakov J, von Schewelov T, Carlsson A. Movement patterns of the C-stem femoral component: an RSA study of 33 primary total hip arthroplasties followed for two years. *J Bone Joint Surg Br*. 2005;87(10):1352-6.
- Walker PS, Mai SF, Cobb AG, Bentley G, Hua J. Prediction of clinical outcome of THR from migration measurements on standard radiographs. A study of cemented Charnley and Stanmore femoral stems. *J Bone Joint Surg Br*. 1995;77(5):705-14.
- Berstock JR, Whitehouse MR, Piper DC, Eastaugh-Waring SJ, Blom AW. A 5-8 year retrospective follow-up of the C-stem AMT femoral component: patient reported outcomes and survivorship analysis. *J Arthroplasty*. 2014;29(9):1753-7.