







Application of 3D Printing Technology in the Treatment of Hoffa's Fracture Nonunion*

Aplicação da tecnologia de impressão 3D no tratamento da pseudartrose da fratura de Hoffa

Celso Júnio Aguiar Mendonça^{1,2} Sidney Carlos Gasoto² Ivan Moura Belo³
João Antônio Palma Setti³ Jamil Faissal Soni^{1,4} Bertoldo Schneider Júnior^{2,3}

¹ Musculoskeletal System Unit, Hospital de Clínicas Federal University of Paraná, Curitiba, Paraná, Brazil

² Graduate Program in Electrical and Computing Industrial Engineering, Federal Technological University of Paraná, Curitiba, Paraná, Brazil

³ Graduate Program in Biomedical Engineering, Federal Technological University of Paraná, Curitiba, Paraná, Brazil

⁴ Cajuru University Hospital, Pontifical Catholic University of Paraná, Curitiba, Paraná, Brazil

Address for correspondence Celso Júnio Aguiar Mendonça, MD, MSc, Graduate Program in Electrical and Computing Industrial Engineering, Federal Technological University of Paraná, Sete de Setembro Avenue, 3.165 Rebouças, 80230-901, Curitiba, Paraná, Brazil (e-mail: celso.mendonca@hc.ufpr.br).

Rev Bras Ortop 2023;58(2):303–312.

Abstract

Objective To evaluate a proposed three-dimensional (3D) printing process of a biomodel developed with the aid of fused deposition modeling (FDM) technology based on computed tomography (CT) scans of an individual with nonunion of a coronal femoral condyle fracture (Hoffa's fracture).

Materials and Methods Thus, we used CT scans, which enable the evaluation of the 3D volumetric reconstruction of the anatomical model, as well as of the architecture and bone geometry of sites with complex anatomy, such as the joints. In addition, it enables the development of the virtual surgical planning (VSP) in a computer-aided design (CAD) software. This technology makes it possible to print full-scale anatomical models that can be used in surgical simulations for training and in the choice of the best placement of the implant according to the VSP. In the radiographic evaluation of the osteosynthesis of the Hoffa's fracture nonunion, we assessed the position of the implant in the 3D-printed anatomical model and in the patient's knee.

Results The 3D-printed anatomical model showed geometric and morphological characteristics similar to those of the actual bone. The position of the implants in relation to the nonunion line and anatomical landmarks showed great accuracy in the comparison of the patient's knee with the 3D-printed anatomical model.

Keywords

- ▶ Hoffa's fracture
- ▶ pseudarthrosis
- ▶ printing, three-dimensional
- ▶ orthopedic surgery

* Work developed at the Federal Technological University of Paraná, Curitiba, Paraná, Brazil.

received
March 1, 2022
accepted
April 28, 2022
article published online
October 3, 2022

DOI <https://doi.org/10.1055/s-0042-1750759>.
ISSN 0102-3616.

© 2022. Sociedade Brasileira de Ortopedia e Traumatologia. All rights reserved.
This is an open access article published by Thieme under the terms of the Creative Commons Attribution-NonDerivative-NonCommercial-License, permitting copying and reproduction so long as the original work is given appropriate credit. Contents may not be used for commercial purposes, or adapted, remixed, transformed or built upon. (<https://creativecommons.org/licenses/by-nc-nd/4.0/>)
Thieme Revinter Publicações Ltda., Rua do Matoso 170, Rio de Janeiro, RJ, CEP 20270-135, Brazil

Resumo

Palavras-chave

- ▶ fratura de Hoffa
- ▶ pseudoartrose
- ▶ impressão tridimensional
- ▶ procedimentos ortopédicos

Conclusion The use of the virtual anatomical model and the 3D-printed anatomical model with the additive manufacturing (AM) technology proved to be effective and useful in planning and performing the surgical treatment of Hoffa's fracture nonunion. Thus, it showed great accuracy in the reproducibility of the virtual surgical planning and the 3D-printed anatomical model.

Objetivo Avaliar uma proposta de processo de impressão tridimensional (3D) de um biomodelo preparado com o auxílio da tecnologia de modelagem por deposição de material fundido (*fused deposition modeling*, FDM, em inglês) a partir de imagens de tomografia computadorizada (TC) de um indivíduo com pseudartrose de fratura coronal do côndilo femoral (fratura de Hoffa).

Materiais e Métodos Para tanto, utilizamos imagens de TC, que permitem estudar a reconstrução volumétrica 3D do modelo anatômico, além da arquitetura e geometria óssea de sítios de anatomia complexa, como as articulações. Também permite o planejamento cirúrgico virtual (PCV) em um programa de desenho assistido por computador (*computer-aided design*, CAD, em inglês). Essa tecnologia possibilita a impressão de modelos anatômicos em escala real que podem ser utilizados em simulações cirúrgicas para o treinamento e a escolha do melhor posicionamento do implante de acordo com o PCV. Na avaliação radiográfica da osteossíntese da pseudartrose de Hoffa, verificou-se a posição do implante no modelo anatômico impresso em 3D e no joelho do paciente.

Resultados O modelo anatômico impresso em 3D apresentou características geométricas e morfológicas semelhantes às do osso real. O posicionamento dos implantes em relação à linha de pseudartrose e pontos anatômicos foram bastante precisos na comparação do joelho do paciente com o modelo anatômico impresso em 3D.

Conclusão A utilização do modelo anatômico virtual e do modelo anatômico impresso em 3D com a tecnologia de manufatura aditiva (MA) foi eficaz e auxiliou o planejamento e a realização do tratamento cirúrgico da pseudartrose da fratura de Hoffa. Desta forma, foi bastante preciso na reprodutibilidade do planejamento cirúrgico tanto virtual quanto no modelo anatômico impresso em 3D.

Introduction

In several fields of medicine, such as orthopedics, anatomical models and personalized implants are manufactured for an accurate preoperative planning, the simulation of surgeries, the training of staff, and better communication with the patient.¹⁻⁴

Three-dimensional (3D) printing, also called rapid prototyping (RP) or additive manufacturing (AM), enables the printing of models reproducing the actual anatomy. These can improve the surgeon's anatomical understanding and interpretation. This technology enables the use of personalized guides to optimize the surgical outcomes. Implants and arthroplasties can be developed according to an individual's anatomy and can also help in the anatomical assessment of the surgical treatment.^{5,6}

Virtual 3D planning enables the surgeon to visualize and understand the complex anatomy and to digitally plan a corrective osteotomy to restore the anatomy and normal function or the best implant placement, for example.

The objective of the present study is to evaluate a proposed 3D printing process of a biomodel developed with the aid of fused deposition modeling (FDM) based on the computed tomography (CT) scans of an individual with nonunion of the coronal femoral condyle fracture (Hoffa fracture).

Materials and Methods

To demonstrate the use of the AM technology in orthopedic surgery, we chose a clinical case of an individual with a Hoffa fracture nonunion. We performed the study of bone geometry, virtual preoperative planning, and preoperative planning with the printing of a 3D anatomical model in full scale (1:1) of the distal region of the femur. In this model, the fixation of the nonunion was simulated with osteosynthesis by plate and screws. After the surgical treatment, the implant position was analyzed (in the anatomical model and in the patient) through the measurement of the angles of the implants in relation to bone structure landmarks. These measurements enabled us to analyze the reproducibility of

the surgical planning and simulation. The present study was performed after approval by the institutional Ethics Committee (CAAE: 94788418.2.0000.5547).

The patient is a 44-year-old male who, in november 2010, suffered a motorcycle accident that resulted in severe poly-trauma with an open segmental fracture of the left femur (fracture of the proximal and distal regions). He presented sequelae of the trauma to the left lower limb with nonunion and angular deformity.

After six years of the accident, he started presenting with progressive pain. The X-ray and CT scans were performed, and a neglected Hoffa's fracture nonunion was diagnosed (Letteneur type III) (►Fig. 1).⁷

For the acquisition of bone images to print the anatomical model, we used the GE lightspeed VCT (GE Healthcare, Chicago, IL, United States) CT scanner, manufactured in 2008, with 64 channels. The scans were performed following a specific image acquisition protocol for bone tissue established by the local radiology team, as shown in ►Table 1.

To create the virtual anatomical model to be used, segmentation was performed (the separation of bone tissue from the CT scans) using the Invesalius (Centro de Tecnologia da Informação [CTI] Renato Acher, Campinas, SP, Brazil) software, version 3.1.1, as shown in ►Fig. 2. The bone segmentation was performed by an automatic algorithm of the software that identified bone tissue in the radiodensity threshold window between 226 and 2014 Hounsfield units (HU). The program created a mask to identify the segmented tissue, which, in this case, was green, as shown in ►Fig. 2. The software enabled the visualization of the reconstructed object in various positions in space, helping to better understand the bone geometry. Volumetric reconstruction of the object was performed, and a file was created in the standard triangle language (STL) format, which can be exported to a computer-aided design (CAD) environment for subsequent virtual modeling of the object or even its 3D printing.

The object was modeled and rendered through the Meshmixer (Autodesk, San Rafael, CA, United States) software, version 3.5, with the levelling of the internal and external surface of the bone (►Fig. 3).

The use of a software with CAD technology enables the development of the virtual surgical planning (VSP) and the

reduction of fragments (►Fig. 4). The non-consolidated fragments were separated virtually to better study the lesion, followed by their reduction in the anatomical position, and the positioning of the implants in the desired location. The entire virtual surgery process was performed in a CAD environment using the Meshmixer software (►Fig. 4).

After the creation of the object in STL format, the file was exported to a G-code generator; G-code is a language used by computer-aided manufacturing (CAM) software to manufacture 3D objects. The main function of the G-code is to instruct the machine to move geometrically in the three dimensions: X, Y, and Z. It is an extremely simple and rudimentary language, consisting of a sequence of lines of instructions in which each line is responsible for a specific task, and the software is run line by line until the end of the code. The G-code of the object was generated using the Slic3r (developed by Alessandro Ranellucci) free software, version 1.3.0.

After the generation of the G-code, the information was exported to a CAM environment. The Repetier-Host (Hot-World GmbH & Co. KG, Willich, Germany) free software, version 2.0.5, was used to set the printing features, such as the type of thermoplastic, polymer density, filament diameter, extrusion temperature, printing speed, height (width) of the layer, resolution, filling of the structure, and support of the parts.

The manufacturing of the printed model reproduced the internal and external profiles of the cortical layer of the bone, which is completely filled with polymer, representing the actual geometry of the bone (►Fig. 5).

The surgical simulation was performed according to recent studies^{7,8} that demonstrate that plate and screws generate more biomechanical stability in the treatment of coronal fracture of the femoral condyle. A 5-hole locking compression plate (LCP) with four 3.5 mm locked screws, a 4.0 mm cancellous screw, a 3.5 mm cortical screw were used.

Fixation of the nonunion of the 3D anatomical model was performed according to the principles of fixation of joint fractures developed by the Arbeitsgemeinschaft für Osteosynthesefragen (AO) Foundation (►Fig. 6).⁹

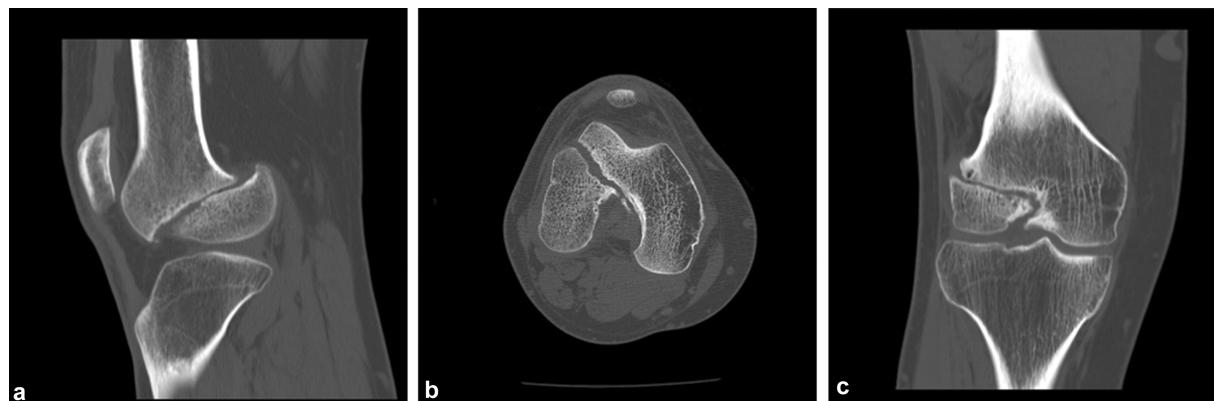


Fig. 1 Sagittal, axial, and coronal CT scans.

Table 1 Parameters used for the acquisition of computed tomography scans

Parameters	Description
Field of view	17 × 17 cm
Scout	Standard protocol of the scanner
Region of interest	Knee
Voltage (KV)	120
Amperage (mA)	298
Pitch	512 × 512
Colimation	Large body
Slice thickness	0,6 mm
Slice increment	0,969 mm

The plate was bent following the geometry of the lateral femoral condyle so that it would be at 90° in relation to the nonunion line. The proper positioning of the implants and the reduction of bone fragments were assessed through perioperative fluoroscopy (→ **Fig. 7**).

After fixating the 3D anatomical model with the implants, stability of the fragment and/or the plate and screws were assessed through manual displacement tests reproducing the flexion and torsion forces.

The anatomical model was sterilized in ethylene oxide to be used during the surgical procedure as a navigation guide (→ **Fig. 8**).

Results

The 3D-printed anatomical model showed geometric and morphological characteristics similar to those of the actual bone. The material used to print the model, the thermoplastic polymer acrylonitrile butadiene styrene (ABS), provided the model with structural strength that enabled the surgical simulation with the placement of the implants, without causing breakage or loosening of the layers of the model. After inserting the implants, the stability of the reduction and fixation of the fragments were assessed.

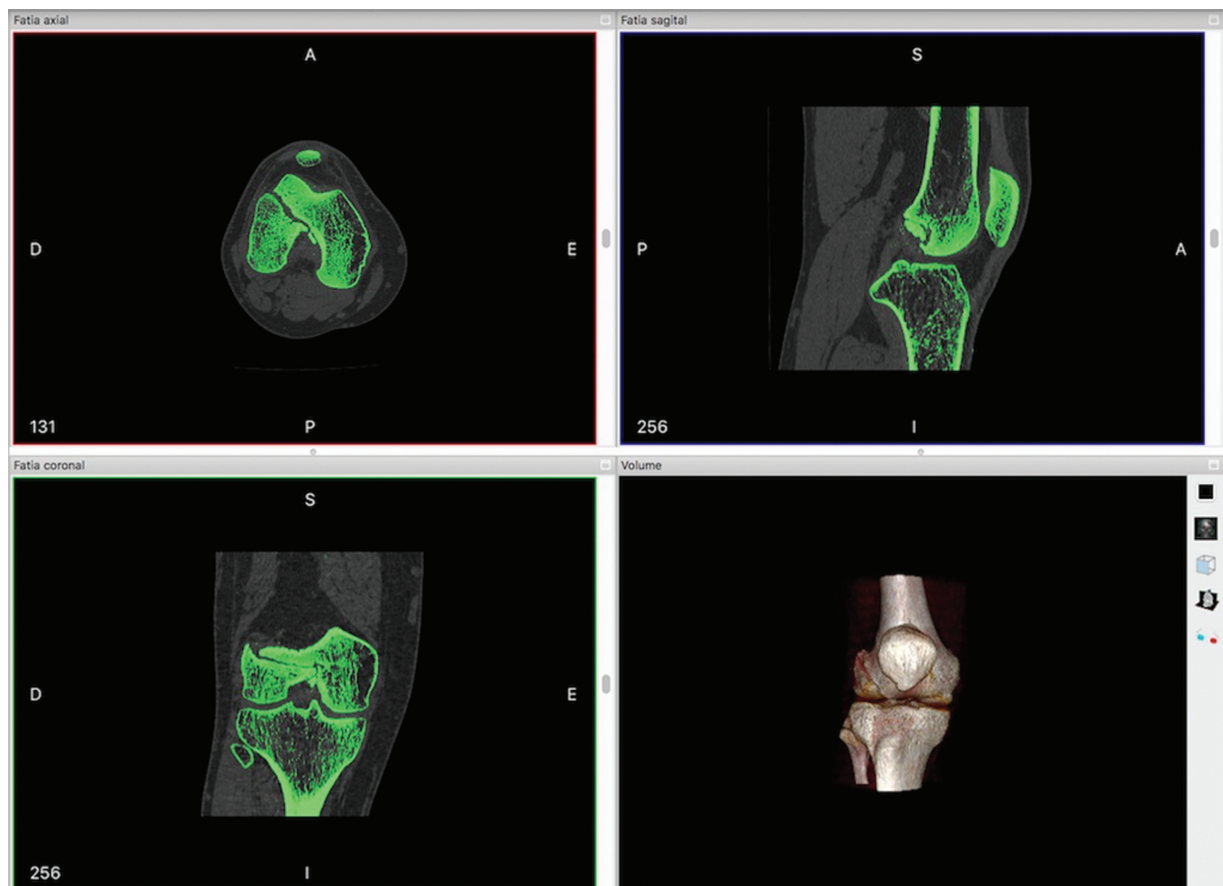


Fig. 2 Screen image of the Invesalius software showing the bone segmentation. Note: The figure shows the images of the axial, sagittal, coronal sections, as well as the image of the reconstructed volume of the segmented bone tissue.

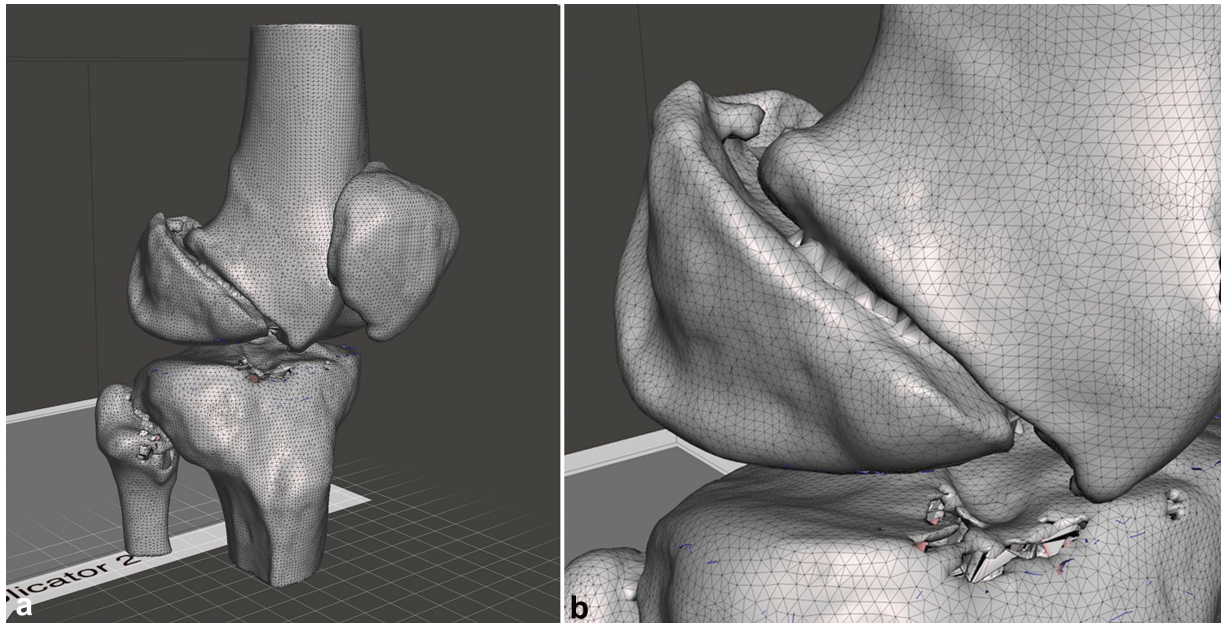


Fig. 3 Virtual bone model before rendering with the Meshmixer software. Note: A mesh was developed to better understand the irregularities and flaws on the surface of the object to facilitate their subsequent correction.

Using the described method, we were able to print a 3D anatomical model with the characteristics of the actual object, which enabled the development of the VSP, a surgical simulation to plan the best position of the implants and train the surgery team.

The assessment of the reproducibility of the technique, that is, determining if the osteosynthesis performed on the patient's distal femur followed the virtual planning and the simulation using the 3D-printed anatomical model, was based on the measurements of the angles in comparison to the anatomical landmarks of the distal femur, the non-union line, and the position of the implant. Angle measure-

ment was performed using the AnimatiPACS (Animati netPACS, Santa Maria, RS, Brazil) software.

To measure the position of the implant, the anatomical landmarks were defined on anteroposterior (AP) and Lateral view (L) radiographs, with the tangential tracing of the lines in the anatomical landmarks to form angles with the implants or the nonunion line. On the AP view, a line was defined as a tangential landmark to the distal end of the femoral condyles. On the Lateral view, a line was defined as a tangential landmark to the posterior cortex of the distal femoral metaphysis. (—Fig. 9).

The radiographs (on AP and Lateral views) of the patient's knee and the 3D-printed anatomical model show that the

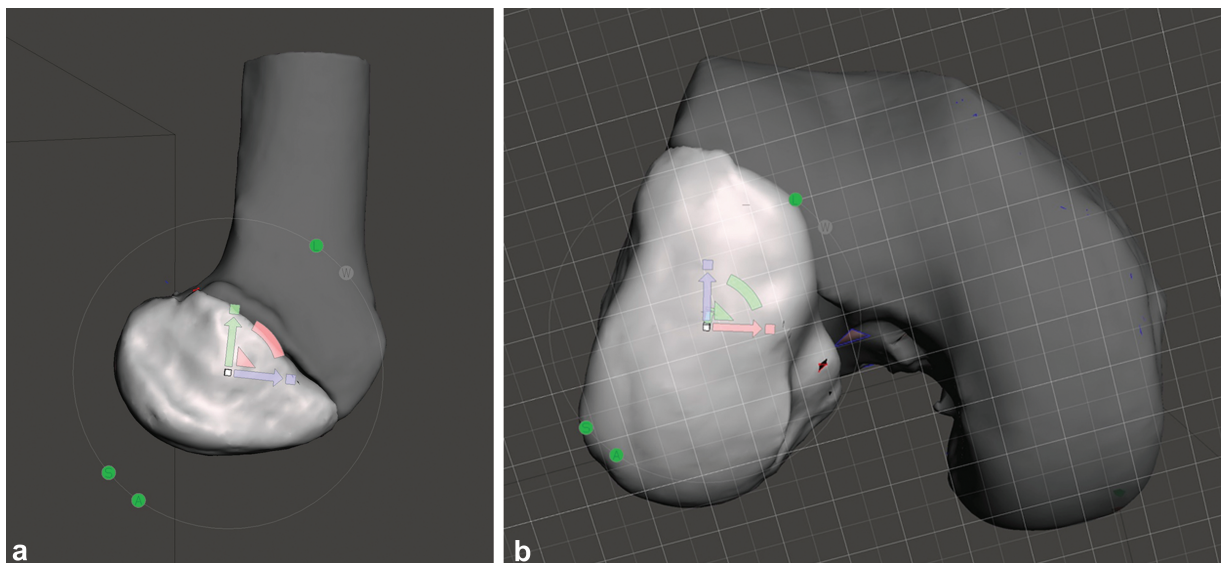


Fig. 4 Images of the reduction of the nonunion fragments.




Fig. 5 Images of the 3D-printed bone model with the FDM technology in white ABS, showing the distal femur and fragment of the lateral femoral condyle.

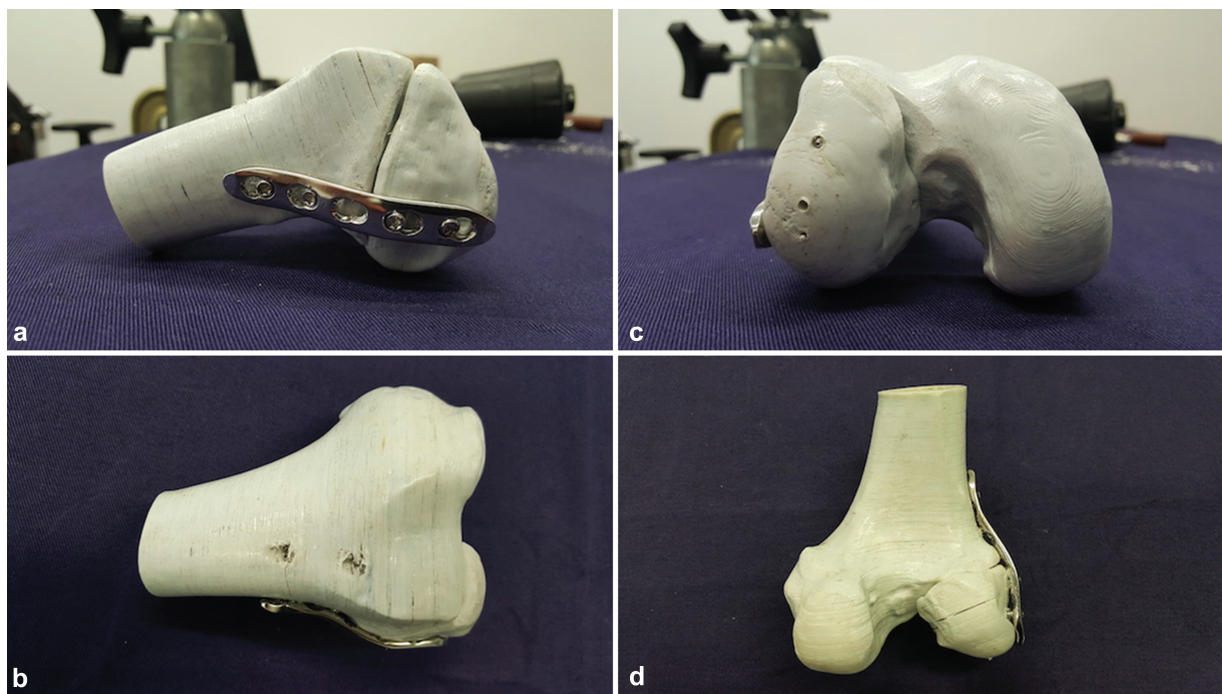


Fig. 6 Images of the 3D printed bone fixated with the LCP plate on the lateral portion of the distal femur.

position of the plate and screws in relation to the defined anatomical landmarks (articular surface of the femoral condyles and the posterior cortical layer of the distal metaphysis of the femur) are different (► **Table 2**).

The patient's knee radiographs on Lateral view and the printed anatomical model show a proximity of the values of the angles between the plate and screws in relation to the nonunion line (► **Table 3**). The differences in percentage

regarding the positioning of the implants in the patient's knee in relation to the anatomical model were of 3.5% on the plate, 18% on the proximal screw, and 4% on the distal screw.

Discussion

Before the advent of computer systems to visualize digitized images, such as the picture archiving and communication

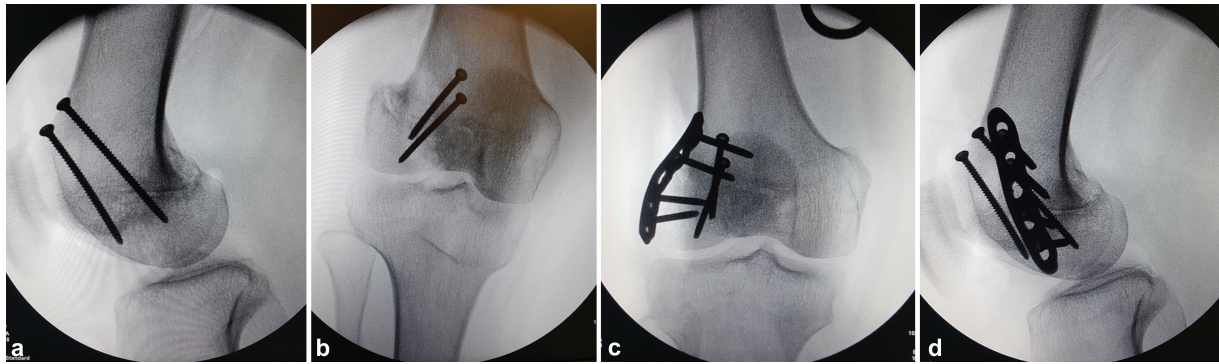


Fig. 7 Perioperative fluoroscopy images to assess the positioning of the implants.

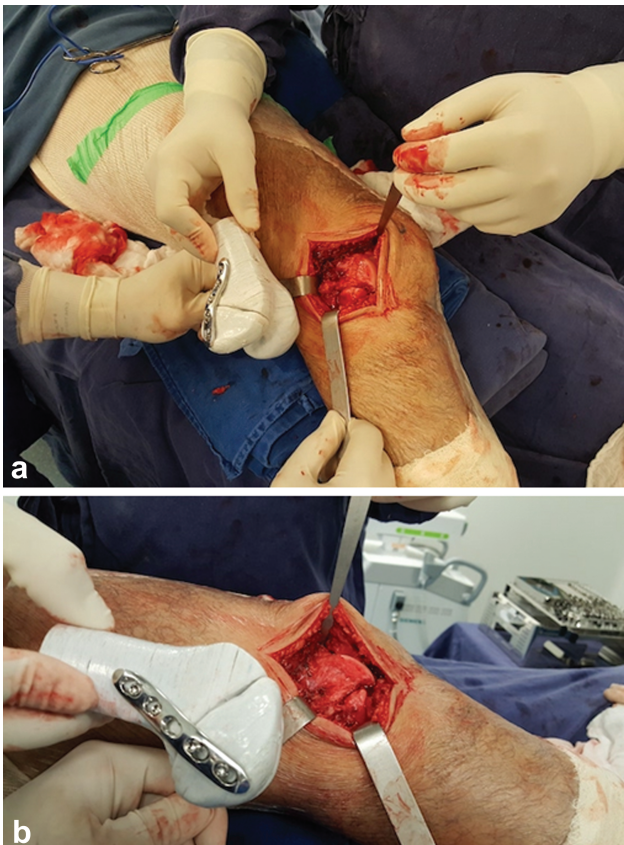

Fig. 8 Use of the 3D-printed anatomical model as a navigation guide for the anatomical landmarks to place the implant according to the virtual planning.

system (PACS), CT and magnetic resonance imaging (MRI) scans were printed on film, with the loss of valuable information in the process. The PACS changed the way of analyzing the images, providing another dimension to their interpretation, since it enables the dynamica visualization of the 3D object from various angles. The volumetric reconstruction of the studied structure can be exported to CAD software for modeling and rendering, which make it possible to print the object.¹⁰

According to several authors,^{6,11-14} currently, the 3D printing process in the medical field (used for teaching, planning, and surgical training, and the development of

surgical guides, implants, and prostheses) consists of the steps showed in **Fig. 10**.

Kim et al.¹⁵ reported their clinical experience with the use of 3D printing techniques in orthopedic trauma, which enables a better understanding of the fracture and its anatomical relationships, and may be applied in the preoperative planning, in medical education, and in surgical training and simulation.

In the present study, the process used for the acquisition of CT scans and rendering and modeling in a CAD environment to create a virtual bone model for 3D printing through FDM technology was successful. According to the literature, the parameters in the acquisition of CT scans, such as the width and number of slices, are determining factors for the accuracy of the volumetric reconstruction. The width of the slices was smaller than 1 mm, which generated enough data for a volumetric reconstruction that was very close to that of the actual bone. Segmentation was performed automatically by a computer algorithm with the identification of bone tissue in the threshold window between 226 HU and 2014 HU, which enabled an accurate segmentation, with little need for the removal of artifacts and smoothing the surface during rendering and modeling.

The use of CAD software, such as Invesalius (used for bone segmentation) and Meshmixer (used for modeling and rendering), enabled us to perform the anatomical reduction of bone fragments during the VSP.

The use of 3D printing technology has been growing exponentially in several fields, including orthopedic surgery, and it is relevant in creation of biomodels, surgical tools (such as guides and templates), implants and prostheses.

The anatomical model may also facilitate the communication among the medical team and the patient and their family, providing information about the type of surgical treatment, promoting a better understanding of the clinical picture and of the possible complications, as well as better adherence to the treatment, which contributes to improve the doctor-patient relationship.^{4,16-19} The participant in the present study was instructed on the severity and prognosis of the joint injury. For this purpose, we used the printed anatomical model submitted to the surgical simulation, with the nonunion fixed with the implants chosen.

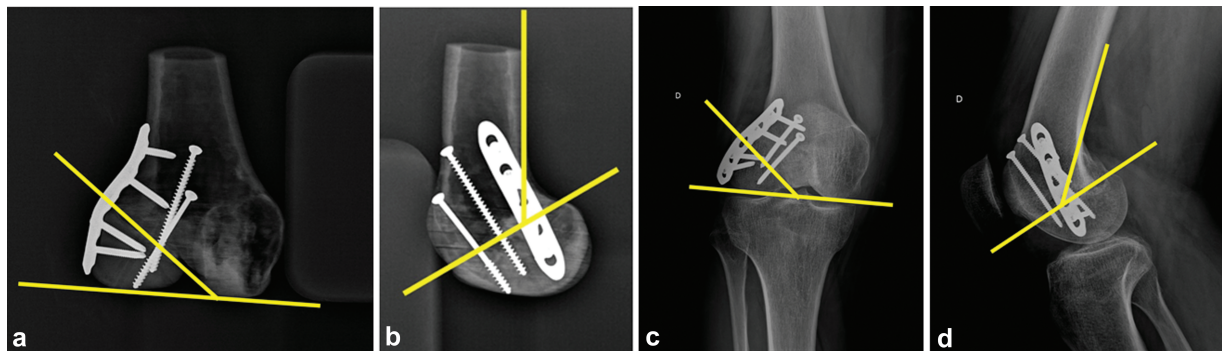


Fig. 9 Anatomical references on the AP and Lateral view radiographs with the tangential tracing of lines on the landmarks and the formation of angles to measure the position of the implants.

Table 2 Measurements of the positioning angles of the nonunion line, the plate, and screws in relation to the anatomical landmarks of the distal femur

	X-ray view	Knee	Anatomical model
Nonunion line	Anteroposterior	41.2°	38,1°
	Lateral	43.8°	61,5°
Plate	Anteroposterior	49,6°	71,8°
	Lateral	36,9°	26,0°
Proximal screw	Anteroposterior	57,2°	74,6°
	Lateral	57,0°	32,1°
Distal screw	Anteroposterior	52,5°	62,8°
	Lateral	50,9°	37,3°

Table 3 Measurements of the positioning angles of the plate and screws in relation to the nonunion line

	X-ray view	Nonunion line	
		Knee	Anatomical model
Plate	Lateral	93.0°	89.8°
Proximal screw	Lateral	70.2°	85.7°
Distal screw	Lateral	76.1°	79.4°

Studies^{4,12,17,20} show the use of anatomical models with AM technology in surgical training. A wide variety of domains including simulation accuracy, anatomical similarity, training in the use of surgical instruments, use printed models for training surgeons. Several studies have demonstrated the effective application of 3D printing in medical education in orthopedics,^{4,11,20-26} mainly in surgical procedures in sites of complex anatomy.⁶

There are several CAD software that enable the performance of the VSP to better understand the spatial geometry and anatomical relations. It is possible to program less invasive surgical approaches and anticipate the reduction of bone fragments, simulating the definitive osteosynthesis.^{27,28} The printing of biomodels provides additional information when compared to conventional imaging scans and increases the knowledge about the lesion.^{5,11,22,29}

Some meta-analyses and systematic reviews^{3,30} on preoperative planning and 3D printing-assisted surgery in orthopedic trauma suggest that this method reduces the surgical time, the levels of intraoperative blood loss, and the fluoroscopy time.

In the present study, the printing of the 3D anatomical model with the FDM technology enabled us to develop a careful VSP, to plan the position of the implants, and train the surgical team. Moreover, the anatomical model fixated with the implants was used as a navigation guide during surgery. There was some technical difficulty in positioning the anatomical model so it would correspond to the precise position of the patient's knee on the AP radiograph. Due to the lack of other anatomical structures adhered or attached to it, the model did not have geometric and anatomical landmarks that would enable the precise reproduction of specific X-ray

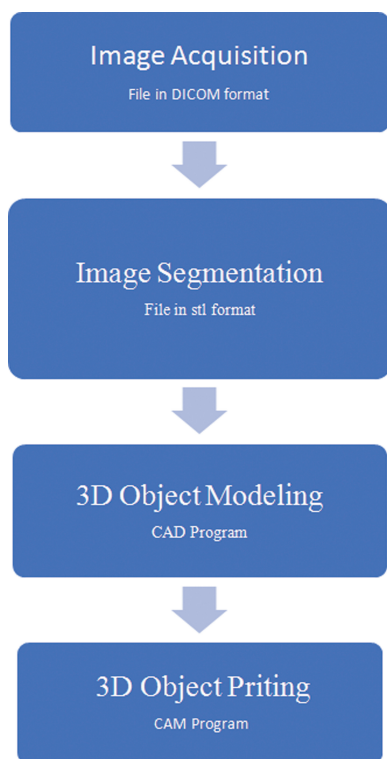


Fig. 10 3D printing process in medicine.

technique for the knee. Thus, the angles reveal that the patient's knee and the anatomical model were not in the same position at the time the X-ray was performed, as shown in ►Table 2.

In order to achieve a stable osteosynthesis, the screws and the plate must be at an angle close to 90° in relation to the nonunion line, according to the AO techniques,⁹ which was achieved in the present study, as shown in ►Table 3.

Despite the difference in the angles of the radiograph of the patient's knee and those of the anatomical model, the positioning of the implants was adequate, and we were able to reproduce the technique of placing the plate and screws as in the simulation in the anatomical model. This resulted on great fixation stability, and enabled a satisfactory reduction and the anatomical reconstruction of the joint.

According to the radiographic analysis, great accuracy was verified in the reproducibility of the VSP and in the surgical simulation compared with the outcome of the osteosynthesis of the Hoffa's fracture nonunion.

Conclusion

The protocol suggested for the acquisition and segmentation of the CT scans of the knee of a patient with Hoffa's fracture nonunion proved to be effective for the volumetric reconstruction and rendering of the 3D anatomical model. The model enabled the performance of a careful VSP, as well as the simulation of the osteosynthesis. According to the radiographic analysis, great accuracy was observed in the reproducibility of the surgical simulation. The use of the 3D-printed model proved to be effective and useful in the

planning and surgical treatment of Hoffa's fracture nonunion.

Financial Support

The authors declare they have received no financial support from public, commercial, or non-profit sources.

Conflict of Interests

The authors have no conflict of interests to declare.

References

- Zheng W, Su J, Cai L, et al. Application of 3D-printing technology in the treatment of humeral intercondylar fractures. *Orthop Traumatol Surg Res* 2018;104(01):83–88
- Rankin TM, Wormer BA, Miller JD, Giovinco NA, Al Kassis S, Armstrong DG. Image once, print thrice? Three-dimensional printing of replacement parts. *Br J Radiol* 2018;91(1083):20170374
- Morgan C, Khatri C, Hanna SA, Ashrafian H, Sarraf KM. Use of three-dimensional printing in preoperative planning in orthopaedic trauma surgery: A systematic review and meta-analysis. *World J Orthop* 2020;11(01):57–67
- Samaila EM, Negri S, Zardini A, et al. Value of three-dimensional printing of fractures in orthopaedic trauma surgery. *J Int Med Res* 2020;48(01):300060519887299
- Vaishya R, Patralekh MK, Vaish A, Agarwal AK, Vijay V. Publication trends and knowledge mapping in 3D printing in orthopaedics. *J Clin Orthop Trauma* 2018;9(03):194–201
- Mishra A, Verma T, Vaish A, Vaish R, Vaishya R, Maini L. Virtual preoperative planning and 3D printing are valuable for the management of complex orthopaedic trauma. *Chin J Traumatol* 2019;22(06):350–355
- Pires RE, Giordano V, Fogagnolo F, Yoon RS, Liporace FA, Kfuri M. Algorithmic treatment of Busch-Hoffa distal femur fractures: A technical note based on a modified Letenneur classification. *Injury* 2018;49(08):1623–1629
- Sun H, He QF, Huang YG, Pan JF, Luo CF, Chai YM. Plate fixation for Letenneur type I Hoffa fracture: a biomechanical study. *Injury* 2017;48(07):1492–1498
- Buckley RE, Moran CG, Apivatthakakul T, Eds. *AO Principles of Fracture Management*. Stuttgart: Thieme; 2018
- Bagaria V, Chaudhary K. A paradigm shift in surgical planning and simulation using 3Dgraphy: Experience of first 50 surgeries done using 3D-printed biomodels. *Injury* 2017;48(11):2501–2508
- Marro A, Bandukwala T, Mak W. Three-Dimensional Printing and Medical Imaging: A Review of the Methods and Applications. *Curr Probl Diagn Radiol* 2016;45(01):2–9
- Hoang D, Perrault D, Stevanovic M, Ghiassi A. Surgical applications of three-dimensional printing: a review of the current literature & how to get started. *Ann Transl Med* 2016;4(23):456–475
- van Eijnatten M, van Dijk R, Dobbe J, Streekstra G, Koivisto J, Wolff J. CT image segmentation methods for bone used in medical additive manufacturing. *Med Eng Phys* 2018;51:6–16
- Aimar A, Palermo A, Innocenti B. The Role of 3D Printing in Medical Applications: A State of the Art. *J Healthc Eng* 2019;2019:5340616
- Kim JW, Lee Y, Seo J, et al. Clinical experience with three-dimensional printing techniques in orthopedic trauma. *J Orthop Sci* 2018;23(02):383–388
- Bizzotto N, Tami I, Tami A, et al. 3D Printed models of distal radius fractures. *Injury* 2016;47(04):976–978
- Tack P, Victor J, Gemmel P, Annemans L. 3D-printing techniques in a medical setting: a systematic literature review. *Biomed Eng Online* 2016;15(01):115

- 18 Wilcox B, Mobbs RJ, Wu AM, Phan K. Systematic review of 3D printing in spinal surgery: the current state of play. *J Spine Surg* 2017;3(03):433–443
- 19 Zheng W, Chen C, Zhang C, Tao Z, Cai L. The Feasibility of 3D Printing Technology on the Treatment of Pilon Fracture and Its Effect on Doctor-Patient Communication. *BioMed Res Int* 2018; 2018:8054698
- 20 Langridge B, Momin S, Coumbe B, Woin E, Griffin M, Butler P. Systematic Review of the Use of 3-Dimensional Printing in Surgical Teaching and Assessment. *J Surg Educ* 2018;75(01): 209–221
- 21 Montgomery SJ, Kooner SS, Ludwig TE, Schneider PS. Impact of 3D Printed Calcaneal Models on Fracture Understanding and Confidence in Orthopedic Surgery Residents. *J Surg Educ* 2020;77(02): 472–478
- 22 Bagaria V, Deshpande S, Rasalkar DD, Kuthe A, Paunipagar BK. Use of rapid prototyping and three-dimensional reconstruction modeling in the management of complex fractures. *Eur J Radiol* 2011;80(03):814–820
- 23 Shui W, Zhou M, Chen S, et al. The production of digital and printed resources from multiple modalities using visualization and three-dimensional printing techniques. *Int J CARS* 2017;12(01):13–23
- 24 Mulford JS, Babazadeh S, Mackay N. Three-dimensional printing in orthopaedic surgery: review of current and future applications. *ANZ J Surg* 2016;86(09):648–653
- 25 Malik HH, Darwood ARJ, Shaunak S, et al. Three-dimensional printing in surgery: a review of current surgical applications. *J Surg Res* 2015;199(02):512–522
- 26 Cromeens BP, Ray WC, Hoehne B, Abayneh F, Adler B, Besner GE. Facilitating surgeon understanding of complex anatomy using a three-dimensional printed model. *J Surg Res* 2017;216:18–25
- 27 Fadero PE, Shah M. Three dimensional (3D) modelling and surgical planning in trauma and orthopaedics. *Surgeon* 2014;12(06): 328–333
- 28 Egger J, Wallner J, Gall M, et al. Computer-aided position planning of miniplates to treat facial bone defects. *PLoS One* 2017;12(08): e0182839
- 29 Zhang Y, Wen L, Zhang J, Yan G, Zhou Y, Huang B. Three-dimensional printing and computer navigation assisted hemipelvectomy for en bloc resection of osteochondroma: A case report. *Medicine (Baltimore)* 2017;96(12):e6414
- 30 Xiong L, Li X, Li H, Chen Z, Xiao T. The efficacy of 3D printing-assisted surgery for traumatic fracture: a meta-analysis. *Postgrad Med J* 2019;95(1126):414–419