



# Aspirin versus Rivaroxaban to Prevent Venous Thromboembolism after Total Knee Arthroplasty: A Double-blinded, Randomized Controlled Trial\*

## *Aspirina versus rivaroxabana na prevenção do tromboembolismo venoso após artroplastia total do joelho: Um ensaio clínico randomizado, controlado e duplo-cego*

Theerawit Hongnaparak<sup>1</sup> Jiranuwat Janejaturanon<sup>1</sup> Khanin lamthanaporn<sup>1</sup> Pramot Tanutit<sup>2</sup>  
Varah Yuenyongviwat<sup>1</sup>

<sup>1</sup> Department of Orthopedics, Faculty of Medicine, Prince of Songkla University, Songkhla, Thailand

<sup>2</sup> Department of Radiology, Faculty of Medicine, Prince of Songkla University, Songkhla, Thailand

Address for correspondence Varah Yuenyongviwat, MD, Department of Orthopedics, Faculty of Medicine, Prince of Songkla University, Hat Yai, Songkhla 90110, Thailand (e-mail: varahortho@gmail.com).

Rev Bras Ortop 2022;57(5):741–746.

### Abstract

**Objective** Aspirin (acetylsalicylic acid, ASA) and rivaroxaban are anticoagulants that have increased in popularity due to ease of use in the prevention of venous thromboembolism (VTE) after total knee arthroplasty (TKA). The present study aimed to evaluate the efficacy of ASA compared with that of rivaroxaban on VTE prophylaxis in patients who underwent TKA.

**Method** Forty patients who had primary knee osteoarthritis and would undergo TKA were randomized into two groups. In total, 20 patients in the ASA group used oral aspirin, at a dose of 300 mg/day, for VTE prophylaxis after TKA, while 20 patients in the rivaroxaban group received oral rivaroxaban, at a dose of 10 mg/day. On days 4 and 14 after the operation, deep vein thrombosis (DVT) in the lower limbs on the operated side was detected through duplex ultrasonography. Other complications were recorded for 14 days.

**Results** There were no positive findings of DVT detected with duplex ultrasonography in the groups of patients, and the occurrence of pulmonary embolism was not

### Keywords

- ▶ aspirin
- ▶ rivaroxaban
- ▶ arthroplasty, replacement, knee
- ▶ venous thromboembolism

\* Study developed at the Department of Orthopedics, Faculty of Medicine, Prince of Songkla University, Songkhla, Thailand.

received  
January 25, 2021  
accepted after revision  
May 14, 2021  
published online  
October 25, 2021

DOI <https://doi.org/10.1055/s-0041-1735941>.  
ISSN 0102-3616.

© 2021. Sociedade Brasileira de Ortopedia e Traumatologia. All rights reserved.  
This is an open access article published by Thieme under the terms of the Creative Commons Attribution-NonDerivative-NonCommercial-License, permitting copying and reproduction so long as the original work is given appropriate credit. Contents may not be used for commercial purposes, or adapted, remixed, transformed or built upon. (<https://creativecommons.org/licenses/by-nc-nd/4.0/>)  
Thieme Revinter Publicações Ltda., Rua do Matoso 170, Rio de Janeiro, RJ, CEP 20270-135, Brazil

observed. In total, 4 patients had subcutaneous ecchymosis on the fourth postoperative day (2 patients in the ASA group and 2 patients in the rivaroxaban group;  $p = 1.0$ ), and another 4 patients on the fourteenth postoperative day (1 patient in the ASA group and 3 patients in the rivaroxaban group;  $p = 0.292$ ). No cases of wound hematoma, major organ bleeding, wound infection, or reoperation were observed in the sample. **Conclusion** Aspirin and rivaroxaban had comparable efficacy to prevent VTE, without increasing the incidence of wound complications and bleeding after TKA.

## Resumo

**Objetivo** A aspirina (ácido acetilsalicílico, AAS) e a rivaroxabana são anticoagulantes que vêm ganhando popularidade devido à facilidade de uso na prevenção do tromboembolismo venoso (TEV) após artroplastia total do joelho (ATJ). Este estudo teve como objetivo avaliar a eficácia do AAS em comparação com a da rivaroxabana na profilaxia de TEV em pacientes submetidos a ATJ.

**Método** Quarenta pacientes com osteoartrite primária do joelho, que seriam submetidos a ATJ, foram randomizados em dois grupos. No total, 20 pacientes do grupo AAS usaram aspirina oral, na dose de 300 mg/dia, para a profilaxia do TEV após ATJ; e 20 pacientes do grupo rivaroxabana receberam uma dose oral de 10 mg/dia. No 4° e 14° dias do pós-operatório, trombose venosa profunda (TVP) dos membros inferiores no lado da cirurgia foi detectada por meio de ultrassonografia duplex. Foram registradas outras complicações durante catorze dias.

**Resultados** Não foram detectados achados positivos de TVP com a ultrassonografia duplex nos grupos de pacientes, e não se observou a ocorrência de embolia pulmonar. No total, 4 pacientes apresentaram equimose subcutânea no 4° dia do pós-operatório (2 pacientes no grupo AAS e 2 pacientes no grupo rivaroxabana;  $p = 1,0$ ), e outros 4 pacientes, no 14° dia do pós-operatório (1 paciente no grupo AAS e 3 pacientes no grupo rivaroxabana;  $p = 0,292$ ). Nenhum paciente da amostra apresentou hematoma da ferida cirúrgica, sangramento de órgão importante, infecção da ferida, ou necessidade de nova cirurgia.

**Conclusão** A aspirina e a rivaroxabana apresentaram eficácia comparável na prevenção do TEV, sem aumentar a incidência de complicações da ferida e sangramento após ATJ.

## Palavras-chave

- ▶ aspirina
- ▶ rivaroxabana
- ▶ artroplastia do joelho
- ▶ tromboembolia venosa

## Introduction

Venous thromboembolism (VTE) is a complication that can occur following total knee arthroplasty (TKA).<sup>1</sup> There are many modalities to prevent VTE, such as mechanical devices, early ambulation protocols, and anticoagulants.<sup>2</sup> Anticoagulants are currently included in the standard treatment protocols for almost every patient, except for those who have a contraindication, such as recent internal organ bleeding.<sup>3</sup> There are many anticoagulants prescribed to prevent VTE; however, aspirin (acetylsalicylic acid, ASA) and rivaroxaban are anticoagulants that have increased in popularity due to the ease of use.<sup>4,5</sup> These anticoagulants come in oral form, and do not require monitoring for blood coagulation. Moreover, ASA and rivaroxaban are effective in the prevention of VTE after TKA.<sup>6,7</sup>

Among the advantages of aspirin are its low cost and ease of administration, and a study<sup>8</sup> reports a lower risk of bleeding complications, such as, wound hematoma or

internal organ bleeding, compared with other anticoagulants. Rivaroxaban is a factor Xa inhibitor, with the advantage of being a potent anticoagulant with simple administration.<sup>9</sup> Some studies have compared the efficacy and safety of ASA and rivaroxaban in patients who underwent TKA. Additionally, in a small randomized controlled trial,<sup>10</sup> the authors found that there was no difference in the incidence of symptomatic deep vein thrombosis (DVT) and local and systemic complications between patients who received ASA and rivaroxaban. However, in another randomized controlled trial,<sup>10</sup> the authors reported there was a lower incidence of DVT in patients who received rivaroxaban compared with those who received ASA.<sup>11</sup>

Due to the limitations of randomized controlled trials comparing the efficacy of ASA and rivaroxaban combined with the lack of consensus regarding the results of previous studies, the present study aimed to evaluate the efficacy of ASA compared with that of rivaroxaban on VTE prophylaxis in patients who underwent TKA. The authors hypothesized

that ASA could prevent the incidence of VTE following TKA as effectively as rivaroxaban.

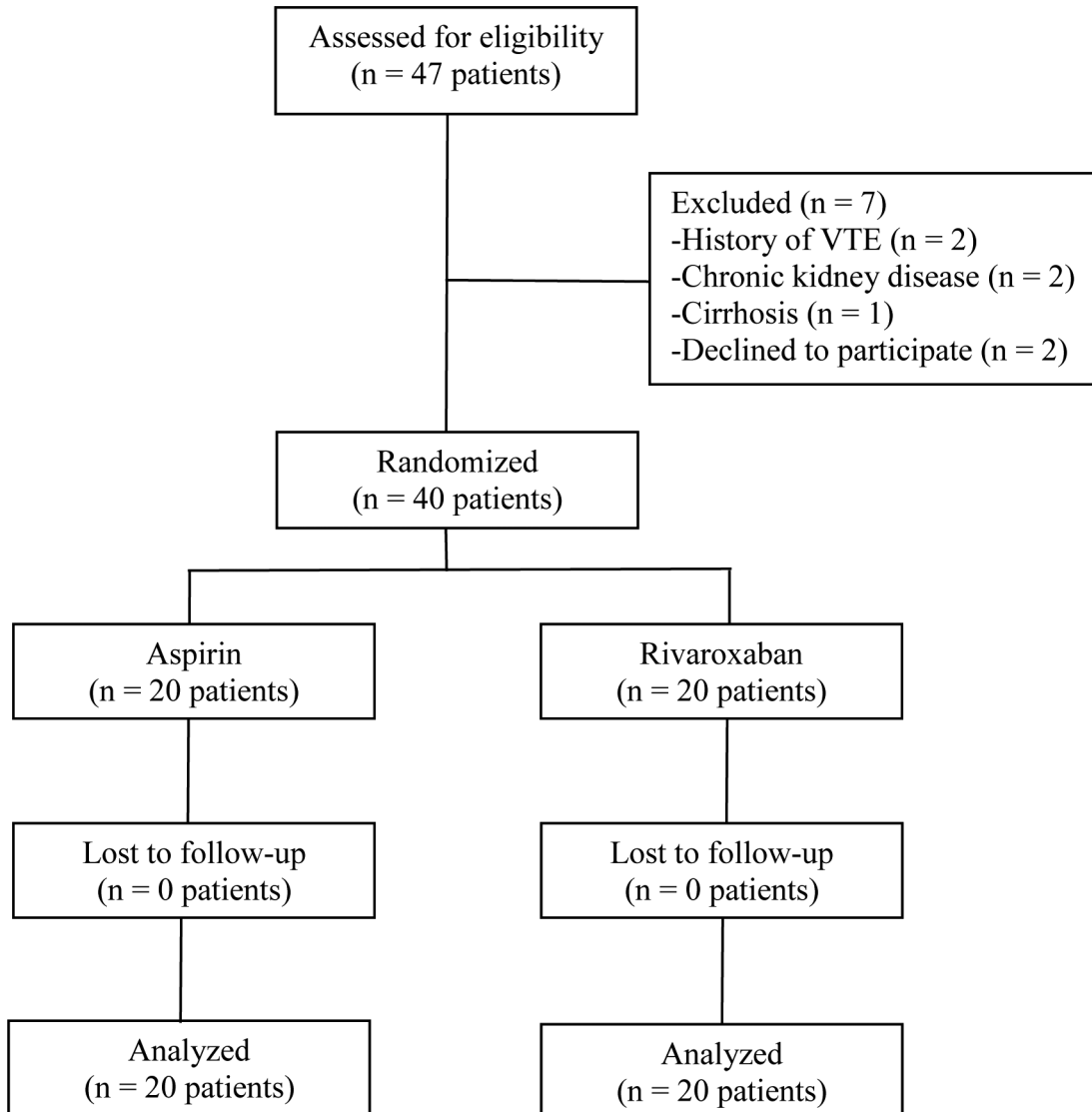
## Methods

The present prospective, randomized, controlled trial was performed with a group divided into 2 arms, with an allocation ratio of 1:1, in a tertiary care hospital from August 10, 2016, to December 31, 2018. The study was approved by the ethics committee and institutional review board. The protocol of the present study followed the Declaration of Helsinki's ethical principles for medical research involving human participants. The written informed consent form was signed by every participant included in the study. Clinical Trials Registry (<http://www.clinicaltrials.in.th>): TCTR20201226005.

A total of 47 patients aged > 50 years who had primary knee osteoarthritis and had an indication to undergo TKA were approached for possible inclusion. The exclusion criteria were patients with a history of coagulopathy, of VET, current use of anticoagulants, azoles, and proteinase

inhibitors, history of allergy to the medications used in the present study, allergy to the contrast material used in computed tomography, severe chronic kidney disease, cirrhosis, and asthma. In total, 7 patients were excluded: 2 had a history of VTE, 2 had chronic kidney disease, 1 had cirrhosis, and 2 declined to participate. Finally, 40 patients were included in the study (► Fig. 1).

The patients were allocated into two groups: in the ASA group, 20 patients received 300 mg of ASA for VTE prophylaxis, while, in the rivaroxaban group, 20 patients received 10 mg of rivaroxaban with the same goal. The patients in both groups took the medicine once a day, after breakfast, for 14 days, starting on the day following TKA. All patients underwent the cemented posterior stabilized total knee prosthesis procedure, with the same surgical techniques, with an inflated pneumatic tourniquet throughout the operation. Cefazolin was used for prophylaxis against surgical infection. In cases of allergy to penicillin or cephalosporin, clindamycin was used instead. Closed suction drainage was placed before wound closure, and was removed 48 hours



**Fig. 1** Flowchart of the study.

postoperatively. Patients were allowed to perform quadriceps isometric exercises and ankle pumping immediately after the operation, and they started range of motion exercises and ambulation with a supportive device the first postoperative day.

Hematocrit was recorded at 6 hours, 4 days and 14 days after the operation. On the fourth and fourteenth postoperative days, an experienced musculoskeletal radiologist diagnosed DVT in the lower extremities through duplex ultrasonography. In cases of patients with any clinical suspicion of pulmonary embolism, spiral chest computed tomography was performed to confirm the diagnosis. Postoperative complications, such as wound complications and unexpected bleeding, were closely observed until the fourteenth postoperative day.

Patients were allocated in groups of four with blocks randomization through a computer-generated random number sequence kept in sealed, opaque envelopes. The envelope was opened on the morning of the operative day by a pharmacist in the inpatient hospital pharmacy. The patients, physician and evaluator were blinded to the groups of patients.

## Statistical Analysis

The R (R Foundation for Statistical Computing, Vienna, Austria) software, version 3.1.0, was used to analyze the data. Patient demographics, such as age, body mass index (BMI), pre- and postoperative hematocrit, platelet count, and tourniquet time and operative time (in minutes), were evaluated using the *t*-test. The Pearson Chi-squared test was used to compare gender, side, rate of blood transfusion, the incidence of DVT, pulmonary embolism, wound complication, bleeding, and other complications. Statistical significance was as  $p < 0.05$ .

## Results

Demographics, including age, gender, operated side, BMI, preoperative hematocrit, platelet count, tourniquet time, and operative time, were not significantly different between the two study groups ( $p > 0.05$ ) (– Table 1).

There was no positive finding of DVT detected with duplex ultrasonography in either group, neither were there cases of

patients with symptoms of pulmonary embolism. The postoperative hematocrit was not different between the groups after 6 hours (ASA:  $33.69 \pm 4.01\%$ ; rivaroxaban:  $32.79 \pm 3.48\%$ ;  $p = 0.453$ ), 24 hours (ASA:  $31.33 \pm 3.3\%$ ; rivaroxaban:  $29.93 \pm 2.99\%$ ;  $p = 0.17$ ), and 2 weeks (ASA:  $34.33 \pm 4.75\%$ ; rivaroxaban:  $33.75 \pm 3.07\%$ ;  $p = 0.649$ ) of the procedure. Five patients in the ASA group and six in the rivaroxaban group received allogenic blood transfusions ( $p = 0.723$ ). In total, 4 patients had subcutaneous ecchymosis on the 4th postoperative day (2 patients in the ASA group and 2 patients in the rivaroxaban group;  $p = 1.0$ ), and another 4 on the 14th postoperative day (1 patient in the ASA group and 3 patients in the rivaroxaban group;  $p = 0.292$ ). No patients in the sample had wound hematoma, major organ bleeding, wound infection or reoperation.

## Discussion

Aspirin and rivaroxaban are widely used for the prevention of VTE after TKA. Previous studies<sup>12–14</sup> comparing the efficacy and safety of ASA and rivaroxaban found no difference in the rates of VTE, bleeding complications, wound complications, and hospital readmission. However, a retrospective study<sup>15</sup> reported that patients who used ASA had a higher risk of VTE, pulmonary embolism, and readmission.

The authors decided to conduct the present study due to the limitations of randomized controlled trials comparing ASA and rivaroxaban in the prevention of VTE after TKA, and due to previous studies in which no consensus was reached regarding the results. Our results showed that the use of ASA or rivaroxaban does not lead to differences in the incidence of VTE, of DVT in screening by duplex ultrasonography, of pulmonary embolisms, and on the rates of blood transfusion, bleeding, and wound complications.

The present study has some limitations. First, the limited number of participants, which might be insufficient to detect the differences regarding VTE. Second, the larger proportion of female patients who were overweight based on BMI calculations. Finally, all of the patients in the study were of Asian ethnicity, which has a lower rate of VTE compared to western populations.<sup>16</sup> However, we believe that our findings could apply to male patients, Western patients, as well as those who are in other BMI ranges.

**Table 1** Demographics of the study sample

Characteristic	Rivaroxaban group: n = 20	Acetylsalicylic acid (ASA) group: n = 20	p-value
Age (years)	70.5 ± 7.25*	68.15 ± 7.43*	0.318
Gender (male:female)	3:17	7:13	0.144
Side (right:left)	12:8	11:9	0.749
Body mass index (kg/m <sup>2</sup> )	26.91 ± 3.66*	29.15 ± 4.49*	0.092
Preoperative hematocrit (%)	38.42 ± 4.57	38.41 ± 4.13	0.994
Platelet (cell/mm <sup>3</sup> )	272,350 ± 106,355	261760 ± 116,594	0.766
Tourniquet time (minutes)	117.6 ± 39.22	121.6 ± 24.41	0.701
Operative time (minutes)	163.65 ± 43.16	167 ± 29.84	0.777

Note: \*Means and standard deviations.

The present study demonstrated that there was no difference in the incidence of VTE, and of DVT demonstrated by screening via duplex ultrasonography; neither were their differences regarding pulmonary embolism in both groups of patients after TKA. Our results are supported by those of a study from Brazil. Colleoni et al.<sup>10</sup> performed a small, randomized controlled trial in 32 patients, comparing ASA 300 mg with rivaroxaban 20 mg, and the results showed there was no difference in the rate of DVT between the groups. However, a previous, prospective, randomized controlled trial contradicts these results: Zou et al.<sup>11</sup> reported that patients who used rivaroxaban at a dose of 10 mg/day had a lower incidence of DVT than patients who used oral ASA at a dose of 100 mg/day. We hypothesized that the lower dose of ASA in the study by Zou et al.<sup>11</sup> might be a factor that led to results that differ from those of the present study and those of the study by Colleoni et al.<sup>10</sup>

Regarding the complications caused by the use of medication, the present study demonstrated a minor complication from ASA and rivaroxaban: postoperative subcutaneous ecchymosis, which was not different in incidence between groups. There were no major complications, such as wound infection, bleeding complications, and reoperation. Our findings coincide with those of Colleoni et al.,<sup>10</sup> who reported no difference in the rates of wound dehiscence, deep infection, and reoperation between the patients who used ASA and those who used rivaroxaban. In contradiction to our findings, Zou et al.<sup>11</sup> observed that rivaroxaban led to a higher incidence of wound complication and subcutaneous ecchymosis than ASA. Nevertheless, the patients in the study by Zou et al.<sup>11</sup> had no intracranial or gastrointestinal tract hemorrhage, which is in line with the findings of the present study.

## Conclusion

Aspirin and rivaroxaban have comparable efficacy in the prevention of VTE, without increasing the incidence of wound complication and bleeding after TKA. For primary TKA, ASA and rivaroxaban could be used to prevent VTE. Further studies with larger populations should be conducted to provide more precise results and more useful information.

### Availability of Data and Materials

The datasets generated during this current study are available from the corresponding author upon reasonable request.

### Financial Support

Funding for this research was provided by the Faculty of Medicine, Prince of Songkla University, Songkhla, Thailand (grant number 59-390-11-1). The funders had no role in study design, data collection and analysis, decision to publish, nor preparation of the manuscript.

### Conflict of Interests

The authors have no conflict of interests to declare.

## Acknowledgments

The authors wish to thank Andrew Jonathan Tait, from the International Affairs Department, for his assistance in proofreading the English of this report.

## References

- Bala A, Huddleston JI III, Goodman SB, Maloney WJ, Amanatullah DF. Venous Thromboembolism Prophylaxis After TKA: Aspirin, Warfarin, Enoxaparin, or Factor Xa Inhibitors? *Clin Orthop Relat Res* 2017;475(09):2205-2213
- Colwell CW. The ACCP guidelines for thromboprophylaxis in total hip and knee arthroplasty. *Orthopedics* 2009;32(12, Suppl):67-73
- Eikelboom JW, Karthikeyan G, Fagel N, Hirsh J. American Association of Orthopedic Surgeons and American College of Chest Physicians guidelines for venous thromboembolism prevention in hip and knee arthroplasty differ: what are the implications for clinicians and patients? *Chest* 2009;135(02):513-520
- Liu J, Zhao J, Yan Y, Su J. Effectiveness and safety of rivaroxaban for the prevention of thrombosis following total hip or knee replacement: A systematic review and meta-analysis. *Medicine (Baltimore)* 2019;98(09):e14539
- Wilson DGG, Poole WEC, Chauhan SK, Rogers BA. Systematic review of aspirin for thromboprophylaxis in modern elective total hip and knee arthroplasty. *Bone Joint J* 2016;98-B(08):1056-1061
- Chen CF, Tsai SW, Wu PK, Chen CM, Chen WM. Does continued aspirin mono-therapy lead to a higher bleeding risk after total knee arthroplasty? *J Chin Med Assoc* 2019;82(01):60-65
- Huang HF, Li SS, Yang XT, Xie Q, Tian XB. Rivaroxaban versus enoxaparin for the prevention of venous thromboembolism after total knee arthroplasty: A meta-analysis. *Medicine (Baltimore)* 2018;97(48):e13465
- Sharrock NE, Gonzalez Della Valle A, Go G, Lyman S, Salvati EA. Potent anticoagulants are associated with a higher all-cause mortality rate after hip and knee arthroplasty. *Clin Orthop Relat Res* 2008;466(03):714-721
- Charters MA, Frisch NB, Wessell NM, Dobson C, Les CM, Silverton CD. Rivaroxaban Versus Enoxaparin for Venous Thromboembolism Prophylaxis after Hip and Knee Arthroplasty. *J Arthroplasty* 2015;30(07):1277-1280
- Colleoni JL, Ribeiro FN, Mos PAC, Reis JP, Oliveira HR, Miura BK. Venous thromboembolism prophylaxis after total knee arthroplasty (TKA): aspirin vs. rivaroxaban. *Rev Bras Ortop* 2017;53(01):22-27
- Zou Y, Tian S, Wang Y, Sun K. Administering aspirin, rivaroxaban and low-molecular-weight heparin to prevent deep venous thrombosis after total knee arthroplasty. *Blood Coagul Fibrinolysis* 2014;25(07):660-664
- Matharu GS, Kunutsor SK, Judge A, Blom AW, Whitehouse MR. Clinical Effectiveness and Safety of Aspirin for Venous Thromboembolism Prophylaxis After Total Hip and Knee Replacement: A Systematic Review and Meta-analysis of Randomized Clinical Trials. *JAMA Intern Med* 2020;180(03):376-384
- Xu J, Kanagaratnam A, Cao JY, Chaggar GS, Bruce W. A comparison of aspirin against rivaroxaban for venous thromboembolism prophylaxis after hip or knee arthroplasty: A meta-analysis. *J Orthop Surg (Hong Kong)* 2020;28(01):2309499019896024
- Yuenyongviwat V, Tuntarattanapong P, Chuaychoosakoon C, Iemsaengchairat C, Iamthanaporn K, Hongnaparak T. Aspirin versus rivaroxaban in postoperative bleeding after total knee arthroplasty: a retrospective case-matched study. *Eur J Orthop Surg Traumatol* 2019;29(04):877-881

- 15 Matharu GS, Garriga C, Whitehouse MR, Rangan A, Judge A. Is Aspirin as Effective as the Newer Direct Oral Anticoagulants for Venous Thromboembolism Prophylaxis After Total Hip and Knee Arthroplasty? An Analysis From the National Joint Registry for England, Wales, Northern Ireland, and the Isle of Man. *J Arthroplasty* 2020;35(09):2631–2639.e6
- 16 Kanchanabat B, Stapanavatr W, Meknavin S, Soorapanth C, Sumanasrethakul C, Kanchanasuttirak P. Systematic review and meta-analysis on the rate of postoperative venous thromboembolism in orthopaedic surgery in Asian patients without thromboprophylaxis. *Br J Surg* 2011;98(10):1356–1364