

# Evaluation of the Functional Outcomes of Arthroscopic Surgical Treatment of Complete Rotator Cuff Lesion with Minimum Follow-up of 10 Years\*

## *Avaliação dos resultados funcionais do tratamento cirúrgico artroscópico da lesão completa do manguito rotador com seguimento mínimo de 10 anos*

André Couto Godinho<sup>1</sup> Flávio Márcio Lago Santos<sup>2</sup> Francisco Pereira Donato Neto<sup>1</sup>  
Paulo Victor Nunes Paz Silva<sup>1</sup> Ricardo Dantas Fonseca Júnior<sup>1</sup>

<sup>1</sup> Shoulder Service, Hospital Ortopédico BH, Belo Horizonte, MG, Brazil

<sup>2</sup> Shoulder Service, Hospital Lifecenter, Belo Horizonte, MG, Brazil

Address for correspondence André Couto Godinho, MSc, Rua dos Aimorés, 2085, Apartamento 1502, Belo Horizonte, MG, 30140-072, Brazil (e-mail: andre\_cgod@hotmail.com).

Rev Bras Ortop 2020;55(5):579–584.

### Abstract

**Objectives** To analyze the functional outcomes in patients submitted to videoarthroscopic surgical treatment for complete rotator cuff tears of the shoulder, with a minimum follow-up of 10 years.

**Methods** A total of 63 patients (63 shoulders) underwent videoarthroscopic surgical repair for complete rotator cuff tears with a minimum follow-up of 10 years. The postoperative functional outcomes of these patients were evaluated using the Constant and University of California at Los Angeles (UCLA) scores.

**Results** The functional evaluation revealed mean UCLA and Constant scores of 26 and 93 points, respectively. Ninety-one percent of the subjects had satisfactory Constant scores, whereas 62% presented satisfactory UCLA scores.

**Conclusion** The arthroscopic repair of rotator cuff complete tear was effective even in the long term (minimum follow-up period of 10 years). The age of the patients before surgery, size of the lesion, the degree of fatty infiltration, and evaluation of muscle trophism are important predictors of prognosis.

### Keywords

- ▶ shoulder
- ▶ arthroscopy
- ▶ rupture
- ▶ rotator cuff
- ▶ evaluation studies

### Resumo

**Objetivo** Analisar o resultado funcional dos pacientes submetidos ao tratamento cirúrgico videoartroscópico da ruptura completa do manguito rotador do ombro, com seguimento mínimo de 10 anos.

**Métodos** Foram avaliados 63 pacientes (63 ombros) submetidos ao reparo cirúrgico videoartroscópico da ruptura completa do manguito rotador com seguimento mínimo

\* Study performed by the Shoulder Surgery and Rehabilitation Group from Belo Horizonte, MG, Brazil (Ortopédico BH, Hospital Belo Horizonte and Lifecenter).

**Palavras-chave**

- ▶ ombro
- ▶ artroscopia
- ▶ ruptura
- ▶ manguito rotador
- ▶ estudos de avaliação

de 10 anos. O resultado funcional no pós-operatório desses pacientes foi avaliado pelos escores de Constant e UCLA.

**Resultados** Os valores médios foram de 26 pontos no escore UCLA e de 93 no escore de Constant. Para o escore de Constant, 91% foram considerados satisfatórios; e para o UCLA, 62% dos pacientes apresentaram escores satisfatórios.

**Conclusão** O reparo artroscópico da ruptura completa do manguito rotador mostrou-se efetivo mesmo a longo prazo (seguimento mínimo de dez anos). A idade dos pacientes antes da cirurgia, o tamanho da lesão, o grau de infiltração gordurosa e a avaliação do trofismo muscular foram importantes preditores de prognóstico.

**Introduction**

Degenerative and traumatic injuries affecting the rotator cuff (RC) are among the most common diseases of the shoulder, especially in the female population over 50 years old.<sup>1</sup>

The pathogenesis of the rotator cuff injury is still unclear, but it is believed to be multifactorial, resulting from avascularity, age or eccentric load; these factors are associated with rotator cuff fibers failure, which leads to functional impairment.<sup>2</sup> Although some rupture cases may be asymptomatic, this is a progressive, degenerative condition resulting in shoulder pain and functional compromise.<sup>3</sup>

Diagnosis is essentially clinical, based on detailed anamnesis and thorough physical examination.<sup>4</sup> Some imaging tests, particularly magnetic resonance imaging (MRI), assist in the diagnosis of RC injuries.<sup>5</sup>

Treatment ranges from non-surgical methods, including pharmacological therapy and muscle strengthening, to surgical repair, either through an open or arthroscopic approach, both leading to good outcomes.<sup>4</sup>

Surgical treatment of RC injuries has been increasingly recommended. In recent years, the arthroscopic technique is the one most frequently used since it is less aggressive to the deltoid muscle and less painful, thus leading to an earlier rehabilitation compared with the open tendon repair.<sup>6</sup> As an advantage, this technique allows a complete assessment of the glenohumeral joint and associated conditions (such as chondral lesions, glenohumeral arthrosis, acromioclavicular arthrosis, tenosynovitis of the long head of the biceps, capsuloligamentous injuries, superior labral anterior and posterior [SLAP] injuries, etc.).<sup>7,8</sup>

The present study aimed to analyze the functional outcomes of patients with complete rotator cuff rupture who were submitted to the videoarthroscopic surgical treatment and assessed using the aforementioned scores and followed-up for at least 10 years.

**Casistry and Methods**

This is a retrospective evaluation study including 100 randomly-selected patients who were submitted to the arthroscopic repair of the rotator cuff and followed-up for at least 10 years. The procedures were performed by shoulder surgeons from the same group, applying a standard surgical technique.

All patients underwent surgical treatment of the rotator cuff injury in lateral decubitus position, using an arthroscopic approach and the simple row tendon suture technique with metal anchors,<sup>9</sup> associated or not with tenotomy and/or tenodesis of the long head of the biceps' tendon (LHBT), acromioplasty, and total Mumford procedure (total resection of the lateral clavicular end).<sup>10</sup>

Arthroscopic Mumford procedures were performed on subjects with symptomatic acromioclavicular joint osteoarthritis confirmed by radiographic findings (sclerosis, subchondral cysts, joint irregularity), presence of edema on the lateral end of the clavicle at MRI, pain during joint palpation, positive adduction test,<sup>11</sup> and positive O'Brien test.<sup>12</sup>

Patients came spontaneously to a clinical and radiographic evaluation performed by three orthopedists specializing in shoulder surgery. Subjects with a previous diagnosis of glenohumeral osteoarthritis, rheumatoid arthritis, sequelae of proximal humeral fractures, associated glenohumeral instability, and incomplete documentation were excluded. After applying these exclusion criteria, 63 patients (63 shoulders) were included in our case series.

Several preoperative factors were analyzed, such as fatty infiltration degree, according to the Goutallier et al.<sup>13</sup> classification, in which muscles were divided in group 0 (no fatty infiltration), group 1 (low grade fatty infiltration, including grades 1 and 2), and group 2 (high grade fatty infiltration, including grades 3 and 4). Age, gender, affected side, smoking, dominance, lesion mechanism, and muscular trophism were also considered. Muscle trophism was characterized by the tangent sign, as described by Zannetti et al.<sup>14</sup> (a line drawn between the end of the coracoid process and the scapular spine at an oblique sagittal MRI scans to determine supraspinatus muscle trophism; muscle location below or above this line indicates hypotrophy or eutrophy, respectively), while the anteroposterior extension of the lesions was classified according to DeOrto and Cofield.<sup>15</sup>

Postoperative follow-up time ranged from 10 (minimum) to 18 years (maximum), with a mean period of 14.2 years. Thirty-six of the patients were female (57.1%) and 27 were male (42.9%). Their mean age was 57.2 years old (minimum of 46 and maximum of 72 years old). The dominant side was affected in 46 patients (73%). Degenerative lesions were observed in 82.5% of the sample, and ~ 17.5% of the patients presented traumatic injuries.

Constant<sup>16</sup> and University of California at Los Angeles (UCLA)<sup>17</sup> scores assessed postoperative functional outcomes and were crossed with preoperative data.

Repair integrity at the late postoperative period was evaluated through MRI scans performed on all patients. The absence of tendon continuity from the myotendinous junction to its attachment at the greater tubercle was classified as de novo rotator cuff rupture.

Data descriptive analysis used mean and standard deviation for quantitative variables and absolute frequency and percentage for qualitative variables. The Student *t*-test was used to detect differences between the groups regarding quantitative variables in independent samples. The association between functional classifications (satisfactory and unsatisfactory scores) and potential explanatory variables was determined by the chi-square test or the Fisher exact test, when appropriate. The effect size for quantitative variables was assessed through Cohen *d*, using the following classification for interpretation: small association, 0.2–0.4; moderate association, 0.5–0.7; high association, ≥ 0.8; for qualitative variables, Cramér *V* was used, with the following classification for interpretation: small association, 0.1–0.2; moderate association, 0.3–0.4; high association, ≥ 0.5. All analyses were performed with the statistical software IBM SPSS version 20.0 (IBM Corp., Armonk, NY, USA). Statistical significance was determined at *p* < 0.05 level.

This study was approved by the Research Ethics Committee from the Hospital under CAEE number 83280217.7.0000.5126.

### Results

► **Tables 1 and 2** show general characteristics from patients and lesions, respectively. The most frequently affected tendon was the supraspinatus (SS) (92%). Most patients had lesions up to 3 centimeters in size (60.3%), with Goutallier classification < 2 (77.8%) and no tangent sign (90.5%).

► **Table 3** characterizes the surgical treatment. In most cases (92.1%), acromioplasty was performed, and 68.3% of the subjects received two anchors for tendon-bone fixation. Approximately half of the patients had intact LHBT (49.2%), and only 6.3% underwent a Mumford procedure.

Re-rupture were observed in only 9.5% of the cases. Functional evaluation revealed a mean UCLA score of 26

**Table 2** Rotator cuff lesion features

	N	%
Affected tendon(s)		
SS	58	92.0
SS + IS	3	4.8
SS + SC	2	3.2
Tangent sign		
Negative	57	90.5
Positive	6	9.5
Goutallier		
0	24	38.1
1	25	39.7
2	14	22.2
Lesion mechanism		
Degenerative	52	82.5
Traumatic	11	17.5
Lesion size		
< 1 cm	8	12.7
1–3 cm	38	60.3
3–5cm	15	23.8
> 5 cm	2	3.2
Re-rupture		
No	57	90.5
Yes	6	9.5
Constant score	92.8 ± 15.9 (62 to 136)	
UCLA score	26.5 ± 4.3 (14 to 30)	

Abbreviations: IS, infraspinatus; SC, subscapularis; SS, supraspinatus; UCLA, University of California at Los Angeles. Mean ± standard deviation (minimum–maximum value).

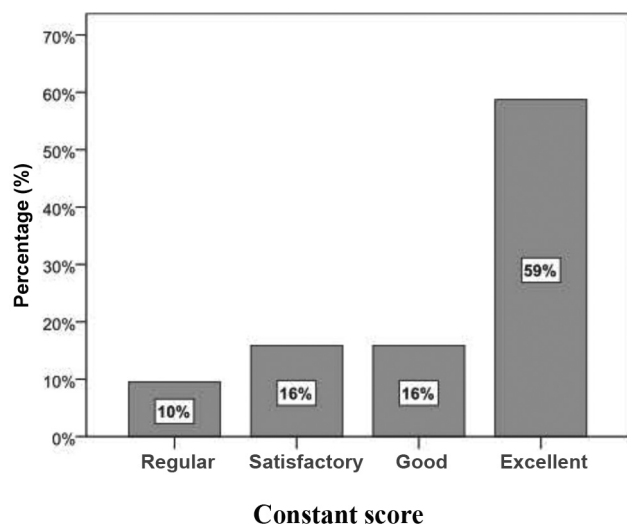
**Table 3** Surgical treatment features

	N	%
Anchors		
1	13	20.6
2	43	68.3
3	6	9.5
4	1	1.6
LHBT		
Intact	31	49.2
Tenotomy	30	47.6
Tenodesis	2	3.2
Acromioplasty		
No	5	7.9
Yes	58	6.3
Mumford		
No	59	93.7
Yes	4	6.3

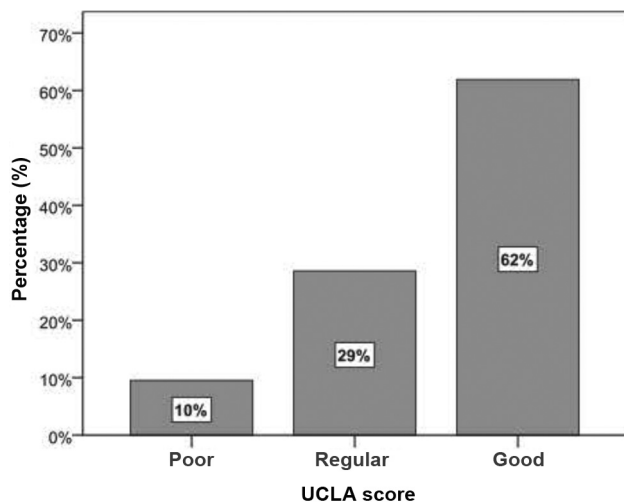
Abbreviations: LHBT, long head of the biceps' tendon.

**Table 1** Patients' characteristics

	N	%
Gender		
Female	36	57.1
Male	27	42.9
Age (years)	57.2 ± 9.6	
Laterality		
Right	49	77.8
Left	14	22.2



**Fig. 1** Functional classification according to the Constant score. 1. Percentage (%). 2. Regular. 3. Satisfactory. 4. Good. 5. Excellent. 6. Constant score.



**Fig. 2** Functional classification according to the University of California at Los Angeles (UCLA) score. 1. Percentage (%). 2. Poor. 3. Regular. 4. Good. 5. UCLA score.

points and a mean Constant score of 93 points (► **Table 2**). ► **Figs. 1** and **2** show functional assessment outcomes. Final Constant scores were classified according to Boehm<sup>18</sup> as excellent (91–100), good (81–90), satisfactory (71–80), regular (61–70), or poor (< 60). No patient presented poor Constant scores (< 60). Most subjects (91% of the sample) had satisfactory, good, or excellent Constant scores, that is, higher than 70 points. Final UCLA scores were classified according to Ellman et al.<sup>19</sup> as excellent (34–35), good (28–33), regular (21–27), and poor (00–20). In total, 62% of the patients had good UCLA scores, that is,  $\geq 28$  points, whereas 29% and 10% had regular and poor scores, respectively. None of our patients presented excellent UCLA scores.

The following explanatory variables were associated with the functional outcome per the UCLA score: Goutallier, tangent sign, LHBT tenotomy, and age (► **Table 4**). Patients with unsatisfactory UCLA scores were classified as Goutallier  $\geq 2$ ,

had a positive tangent sign and underwent LHBT tenotomy; in addition, most of them were older, with a mean age higher than 63 years old. From a practical point of view, the association between these variables (Goutallier classification, tangent sign, and LHBT tenotomy) and the UCLA score had a moderate magnitude, explaining 9 to 14% of unsatisfactory outcomes, according to Cramér V-values. On the other hand, age had a high association, suggesting that being older than 63 is a strong predictor of unsatisfactory UCLA scores.

The following explanatory variables were associated with the functional outcome per the Constant score: Goutallier classification, tangent sign, and age (► **Table 4**). Patients with unsatisfactory Constant scores were classified as Goutallier  $\geq 2$ , presented positive tangent sign and were older, with an average age higher than 69 years old. From a practical point of view, the association between Goutallier classification  $\geq 2$ , positive tangent sign and Constant scores had a moderate magnitude, explaining 7 to 12% of the unsatisfactory Constant scores, according to Cramér V-values. On the other hand, age over 69 years presented a high association, suggesting that being older is a strong predictor for unsatisfactory Constant scores.

## Discussion

The literature provides few studies assessing functional scores in patients submitted to videoarthroscopic RC repairs and followed-up for at least 10 years after surgery.<sup>20–26</sup>

DeFranco et al.<sup>27</sup> reported age as the main predictor of structural integrity after an arthroscopic repair. In our study, younger patients achieved better functional outcomes compared with older subjects.

Despite the lack of statistical significance, infraspinatus, teres minor, and subscapularis tendon lesions were associated with a higher degree of dissatisfaction compared with supraspinatus injuries alone. The literature<sup>2</sup> may explain this association, since posterosuperior and anterosuperior injuries are related to bigger lesions (> 3 cm), with a more advanced degree of fatty infiltration (Goutallier > 2) and a low-quality muscle trophism (positive Zanetti tangent sign).

Follow-up MRI scans performed 10 years after RC repair revealed an average rate of 9.5% of re-ruptures, consistent with values found by Sugaya et al.,<sup>28</sup> who observed re-ruptures rates of 13% in medium-sized lesions and 44% in large, massive lesions.

Most lesions were degenerative (82.5%), consistent with previous literature reports.<sup>1,2</sup> The number of anchors used for lesion repair did not influence functional outcomes. In addition, it did not influence the performance or not of the total Mumford procedure and of acromioplasty, as corroborated by Miyazaki et al.<sup>21</sup>

Patients who did not undergo LHBT tenotomy showed better Constant (97.0% of satisfactory outcomes) and UCLA scores (78.8% of satisfactory outcomes).

Arthroscopic repair in lesions < 3 cm resulted in better Constant and UCLA scores (91.3% and 67.4% of satisfactory scores, respectively). These values are consistent with the literature.<sup>26</sup> Large and massive lesions according to the Cofield classification are associated with worse functional scores.<sup>2</sup>

**Table 4** Association between potential exposure factors and functional outcome

Variable	Category	Satisfactory Constant (n = 57)	Unsatisfactory Constant (n = 6)	p-value	ES	Satisfactory UCLA (n = 39)	Unsatisfactory UCLA (n = 24)	p-value	ES
Gender	Female (n = 36)	88.9%	11.1%	0.69	0.06	58.3%	41.7%	0.05	0.008
	Male (n = 27)	92.6%	7.4%			66.7%	33.3%		
Acromioplasty	No (n = 5)	80.0%	20.0%	0.40	0.10	80.0%	20.0%	0.64	0.11
	Yes (n = 58)	91.4%	8.6%			60.3%	39.7%		
Mumford	No (n = 59)	91.5%	8.5%	0.34	0.14	62.7%	37.3%	0.63	0.06
	Yes (n = 4)	75.0%	25.0%			50.0%	50.0%		
Lesion size	Up to 3 cm (n = 46)	88.2%	11.8%	0.66	0.05	67.4%	32.6%	0.14	0.19
	> 3 cm (n = 17)					47.1%	52.9%		
Goutallier	< 2 (n = 49)	95.9%	4.1%	0.02*	0.35	71.4%	28.6%	0.004*	0.37
	≥2 (n = 14)	71.4%	28.6%			28.6%	71.4%		
Affected tendons	SS (n = 58)	93.1%	6.9%	0.07	0.30	63.8%	36.2%	0.36	0.13
	SS + IS/SC (n = 5)	60.0%	40.0%			40.0%	60.0%		
Tangent sign	Negative (n = 57)	93.0%	7.0%	0.04*	0.26	66.7%	33.3%	0.03*	0.30
	Positive (n = 6)	66.7%	33.3%			16.7%	83.3%		
Tenotomy	No (n = 33)	97.0%	3.0%	0.09	0.23	78.8%	21.2%	0.004*	0.36
	Yes (n = 30)	83.3%	16.7%			43.3%	56.7%		
Age (years)		55.9 ± 8.9	69.3 ± 8.8	0.001*	1.50	53.7 ± 8.6	63.0 ± 8.4	< 0.001*	1.09
Number of anchors		1.9 ± 0.6	2.2 ± 1.0	0.30	0.37	1.8 ± 0.6	2.0 ± 0.6	0.21	0.33

Abbreviations: SS, supraspinatus; IS, infraspinatus; SC, subscapularis; UCLA, University of California at Los Angeles.

(Percentage regarding line total; \*significant difference,  $p < 0.05$ ; ES: effect size. – Cohen's d [quantitative variables] small: 0.2–0.4; moderate: 0.5–0.7; high:  $\geq 0.8$ ; – Cramer's V [qualitative variables] small: 0.1–0.2; moderate: 0.3–0.4; high:  $\geq 0.5$ ).

Collin et al.<sup>3</sup> reported that patients with Goutallier < 2 had 84.9% of satisfaction at the Constant score and that the preoperative degree of fatty infiltration is inversely proportional to the functional score. In our study, RC injuries with Goutallier < 2 obtained excellent results at the Constant and UCLA scores (95.9% and 71.4% of satisfaction, respectively). Although a Goutallier index > 2 does not contraindicate arthroscopic RC repair, this variable suggests a worse prognosis, confirmed by the unsatisfactory Constant and UCLA scores (28.6% and 71.4%, respectively).<sup>3</sup>

Negative tangent signs are associated with better functional results, with satisfaction indexes of 93.0% and 66.7% at the Constant and UCLA scores, respectively. These findings are consistent with Collin et al.,<sup>3</sup> who obtained similar Constant scores, confirming the best prognosis for injuries with good muscular trophism.

The arthroscopic repair of the RC provided durable, satisfactory outcomes, with 75% of the patients reporting excellent and good Constant scores, as demonstrated by Galatz et al.,<sup>20</sup> with a 91% rate in patients followed-up for at least 10 years.

The lack of a preoperative functional assessment using the UCLA and Constant scores can be pointed out as a limitation of our study. The follow-up of these patients will show a potential functional variation over time. Another important fact to be considered is that most of our patients had isolated supraspinatus tendon lesions (92%), which can influence the results of the evaluation.

## Conclusion

Arthroscopic RC repair proved to be effective even in the long term (minimum follow-up time of 10 years).

Patient's age at the time of surgery, size of the lesion, degree of fatty infiltration (Goutallier), and muscle trophism (tangent sign) were the most reliable predictors of success and/or failure.

### Conflict of Interests

The authors declare that there is no conflict of interests.

## References

- White JJ, Titchener AG, Fakis A, Tambe AA, Hubbard RB, Clark DI. An epidemiological study of rotator cuff pathology using The Health Improvement Network database. *Bone Joint J* 2014;96-B(03):350–353
- Veado MAC, Gomes TPO, Pinto RZA. Análise funcional e estrutural do reparo das lesões extensas do manguito rotador. *Rev Bras Ortop* 2006;41(08):294–301
- Collin P, Kempf JF, Molé D, et al. Société Française de Chirurgie Orthopédique et Traumatologique (SoFCOT). Ten-Year Multicenter Clinical and MRI Evaluation of Isolated Supraspinatus Repairs. *J Bone Joint Surg Am* 2017;99(16):1355–1364
- Godinho GG, França FO, Freitas JM, et al. Avaliação da integridade anatômica por exame de ultrassom e funcional pelo índice de Constant & Murley do manguito rotador após reparo artroscópico. *Rev Bras Ortop* 2010;45(02):174–180



- 5 Rutten MJ, Spaargaren GJ, van Loon T, de Waal Malefijt MC, Kiemeny LA, Jager GJ. Detection of rotator cuff tears: the value of MRI following ultrasound. *Eur Radiol* 2010;20(02):450–457
- 6 Ghodadra NS, Provencher MT, Verma NN, Wilk KEW, Romeo AA. Open, mini-open, and all-arthroscopic rotator cuff repair surgery: indications and implications for rehabilitation. *J Orthop Sports Phys Ther* 2009;39(02):81–89
- 7 Gartsman GM, Khan M, Hammerman SM. Arthroscopic repair of full-thickness tears of the rotator cuff. *J Bone Joint Surg Am* 1998;80(06):832–840
- 8 Checchia SL, Doneux PS, Miyazaki AN, et al. Avaliação dos resultados obtidos na reparação artroscópica das lesões do manguito rotador. *Rev Bras Ortop* 2005;40(05):229–238
- 9 Godinho GG, Souza JM, Bicalho LA. Reparo das rupturas do manguito rotador do ombro pela videoartroscopia cirúrgica: técnica. *Rev Bras Ortop* 1996;31(04):284–288
- 10 Levine WN, Barron OA, Yamaguchi K, Pollock RG, Flatow EL, Bigliani LU. Arthroscopic distal clavicle resection from a bursal approach. *Arthroscopy* 1998;14(01):52–56
- 11 McLAUGHLIN HL. On the frozen shoulder. *Bull Hosp Jt Dis* 1951;12(02):383–393
- 12 O'Brien SJ, Pagnani MJ, Fealy S, McGlynn SR, Wilson JB. The active compression test: a new and effective test for diagnosing labral tears and acromioclavicular joint abnormality. *Am J Sports Med* 1998;26(05):610–613
- 13 Goutallier D, Postel JM, Radier C, Bernageau J, Zilber S. Long-term functional and structural outcome in patients with intact repairs 1 year after open transosseous rotator cuff repair. *J Shoulder Elbow Surg* 2009;18(04):521–528
- 14 Zanetti M, Gerber C, Hodler J. Quantitative assessment of the muscles of the rotator cuff with magnetic resonance imaging. *Invest Radiol* 1998;33(03):163–170
- 15 Cofield RH. Subscapular muscle transposition for repair of chronic rotator cuff tears. *Surg Gynecol Obstet* 1982;154(05):667–672
- 16 Constant CR, Murley AH. A clinical method of functional assessment of the shoulder. *Clin Orthop Relat Res* 1987;(214):160–164
- 17 Amstutz HC, Sew Hoy AL, Clarke IC. UCLA anatomic total shoulder arthroplasty. *Clin Orthop Relat Res* 1981;(155):7–20
- 18 Boehm D. Valuation of the Constant score. In: Habermeyer P, Magošch P, Lichtenberg S, eds. *Classifications and scores of the shoulder*. Heidelberg: Springer; 2006:204
- 19 Ellman H, Hunker G, Bayer M. Repair of the rotator cuff. End-result study of factors influencing reconstruction. *J Bone Joint Surg Am* 1986;68(08):1136–1144
- 20 Galatz LM, Griggs S, Cameron BD, Iannotti JP. Prospective longitudinal analysis of postoperative shoulder function : a ten-year follow-up study of full-thickness rotator cuff tears. *J Bone Joint Surg Am* 2001;83(07):1052–1056
- 21 Miyazaki AN, Santos PD, da Silva LA, do Val Sella G, Checchia SL, Yonamine AM. Os bons resultados funcionais do reparo artroscópico das lesões extensas do manguito rotador mantêm-se em longo prazo? *Rev Bras Ortop* 2015;51(01):40–44
- 22 Paxton ES, Teefey SA, Dahiya N, Keener JD, Yamaguchi K, Galatz LM. Clinical and radiographic outcomes of failed repairs of large or massive rotator cuff tears: minimum ten-year follow-up. *J Bone Joint Surg Am* 2013;95(07):627–632
- 23 Miškulin M, Vrgoč G, Sporiš G, Dulic O, Gavrilovic G, Milanović Z. Single-row arthroscopic cuff repair with double-loaded anchors provides good shoulder function in long-term follow-up. *Int Orthop* 2015;39(02):233–240
- 24 Wolf EM, Pennington WT, Agrawal V. Arthroscopic rotator cuff repair: 4- to 10-year results. *Arthroscopy* 2004;20(01):5–12
- 25 Nové-Josserand L, Collin P, Godenèche A, Walch G, Meyer N, Kempf JF; SOFCOT. Ten-year clinical and anatomic follow-up after repair of anterosuperior rotator cuff tears: influence of the subscapularis. *J Shoulder Elbow Surg* 2017;26(10):1826–1833
- 26 Kluger R, Bock P, Mittlböck M, Krampla W, Engel A. Long-term survivorship of rotator cuff repairs using ultrasound and magnetic resonance imaging analysis. *Am J Sports Med* 2011;39(10):2071–2081
- 27 DeFranco MJ, Bershadsky B, Ciccone J, Yum JK, Iannotti JP. Functional outcome of arthroscopic rotator cuff repairs: a correlation of anatomic and clinical results. *J Shoulder Elbow Surg* 2007;16(06):759–765
- 28 Sugaya H, Maeda K, Matsuki K, Moriishi J. Functional and structural outcome after arthroscopic full-thickness rotator cuff repair: single-row versus dual-row fixation. *Arthroscopy* 2005;21(11):1307–1316