



Case Report

Surgical features of Trevor's disease of the patella ☆,☆☆



Frederico Barra de Moraes*, **Geraldo dos Passos Barcelos Filho**,
Guilherme Felipe Faria Lobo, **Cícero Almeida Santos**, **Luiz Augusto Alves Reis**,
Mauro Rodrigues dos Santos

Faculdade de Medicina da Universidade Federal de Goiás, Goiânia, GO, Brazil

ARTICLE INFO

Article history:

Received 1 May 2013

Accepted 6 March 2014

Available online 12 July 2014

Keywords:

Osteochondrodysplasia

Bone neoplasia

Knee

ABSTRACT

The aim of this study was to describe surgical features of resection of hemimelic epiphyseal dysplasia of the patella. We already described the clinical and imaging features in another article. The patient was a six-year-old boy with a tumor in his right knee measuring 12 cm longitudinally and 6 cm transversally, which was adhering to the patella and had been slowly growing for two years. Biopsy findings were suggestive of a benign osteochondromatous lesion, without a defined diagnosis. Imaging examinations such as radiography and tomography showed areas of bone formation and radiotransparent areas, while magnetic resonance imaging showed areas of hypo and hypersignal in T1 and T2, of estimated size 8.5 cm longitudinally and 6 cm transversally. The tumor growth was surgically resected and curettage was performed on the epiphyseal nucleus of ossification of the upper and medial centers of the patella, with good patellar remodeling and normal development. The patient did not present any recurrence of the lesion up to the time of reaching skeletal maturity.

© 2014 Sociedade Brasileira de Ortopedia e Traumatologia. Published by Elsevier Editora Ltda. All rights reserved.

Palavras-chave:

Osteocondrodismplasias

Neoplasias ósseas

Joelho

Aspectos cirúrgicos na doença de Trevor da patela

RESUMO

Descrever aspectos cirúrgicos da ressecção de displasia epifisária hemimélica da patela. Os aspectos clínicos e de imagem já foram descritos em outro artigo. Paciente masculino, seis anos, com tumor de crescimento lento em joelho direito, por dois anos, com dimensões de 12 cm no eixo longitudinal e 6 cm no transversal, aderido à patela. Biópsia sugeriu lesão osteocondromatosa benigna, sem diagnóstico definido. Exames de imagem, como radiografias e tomografias, com áreas de formação óssea e áreas radiotransparentes e na ressonância magnética áreas de hipo e hiperssinal em T1 e T2, de tamanho estimado em 8,5 cm no eixo longitudinal e 6 cm no transversal. Foram feitas ressecção cirúrgica da

* Please cite this article as: de Moraes FB, Filho GPB, Lobo GFF, Santos CA, Reis LAA, dos Santos MR. Aspectos cirúrgicos na doença de Trevor da patela. Rev Bras Ortop. 2014;49:414-419.

** Work performed in the Department of Orthopedics and Traumatology of the School of Medicine, Federal University of Goiás, Goiânia, GO, Brazil.

* Corresponding author.

E-mail: frederico.barra@yahoo.com.br (F.B. de Moraes).

<http://dx.doi.org/10.1016/j.rboe.2014.06.002>

2255-4971/© 2014 Sociedade Brasileira de Ortopedia e Traumatologia. Published by Elsevier Editora Ltda. All rights reserved.

tumoração e curetagem do núcleo de ossificação epifisário do polo superior e medial da patela, com boa remodelação patelar e desenvolvimento normal. Paciente não apresentou recidiva da lesão até o término da maturidade esquelética.

© 2014 Sociedade Brasileira de Ortopedia e Traumatologia. Publicado por Elsevier Editora Ltda. Todos os direitos reservados.

Introduction

Hemimelic epiphyseal dysplasia is a very rare disease of epiphyseal osteocartilaginous development that occurs during children's growth. It was first described by Mouchet and Belot¹ in 1926, with the name tarsomegaly, because of the increased volume in the region of the ankle, and then by Trevor² in 1950, as tarsoepiphyseal aklasia, since the lesions frequently occurred in the epiphyseal region of the foot and ankle. In 1956, Fairbank³ reported further cases and described this condition as hemimelic epiphyseal dysplasia (HED), since it could occur in other joints. The first case of HED originating in the patella was only described in 1980, in Spain, by Enriquez et al.⁴

In 2003, we operated on a similar case at the Knee Surgery Service of the Department of Orthopedics and Traumatology, School of Medicine, Federal University of Goiás. The clinical and imaging characteristics of this case were published by Araújo et al. in 2006,⁵ but the surgical aspects of the case were not addressed. The treatment for HED generally consists of resection of the lesion in order to avoid pain and limitations on joint movements, and deformities that could generate a condition of early osteoarthritis. The objective of the present study was to report on the surgical aspects of that case of HED of the patella.

Case report

The patient was a six-year-old male with a history of slowly growing but progressive tumor formation in his right knee over a two-year period. The tumor measured approximately 12 cm longitudinally and 6 cm transversally and was adhering to the patella. It was associated with a condition of pain, edema, claudication, moderate hypotrophy of the quadriceps and movement limitation, such that flexion-extension was limited over its last 30°. Mild joint effusion was present, without pain on palpation of the metaphysis. The patient was not feverish and in a good general state, without redness or secretions at the site. A biopsy suggested that this was a benign osteochondromatous lesion, without a defined diagnosis (Fig. 1).

Over two years of evolution of this lesion in the right knee, there was a large increase in the patellar tumor mass on imaging examinations, with areas of bone formation and radiopaque area. The estimated size of the tumor was 8.5 cm longitudinally, 6 cm transversally and 3.5 cm in depth (Figs. 2 and 3).

The surgical procedure was started with the patient in dorsal decubitus under general anesthesia, with asepsis, sterile fields and a pneumatic tourniquet applied to the right thigh.

The procedure took 1 h, without interurrences, and was performed in the following sequence:

1. A longitudinal lateral parapatellar incision of approximately 10 cm was made, with dissection in layers (Fig. 4A).
2. The suprapatellar quadriceps tendon was pushed back to the lateral region of the knee, together with the vastus medialis muscle, which was found to have bulged out due to the tumor formation (Fig. 4B).
3. Medial capsulotomy was performed as far as the plane of the tumor. A superficial cartilaginous cover and bone pedicle were observed at the upper and medial center of the patella, and these were resected (Figs. 4C and 5A).
4. Surgical cleaning was performed, with curettage of the nucleus of epiphyseal ossification at the upper and medial center of the patella, in order to avoid recurrence of the lesion (Fig. 5B and C).
5. Hemostasis, capsulorrhaphy, reinsertion of the quadriceps tendon in the patella, suturing in layers, skin suturing, application of dressings and immobilization were performed.

The patient continued to be followed up at our service, and the condition of HED was seen to become clinically and radiologically resolved, without any recurrence of the lesion and without any deficit of functioning of the knee extensor mechanism up to the end of the skeletal maturation process. The patient returned to his normal activities (Figs. 6 and 7).

Discussion

HED is a disease of unknown etiology that is generally restricted to the medial or lateral side of the affected limb and which ceases to evolve further when skeletal maturity is reached. In the case reported here, it was found on the medial line of the limb, since it originated at the upper and medial center of the patella of the right knee. HED occurs more frequently among males, with proportions of three male cases to each female case. It generally arises in children or adolescents between the ages of 2 and 14 years, and it is only rarely diagnosed at older ages. Its estimated incidence is one case in every one million individuals, but fewer than 300 cases have been described in the literature.^{6,7}

It can be presented in the following forms: localized (solitary); classical (more than one lesion in the same joint); or general (more than one joint in the same limb). The most commonly affected locations are the tarsal bones (foot and ankle), which account for 50% of all the lesions, followed by the knee (distal femur and proximal tibia), pelvic belt (hip), scapular belt (shoulder) and carpal bones (wrist).^{8,9} The case in question

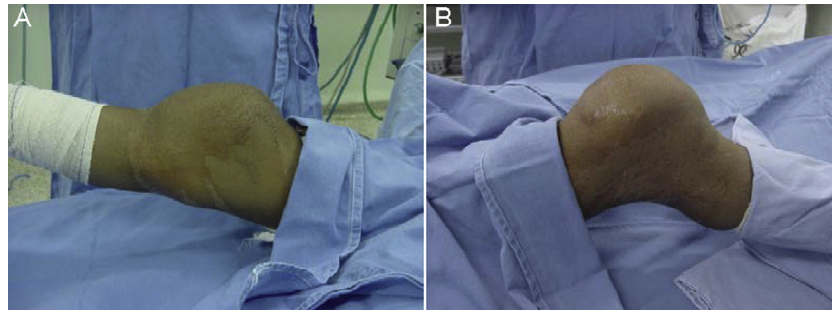


Fig. 1 – Preoperative appearance, with medial view (A) and lateral view (B) of the right knee with patellar tumor formation: hemimelic epiphyseal dysplasia.

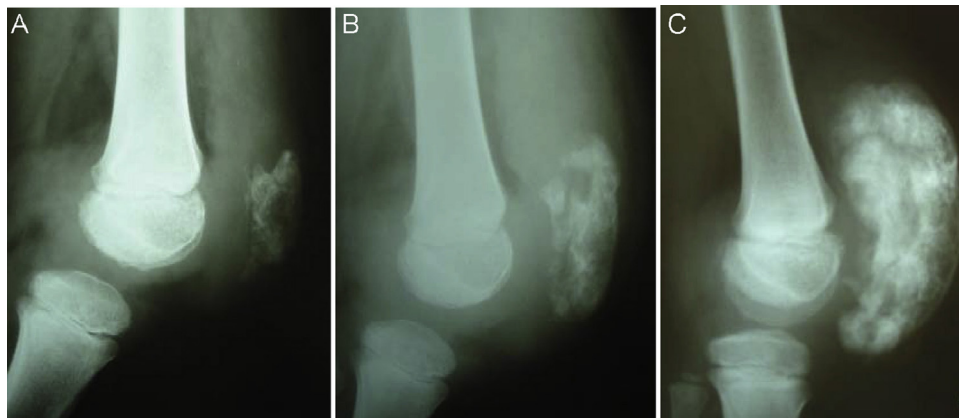


Fig. 2 – Preoperative appearance on lateral radiographs of the right knee, with patellar tumor formation showing one month of evolution (A), one year (B) and immediately before the surgery (C): hemimelic epiphyseal dysplasia.

presented an unusual location, originating at the upper center of the patella, and its clinical and imaging characteristics were described previously.⁵

Tumors originating from the patella are rare; 70% of them are benign and they need to be approached from the clinical, imaging, surgical and histological points of view for these cases to be concluded in the best way possible. The report presented showed that biopsy prior to surgery revealed a benign osteocartilaginous lesion, but without a final definition. The

differential diagnosis in relation to HED should be made with several other types of tumor, including: osteochondroma, chondroblastoma, intracapsular chondroma, giant-cell tumor, tumoral calcinosis and synovial chondromatosis; and also with non-tumoral lesions such as: ossifying myositis, vascular or parasitic calcification, tuberculosis and neurological syndromes (CINCA or Charcot).¹⁰⁻¹²

Imaging examinations (radiographs, computed tomography scans and magnetic resonance imaging) may suggest the

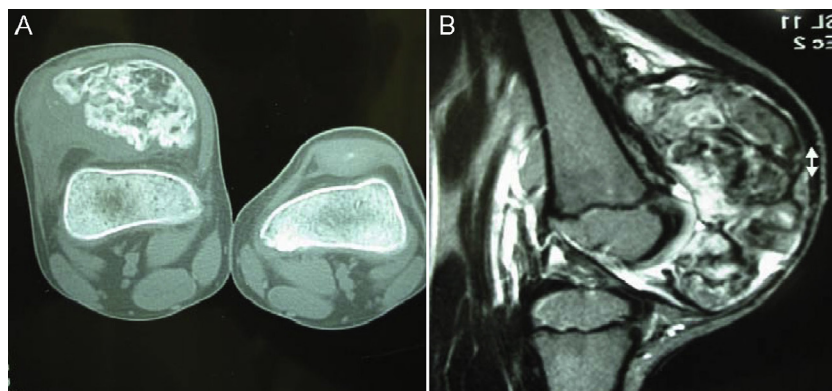


Fig. 3 – Preoperative appearance on axial computed tomography slice (A) and on T2-weighted sagittal magnetic resonance slice (B) of the right knee with voluminous patellar tumor formation, immediately before surgery: hemimelic epiphyseal dysplasia.

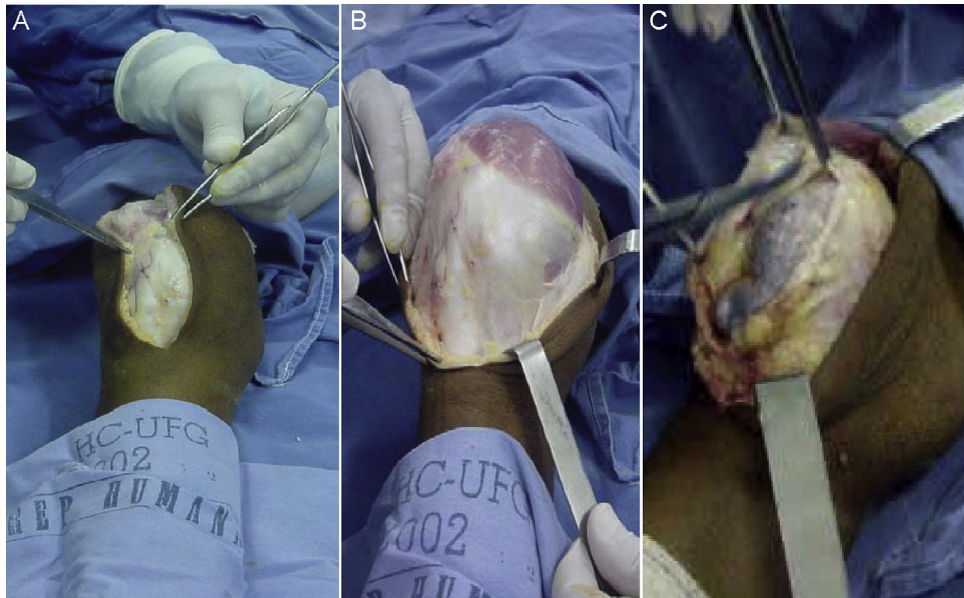


Fig. 4 – Intraoperative appearance of the resection of the patellar tumor formation (hemimelic epiphyseal dysplasia), showing lateral longitudinal parapatellar incision (A), dissection at muscle-tendon layer (B) and intracapsular layer (C).

diagnosis of HED, especially in the usual regions such as the foot and ankle. However, when the lesion is in an unusual location, such as the patella, this becomes more difficult. The nucleus of epiphyseal ossification of the patella appears around the age of four to five years in males and at the age of three years in females.^{13,14}

The treatment for HED can be clinical or surgical, depending on the symptoms. There is no single guideline regarding the treatment, but most authors have reported resecting the lesion, which shows that observation is only for asymptomatic cases. Clinical treatment is less invasive, and does

not have the risks of surgery. Nevertheless, surgical treatment produces better results in the following situations: (1) compression of nerves, arteries or tendons; (2) exostosis that interferes with growth of the extremity; (3) functional limitations of the joint; and (4) deformities and pain. The tumor growth is generally aggressive and so the treatment should also be aggressive; moreover, this approach is taken in order to avoid pain, deformities, limitations and early osteoarthritis. Recurrence is common after simple excision of the tumor. Extracapsular cases present better results than intracapsular cases.¹⁵⁻¹⁷

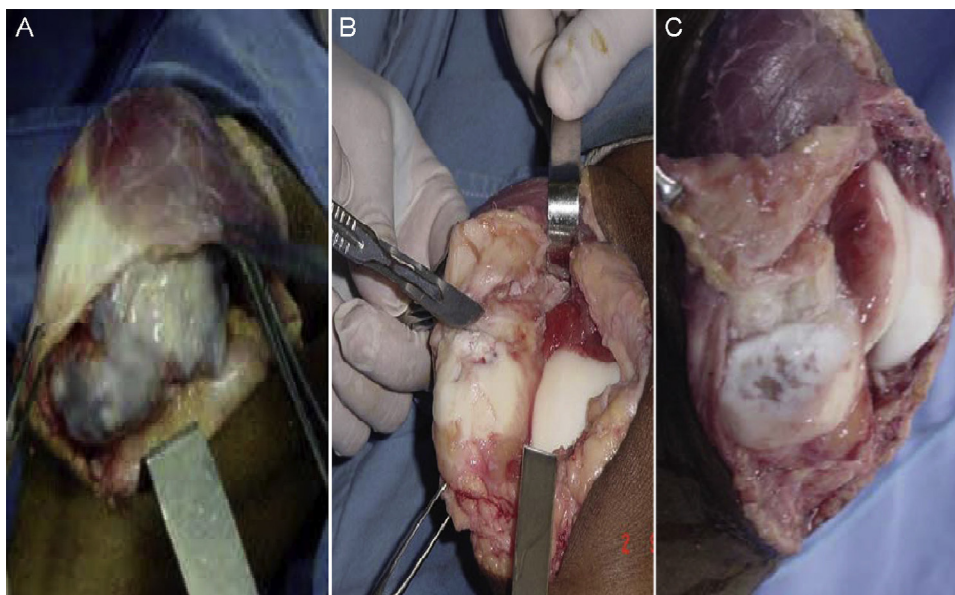


Fig. 5 – Intraoperative appearance of the resection of the patellar tumor formation (hemimelic epiphyseal dysplasia), showing excision of the pedunculate voluminous mass with osteocartilaginous characteristics (A), surgical removal of the nucleus of ossification that originated the dysplasia (B), curettage and final cleaning of the upper center of the patella (C).

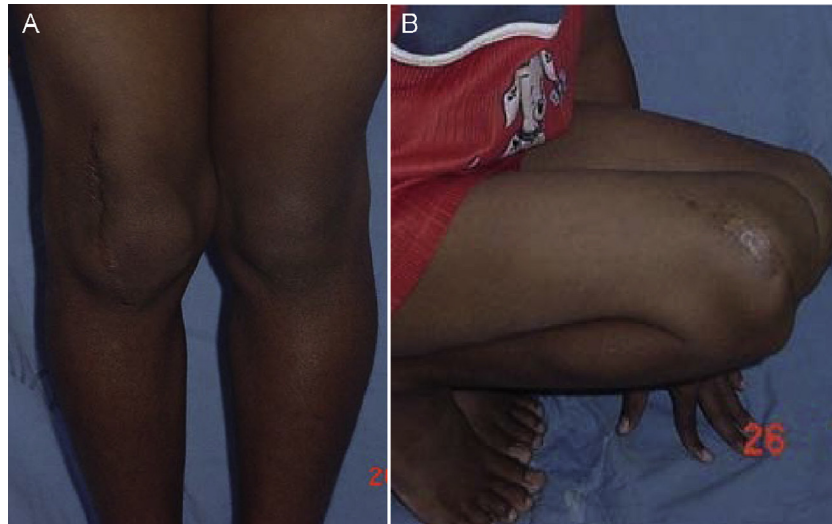

Fig. 6 – Appearance one year after the operation, with anterior view (A) and lateral view (B) of the right knee, with full extension and flexion: hemimelic epiphyseal dysplasia.

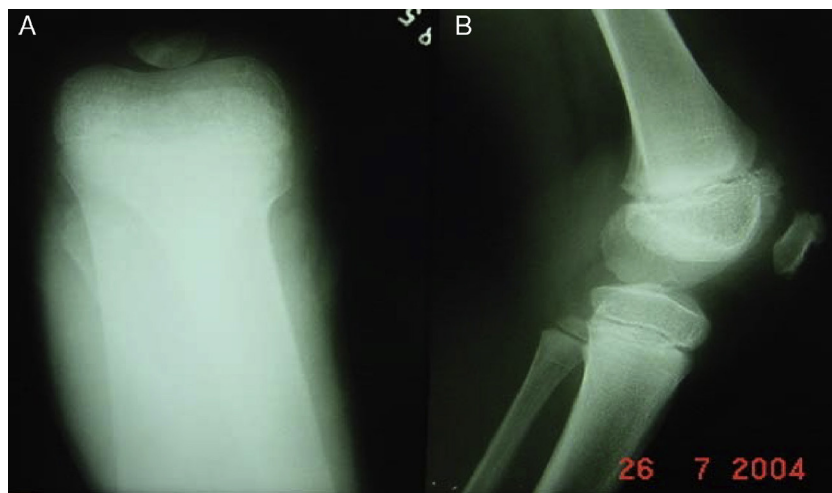


Fig. 7 – Appearance one year after the operation, on radiographs of the right knee in axial view (A) and lateral view (B), showing adequate growth of the patella.

Regarding the possible types of surgery for such cases, these can be divided into four types, according to the aggressiveness of the tumor. The first type is arthroscopic resection, which presents least morbidity but has a greater chance of recurrence and has greater technical difficulty in children. Open resection of the tumor formation enables a larger surgical field and should always be accompanied by curettage of the compromised nucleus of ossification, in order to reduce the recurrence rate. Surgical procedures of greater aggressiveness, such as hemipatellectomy and total patellectomy can be performed in order to avoid lesion recurrence and early osteoarthritis, but imply loss of the potency of function of the knee extensor mechanism and, because this is in a child, hypoplasia of the femoral condyles.^{4,10,17}

Our patient presented a very voluminous lesion, which was resected using an open procedure, at its pedicle. To avoid

recurrence of tumor formation, we performed surgical cleaning and curettage of the nucleus of epiphyseal ossification of the upper center of the patella. The risk of this procedure is that the patella may develop abnormally. However, what we observed was good remodeling of the patella and normal development, probably because of the patient's young age and the potential of his immature skeleton, with continual stimulation of the knee extensor mechanism, given that the patella is a sesamoid bone and functions as a pulley. Our patient did not present any recurrence up to the time of completing his skeletal maturation.

Conflicts of interest

The authors declare no conflicts of interest.

REFERENCES

1. Mouchet A, Belot J. La tarsomégalie. *J Radiol Électrol.* 1926;10:289-93.
2. Trevor D. Tarso-epiphysialaqlasis. A congenital error of epiphysial development. *J Bone Joint Surg Br.* 1950;32(2):204-13.
3. Fairbank TJ. Dysplasia epiphysealis hemimelica (tarso-epiphysial acalasis). *J Bone Joint Surg Br.* 1956;38(1):237-57.
4. Enriquez J, Quiles M, Torres C. A unique case of dysplasia epiphysealis hemimelica of the patella. *Clin Orthop Relat Res.* 1981;(160):168-71.
5. Araujo Jr CR, Montandon S, Montandon C, Teixeira KI, Moraes FB, Moreira MA. Best cases from the AFIP: dysplasia epiphysealis hemimelica of the patella. *Radiographics.* 2006;26(2):581-6.
6. Wynne-Davis R, Hall CM, Apley AG. Dysplasia epiphysealis hemimelica. In: Wynne-Davis R, Hall CM, Apley AG, editors. *Atlas of skeletal dysplasias.* New York: Churchill Livingstone; 1985. p. 539-43.
7. Kircher J, Westhoff B, Bittersohl B, Ziskoven C, Krauspe R. A rare case of Trevor's disease (dysplasia epiphysealis hemimelica) in the elbow. *J Shoulder Elbow Surg.* 2013;22(2):e12-5.
8. Azouz EM, Slomic AM, Marton D, Rigault P, Finidori G. The variable manifestations of dysplasia epiphysealis hemimelica. *Pediatr Radiol.* 1985;15(1):44-9.
9. Lamesch AJ. Dysplasia epiphysealis hemimelica of the carpal bones. Report of a case and review of the literature. *J Bone Joint Surg Am.* 1983;65(3):398-400.
10. Mercuri M, Casadei R. Patellar tumors. *Clin Orthop Relat Res.* 2001;(389):35-46.
11. Silverman FN. Dysplasia epiphysealis hemimelica. *Semin Roentgenol.* 1989;24(4):246-58.
12. Lang IM, Azouz EM. MRI appearances of dysplasia epiphysealis hemimelica of the knee. *Skeletal Radiol.* 1997;26(4):226-9.
13. Peduto AJ, Frawley KJ, Bellemore MC, Kuo RS, Foster SL, Onikul E. MR imaging of dysplasia epiphysealis hemimelica: bony and soft-tissue abnormalities. *Am J Roentgenol.* 1999;172(3):819-23.
14. Lin YH, Chou YJ, Yeh LR, Chen CKH, Pan HB, Yang CF. Dysplasia epiphysealis hemimelica or Trevor's disease: a case report. *Chin J Radiol.* 2001;26(5):215-20.
15. Keret D, Spatz DK, Caro PA, Mason DE. Dysplasia epiphysealis hemimelica: diagnosis and treatment. *J Pediatr Orthop.* 1992;12(3):365-72.
16. Strujis PA, Kerkhoffs GM, Besselaar PP. Treatment of dysplasia epiphysealis hemimelica: a systematic review of published reports and a report of seven patients. *J Foot Ankle Surg.* 2012;51(5):620-6.
17. Luevitoonvachkij S, Khunsree S, Sirirungruangsam Y, Settakorn J. Dysplasia epiphysealis hemimelica: a huge articular mass with unpredictable surgical results. *BMJ Case Rep.* 2012;7:259.