



Original Article

The effects of ethyl-2-cyanoacrylate and butyl-2-cyanoacrylate in the process of bone healing in rats. A controlled experimental study[☆]



Evandro Pereira Palacio^{a,*}, Gilberto José Cação Pereira^a,
Paulo Roberto de Almeida Silveiras^a, Gabriel Guimarães Di Stasi^b,
Caio de Andrade Staut^b, Trajano Sardenberg^a

^a Departamento de Cirurgia e Ortopedia, Faculdade de Medicina de Botucatu, Universidade Estadual Paulista (UNESP), Botucatu, SP, Brazil

^b Faculdade de Medicina de Marília, Marília, SP, Brazil

ARTICLE INFO

Article history:

Received 17 October 2016

Accepted 23 December 2016

Available online 6 December 2017

Keywords:

Cyanoacrylates

Tissue adhesives

Fractures, bones

Fracture healing

ABSTRACT

Objective: Synthetic adhesives are used by various medical specialties, especially in surgery; however, studies reporting their use in orthopedic practice are scarce. The aim of this study was to compare the results in using ethyl-2-cyanoacrylate or butyl-2-cyanoacrylate in the treatment of fractures in rats.

Methods: This was an experimental prospective controlled study in 90 rats, with humerus, femur, and tibia fractures, treated with ethyl-2-cyanoacrylate (SB group; $n=45$) or butyl-2-cyanoacrylate (HA group; $n=45$). Biomechanical and histomorphometric analyses were performed at three different moments (60, 120, and 180 days); besides a clinical study performed weekly by measurement of the animals body mass.

Results: No differences were observed regarding body mass ($p=0.07$). In both groups, there were no significant differences regarding maximum load ($p=0.6$), yield point strength ($p=0.6$), and stiffness coefficient ($p=0.4$) of the femurs. The same was observed in tibias for maximum load ($p=0.4$), yield point strength ($p=0.7$), and stiffness coefficient ($p=0.6$). The humerus from both groups had similar bone callus area ($p=0.66$). In both groups, there were no statistical differences related to inflammatory cells ($p=0.4$), osteoblasts ($p=0.2$), and osteoclasts ($p=0.2$).

Conclusion: Ethyl-2-cyanoacrylate was more effective than butyl-2-cyanoacrylate in the treatment of fractures in rats.

© 2017 Sociedade Brasileira de Ortopedia e Traumatologia. Published by Elsevier Editora Ltda. This is an open access article under the CC BY-NC-ND license (<http://creativecommons.org/licenses/by-nc-nd/4.0/>).

[☆] Study conducted at the Departamento de Cirurgia e Ortopedia, Faculdade de Medicina de Botucatu (UNESP), Botucatu, SP, Brazil.

* Corresponding author.

E-mail: palacio@fmb.unesp.br (E.P. Palacio).

<https://doi.org/10.1016/j.rboe.2017.11.010>

2255-4971/© 2017 Sociedade Brasileira de Ortopedia e Traumatologia. Published by Elsevier Editora Ltda. This is an open access article under the CC BY-NC-ND license (<http://creativecommons.org/licenses/by-nc-nd/4.0/>).

Efeitos do etil-2-cianoacrilato e do butil-2-cianoacrilato no processo de consolidação óssea em ratos. Estudo experimental controlado

R E S U M O

Palavras-chave:

Cianoacrilatos
Adesivos teciduais
Fraturas ósseas
Consolidação da fratura

Objetivo: Os adesivos sintéticos são usados em várias especialidades médicas cirúrgicas, contudo, os estudos que relatam seu uso na prática ortopédica são escassos. O objetivo deste trabalho foi comparar os resultados do uso do etil-2-cianoacrilato e do butil-2-cianoacrilato no tratamento de fraturas em ratos.

Métodos: Foi realizado um estudo experimental, prospectivo e controlado em 90 ratos com fraturas de úmero, fêmur e tibia, tratados com etil-2-cianoacrilato (grupo SB; n=45) ou butil-2-cianoacrilato (grupo HA; n=45). Foram realizadas análises biomecânicas e histomorfométricas em três momentos (60, 120 e 180 dias), além do estudo clínico pela aferição semanal da massa corporal dos animais.

Resultados: Não foram observadas diferenças relacionadas à massa corporal dos animais ($p=0,07$). Os fêmures de ambos os grupos não apresentaram diferença com relação à carga máxima ($p=0,6$), limite de elasticidade ($p=0,6$) e coeficiente de rigidez ($p=0,4$). Analisando-se as tíbias, o mesmo foi observado com relação à carga máxima ($p=0,4$), ao limite de elasticidade ($p=0,7$) e ao coeficiente de rigidez ($p=0,6$). Os úmeros de ambos os grupos apresentaram a mesma área de calo ósseo formado ($p=0,66$). Em ambos os grupos, não houve diferença estatística relacionada ao número de osteoblastos ($p=0,2$), osteoclastos ($p=0,2$) e células inflamatórias ($p=0,4$).

Conclusão: O etil-2-cianoacrilato foi mais eficaz do que o butil-2-cianoacrilato no tratamento de fraturas em ratos.

© 2017 Sociedade Brasileira de Ortopedia e Traumatologia. Publicado por Elsevier Editora Ltda. Este é um artigo Open Access sob uma licença CC BY-NC-ND (<http://creativecommons.org/licenses/by-nc-nd/4.0/>).

Introduction

The use of synthetic adhesives in medical practice has drawn the attention of researchers worldwide. The ideal adhesive should have the following essential characteristics: fast adhesion to the tissue, low heat release, good adhesion even in an internal human environment, the ability to be sterilized and, especially, it should not have carcinogenic potential.¹

In medicine, cyanoacrylates are well known for their bactericidal characteristics.² De Almeida Manzano et al.³ reported the effective antimicrobial action of ethyl-2-cyanoacrylate against *Staphylococcus*, *Streptococcus*, *Escherichia coli*, and *Escherichia faecalis* strains. Shamiyeh et al.⁴ and Coulthard et al.⁵ did not observe any increase in infection rates after the use of cyanoacrylates. Regarding histotoxicity, several authors⁶⁻¹³ have analyzed the inflammatory and carcinogenic effects of these adhesives, finding few or no deleterious effects to the human body.

The medical literature leaves no doubt as to the safety and efficacy of the use of these adhesives. However, there are few reports¹⁴⁻¹⁷ on their use in the treatment of bone lesions.

In the case of intra-articular fractures, it is agreed that fixation must be anatomical. With the exception of large bones (femur, humerus, tibia, etc.), which must be reconstructed with the aid of metal implants, there is a great debate on the best treatment option for small and tubular bones.

Thus, considering the lack of publications on the subject in the various databases available, the possibility of opening new lines of research and, primarily, the goal of reducing financial costs, sequelae, and hospitalization time, this study is aimed

at comparing the results of the use of ethyl-2-cyanoacrylate to butyl-2-cyanoacrylate in the treatment of fractures in rats.

Material and methods

All procedures were approved by the Ethics Committee on Animal Use of this institution under No. 1495/2014.

The sample size was determined prior to the start of the study, considering the α -risk (0.5%) and β -risk (80%), and the range of the variables, reaching a total of ten animals per group.

Ninety male Wistar rats (*Rattus norvegicus albinus*) were used. At the beginning of the study, the rats were 60-days-old and, after being clinically evaluated and weighed, were housed in polypropylene cages, in an environment with a controlled temperature of 22 °C and a light-dark cycle of 12 h. Rodent feed and water were offered *ad libitum*.

The animals were randomly selected by the process of opaque and sealed envelopes^{18,19} into two groups: Group SB (n=45) and Group HA (n=45).

Osteotomies were performed after intraperitoneal anesthesia (30 mg/kg of sodium pentobarbital 3%) and bilateral trichotomy along the humerus, femur, and tibia. Subsequently, the animals underwent regional asepsis with soap and water, followed by antiseptics with 0.2% chlorhexidine aqueous solution, and then were placed on a surgical table in the lateral decubitus position.

After fenestrated sterile drapes were placed, longitudinal incisions were made in the skin between the shoulder and

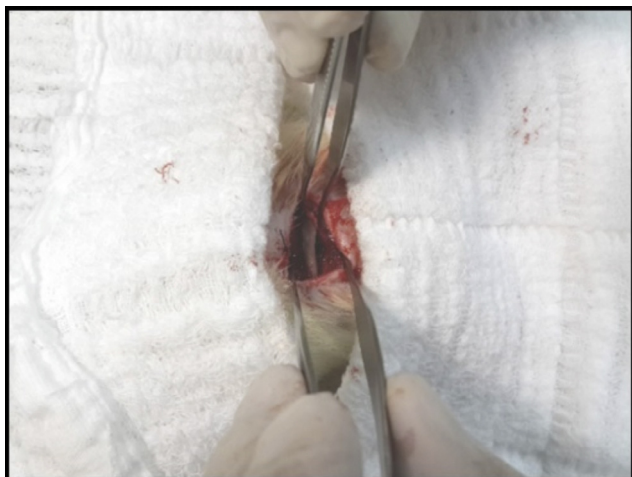

Fig. 1 – Dissection and exposure of the femur prior to osteotomy.

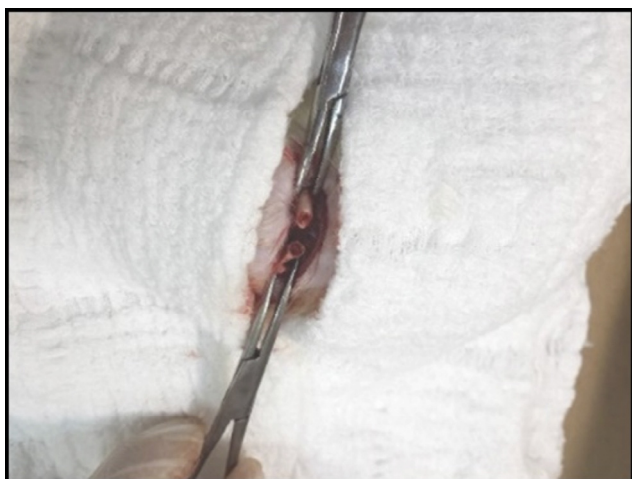

Fig. 2 – Femoral osteotomy.

elbow joints (for access to the humerus), between the hip and knee (for access to the femur), and between the knee and ankle (for access to the tibia).

The bones were exposed, passing through the muscle layers, allowing access to them (Fig. 1). Bone osteotomy was then performed in diaphyseal regions (Fig. 2), under continuous manual irrigation with 0.9% saline solution.

The osteotomies on the right side were treated with two drops of colorless ethyl-2-cyanoacrylate or butyl-2-cyanoacrylate, placed directly between the osteotomized ends. The osteotomies on the left side were treated without any exogenous substance, serving as controls. Muscle and skin were sutured with Mononylon* 3-0 (Ethicon®). After the surgical procedures, the animals were kept in confinement, receiving 0.1 mL of sodium dipyrone every 6 h, for 36 h.

Throughout the study period, the animals were weighed weekly.

The animals were euthanized in three moments: 60, 120, and 180 postoperative days, when 15 animals from each group were euthanized with a lethal intraperitoneal dose of 80 mg/kg of sodium pentobarbital 3%. The right and left humeri, femurs

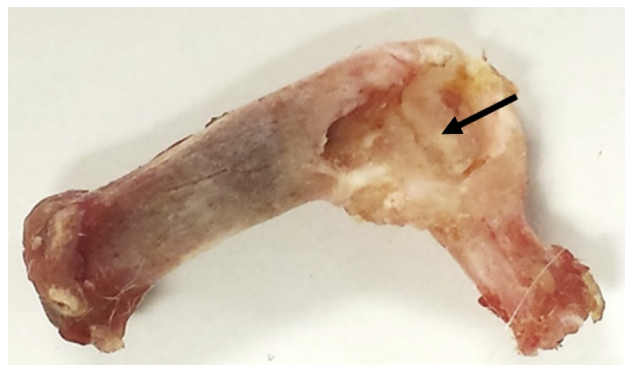


Fig. 3 – Tibia from the HA group with abscess region (arrow).

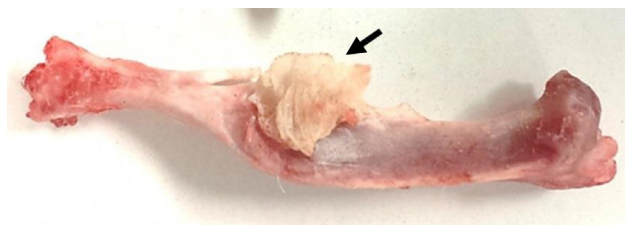


Fig. 4 – Tibia from the SB group with adhesive extrusion (arrow).

and tibiae were disarticulated and cleansed of all soft tissue (Figs. 3 and 4).

The anatomical pieces were wrapped in gauze soaked in 0.9% saline, then wrapped in aluminum foil, labeled, and immediately sent for biomechanical and histomorphometric assays.

Body mass analysis

Measurements were made weekly, preferably on the same day of the week, using a portable electronic scale, with a capacity of $600 \text{ g} \times 0.01 \text{ g}$.

Biomechanical analysis

The biomechanical tests were performed using an EMIC® universal testing machine, model DL 10,000, with accuracy of $\pm(0.018 + F/3700) \text{ kN}$, conforming to the specifications of the following standards: ABNT NBR NM ISO 7500-1: 2004 (Corrected Version: 2004) and ABNT NBR ISO 376: 2012 (Corrected Version: 2013).

Axial compression tests were performed on the femurs: the femoral distal ends were fixated vertically in 35 mL plastic containers with 30 mL of self-polymerizing acrylic resin (Jet®). The cleaver of the testing machine, its end being concave, was positioned at the head of the femur, fitting it perfectly.

Once the test was initiated, the cleaver was set at a speed of 30 mm/min to the breaking point of the test piece, at which point the Mtest® program automatically stopped the test and provided the final results through a “load vs. deformation” diagram (Fig. 5).

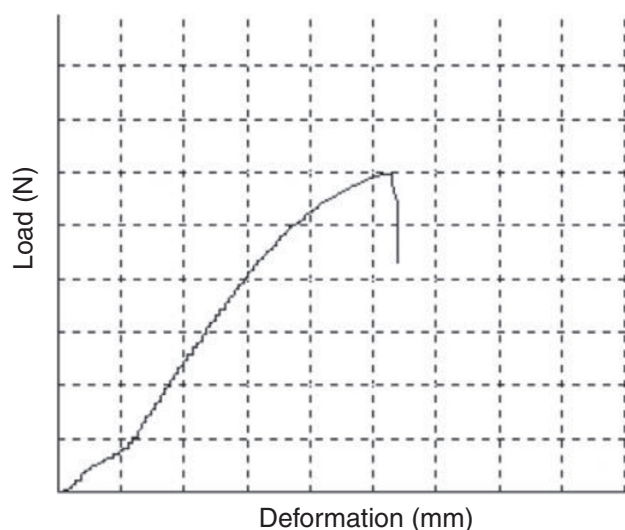


Fig. 5 – Diagram of load vs. deformation.

The same procedures were adopted for the tibiae, but three-point flexion tests were conducted: the tibiae were positioned horizontally, supported at their extremities. The distance between the support points was standardized as two-thirds of the length of the test piece. The cleaver delivered a load perpendicular to the bone diaphysis.

The following variables were studied both in the femurs and tibiae: yield point strength (N), maximum supported load (N), and stiffness coefficient (N/mm).

Histomorphometric analysis

The humerus slides were prepared with hematoxylin-eosin (HE) staining, so as to provide longitudinal cuts of the area of interest (bone callus).²⁰

In the histological analysis, the following variables were studied: number of osteoclasts per mm² (n⁻¹), number of osteoblasts per mm² (n⁻¹), and number of anomalous cells (tumor or inflammatory) per mm² (n⁻¹).

For the morphometric analysis, the slides were placed under a microscope (Laica[®]) coupled to a video monitor with a resolution of 1024 × 768 pixels, which sent the digital images to a computer. The area (μm²) of neoformed bone was calculated with the Image Pro Plus imaging program (Media Cybernetics, Silver Spring, MD, United States).

Statistical analysis

The statistical analysis was performed by analysis of variance, in a completely randomized model, complemented

by respective multiple comparison tests, using the software SigmaStat[®], version 3.5.1.2 (Systat Software, Inc., Germany, 2006) and Minitab[®], version 17.3.1 (Minitab Inc., 2016).

In all applied tests, the level of significance was set at 95% ($p < 0.05$).

The results of the statistical procedures were presented as tables and graphs, with descriptive measures of central tendency (mean) and variability (standard deviation) and their respective significance.

Results

Throughout the experiment, the animals were examined daily; no clinical or behavioral changes were observed.

Regarding the body mass of the animals, no statistical difference related to the adhesive used was observed throughout the experiment ($p = 0.07$; Table 1).

Regarding the maximum load, the analysis of variances demonstrated that the femurs of the SB group supported an axial load equal to that of the femurs of the HA group ($p = 0.6$); the same was observed for the yield point strength ($p = 0.6$) and the stiffness coefficient ($p = 0.4$; Table 2).

In the case of the three-point flexion tests, the study of the variances showed that the tibiae of the SB group supported a maximum load equal to that of the tibiae in the HA group ($p = 0.4$); the same was observed for the yield point strength ($p = 0.7$) and the stiffness coefficient ($p = 0.6$; Table 3).

Regarding the area of bone callus formation, the statistical analysis demonstrated that the humeri from the SB group had the same neoformed bone area as those from the HA group ($p = 0.66$; Table 4).

The results of the statistical analysis of the cellularity, shown in Table 5, demonstrated that the concentration of osteoblasts found in the bones of the SB group was the same as in the HA group ($p = 0.2$); the same was observed for osteoclast concentration ($p = 0.2$) and for inflammatory cells ($p = 0.4$), although the results found in the latter variable were markedly higher in the HA group.

No tumor cells were identified in any of the groups.

All specimens assessed presented adhesive residue; however, in the butyl-2-cyanoacrylate group, these residues were larger in diameter. In fact, the rapid polymerization of that adhesive may originate solid nodules that act as true “foreign bodies.” These remain attached to bone tissue and adjacent musculature, perpetuating a white cell line at high levels¹⁷ (Table 5).

Discussion

Since 1940, the use of synthetic adhesives for the reconstruction of human tissues has been intensively researched.

Table 1 – Mean and standard deviation of body mass (g), according to the adhesive used and the moment of euthanasia.

Adhesive used	Moment of euthanasia		
	60 days	120 days	180 days
Ethyl-2-cyanoacrylate	204 ± 15.3	289.1 ± 23.6	330.8 ± 6.4
Butyl-2-cyanoacrylate	195.4 ± 7.2	273.5 ± 14.8	312.2 ± 21.2

Table 2 – Results of femoral tests: mean and standard deviation of the maximum load (N), yield point strength (N), and stiffness coefficient (N/mm), according to the adhesive used and the moment of euthanasia.

Studied variable	Adhesive used	Moment of euthanasia		
		60 days	120 days	180 days
Maximum load (N)	Ethyl-2-cyanoacrylate	138.7 ± 12.4	141.4 ± 13.1	153.7 ± 10.6
	Butyl-2-cyanoacrylate	112.6 ± 8.9	124.2 ± 12.2	129.8 ± 14.8
Yield point strength (N)	Ethyl-2-cyanoacrylate	119.8 ± 14.1	124.6 ± 16.8	129.7 ± 13
	Butyl-2-cyanoacrylate	105.8 ± 8.9	112.6 ± 9.2	113 ± 11.4
Stiffness coefficient (N/mm)	Ethyl-2-cyanoacrylate	171.7 ± 15.1	214.3 ± 28.2	236.2 ± 32.7
	Butyl-2-cyanoacrylate	130.1 ± 19.3	158.2 ± 11	176.4 ± 6.7

Table 3 – Results of the tibial tests: mean and standard deviation of the maximum load (N), yield point strength (N), and stiffness coefficient (N/mm), according to the adhesive used and the moment of euthanasia.

Studied variable	Adhesive used	Moment of euthanasia		
		60 days	120 days	180 days
Maximum load (N)	Ethyl-2-cyanoacrylate	124.7 ± 10.5	133.8 ± 11.3	137.5 ± 9.8
	Butyl-2-cyanoacrylate	111.4 ± 12.6	121.3 ± 16.6	125.1 ± 8.3
Yield point strength (N)	Ethyl-2-cyanoacrylate	121.5 ± 6.3	129.6 ± 10.2	132.9 ± 11.1
	Butyl-2-cyanoacrylate	108.4 ± 4.7	118.3 ± 9.8	119.8 ± 7.5
Stiffness coefficient (N/mm)	Ethyl-2-cyanoacrylate	178.1 ± 10.7	222.5 ± 17.1	229.8 ± 17.9
	Butyl-2-cyanoacrylate	144.3 ± 11.2	163.7 ± 12.9	170.4 ± 15.2

Table 4 – Mean and standard deviation of the bone callus area (μm^2), according to the adhesive used and the moment of euthanasia.

Adhesive used	Moment of euthanasia		
	60 days	120 days	180 days
Ethyl-2-cyanoacrylate	304,468 ± 72,101	334,785.2 ± 111,205	356,903.8 ± 98,003
Butyl-2-cyanoacrylate	102,448.1 ± 86,247	175,978.5 ± 144,632	195,925.4 ± 106,022

Table 5 – Mean and standard deviation of the cellularity observed (osteoblasts, osteoclasts, inflammatory cells; n^{-1}), according to the adhesive used and the moment of euthanasia.

Adhesive used	Cellularity	Moment of euthanasia		
		60 days	120 days	180 days
Ethyl-2-cyanoacrylate	Osteoblasts	251 ± 4	306 ± 23	280 ± 26
	Osteoclasts	21 ± 7	37 ± 19	28 ± 11
	Inflammatory cells	115 ± 11	299 ± 24	187 ± 25
Butyl-2-cyanoacrylate	Osteoblasts	221 ± 16	274 ± 31	255 ± 30
	Osteoclasts	19 ± 8	25 ± 11	23 ± 12
	Inflammatory cells	227 ± 12	512 ± 28	461 ± 39

Initially, the use of adhesives of biological origin was more common. However, from 1960 onwards, synthetic polymers have become a therapeutic option in all manner of medical specialties.

Among all the available adhesives, cyanoacrylates have drawn special attention from medical professionals due to their low cost and, primarily, their easy handling.

In the present study, the adhesive effect between the fractured extremities presented better results in the SB group, a fact that could be verified by the simple observation of the animals, who were able to full weight-bearing on the operated limbs immediately after the anesthetic recovery, a fact not observed in the animals from the HA groups.

In the HA group, it was observed that, once the butyl-2-cyanoacrylate was added, it polymerized almost instantaneously upon minimal contact with the bone, eliminating any possibility of repositioning the fragments or redoing a fracture reduction.

Another fact to consider is the inflammatory/infectious processes that are often associated with new products and/or surgical techniques. In the present study, a marked increase in inflammatory cellularity in the group treated with butyl-2-cyanoacrylate was observed.

In publications on synthetic adhesives, it is not common to search for tumor or carcinogenic cells. In fact, in the various databases searched, the authors were unable to retrieve

studies that provided any relevant information on the subject. In the present study, the non-observation of anomalous cells throughout the entire experiment was an exciting and unprecedented finding. However, the authors consider this to be a variable that requires more in-depth, long-term studies, with larger samples.

Regarding the biomechanical and morphometric analysis, the bones treated with ethyl-2-cyanoacrylate presented higher maximum load and yield point strength when compared with the HA groups, although this data did not present statistical significance. Such results, when associated with the increase of the bone callus area formation also observed in those groups, allow the assumption that ethyl-2-cyanoacrylate provided conditions for the bone healing process to occur without anomalies, i.e., ethyl-2-cyanoacrylate did not interfere with local osteoblastic activity.

It is important to highlight the values observed in the analysis of the stiffness coefficient. The higher value observed in the bones of the SB group may predict a greater fragility of the bone callous formed, i.e., although the bones treated with ethyl-2-cyanoacrylate were able to withstand a higher load (Tables 2 and 3), surprisingly, they were only able to withstand a little deformation, which made them more brittle. In fact, previous studies²¹⁻²³ have demonstrated the brittleness of bones with high stiffness coefficients, which is why the authors do not recommend the use of synthetic adhesives in bones that are submitted to moderate/high intensity deforming forces.

Amid the wide range of therapeutic options related to traumatology, the fact that synthetic adhesives are easy to obtain, have low cost, and present good results and easy handling makes them a feasible option in the treatment of small volume bone fractures and, especially, in the re-establishment of joint anatomy.

Conclusion

Under the conditions of the present study, ethyl-2-cyanoacrylate was more effective than butyl-2-cyanoacrylate in the treatment of fractures in rats.

Conflicts of interest

The authors declare no conflicts of interest.

Acknowledgments

To the Foundation for Research Support of the State of São Paulo (Fundação de Amparo à Pesquisa do Estado de São Paulo [Fapesp]) for the support given to the development of this research (processes: 8514-6/2014 and 8605-1/2014).

Sincere thanks to Prof. Dr. Luiz Cláudio Di Stasi, Adjunct Professor of the Department of Pharmacology of the Institute of Biosciences (Unesp/Botucatu), without whom this study would not have been possible.

REFERENCES

- Allen JG, Beal JM, Creech O Jr, Hanlon CR, Judd ES, Russell PS, et al. Toxicity of cyanoacrylates. *Arch Surg.* 1966;93(1):34-40.
- Ardis AE. Preparation of monomeric alkyl alpha-cyanoacrylates. US Patent # 2467926. 1949. Available from: <https://www.google.com/patents/US2467926>.
- de Almeida Manzano RP, Naufal SC, Hida RY, Guarnieri LO, Nishiwaki-Dantas MC. Antibacterial analysis in vitro of ethyl-cyanoacrylate against ocular pathogens. *Cornea.* 2006;25(3):350-1.
- Shamiyeh A, Schrenk P, Stelzer T, Wayand WU. Prospective randomized blind controlled trial comparing sutures, tape, and octylcyanoacrylate tissue adhesive for skin closure after phlebectomy. *Dermatol Surg.* 2001;27(10):877-80.
- Coulthard P, Worthington H, Esposito M, Elst M, Waes OJ. Tissue adhesives for closure of surgical incisions. *Cochrane Database Syst Rev.* 2004;(2):CD004287.
- Toriumi DM, Raslan WF, Friedman M, Tardy ME. Division of facial plastic and reconstructive surgery. *Arch Otolaryngol Head Neck Surg.* 1990;116(5):546-50.
- Diaz-Barreiro PG, Servin Ramirez JF, Diaz Lopez DE. Experiencia en 10 casos de sutura cutánea usando el adhesivo etil-cianoacrilato. *Ginecol Obstet Mex.* 1995;63:10-4.
- Lehman RAW, Hayes GJ, Leonard F. Toxicity of cyanoacrylates. *Acta Surg.* 1987;93:45-8.
- Gonzalez E, Orta J, Quero C, Niemshik L, Galera R, Onay D, et al. Ethyl-2-cyanocrilate fixation of the cranial bone flap after craniotomy. *Surg Neurol.* 2000;53(3):288-9.
- Mezarobba G. Coração remendado. *Revista Veja:* Ed. Abril, 11 de março de 1998.
- Souza M, Fagundes DJ, Gomes PO, Ascensão AM, Guimarães CA, Mendonça ITM Jr, et al. Fios de sutura: uma revisão histórica. *Publ UEPG Ci Biol Saúde.* 2001;2(1):98-100.
- Anciuti AN, Felix AOC, Mueller EN, Grecco FB, Nobre MO. Avaliação da histotoxicidade e de alterações hepáticas após o uso do etil-cianoacrilato e n-butil-cianoacrilato em camundongos. In: XX Congresso de Iniciação Científica. III Mostra Científica. 2004.
- Biondo-Simões MLP, Vivi AAG, Fagundes DJ. Adesivos em anastomoses do trato digestivo. *Acta Cir Bras.* 1993;8(1):41-4.
- Borges APB, Rezende CMF, Sampaio R, Oliveira HP, Ponpermayer LG. Emprego de adesivo butil-2-cianoacrilato na fixação de esquirolas em fraturas de fêmur de cães. *Aspectos radiológicos.* *Arq Bras Med Vet Zootec.* 1992;44(1):29-41.
- Yilmaz C, Kuyurtar F. Fixation of a talar osteochondral fracture with cyanoacrylate glue. *Arthroscopy.* 2005;21(8):1009.
- Gul R, Khan F, Maher Y, O'Farrell D. Osteochondral fractures in the knee treated with butyl-2-cyanoacrylate glue. A case report. *Acta Orthop Belg.* 2006;72(5):641-3.
- Xavier MSV, Leite VM. Efeito do adesivo butil-2-cianoacrilato em osteotomias e enxerto ósseo em coelhos: aspecto macroscópico e radiográfico. *Rev Bras Ortop.* 2012;47(5):638-45.
- Doig GS, Simpson F. Randomization and allocation concealment: a practical guide for researches. *J Crit Care.* 2005;20(2):187-91.
- Altman DG, Schulz KF. Statistics notes: concealing treatment allocation in randomised trials. *BMJ.* 2001;323(7310):446-7.
- Junqueira LC, Carneiro J. *Histologia básica.* 8ª ed. Rio de Janeiro: Guanabara-Koogan; 1995.
- Pereira FRA, Dutra RC, Olímpio TCR, Muller SS, Palacio EP. Effects of zoledronic acid on ooforectomized rats' tibiae: a prospective and randomized study. *Rev Bras Ortop.* 2015;44(1):61-8.

-
22. Palacio EP, Jacob EM, Campi TB, Muller SS. Zoledronate for treatment of humeral osteoporosis in female rats. A prospective randomized trial. *Acta Ortop Bras.* 2010;18(2):90-5.
 23. Palacio EP, Muller SS, Sardenberg T, Mizobuchi RR, Galbiatti JA, Durigan A Jr, et al. Detecting early biomechanical effects of zoledronic acid on femurs of osteoporotic female rats. *J Osteoporos.* 2012;2012:162806.