

Evaluation of the Southwick Angle in Two Hundred Hips of Asymptomatic Children and Adolescents*

Avaliação do ângulo de Southwick em duzentos quadris de crianças e adolescentes assintomáticos

Felipe Alves Monte¹ Paulo Sergio Melo² Amaro Alves¹ José Venâncio Oliveira Junior²
George Alencar² Fabio Couto Soares²

¹Department of Orthopedics and Traumatology, Hospital da Restauração Governador Paulo Guerra, Recife, PE, Brazil

²Department of Orthopedics and Traumatology, Instituto Materno Infantil de Pernambuco, Recife, PE, Brazil

Address for correspondence Felipe Alves do Monte, MD, PhD, Hospital da Restauração Governador Paulo Guerra, Avenida Agamenon Magalhaes s/n, Derby, Recife-PE, 50110-900, Brasil (e-mail: falves74@hotmail.com).

Rev Bras Ortop 2020;55(3):360–366.

Abstract

Objectives To measure the mean value of the Southwick angle using two different methods, the manual (1) and digital (2) methods, and to establish a normality value.

Methods A primarily descriptive study with 100 children and adolescents. Individuals with orthopedic complaints regarding the hips and/or knees or gait alterations were excluded. For each patient, an X-ray was performed on the lateral incidence of Lowenstein, totaling 100 radiographs and 200 hips. The Southwick angle was measured in two different ways by the same researcher: the conventional method (1), tracing the lines with pencils and measuring the angle with the use of a goniometer and negatoscope, and through the GNU Image Manipulation Program (GIMP) image editor (open source), version 2.7.0 (2), in which the lines were plotted and the angles of both hips were gauged on each radiograph. Later, we sought to evaluate the correlation between the two methods and to verify the mean Southwick angle by categorically correlating it by gender, age group and body mass index (BMI) in asymptomatic children and adolescents. All radiographs were authorized by the children and adolescents' parents/legal guardians. The study was approved by the ethics committee of the institutions in which the research was conducted.

Results The mean of the Southwick angles obtained by the conventional method was of $8.7^\circ (\pm 2.0^\circ)$, and, by the digital method, it was of $9.9^\circ (\pm 1.8^\circ)$. The angle obtained by the two methods was statistically significant ($p < 0.001$). The majority of the studied population (95%) had a body mass index (BMI) > 18.5 , and the mean of the angles was within the previously established value ($\sim 10^\circ$).

Conclusion For the first time, using a substantial sample size, a normal value for the Southwick angle measured in asymptomatic individuals was demonstrated. In addition, the image editor proved to be a reliable method to measuring the Southwick angle.

Keywords

- ▶ slipped capital femoral epiphysis
- ▶ hip joint
- ▶ adolescent

* Work performed at Hospital da Restauração Governador Paulo Guerra, Recife, PE, Brazil.

Resumo

Objetivos Medir o valor médio do ângulo de Southwick utilizando dois diferentes métodos, manual (1) e digital (2), e estabelecer um valor de normalidade.

Métodos Estudo primariamente descritivo, realizado com 100 crianças e adolescentes. Foram excluídos indivíduos que apresentavam queixa ortopédica nos quadris e/ou joelhos, ou alterações de marcha. Para cada paciente, foi realizada uma radiografia na incidência lateral de Lowenstein, totalizando 100 radiografias e 200 quadris. O ângulo de Southwick foi medido de duas formas pelo mesmo pesquisador: pelo método convencional (1), traçando-se as retas com lápis e medindo o ângulo com o uso de goniômetro e negatoscópio, e por meio do editor de imagem GNU Image Manipulation Program (GIMP; código aberto), versão 2.7.0 (2), no qual foram traçadas as linhas e aferidos os ângulos de ambos os quadris em cada radiografia. Posteriormente, buscou-se avaliar a correlação entre os dois métodos e verificar o ângulo médio de Southwick correlacionando-o categoricamente por gênero, faixa etária e índice de massa corpórea (IMC) em crianças e adolescentes assintomáticos. Todas as radiografias foram autorizadas pelos responsáveis. O estudo foi aprovado pelo comitê de ética das instituições em que a pesquisa foi realizada.

Resultados A média do ângulo de Southwick obtida pelo método convencional foi de $8,7^\circ (\pm 2,0^\circ)$, e pelo método do editor de imagem, foi de $9,9^\circ (\pm 1,8^\circ)$. O ângulo obtido pelas duas formas teve significância estatística ($p < 0,001$). A maioria da população estudada (95%) tinha índice de massa corpórea (IMC) $> 18,5$, e a média dos ângulos esteve dentro do valor previamente estabelecido como normal ($\sim 10^\circ$).

Conclusão Demonstrou-se, pela primeira vez, utilizando uma amostra substancial, um valor normal do ângulo de Southwick medido em indivíduos assintomáticos. Além disso, o editor de imagem mostrou ser um método confiável para mensuração do ângulo de Southwick.

Palavras-chave

- ▶ escorregamento das epífises proximais do fêmur
- ▶ articulação do quadril
- ▶ adolescente

Introduction

Proximal epiphysiolysis of the femur is still a neglected disease due to the lack of early diagnosis.^{1,2} Simple pelvis radiography is the method of choice for the diagnosis through the measurement of the lateral angle between the proximal epiphysis and the diaphysis of the femur. Southwick, in his original work,³ considered the angle of normality of around 10° based on a small number of individuals. There is a need for an adequate characterization of this parameter of normality in a larger sample, so that it can be restored or corroborated the normal values of the angle between the proximal epiphysis of the femur and its diaphysis.

Epiphysiolysis of the hip is an affection characterized by increased thickness, and consequent weakening, of the proximal femoral growth plate at the level of the hypertrophic layer.⁴⁻⁷ Although the disease occurs in adolescence, the slippage causes mechanical alteration in load articulation, and this may trigger, in the future, degenerative osteoarthritis of the hip, hence the need to establish an early diagnosis and to institute the appropriate treatment.^{8,9}

This disease affects the hips of children and adolescents aged between 10 and 15 years.^{8,9} Evidence indicates that when this condition occurs on one side, there is a greater possibility that the contralateral hip will develop the same condition in the following 18 months.^{4,10,11} The prevalence

of proximal femoral epiphysiolysis, depending on the region of the world and on ethnicity, varies on average from 2 to 10 for every 100,000 susceptible individuals.¹²⁻¹⁴ Studies indicate that this disease is more common in boys⁷ and young black individuals,¹⁵ with a greater dominance on the left side.^{4,5,7,13,14}

The diagnosis of proximal femoral epiphysiolysis is confirmed by simple radiographs in anteroposterior (AP) projection of the pelvis in the frog-leg position or double abduction (Lowenstein), in which, even before the displacement of the epiphysis in relation to the cervix, an increase at the height or thickness of the growth plate and a reduction in the projection of the mammillary bodies can be detected.¹⁶ On AP radiographs, a line traced in the upper portion of the femoral neck should cross part of the epiphyseal nucleus (Trethowan sign) and, when it does not, this suggests the presence of slippage.¹⁷ In addition to osteopenia detected in the femoral neck, which is attributed to the relative lack of use or to the reactional hypervascularization, in cases of greater slippage, one can notice a line of sclerosis superimposed on the image of the cervix (Steel crescent sign), which translates the frontal radiographic view of the epiphysis, positioned posteriorly in relation to the lap.¹⁸

In 1967, Southwick³ quantified this slippage in degrees, relying mainly on radiographs in double abduction of the hips,

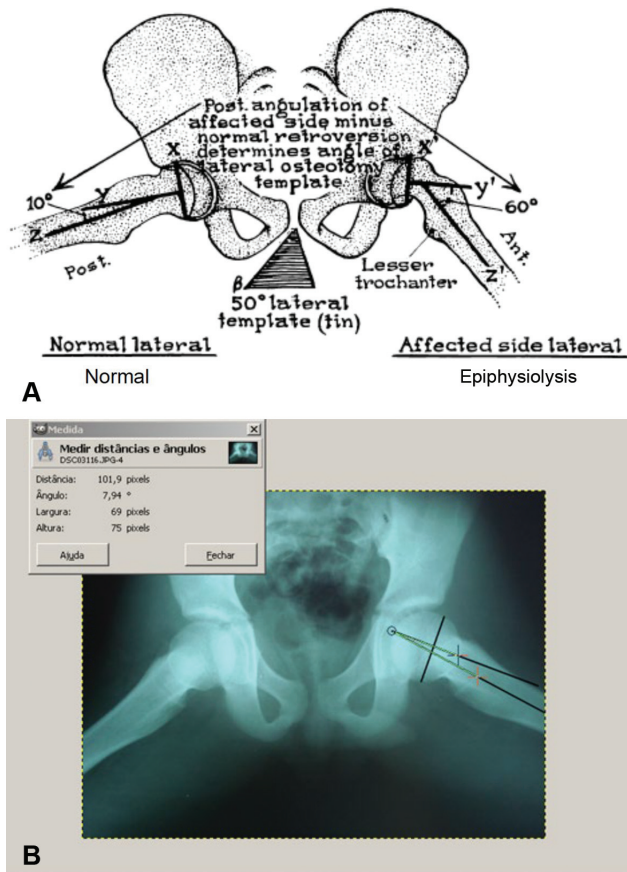


Fig. 1 Schematic drawing of the epiphysio-diaphyseal angle of Southwick in the Lowenstein lateral position of the hips (A).³ Pelvis radiograph in the Lowenstein lateral position of the hips in the GIMP image editor, version 2.7.0, with lines traced on left hip to measure the Southwick angle (B).

in which the AP deviation was verified. According to the author, the extreme points of the epiphysis are joined together with a line and then a line perpendicular to it is traced, which will form a certain angle with a third line parallel to the long shaft of the diaphysis (► **Figure 1A**).³ The deviation up to 10° is considered normal;³ deviations above normal, but not higher than 30°, are considered mild epiphysiolysis; deviations between 30° and 60° are considered moderate; and those higher than 60° degrees are considered severe.¹⁹

However, the establishment of this 10-degree limit does not necessarily match the average of the Brazilian population or that of other countries, since there are no studies with a significant sample that can be used as a normality parameter. In Brazil, there are few studies on this subject, and they do not establish average values of normality for the angle of Southwick.^{17,20}

With the technological evolution and digitization of plain radiographs, computer programs have been increasingly used to establish and measure lines and angles, because they make the diagnosis more accurate and optimize the treatment, improving the prognosis of diseases such as epiphysiolise.²¹

Therefore, the aim of the present study was to verify the mean value of the Southwick angle of the hip using two methods. In the first method, the lines were traced in the

radiograph with a negatoscope, in which and then a goniometer was used to measure the angle (conventional method); in the second method, the GNU Image Manipulation Program (GIMP; open source) software, version 2.7.0, was used to trace the lines and measure the angles on both hips. Subsequently, we attempted to evaluate the correlation between the two methods and verify the average angle of Southwick by gender, body mass index (BMI), and age group in asymptomatic children and adolescents.

Materials and methods

The present is a primarily descriptive study with secondary analyses, conducted with 100 individuals aged between 10 and 15 years, of both genders. The study was performed in the infirmary, emergency and pediatric and orthopedic outpatient clinic. Patients who presented orthopedic complaints on the hips and/or knees, or gait changes, were excluded. For each patient, an x-ray was performed in the lateral Lowenstein incidence, totaling 100 x-rays and 200 hips.

The method to perform radiographs was originally suggested by Southwick³ as follows: 1) the pelvis is kept parallel to the table; 2) the x-ray tube is centered exactly at the midline between the hips; 3) for the lateral incidence, the hips are placed in maximum abduction and external rotation, with the knees flexed and the plantar surfaces of the feet against each other, while the side surfaces rest on the table.

The Southwick angle is measured as follows: the extreme points of the growth cartilage (physis) of the proximal femur epiphysis are joined with a line, and then a perpendicular line is traced, forming a certain angle with a third line that is parallel to the long axis of the femoral diaphysis. The long axis of the femoral diaphysis was identified by a straight line formed by the union of 2 different points 1.5 cm apart, positioned centrally at 2 levels in the proximal diaphysis of the femur.^{3,22}

The angle was measured in two ways by the same researcher: by the conventional method, tracing the lines with a pencil and measuring the angle using a goniometer in a negatoscope (► **Figure 1A**),³ and by digital photographs with 12-megapixel camera without flash that were inserted into the GIMP software, in which the lines were traced and the angles of both hips were measured (► **Figure 1B**).

In addition, the weight and height of the individuals were measured to calculate the body mass index (BMI), considering the well-established relationships between obesity and the incidence of epiphysiolise,²³ which must be studied even when dealing with normal hips.

The methods and purposes of the work were explained to the parents/legal guardians, especially regarding the performance of the radiographs and protection against radiation with the use of lead protectors in the region of the testicles and ovaries. Each patient was only evaluated after we received full consent of the parent/legal guardian, which was recorded in an informed consent form. The research project was approved by the Ethics in Research Committee of the institutions in which the research was conducted (under CAEE number 0299.0.099.000-11).

To make the calculations easier, the value of each angle was approximated to the nearest integer. The data were inserted in a Microsoft Office Excel 2016 (Microsoft Corp., Redmond, WA, US) spreadsheet. For the analysis of the graphic data, the Origin (OriginLab, Northampton, MA, US) software, version 2016, was used, with descriptive (frequency distribution, central tendency measures, dispersion and amplitude) and inductive statistic procedures. The Kolmogorov-Smirnov test and graphic representation were used to analyze the normal distribution of the data. The intraclass correlation coefficient (ICC) was used to evaluate the consistency of the hip angles. The Pearson correlation was used to verify if the hip angle in the image editor is related to the angle measured by the conventional method, as well as to analyze a possible correlation between the angle and the BMI.

The Student *t*-test for independent samples was used to compare the mean values of the angles of the left and right hips by both methods according to gender and to the 2 age group categories (10 to 12 years, and 13 to 15 years). In all of the statistical analyses, a significance level of 5% was considered as a criterion for the rejection of the null hypothesis, with a confidence interval of 95% and power of 80%.

Results

We evaluated 100 individuals aged between 10 and 15 years, and 60% of the sample were aged between 10 and 12 years. Most subjects were male (*n* = 60), and 95% of the individuals had a BMI higher than 18.5. ► **Table 1** presents the descriptive data of the variables investigated.

The hip angle measured digitally had a good consistency (ICC: 0.72; 0.60–0.81) when compared to the one measured by the conventional method. The ICC of the left hip was of 0.74 (95%CI: 0.56–0.85), and that of the right hip was of 0.70 (95%CI: 0.49–0.83). We found that the angle measured digitally was statistically related to the one measured by the conventional method (*p* < 0.001).

The mean angle of the left hip did not differ statistically by gender: by the digital method, it was of 9.4° ± 2.4° among boys, and of 10.6° ± 2° among girls (*p* = 0.093), and, by the conventional method, it was of 9° ± 1.9° among boys, and of 7.8° ± 2.2°

among girls (*p* = 0.092) (► **Figures 2A** and **C**). However, the mean angle of the right hip was statistically higher in females in both methods: in the digital method, it was of 9.3° ± 1.6° among boys, and of 11.2° ± 2° among girls (*p* = 0.001), and, in the conventional method, it was of 8.3° ± 1.75° among boys, and of 10.1° ± 1.85° among girls (*p* = 0.005) (► **Figure 2B** and **D**).

In the digital method, the mean angles of the left (10.6° ± 2.2°; *p* = 0.002) and right hip (10.5° ± 2.1°; *p* = 0.02) was statistically higher among younger patients (aged between 10 and 12 years) when compared to those of the patients aged 13 to 15 years (left: 8.6° ± 1.8°; right: 9.1° ± 1.9°) (► **Figure 3A**). However, no difference was found in the conventional method regarding age group (left: *p* = 0.059; right: *p* = 0.079) (► **Figure 3B**).

The BMI presented a moderate positive correlation with the angle in both methods (manual: *r* = 0.5; *p* = 0.041; digital: *r* = 0.59; *p* = 0.015).

Discussion

The objective of the present study was to describe normal values of Southwick angle in 100 hips in asymptomatic children and adolescents aged between 10 and 15 years. Additionally, a probable correlation was also observed between the studied angles and variables.

Most of the patients were male and aged between 10 and 12 years, which is in line with the literature^{24,25} findings, in which epiphysiolysis has been reported more frequently in this patient profile.

The mean angle obtained by the conventional method was of 8.7°, and, by the digital method, it was of 9.9°, with good consistency and statistical significance, which confirms the reproducibility and reliability of the measurement by both methods, since they were analyzed by the same researcher. The mean values were close to those recommended by Southwick,³ around 10°, which seems to represent the normal retroversion value of the proximal epiphysis of the femur of the children and adolescents in the studied age group.

The emergence of operating systems has provided a growth in computer applications in the field of health. The GIMP image editor proved to be practical, useful and reliable. Other methods

Table 1 Mean, standard deviation, median and minimum and maximum values of the investigated variables

Variable	Average	Standard deviation	Medium	Minimum	Maximum
Age (years)	12.1	1.5	12	10	15
Weight (kg)	47.5	7.6	47.5	32	60
Height (cm)	147.2	7.0	149.0	133	159
Body Mass Index	21.7	2.0	21.3	16.8	25.6
Left-hip angle (conventional method)	8.5	2.1	8.0	4	12
Right-hip angle (conventional method)	8.9	1.8	8.5	5	14
Both hips angle (conventional method)	8.7	2.0	8.0	4	14
Left-hip angle (digital method)	9.8	2.2	10.0	5	14
Right-hip angle (digital method)	9.9	1.8	10.0	6	14
Both hips angle (digital method)	9.9	2.0	10.0	5	14

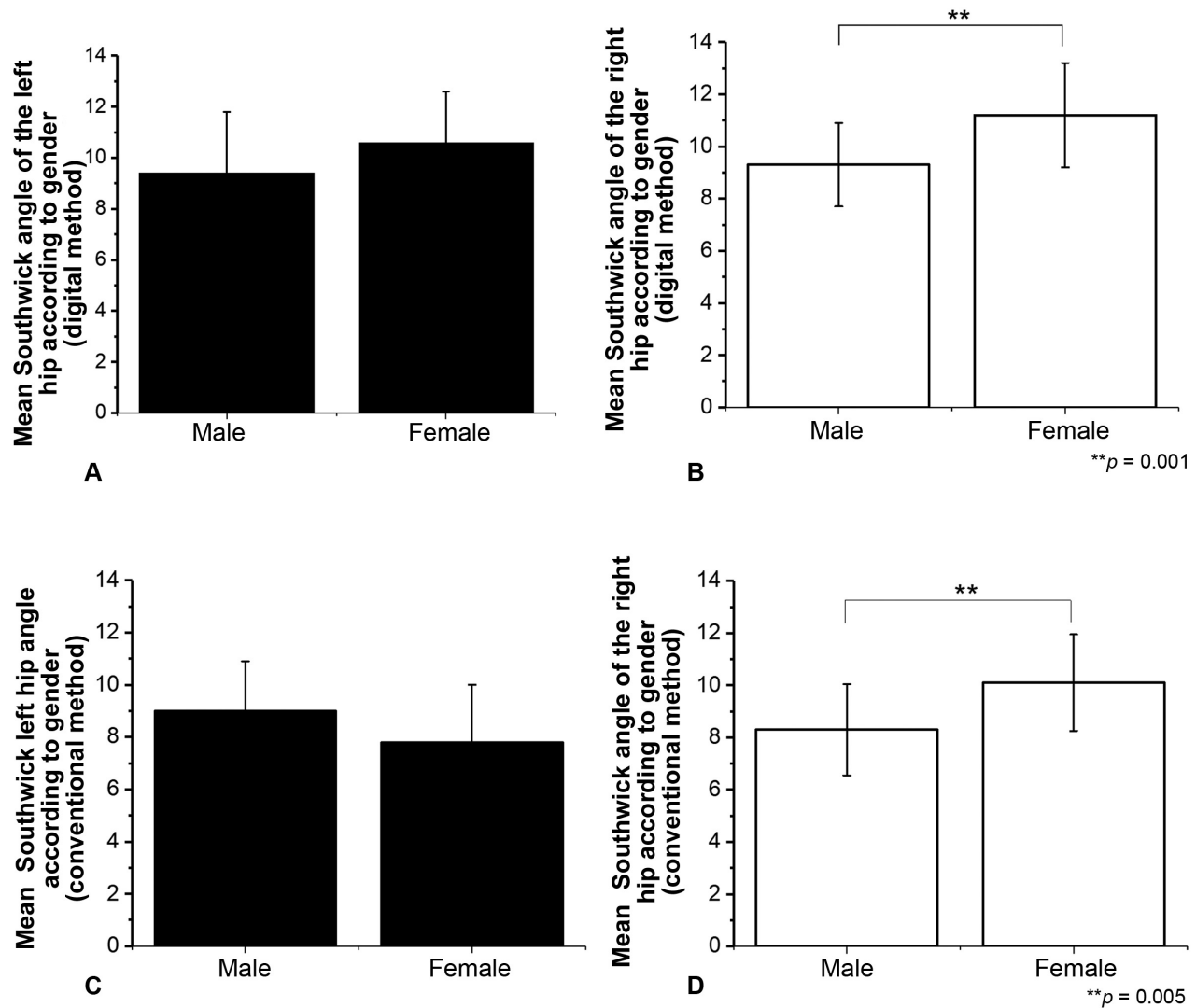


Fig. 2 Mean values of the angles of the left and right hips by the editor method (A, B) (Student *t*-test, $**p = 0.001$) and by the conventional method (C, D) (Student *t*-test, $**p = 0.005$) by gender.

that are also practical and free of charge have been used, such as the ImageJ (public domain) software, which is made available by the National Institutes of Health (NIH).²⁶

The consideration of the lateral incidence of Southwick and not of the AP incidence is justified because there are doubts regarding the real value, or even the existence, of the medial-lateral deviation, with medial positioning of the epiphysis in relation to the metaphysis, causing the varus observed in the AP incidence, since this would only be the effect of the parallax, which is the apparent displacement or the difference in apparent direction of an object as seen from two different points not on a straight line with the object.²⁷ There is no doubt, however, about the posterior position of the epiphysis in relation to the metaphysis, which can be compared with the molds made by Southwick, which is why we used the incidence of Lowenstein to guide the search for a mean value. However, some authors have shown that patients with epiphysiolysis have a reduced Southwick angle on the AP incidence.¹⁷ This finding may be due to the difficulty in obtaining an AP incidence in patients with

epiphysiolysis, due to the attitude of rotation and difficulty to perform the internal rotation of the hip.²⁷

In total, 95% of the patients had BMI > 18.5, a risk factor for the emergence of epiphysiolysis. Loder et al¹⁰ found that 95% of the patients with epiphysiolysis of the proximal femur are above the weight percentile for their age group. In the present study, even in patients with BMI above normal (> 18.5), the mean angle was below 10°, a range considered normal according to Southwick.³ However, a positive correlation was demonstrated between the increase in the lateral angle and the increase in BMI, which suggests that overweight may be a contributing factor for the emergence and/or worsening of the disease, as previously verified by some authors.^{10,23}

One study¹⁷ found normality of the Southwick angle in an AP radiograph of the pelvis. However, we believe that the normal value in the lateral incidence of Southwick also needs to be described, since the deviation in epiphysiolysis is primarily in the AP incidence.

With a larger sample, differences with greater statistical significance could have been demonstrated, as it can be

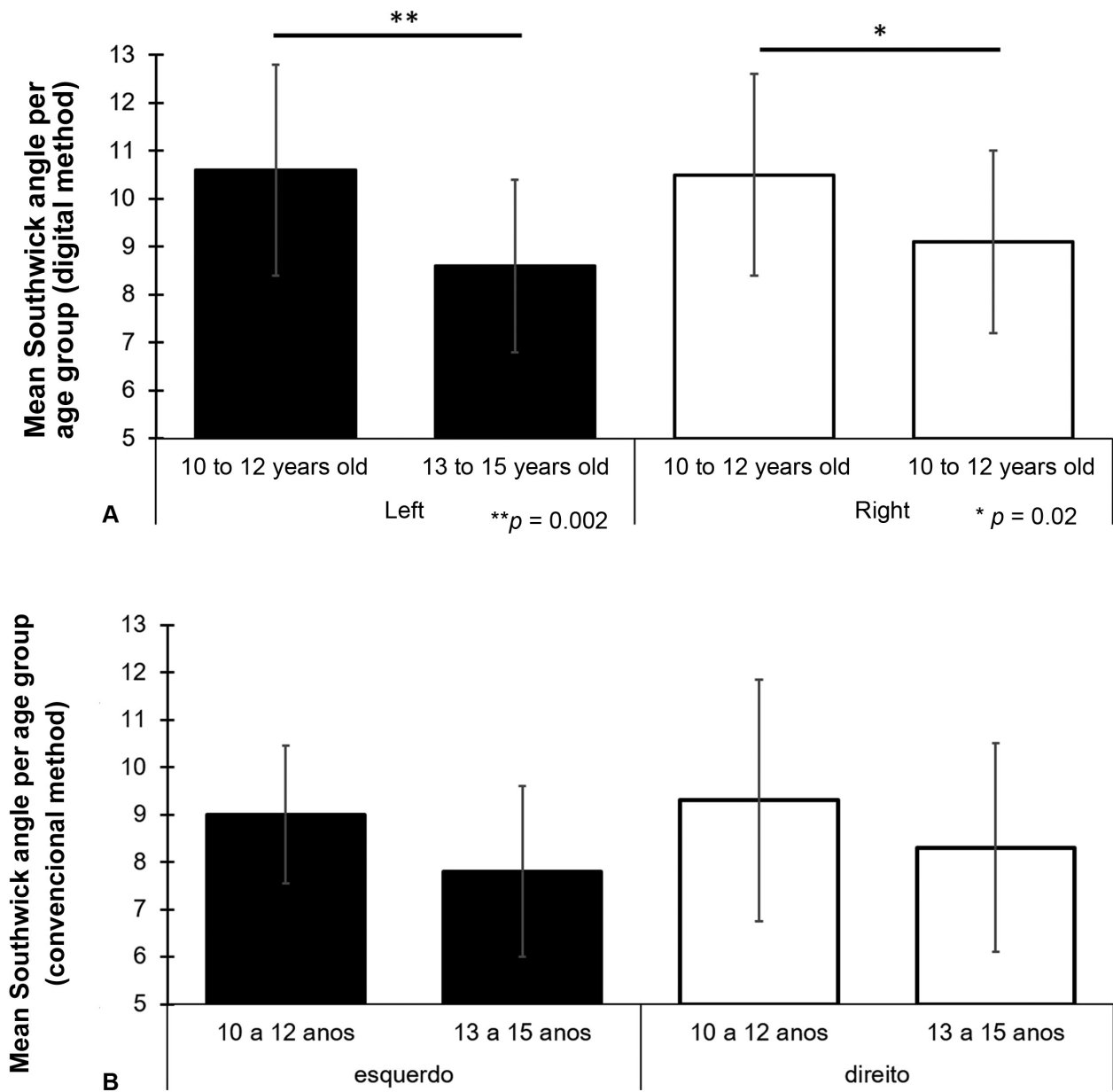


Fig. 3 Mean values of the Southwick angle of the left (Student t-test, ** $p = 0.002$) and right (Student t-test, ** $p = 0.02$) hips by the digital (A) and conventional (B) methods by age group (Student t-test; $p < 0.05$).

observed in the comparison by age group of the mean angles of the left and right hips, which presented a p -value that was statistically borderline to the left ($p = 0.059$) for the level of significance considered in the present study ($p < 0.05$). A larger number of parents/legal guardians were interviewed in order to increase the number of participants and radiographs in the study. however, their refusal to participate did not make that possible.

With the inclusion of a larger number of evaluators, inter- and intra-observer analyses could be made to compare the efficiency of both methods, but this type of analysis escapes from the initial scope of the present study and may be checked in the future.

Conclusion

The two methods used to measure the angle of Southwick showed good consistency. With a relevant sample size, for the first time a normal approximate value of the angle of Southwick was demonstrated: by the conventional method, the mean value was of 8.7° , and, by the digital method, it was of 9.9° . The GIMP image editor proved to be a reliable method to measure the angle of Southwick, and it can make the precise and early diagnosis of epiphysiolysis easier.

Conflict of Interests

The authors have no conflict of interests to declare.

Acknowledgments

We would like to thank Dr. Rômulo de Araújo Rego for the help provided in the acquisition of the x-rays of the study participants.

References

- 1 Monin JO, Guoin F, Guillard S, Rogez JM. [Late results of the treatment of the slipped upper femoral epiphysis (26 cases with follow-up study over 10 years)]. *Rev Chir Orthop Reparatrice Appar Mot* 1995;81(01):35-43
- 2 Westhoff B, Schröder K, Weimann-Stahlschmidt K, Zilkens C, Wilters R, Krauspe R. Radiological outcome and gait function of SCFE patients after growth arrest. *J Child Orthop* 2013;7(06):507-512
- 3 Southwick WO. Osteotomy through the lesser trochanter for slipped capital femoral epiphysis. *J Bone Joint Surg Am* 1967;49(05):807-835
- 4 Jingushi S, Suenaga E. Slipped capital femoral epiphysis: etiology and treatment. *J Orthop Sci* 2004;9(02):214-219
- 5 Krauspe R, Weinstein S. Special symposium issue: slipped capital femoral epiphysis (SCFE). *J Child Orthop* 2017;11(02):85-86
- 6 Tresoldi I, Modesti A, Dragoni M, Potenza V, Ippolito E. Histological, histochemical and ultrastructural study of slipped capital femoral epiphysis. *J Child Orthop* 2017;11(02):87-92
- 7 Current concepts review. Slipped capital femoral epiphysis. *J Bone Joint Surg Am* 1990;72(04):631-633
- 8 Örtengren J, Peterson P, Svensson J, Tiderius CJ. Persisting CAM deformity is associated with early cartilage degeneration after Slipped Capital Femoral Epiphysis: 11-year follow-up including dGEMRIC. *Osteoarthritis Cartilage* 2018;26(04):557-563
- 9 Helgesson L, Johansson PK, Aurell Y, Tiderius CJ, Kärrholm J, Riad J. Early osteoarthritis after slipped capital femoral epiphysis. *Acta Orthop* 2018;89(02):222-228
- 10 Loder RT, Aronson DD, Greenfield ML. The epidemiology of bilateral slipped capital femoral epiphysis. A study of children in Michigan. *J Bone Joint Surg Am* 1993;75(08):1141-1147
- 11 Griffith MJ. Slipping of the capital femoral epiphysis. *Ann R Coll Surg Engl* 1976;58(01):34-42
- 12 Ward WT, Stefko J, Wood KB, Stanitski CL. Fixation with a single screw for slipped capital femoral epiphysis. *J Bone Joint Surg Am* 1992;74(06):799-809
- 13 Hergren B, Stenmarker M, Vavrouch L, Hagglund G. Slipped capital femoral epiphysis: a population-based study. *BMC Musculoskelet Disord* 2017;18(01):304
- 14 Perry DC, Metcalfe D, Costa ML, Van Staa T. A nationwide cohort study of slipped capital femoral epiphysis. *Arch Dis Child* 2017;102(12):1132-1136
- 15 Aronson DD, Loder RT. Slipped capital femoral epiphysis in black children. *J Pediatr Orthop* 1992;12(01):74-79
- 16 Loder RT, Richards BS, Shapiro PS, Reznick LR, Aronson DD. Acute slipped capital femoral epiphysis: the importance of physeal stability. *J Bone Joint Surg Am* 1993;75(08):1134-1140
- 17 Damaceno FL, Santili C, Longui CA. Normal reference values of Southwick's anteroposterior angle in prepubertal and pubertal normal adolescents. *J Pediatr Orthop B* 2007;16(06):389-392
- 18 Steel HH. The metaphyseal blanch sign of slipped capital femoral epiphysis. *J Bone Joint Surg Am* 1986;68(06):920-922
- 19 Millis MB. SCFE: clinical aspects, diagnosis, and classification. *J Child Orthop* 2017;11(02):93-98
- 20 Santili C, de Assis MC, Kusabara FI, Romero IL, Sartini CM, Longui CA. Southwick's head-shaft angles: normal standards and abnormal values observed in obesity and in patients with epiphysiolyis. *J Pediatr Orthop B* 2004;13(04):244-247
- 21 Baecker V. Image J Macro Tool Sets for Biological Image Analysis. Disponível em: https://www.researchgate.net/profile/Volker_Baecker/publication/273769192_ImageJ_Macro_Tool_Sets_for_Biological_Image_Analysis/links/550c039c0cf2528164dae59a/ImageJ-Macro-Tool-Sets-for-Biological-Image-Analysis.pdf?origin=publication_detail
- 22 Subburaj K, Ravi B, Agarwal M. Computer-aided methods for assessing lower limb deformities in orthopaedic surgery planning. *Comput Med Imaging Graph* 2010;34(04):277-288
- 23 Aversano MW, Moazzaz P, Scaduto AA, Otsuka NY. Association between body mass index-for-age and slipped capital femoral epiphysis: the long-term risk for subsequent slip in patients followed until physeal closure. *J Child Orthop* 2016;10(03):209-213
- 24 Crawford AH. Slipped capital femoral epiphysis. *J Bone Joint Surg Am* 1988;70(09):1422-1427
- 25 Santili C, Akkari M, Waisberg G, Braga SR, Kasahara A, Perez MC. Evolution of slipped capital femoral epiphysis after nonsurgical treatment. *Rev Bras Ortop* 2015;45(05):397-402
- 26 Schneider CA, Rasband WS, Eliceiri KW. NIH Image to ImageJ: 25 years of image analysis. *Nat Methods* 2012;9(07):671-675
- 27 Fujiki EM, Honda EK, Pradal A, Téo JB, Seixas LF, Porto LC. Epifisiólise femoral grau III: proposta de uma metodologia parao estudo radiográfico. *Rev Bras Ortop Pediatr* 2002;3(01):28-33