



## Case Report

# Calcaneal chondrosarcoma: a case report<sup>☆,☆☆</sup>

Frederico Barra de Moraes\*, Nicolle Diniz Linhares,  
Pryscilla Moreira de Souza Domingues, Vanessa Nogueira Machado Warzocha,  
Jefferson Martins Soares

Faculdade de Medicina da Universidade Federal de Goiás, Goiânia, GO, Brazil

### ARTICLE INFO

#### Article history:

Received 23 April 2013

Accepted 9 October 2013

Available online 14 May 2014

#### Keywords:

Chondrosarcoma

Calcaneus

Bone neoplasms

### ABSTRACT

The objective was to report on a rare case of chondrosarcoma of the bones of the foot, and specifically the calcaneus. The patient was a 30-year-old woman with a complaint of painless nodulation on the lateral face of the calcaneus, which she had had for around eight years, which then started to present significant pain. Radiography showed a tumor with imprecise limits, compromising the calcaneus, talus and lateral malleolus. The lesion had a destructive, aggressive and osteolytic appearance, with invasion of the surrounding soft tissues and the presence of points of calcification. Amputation was performed in the middle third of the right lower leg, with a histological diagnosis of chondrosarcoma. The case evolved with local recurrence of the tumor formation and subsequent amputation in the middle third of the right thigh. One year after the second amputation, the patient evolved with metastasis from the chondrosarcoma in soft tissues throughout the body and in the lungs, and she died one year and ten months after the diagnosis was made. Chondrosarcomas that involve the calcaneus are rare in young adults, with few reports in the literature. For this reason, the present report becomes important in that it shows that even though this is a rare condition, it is present in our environment. Early investigation is essential, especially by means of imaging examinations, with the aim of diminishing the chances of malignant transformation and consequent complications, so as to avoid death.

© 2014 Sociedade Brasileira de Ortopedia e Traumatologia. Published by Elsevier Editora Ltda. All rights reserved.

### Condrossarcoma de calcâneo: relato de caso

#### R E S U M O

Relatar um caso raro de condrossarcoma dos ossos do pé, mais especificamente no calcâneo. Mulher de 30 anos, com queixa de nodulação indolor na face lateral do calcâneo havia cerca de oito anos, que iniciou com dor importante. A radiografia mostrou um tumor de limites imprecisos, que comprometeu o calcâneo, o tálus e o maléolo lateral. A lesão apresentou aspecto destrutivo, agressivo e osteolítico, com invasão de partes moles circunvizinhas e

#### Palavras-chave:

Condrossarcoma

Calcâneo

Neoplasias ósseas

<sup>☆</sup> Please cite this article as: de Moraes FB, Linhares ND, de Souza Domingues PM, Warzocha VNM, Soares JM. Condrossarcoma de calcâneo: relato de caso. Rev Bras Ortop. 2014;49:409-413.

<sup>☆☆</sup> Work performed in the Department of Orthopedics and Traumatology, Hospital das Clínicas, School of Medicine, Universidade Federal de Goiás, Goiânia, GO, Brazil.

\* Corresponding author.

E-mail: frederico\_barra@yahoo.com.br (F.B. de Moraes).

2255-4971/\$ – see front matter © 2014 Sociedade Brasileira de Ortopedia e Traumatologia. Published by Elsevier Editora Ltda. All rights reserved.  
<http://dx.doi.org/10.1016/j.rboe.2014.04.020>

presença de pontos de calcificação. Foi feita amputação no terço médio da perna direita, com diagnóstico histológico de condrossarcoma. Evoluiu com recidiva local da tumoração e, posteriormente, amputação no terço médio da coxa direita. Após um ano da última amputação, a paciente evoluiu com metástase de condrossarcoma em partes moles pelo corpo e nos pulmões e faleceu um ano e dez meses após o diagnóstico. Os condrossarcomas que envolvem o calcâneo em adultos jovens são raros, com poucos relatos na literatura. Por esse motivo, o presente relato torna-se importante no sentido de mostrar que apesar de essa ser uma afecção rara, ainda assim ela está presente no nosso meio. É imprescindível sua investigação precoce, principalmente por exames de imagem, com o intuito de diminuir as chances de malignização e, conseqüentemente, de complicações e evitar o óbito.

© 2014 Sociedade Brasileira de Ortopedia e Traumatologia. Publicado por Elsevier Editora Ltda. Todos os direitos reservados.

## Introduction

Sarcomas are rare mesenchymatous neoplasms (less than 1% of all types of cancer) that arise in muscles, endothelium, cartilage and support structures. The incidence of malignant sarcomas is low: 1.5 per 100,000 inhabitants. This incidence results in approximately 8000 new cases per year in the United States.<sup>1</sup> Sarcomas generally have mesodermal origin, although some are derived from the neuroectoderm, and they are divided into two groups: bone and soft-tissue sarcomas. It should be noted that approximately 3% of bone tumors occur in the foot or ankle.<sup>2,3</sup>

Chondrosarcomas are tumors that develop during adulthood and old age, with maximum incidence between the fourth and sixth decades of life. They account for approximately 20–25% of bone sarcomas, but involvement of the calcaneus is rare. They preferentially affect the flat bones, especially the scapular and pelvic belts, but may also affect the diaphyseal parts of the long bones. They may arise primarily or secondarily, as malignant transformation of enchondromas or, more rarely, from the cartilaginous cover of osteochondromas.<sup>2,3</sup>

Chondrosarcomas have an indolent natural history, and patients typically present with pain and tumefaction. Radiologically, the lesion may have a lobular appearance, with mottled, spotty or ring-like calcification of the cartilaginous matrix. It is difficult to distinguish low-grade chondrosarcoma from benign lesions through radiographs or histological examination. For this reason, clinical history-taking and physical examination are fundamental steps in the diagnostic reasoning.

The objectives of this case were therefore to report on a rare case of chondrosarcoma of the calcaneus in a young adult patient with several complications, and to review the literature on this subject.

## Case report

The patient was a 30-year-old white woman who was assessed in the outpatient clinic of Hospital das Clínicas, School of Medicine of the Federal University of Goiás, with a history of a sprained right ankle that she had suffered approximately eight years earlier, with subsequent appearance of painless nodulation on the lateral face of the calcaneus. The tumor formation

had gradually increased in volume and the patient started to present a painful condition. For this reason, at a hospital elsewhere in the same state, the tumor was resected. However, complete healing was not achieved and the operative wound continued to be open, with active secretion.

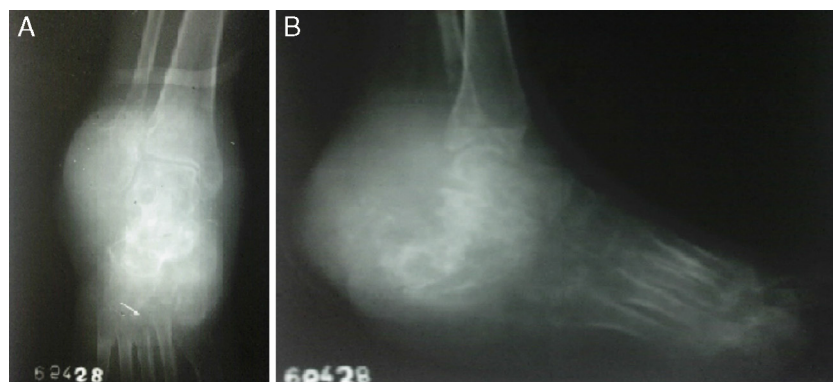
On physical examination, the right foot and ankle were seen to be very swollen, with tense and shiny skin. There were two fistulas in the lateral region of the calcaneus, with yellowish secretion. The foot was in the equinus position and was painful on palpation. Radiography showed a tumor with imprecise limits that compromised the calcaneus, talus and lateral malleolus. The lesion presented a destructive, aggressive and osteolytic appearance, with invasion of the surrounding soft tissues and presence of points of calcification in the tumor formation (Fig. 1).

The initial chest radiograph had a normal appearance. Macroscopically, the tumor tissue presented a straw-yellow color, and anatomopathological examination indicated that this was a chondrosarcoma. One month after the initial consultation, amputation was performed in the proximal third of the right foot, but healing of the operative wound did not take place and there was elimination of necrotic material and yellowish secretion. Radiography of the amputation stump showed an osteolytic lesion in the amputated tibia, and this was considered to be recurrence in the amputation stump (Fig. 2).

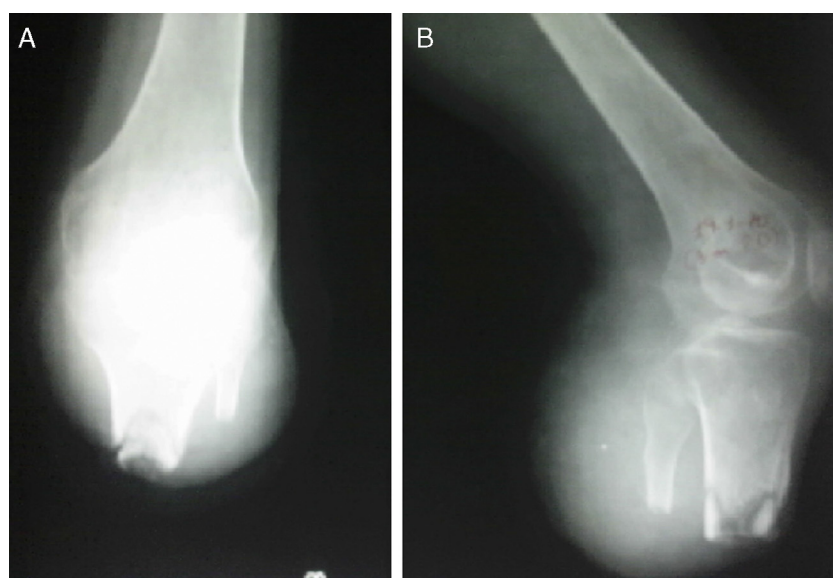
Six months after the first amputation, the patient was admitted to the hospital. A chondrosarcoma was observed in the amputation stump of the tibia and a new amputation was performed in the middle third of the right thigh (Fig. 3A). One year later, the patient returned to the outpatient clinic with a complaint of dyspnea, with a compromised general condition and nodulation of rubbery consistency over the entire body. Biopsies on these lesions revealed the presence of soft-tissue metastasis from the chondrosarcoma. Chest radiography revealed metastatic nodulation in both lungs (Fig. 3B). The patient died later in the week of the return visit, approximately one year and ten months after the diagnosis.

## Discussion

Chondrosarcomas are malignant bone tumors characterized by the production of neoplastic cartilage and are the second commonest variety of matrix-producing malignant bone tumor. They are morphologically subdivided into



**Fig. 1 – Radiographs of the right foot and ankle in anteroposterior view (A) and lateral view (B), showing lesion of destructive, aggressive and osteolytic appearance, with invasion of the surrounding soft tissues and the presence of points of calcification in the tumor formation.**



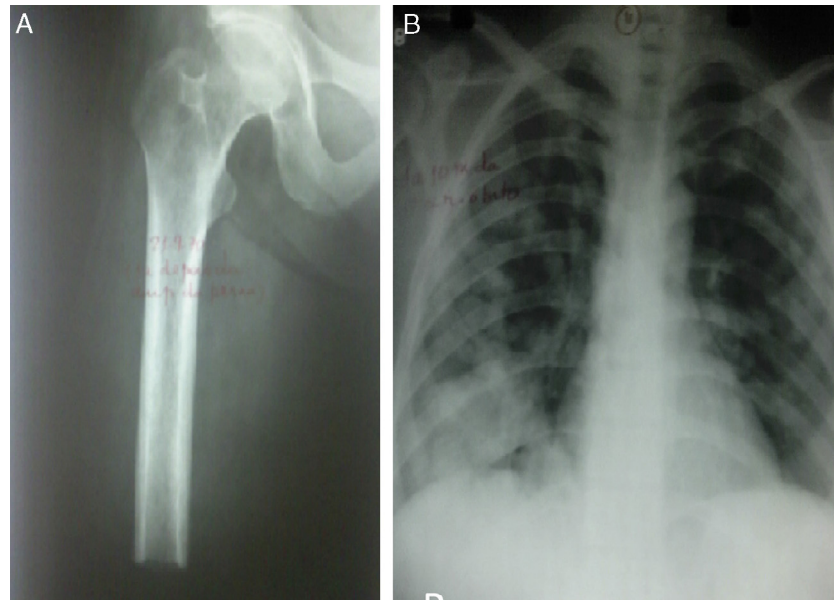
**Fig. 2 – Radiographs of the amputation stump in anteroposterior view (A) and lateral view (B), showing an osteolytic lesion in the amputated tibia.**

intramedullary and conventional juxtacortical variants, with clear, undifferentiated and mesenchymal cells, and 90% are of conventional chondrosarcoma type.<sup>4</sup>

They generally develop as intramedullary lesions and affect the scapular and pelvic belts more frequently than the feet. Among the chondrosarcomas affecting the bones of the foot, those that affect the calcaneus are more common.<sup>5,6</sup> They may be primary or secondary and, in the latter case, they represent malignant transformation of enchondromas or osteochondromas. Furthermore, they are commonly associated with the hereditary syndrome of multiple exostosis in 6% of the cases.<sup>7,8</sup> Since osteochondromas are commonly asymptomatic, the patients are unaware of the existence of the lesion, such that sudden pain and rapidly growing pain are the clinical manifestations of suspected malignancy, along with focal compressive neuropathy.<sup>9</sup> The process of malignant transformation occurs at a frequency of 5%.<sup>7</sup>

Chondrosarcomas are the second commonest type of bone neoplasm among the malignant primary bone tumors. The behavior of these tumors is variable, ranging from a slow-growth form with little possibility of metastasis, to an aggressive sarcomatous form with a high likelihood of metastatic transformation. They affect males and females equally, without any preferential age. They are predominantly observed in individuals between their fifth and sixth decades of life and are more frequently seen in the appendicular skeleton. Clinically, they are characterized by insidious, progressive and long-duration pain.

The diagnosis of calcaneal chondrosarcoma is made radiologically. Thus, several methods are used for detecting these neoplasms, such as conventional radiography, computed tomography (CT) and magnetic resonance imaging (MRI).<sup>10</sup> The nodular growth pattern of the cartilage produces radiographically prominent endosteal scalloping. The calcified matrix appears as foci of flocculent density, and mottled,



**Fig. 3 – Anteroposterior radiograph of the right thigh showing amputation in the middle third of the femur (A). Posteroanterior radiograph of the chest showing metastatic nodulation in both lungs (B).**

“popped”, spotty or ring-like calcification of the cartilaginous matrix.<sup>11</sup> One good option for following up patients who present some type of bone tumor alteration is to use serial radiographs in order to study malignant transformation. In these, it may be possible to differentiate between lesions with well-defined and indistinct margins, or to note that the lesion increases in size, or to note that its mineralization takes on the appearance of opaque glass.<sup>7</sup> Radiography of the right foot of our patient showed a tumor with imprecise limits that compromised the calcaneus, talus and lateral malleolus. The lesion had a destructive, aggressive and osteolytic appearance, with invasion of surrounding soft tissues and the presence of points of calcification in the tumor formation.

Relative radiolucency inside a previously mineralized region of the cartilaginous cover also implies the possibility of sarcomatous degeneration. Although the thickness of the demineralized cartilaginous cover is generally less than 1 cm in benign osteochondromas, it is generally more than 2 cm when malignant transformation occurs. Evidence regarding the thickness of the cartilaginous cover is generally, but not always, a reliable sign of malignancy or benignity. The more radiotransparent the tumor is, the higher the likelihood that it will be of high-grade. Slow-growing low-grade tumors cause reactive thickening of the cortex, while high-grade neoplasms that are more aggressive destroy the cortex and form a soft-tissue mass.<sup>7</sup>

CT is an excellent auxiliary method for diagnosing osteosarcomas and chondrosarcomas. It provides significant improvement in determinations of the morphological modifications resulting from benign or malignant disease, along with high-quality images with excellent anatomical resolution and reduced levels of artifacts.<sup>10</sup> In many studies, CT has presented very high sensitivity for detecting morphological alterations caused by neoplasia (between 80% and 100%), and

has shown the primary origin of the lesions, with excellent viewing of radiopaque areas and the number of neoplastic foci present.<sup>10</sup> This high sensitivity rate has been demonstrated by the capacity that CT has for showing the extent of the lesion, its depth and the involvement of the adjacent soft and hard tissues, with reduced levels of technical artifacts. Thus, the radiograph pattern of chondrosarcomas, observed using CT, may help and facilitate the final histopathological diagnosis, through the individual characteristics of these lesions, which may be identified and analyzed through qualitative studies. Moreover, CT is a safe method for determining the morphological alterations caused by malignant and benign neoplasia and shows the relationship between the lesion and the adjacent tissues, and also the degree of infiltration and depth of the tumor mass. In this manner, the prognosis can be better established and therapy that is more appropriate can be administered.<sup>10</sup>

To treat chondrosarcomas, it is important to separate them into two major groups seen in imaging examinations: localized and aggressive lesions. Localized lesions are of low histological grade, with little possibility of metastasis. Thus, the treatment consists of wide resection of the lesion, which makes it possible to conserve the bone adjacent to the tumor.<sup>9</sup> In aggressive cases, the histology points toward intermediate and high-grade tumors, which are treated by means of amputation.<sup>12</sup>

It is important to seek to maintain the patient's independence. Proximal amputation increases the morbidity and mortality. Wide resection of the calcaneus in cases of malignant lesions can be performed, followed by reconstruction using osteomyocutaneous flaps from the fibula in order to achieve functional recovery. The most frequent local complications are hematomas and skin necrosis, with a mean graft consolidation time of six months.<sup>13</sup>

In the present case, it was decided to amputate the limb, but with the development of effective chemotherapy, salvage surgery on the limb has become the preferred treatment for primary bone sarcomas. Currently, 90% of the patients with sarcomas in limb extremities can successfully undergo salvage surgery on the limb.<sup>13</sup> Nonetheless, it is also worth noting that there are still great doubts in relation to limb salvage surgery for the foot, given that because the foot has a compartmentalized structure, it enables early involvement of bones and the adjacent soft tissues, which leads the great majority of physicians to choose to amputate the limb. However, depending on the size and location of the tumor in the foot, surgical margins may be attained in calcaneal tumors when the neurovascular structures of the tarsal tunnel remain unimpaired. Such situations provide the option of tumor resection and subsequent reconstruction and salvage of the limb, using bone, muscle and skin grafts, thereby ensuring that the patient continues to have a body part that is essential for physiological locomotion.

Survival will depend on achieving complete control over the primary neoplasm so that spreading into neighboring tissues and occurrences of metastatic foci are avoided. In this regard, the first surgical intervention should have the main aim of performing resection that is wide enough to prevent local recurrence. For this to be achieved, surgical margins of 4 cm on all sides are necessary, thereby leading to cure for almost all patients and resulting in 10-year survival of 97%.<sup>7</sup> Wide resection of cases of chondrosarcoma of the thoracic wall is advocated by some authors because of the difficulty in making a preoperative histopathological diagnosis, thereby representing a form of prophylaxis against future complications such as metastases.<sup>14</sup> In this sense, the first surgical intervention made in the patient of the case presented in this study does not seem to have been the best therapeutic approach, given that the lesion recurred and that pulmonary metastasis subsequently occurred. This corroborates the idea that wide intervention, although considered to be radical by some authors, is in many cases the best therapeutic option and has an influence on the patient's survival.

### Conflicts of interest

The authors declare no conflicts of interest.

### REFERENCES

1. Moley JF, Eberlein TJ. Soft-tissue sarcomas. *Surg Clin North Am.* 2000;80(2):687-708.
2. Patel SR, Benjamin RS. Sarcomas ósseos e das partes moles e metástases ósseas. In: Braunwald E, Kasper DL, Fauci AS, Jameson JL, Longo DL, Hauser S, editors. *Harrison medicina interna.* 17ª ed. Rio de Janeiro: Mcgraw-Hill Interamericana do Brasil; 2008. p. 610-3.
3. Kilgore WB, Parrish WM. Calcaneal tumors and tumor-like conditions. *Foot Ankle Clin.* 2005;10(3):541-65.
4. Rosenberg AE. Ossos articulações e tumores de tecidos moles. In: Kumar V, Abbas AK, Fausto N, editors. *Robbins & Cotran. Patologia – Bases patológicas das doenças.* 7ª ed. Rio de Janeiro: Elsevier; 2005. p. 1331-85.
5. Ogose A, Unni KK, Swee RG, May GK, Rowland CM, Sim FH. Chondrosarcoma of small bones of the hands and feet. *Cancer.* 1997;80(1):50-9.
6. Gupta K, Radhika S, Vasishta RK. Chondrosarcoma of calcaneum in a 12-year-old male patient: a case report. *Diagn Cytopathol.* 2004;31(6):399-401.
7. Gomes AC, Silveira CR, Paiva RG, Aragão Junior AG, Castro Junior JR. Condrossarcoma em paciente com osteocondromatose múltipla: relato de caso e revisão da literatura. *Radiol Bras.* 2006;39(6):449-51.
8. Wicks IP, Fleming A. Chondrosarcoma of the calcaneum and massive soft tissue calcification in a patient with hereditary and acquired connective tissue diseases. *Ann Rheum Dis.* 1987;46(4):346-8.
9. Sugawara M, Osanai T, Tsuchiya T, Kikuchi N. Limb-sparing surgery for a calcaneal chondrosarcoma transformed from a solitary osteochondroma. *J Orthop Sci.* 2009;14(1):100.
10. Tossato PS, Pereira AC, Cavalcanti MG. Osteossarcoma e condrossarcoma: diferenciação radiográfica por meio da tomografia computadorizada. *Pesq Odontol Bras.* 2002;16(1):69-76.
11. Merchan EC, Sanchez-Herrera S, Gonzalez JM. Secondary chondrosarcoma. Four cases and review of the literature. *Acta Orthop Belg.* 1993;59(1):76-80.
12. Geertzen JH, Jutte P, Rompen C, Salvans M. Calcaneotomy, an alternative amputation? Two case reports. *Prosthet Orthot Int.* 2009;33(1):78-81.
13. Li J, Guo Z, Pei GX, Wang Z, Chen GJ, Wu ZG. Limb salvage surgery for calcaneal malignancy. *J Surg Oncol.* 2010;102(1):48-53.
14. Rosenberg NP, Leuck Junior I, Schuler C, Delgiovio F, Araújo ES, Martini PV. Condrossarcoma de calcâneo. *J Pneumol.* 2003;29(1):3-4.