

# Hip Desarthrodesis – Report of Three Cases\*

## Desartrodese de anca – relato de três casos

Diogo Lino Moura<sup>1</sup>  António Figueiredo<sup>1</sup>

<sup>1</sup>Department of Orthopedics, Centro Hospitalar e Universitário de Coimbra, Coimbra, Portugal

Address for correspondence Diogo Lino Moura, Departamento de Ortopedia, Centro Hospitalar e Universitário de Coimbra, Coimbra, Portugal (e-mail: dmoura@gmail.com).

Rev Bras Ortop 2019;54:83–86.

### Abstract

Hip desarthrodesis, which is the conversion of an arthrodesis or of a surgical bone fusion into a hip replacement arthroplasty, is a difficult and challenging operation because of the need of a joint reconstruction in cases with bone fusion and an often long-term immobilization between the femur and the acetabulum, with important anatomic changes, retractions of adjacent soft tissues, and an associated limb shortening. Hip arthrodesis is an operation performed less and less; consequently, its desarthrodesis is even rarer. The present report details three rare cases of patients with long-term hip arthrodesis who were submitted to hip replacement conversion arthroplasty; it describes the applied surgical techniques and their clinical and functional outcomes.

### Keywords

- ▶ arthrodesis
- ▶ arthroplasty
- ▶ hip

### Resumo

A desartrodese de anca, isto é, a conversão da artrodese ou fusão óssea cirúrgica em uma artroplastia de substituição articular da anca, é uma intervenção difícil e desafiante, na medida em que é preciso reconstruir uma articulação perante uma consolidação óssea e uma imobilização muitas vezes de longa duração entre fêmur e acetábulo, já com importantes alterações anatômicas e retrações dos tecidos moles adjacentes, com encurtamento do membro associado. Visto que a artrodese de anca é uma cirurgia cada vez mais raramente aplicada, consequentemente a desartrodese é cada vez menos frequente. No presente artigo, os autores apresentam três casos raros de pacientes com artrodeses da anca de longa duração submetidos a conversão para artroplastia total e descrevem a técnica de desartrodese usada e seus resultados clínico-funcionais.

### Palavras-chave

- ▶ artrodese
- ▶ artroplastia
- ▶ anca

### Introduction

Due to the increase of the functional requirements of the patients and to the survival time of total hip arthroplasty, as well as to the development of conservative surgeries for

painful hip, hip arthrodesis became a resourceful intervention and an option for last-line revision.<sup>1–4</sup> Despite providing pain relief, the loss of joint mobility results in excessive biomechanical compensatory loads on the adjacent joints, causing symptomatic degenerative changes, in particular of the lumbar spine, of the homolateral knee, and of the contralateral hip. Moreover, the gait of the patient is limited, and many individuals are not able to sit down. A surgery that can solve these limitations is desarthrodesis, that is, the conversion of bone fusion into an arthroplasty.<sup>2,5,6</sup> Hip

\* Work developed at the Department of Orthopedics (Departamento de Ortopedia), Centro Hospitalar e Universitário de Coimbra, Coimbra, Portugal.

 Diogo Lino Moura's ORCID: is <https://orcid.org/0000-0003-4037-2442>.

received  
May 20, 2017  
accepted  
June 6, 2017  
published online  
January 17, 2018

DOI <https://doi.org/10.1016/j.rbo.2017.06.029>.  
ISSN 0102-3616.

Copyright © 2019 by Sociedade Brasileira de Ortopedia e Traumatologia. Published by Thieme Revinter Publicações Ltda, Rio de Janeiro, Brazil

License terms



arthrodesis is a surgery less and less indicated, and, as a result, desarthrodesis is even rarer. We present three rare cases of hip desarthrodesis performed by the same surgeon.

## Case Reports

### Desarthrodesis Technique

Preoperatively, the procedure is planned, with attention to the grade of dysmetria to be corrected and to the characteristics of the arthrodesis material to be extracted. An in situ femoral neck osteotomy is performed through the posterior approach. The identification of the greater sciatic notch, of the radiological U, of the anterior and posterior acetabular columns, and of the obturator foramen allows the localization of the original acetabular cavity. To determine how far to advance in the acetabular milling, the authors progressively drill the center of the acetabular cavity with a fine drill until bone consistency can no longer be felt. The length of the drill in the intraosseous position will correspond to the remaining bone quantity in the acetabulum until the intrapelvic position; the milling should be less deep than this measured length. An intraoperative fluoroscopy can also be useful in identifying the level of the femoral neck osteotomy and of the true acetabular fundus. In this phase, the surgeon tries to correct limb shortening and to assure an acceptable range of motion by releasing retracted soft tissues (including iliopsoas, rectus femoris, hamstring, and long adductor tenotomies). Next, the femoral milling is performed, and the prosthetic components are applied after proofs of stability. Since most desarthrodesis are performed in relatively young patients, with good bone stock, the preferred prosthetic fixation is non-cemented and reinforced with screws at the acetabulum. The articular pair of choice is metal-polyethylene. The surgery takes 2 to 3 hours, with a blood loss of ~ 1,000 mL. The postoperative management consists in walking with crutches with partial weight-bearing for 2 months, followed by a prolonged rehabilitation period focusing on the abductor apparatus.

### Case 1

Male patient submitted to a right hip arthrodesis with snake plate at 18 years old due to painful arthrosis associated with

ankylosing spondylitis (► **Fig. 1**). Fifteen years after the arthrodesis, the patient was submitted to a desarthrodesis due to complaints of reduced functionality. Unlike other cases, this patient received a metal-on-metal pair. After 8 years of follow-up, the Harris Hip Score is 78,<sup>7</sup> and the patient walks with one crutch with mild Trendelenburg and refers a surgery satisfaction index of 4 out of 5 (0 to 5 scale). This patient developed a metal-on-metal reaction, which was resolved by replacing the interface with metal-polyethylene.

### Case 2

Male patient submitted to a left hip arthrodesis with plate at 14 years old due to a hip fracture (► **Fig. 2**). Fifty-nine years after the arthrodesis, the patient was submitted to a desarthrodesis due to complaints of dysmetria and of axial pain in the lumbar spine and in the homolateral knee. Due to the poor function of the abductor muscle and to the insufficient neoarticular stability verified during the procedure, a double-mobility prosthesis was applied. After 3 years of follow-up, the patient reports partial pain improvement. The Harris Hip Score is 89.<sup>3</sup> The patient walks independently with mild Trendelenburg and his satisfaction index is 5 out of 5.

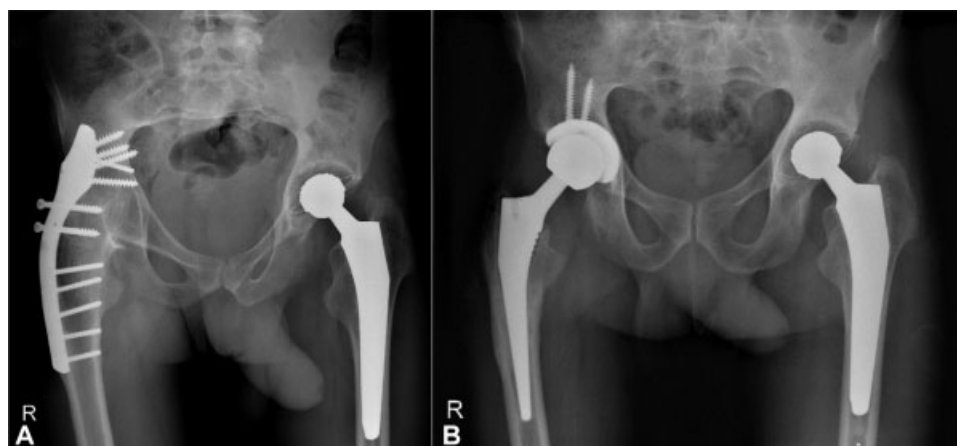### Case 3

Female patient submitted to a left hip arthrodesis with screws at 15 years old due to a hip fracture (► **Figs. 3 and 4**). Thirty-one years after the arthrodesis, the patient was submitted to a desarthrodesis due to complaints of reduced functionality. Due to a femoral fissure during the application of the stem, the proximal femur was reinforced with cerclage. After 2 years of follow-up, the Harris Hip Score is 94.6 and the patient walks independently with mild Trendelenburg and reports a satisfaction index of 5 out of 5.

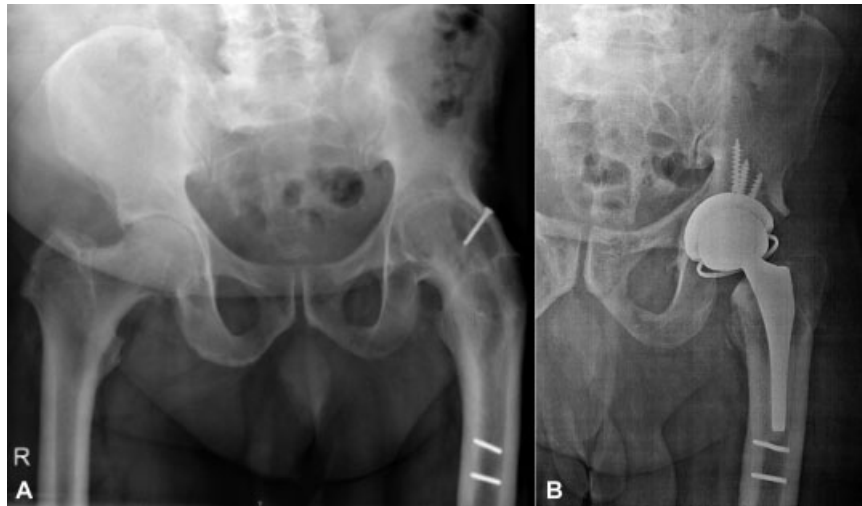
No more complications were reported, and all of the cases resulted in isometric limbs.

## Discussion

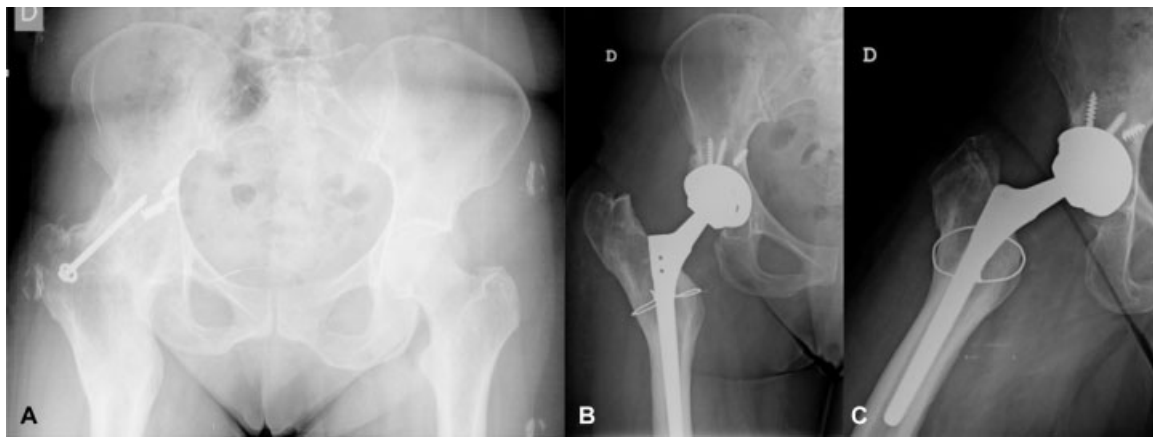
Hip desarthrodesis is a challenging surgery, since a joint has to be reconstructed in the presence of bone fusion and of a long-



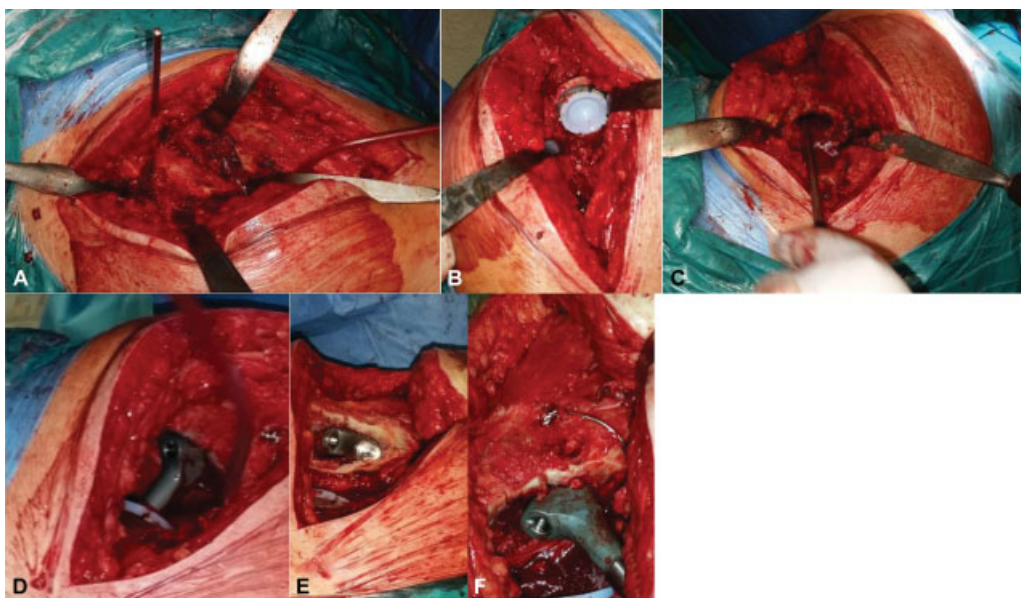
**Fig. 1** (A) radiography showing right hip arthrodesis with a snake plate; (B), radiography showing right hip desarthrodesis at 8 years of postoperative follow-up.



**Fig. 2** (A) radiography showing left hip arthrodesis; (B), radiography showing left hip desarthrodesis at 4 years of postoperative follow-up.



**Fig. 3** (A) radiography showing right hip arthrodesis with transarticular screws; (B), radiography showing right hip desarthrodesis at 3 years of postoperative follow-up.



**Fig. 4** (A) posterolateral route and osteotomy of the femoral neck before acetabular milling; (B), acetabular component application; (C), femoral preparation; (D), stability proofs; (E), non-cemented rod application and iatrogenic fissure; (F), definite femoral rod application and reinforced cerclage.

term immobilization of the femur and of the acetabulum, which are associated with important anatomical changes, retractions of soft tissues, and limb shortening.<sup>1,2,5,7-9</sup> Hip biomechanical alterations, a previous surgery (arthrodesis), and the complexity of the procedure result in the association of the procedure with important complication rates, including abductor apparatus insufficiency, instability, loosening of the prosthesis, and infection.<sup>1-3,6,8,10</sup> The single complication verified in the reported cases was a metal-on-metal reaction, not related to the desarthrodesis, but rather with the used articular pair, currently non-available. The use of a double-mobility cup in the second case probably allowed to prevent instability due to the insufficiency of the abductor and assured good functional outcomes in this patient. The major surgical challenge of desarthrodesis is the recognition and the creation of the acetabular cavity at the hip rotational center, while the major challenge in the postoperative period is the rehabilitation of the atrophied, devascularized and afunctional abductor muscle decades after the hip arthrodesis.<sup>3,4,7,9,10</sup> Even so, the function of the abductor is vastly improved, which is evidenced by the only mild Trendelenburg sign after a period of progressive rehabilitation. Although desarthrodesis is a demanding intervention with a high rate of complications reported in the literature, these cases show that an adequate surgical technique and rehabilitation can lead to satisfactory functional results with a lower complication rate, allowing a substantial improvement in the quality of life of the patients with hip arthrodesis.

#### Conflicts of Interest

The authors have no conflicts of interest to declare.

#### References

- 1 Stover MD, Beaulé PE, Matta JM, Mast JW. Hip arthrodesis: a procedure for the new millennium? *Clin Orthop Relat Res* 2004; (418):126-33
- 2 Jain S, Giannoudis PV. Arthrodesis of the hip and conversion to total hip arthroplasty: a systematic review. *J Arthroplasty* 2013; 28(9):1596-602
- 3 Joshi AB, Markovic L, Hardinge K, Murphy JC. Conversion of a fused hip to total hip arthroplasty. *J Bone Joint Surg Am* 2002;84-A(8): 1335-41
- 4 Reikerås O, Bjerkeim I, Gundersson R. Total hip arthroplasty for arthrodesed hips. 5- to 13-year results. *J Arthroplasty* 1995;10(4): 529-31
- 5 Beaulé PE, Matta JM, Mast JW. Hip arthrodesis: current indications and techniques. *J Am Acad Orthop Surg* 2002;10(4):249-58
- 6 Neumann D, Thaler C, Dorn U. Femoral shortening and cementless arthroplasty in Crowe type 4 congenital dislocation of the hip. *Int Orthop* 2012;36(3):499-503
- 7 Swanson MA, Huo MH. Total hip arthroplasty in the ankylosed hip. *J Am Acad Orthop Surg* 2011;19(12):737-45
- 8 Kilgus DJ, Amstutz HC, Wolgin MA, Dorey FJ. Joint replacement for ankylosed hips. *J Bone Joint Surg Am* 1990;72(1):45-54
- 9 Amstutz HC, Sakai DN. Total joint replacement for ankylosed hips. Indications, technique, and preliminary results. *J Bone Joint Surg Am* 1975;57(5):619-25
- 10 Harris WH, McCarthy JC Jr, O'Neill DA. Femoral component loosening using contemporary techniques of femoral cement fixation. *J Bone Joint Surg Am* 1982;64(7):1063-7