



Original Article

Magnetic resonance study on the anatomical relationship between the posterior proximal region of the tibia and the popliteal artery[☆]



Rogério Franco de Araujo Goes^{a,*}, Augusto Cardoso Filho^a,
Gabriel Novaes Pillar de Oliveira Castro^a, Fabricio Bolpato Loures^a,
Idemar Monteiro Da Palma^b, André Kinder^c, Pedro José Labronici^a

^a "Prof. Dr. Donato D'Ângelo" Orthopedics and Traumatology Service, Hospital Santa Teresa, Petrópolis, RJ, Brazil

^b Knee Group, Instituto Nacional de Traumatologia e Ortopedia (INTO), Rio de Janeiro, RJ, Brazil

^c Universidade Federal do Rio de Janeiro, Rio de Janeiro, RJ, Brazil

ARTICLE INFO

Article history:

Received 19 January 2014

Accepted 29 July 2014

Available online 30 July 2015

Keywords:

Knee

Magnetic resonance

Popliteal artery

Anatomy

ABSTRACT

Objective: To analyze and describe the distance from the popliteal artery to three specific areas of the proximal region of the tibia, with the knee extended, by means of magnetic resonance.

Methods: Images of 100 knees of patients who underwent magnetic resonance examinations were analyzed. The location of the popliteal artery was measured in three different areas of the posterior proximal region of the tibia. The first measurement was made at the level of the knee joint (tibial plateau). The second was 9 mm distally to the tibial plateau. The third was at the level of the anterior tuberosity of the tibia (ATT).

Results: The distances between the popliteal artery and the tibial plateau and ATT region were significantly greater in males than in females. The distances between the popliteal artery and the regions 9 mm distally to the tibial plateau and the ATT were significantly greater in the age group over 36 years than in the group ≤ 36 years.

Conclusion: Knowledge of the anatomical position of the popliteal artery, as demonstrated through magnetic resonance studies, is of great relevance in planning surgical procedures that involve the knee joint. In this manner, devastating iatrogenic injuries can be avoided, particularly in regions that are proximal to the tibial plateau and in young patients.

© 2014 Sociedade Brasileira de Ortopedia e Traumatologia. Published by Elsevier Editora Ltda. All rights reserved.

[☆] Work performed in the "Prof. Dr. Donato D'Ângelo" Orthopedics and Traumatology Service, Hospital Santa Teresa, Petrópolis, RJ, and the Faculdade de Medicina de Petrópolis, Petrópolis, RJ, Brazil.

* Corresponding author.

E-mail: rsgoes3@uol.com.br (R.F. de Araujo Goes).

<http://dx.doi.org/10.1016/j.rboe.2015.07.005>

2255-4971/© 2014 Sociedade Brasileira de Ortopedia e Traumatologia. Published by Elsevier Editora Ltda. All rights reserved.

Estudo por ressonância magnética da relação anatômica entre a região proximal posterior da tíbia e a artéria poplíteia

R E S U M O

Palavras-chave:

Joelho
Ressonância magnética
Artéria poplíteia
Anatomia

Objetivo: Analisar e descrever, com o joelho em extensão, a distância da artéria poplíteia em três áreas específicas da região proximal da tíbia, por meio de ressonância magnética.

Métodos: Foram analisadas as imagens de 100 joelhos de pacientes submetidos a exame por ressonância magnética. A localização da artéria poplíteia foi medida em três áreas distintas da região proximal posterior da tíbia. A primeira medida foi feita no nível da articulação do joelho (platô tibial). A segunda, a 9 mm distal do platô tibial. A terceira, ao nível da tuberosidade anterior da tíbia (TAT).

Resultados: As distâncias entre a artéria poplíteia e o platô tibial e a região da TAT foram significativamente maiores no sexo masculino do que no feminino. As distâncias entre a artéria poplíteia e a região 9 mm distal do platô tibial e a TAT foram significativamente maiores na faixa acima de 36 anos do que na faixa \leq 36 anos.

Conclusão: O conhecimento da posição anatômica da artéria poplíteia, demonstrada por estudos de RM, é de grande relevância no planejamento de procedimentos cirúrgicos que envolvam a articulação do joelho. Com isso, podem-se evitar lesões iatrogênicas devastadoras, principalmente em regiões proximais ao platô tibial e em pacientes jovens.

© 2014 Sociedade Brasileira de Ortopedia e Traumatologia. Publicado por Elsevier Editora Ltda. Todos os direitos reservados.

Introduction

Posterior neurovascular structures of the proximal region of the tibia can be injured during surgical procedures. The chances that iatrogenic injuries to the popliteal artery might occur, with formation of pseudoaneurysm, may be up to around 37.5%.¹ Vascular complications have been reported in procedures such as arthroscopic surgery, upper tibial osteotomy, osteotomy at the level of the anterior tuberosity of the tibia (ATT) and fixation of fractures of the tibial plateau.²⁻⁶ Although rare, vascular injury is one of the complications that may compromise the results from total knee arthroplasty (TKA).⁷⁻¹⁸ Its incidence is approximately 0.2%.¹⁹⁻²¹ The risk of vascular injury is greater among patients with previous vascular insufficiency.²²⁻²⁵ Direct laceration of the artery during TKA is also rare.^{12,18,26} This injury has also been described during reconstruction of anterior and posterior cruciate ligaments,²⁷ and also during meniscectomy through arthroscopy.²⁸

In normal anatomical situations, the popliteal artery is located laterally to the intercondylar fossa and passes obliquely along the medial border of the popliteal muscle, where it divides in to the anterior and posterior tibial arteries.^{6,21,22} The inferior lateral genicular artery originates 1-2 cm below the joint line and circles the tibia deeply. The inferior medial genicular artery originates posteriorly between the soleus muscle and the lateral head of the gastrocnemius.⁶

Several authors have identified the location of the popliteal artery in knees with osteoarthritis or in the knees of cadavers, using magnetic resonance imaging (MRI), arteriography or ultrasonography.²³⁻²⁸

The objective of the present study was to analyze the distance to the popliteal artery with the knee extended, in three specific areas of the proximal region of the tibia, by means of

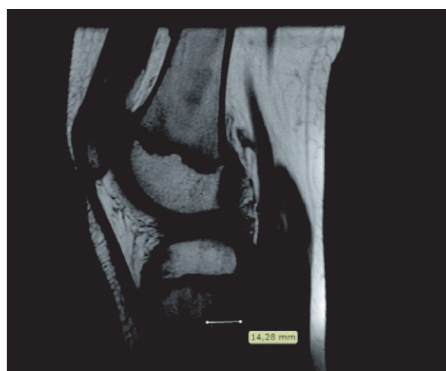MRI, and to compare the results between patients over and under 36 years of age.

Materials and methods

Between May and August 2012, the positioning of the popliteal artery in 100 knees of patients undergoing MRI examinations was retrospectively analyzed. All the images were obtained with the knee completely extended. The images were chosen by excluding patients who presented histories of fractures, tumors or deformities of the knee, or previous surgical procedures. Patients whose MRI presented any soft-tissue or bone abnormalities in the proximal region of the tibia were also excluded.

The MRI examinations were performed using a 1.5 T machine (Magnetom Essenza®, Siemens, Germany), with the patient in dorsal decubitus and the knee joint completely extended. The following sequences were obtained: T1-weighted sagittal sequence with repetition time (RT) of 540 ms, echo time (ET) of 13 ms, thickness of 4 mm, field of view (FOV) of 160/160 mm and matrix of 230/7384; and proton density-weighted with fat suppression in the axial plane (RT 3920, ET 35, thickness 3 mm, FOV 160/160 and matrix 192/320), sagittal plane (RT 2800, ET 35, thickness 4, FOV 160/160 and matrix 230/320) and coronal plane (RT 2550, ET: 32, thickness 3.5, FOV 160/160 and matrix 224/320).

The distance from the popliteal artery to the posterior tibial cortex was measured and processed in a Leonardo Siemens workstation in three different areas of the proximal region of the tibia. The first measurement was made at the level of the knee joint, where injuries can occur, especially due to arthroscopic procedures. The second was made 9 mm distally to the tibial plateau, at the location where the cut is made during



Level of the ATT and at 9 mm from the joint on the tibial plateau

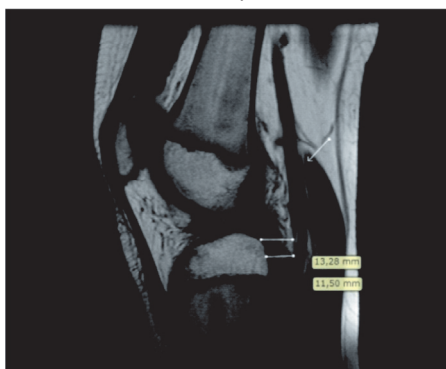


Fig. 1 – Location of the distance measurements between the popliteal artery and the posterior tibial cortex, at the level of the ATT and at 9 mm from the joint on the tibial plateau.

TKA. The third was made at the level of the anterior tuberosity of the tibia (ATT), where proximal osteotomy of the tibia is performed.

The measurements were obtained by means of MRI, on TI sagittal slices with the knee completely extended. At all levels, the posterior cortex of the proximal region of the tibia and the anterior wall of the popliteal artery were used as references (Fig. 1).

Characterization of the sample

Table 1 presents a descriptive analysis on the study sample of 100 knees, regarding the distances (in mm) in the three

Table 1 – Description of the distances in the three regions, in the sample of 100 knees.

Region	Mean	SD	Median	Minimum	Maximum
Tibial plateau (mm)	9.54	3.60	8.90	2.28	17.47
9 mm distally (mm)	6.59	2.46	6.19	3.00	12.70
ATT (mm)	12.97	2.74	13.03	7.61	19.31

Source: Hospital service files.

SD, standard deviation.

regions, which were defined thus: the tibial plateau at the level of the joint interline; 9 mm distally to the tibial plateau; and at the level of the ATT.

Statistical analysis

The descriptive analysis presented the observed data in the form of tables, expressed using means, standard deviations and medians, along with illustrative graphs.

The inferential analysis was composed of the following methods:

- Numerical variables were compared between pairs of subgroups using the Mann-Whitney test; and
- Spearman's correlation coefficient (r_s) was used to measure the degree of association between the distance measurements analyzed, i.e. between pairs of numerical variables. It can range from -1 to 1 . The closer it is to 1 or -1 , the stronger the association is; and the closer it is to zero, the weaker the relationship between the two variables is.

Non-parametric methods were used, because the variables did not present normal (Gaussian) distribution, given the wide dispersion of the data and rejection of the hypothesis of normality according to the Kolmogorov-Smirnov test. The criterion used for determining significance was the level of 5%. The statistical analysis was processed using the SAS 6.11 computer software (SAS Institute, Inc., Cary, NC, USA).

Results

The first objective was to ascertain whether there were any significant differences in the distances between the popliteal artery and the three regions (tibial plateau, 9 m distally to the tibial plateau and ATT) in the study sample of 100 knees, with regard to sex and age group. Tables 2 and 3 present the mean, standard deviation (SD) and median of the distances to the three regions, according to sex and age group (≤ 36 years and >36 years), respectively, and the corresponding descriptive levels from the Mann-Whitney test.

It was observed that the distance between the popliteal artery and the posterior tibial cortex at the level of the tibial plateau ($p=0.037$) and at the level of the ATT ($p=0.016$) was significantly greater among males than among females. There was no significant difference (at the 5% level) in that distance, in the region 9 mm distally to the tibial plateau ($p=0.46$) between the sexes.

It was demonstrated that the distances between the popliteal artery and the posterior tibial cortex in the region 9 mm distally to the tibial plateau ($p=0.006$) and at the ATT level ($p=0.005$) were significantly greater in the age group over 36 years than in the group ≤ 36 years. There was no significant difference (at the 5% level) in the distance in the region of the tibial plateau ($p=0.14$) between the age groups.

The second objective was to ascertain whether there was any correlation between age and the distances in the three regions (tibial plateau, 9 mm distally to the tibial plateau and ATT) and between the three distances, in the sample of 100 knees (Table 4).

Table 2 – Analysis on the distances from the three regions according to sex.

Variable	Male (n = 56)		Female (n = 44)		p value ^a
	Mean ± SD	Median	Mean ± SD	Median	
Age (years)	37.3 ± 15.2	34	44.0 ± 19.2	43	0.078
Distance					
Tibial plateau (mm)	10.1 ± 3.5	10.1	8.8 ± 3.6	8.1	0.037
9 mm distally (mm)	6.7 ± 2.4	6.5	6.4 ± 2.5	5.8	0.46
ATT (mm)	13.5 ± 2.5	13.7	12.3 ± 2.9	12.5	0.016

Source: Hospital service files.

SD, standard deviation.

^a Mann-Whitney test.

Table 3 – Analysis on the distances from the three regions according to age group.

Variable	≤36 years (n = 47)		>36 years (n = 53)		p value ^a
	Mean ± SD	Median	Mean ± SD	Median	
Distance					
Tibial plateau (mm)	9.0 ± 3.6	8.6	10.1 ± 3.6	9.0	0.14
9 mm distally (mm)	5.9 ± 2.2	5.6	7.2 ± 2.5	6.8	0.006
ATT (mm)	12.1 ± 2.6	12.4	13.8 ± 2.6	13.3	0.005

Source: Hospital service files.

SD, standard deviation.

^a Mann-Whitney test.

The following was observed:

- The distance between the popliteal artery and the posterior tibial cortex in the region 9 mm distally to the tibial plateau presented a significant direct correlation with age, in years ($r_s = 0.238$; $p = 0.017$), although this correlation was of low strength;
- The distance between the popliteal artery and the posterior tibial cortex in the region of the ATT presented a significant direct correlation with age, in years ($r_s = 0.258$; $p = 0.017$), although this correlation too was of low strength; and
- The distance between the popliteal artery and the posterior tibial cortex in the region of the tibial plateau did not present any significant correlation at the 5% level with age in years ($p = 0.13$).

Table 4 – Correlation between the distances from the three regions.

		Distance from the region		
		Tibial plateau	9 mm distally	ATT
Age (years)	r_s	0.151	0.238	0.258
	p	0.13	0.017	0.010
9 mm distally (cm)	r_s	0.770		
	p	0.0001		
ATT (cm)	r_s	0.365	0.523	
	p	0.0002	0.0001	

Source: Hospital service files.

r_s , Spearman correlation coefficient; p , descriptive level.

Figs. 2 and 3 illustrate the correlation of age with the distances between the popliteal artery and the posterior tibial cortex in the regions 9 mm distally to the tibial plateau and at the level of the ATT, respectively.

The following was observed:

- The distance between the popliteal artery and the posterior tibial cortex in the region 9 mm distally to the tibial plateau presented a significant direct correlation ($r_s = 0.770$; $p = 0.0001$);
- The distance between the popliteal artery and the posterior tibial cortex in the region of the tibial plateau presented a significant direct correlation with the ATT distance ($r_s = 0.365$; $p = 0.0002$), although this correlation too was of low strength; and

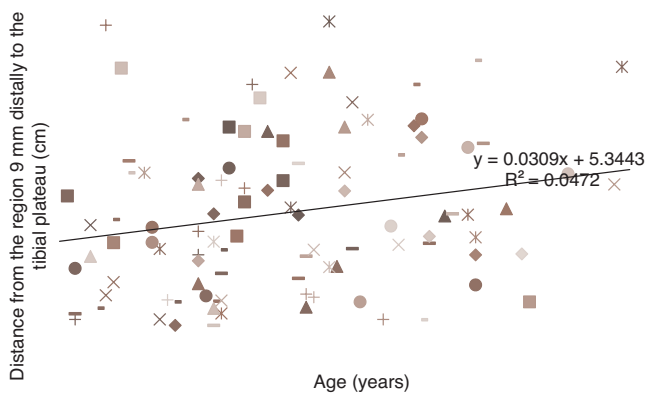


Fig. 2 – Age dispersion according to distance from the popliteal artery to the posterior tibial cortex in the region 9 mm distally to the tibial plateau.

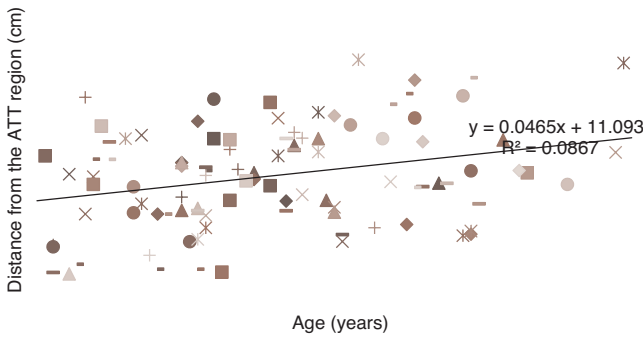


Fig. 3 – Age dispersion according to distance from the popliteal artery to the posterior tibial cortex in the ATT region.




Fig. 6 – Dispersion of the distances between the region 9 mm distally to the tibial plateau and the region at the ATT level.

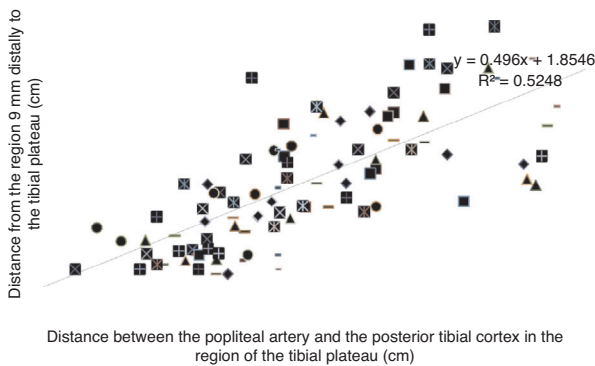


Fig. 4 – Dispersion of the distances between the region 9 mm distally to the tibial plateau and the level of the tibial plateau.

- The distance between the popliteal artery and the posterior tibial cortex in the region 9 mm distally to the tibial plateau presented a significant direct correlation with the distance in the ATT region ($r_s = 0.523$; $p = 0.0001$).

Figs. 4-6 illustrate the correlations between the distance measurements in the regions studied.

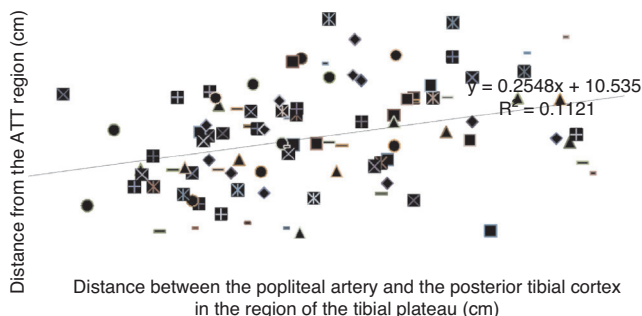


Fig. 5 – Dispersion of the distances between the distal region and the tibial plateau and ATT.

Discussion

The popliteal artery is the most anterior structure of the neurovascular bundle of the posterior region of the knee. It is a fixed structure and is closest to the joint in the region of the insertion of the posterior cruciate ligament, near to the fibrous arcade of the soleus muscle.²⁹

In surgery involving the proximal region of the tibia, iatrogenic injuries to the posterior neurovascular structures are devastating and may put the limb at risk.³⁰ This danger zone is located slightly laterally to the intercondylar fossa.

Small³¹ reported on 12 cases of vascular injuries, which represented 0.54% of all complications in the case series. There were nine cases of direct trauma to the popliteal artery, one of displacement of the fibrous arcade and two of nonspecific injuries. Tawes et al.³² reported on three cases in which the popliteal artery was injured during arthroscopic meniscectomy but this was diagnosed only later on, which led to amputation. More than 50% of the patients with injuries to the popliteal artery present deficient circulation, despite presenting a palpable distal pulse.³³

Yang et al.³⁰ studied the neurovascular structures in the proximal region of the tibia. They found that the artery was lateral to the midline of the tibia, especially in female patients. There was a great difference in distance between the neurovascular structures and the posterior cortex of the tibia. This means that greater care should be taken when surgery requires access to the posterior cortex. This difference in distance was similar to what was reported by Zaidi et al.⁶ at the level of the joint line, but slightly smaller than the distance reported by Smith et al.¹⁸ at the level of the tibial cut for total knee arthroplasty. Our study demonstrated that in the general sample, the distances to the popliteal artery in the three regions studied (tibial plateau, which corresponds to arthroscopic surgery; 9 mm distally to the tibial plateau, which corresponds to the tibial cut for total knee arthroplasty; and at the level of the ATT, which corresponds to proximal osteotomy of the tibia) was 9.54 mm (SD: 3.60), 6.59 mm (SD: 2.46) and 12.97 mm (SD: 2.74), respectively. Comparison according to sex showed that in the male patients, the distances between the popliteal artery and the posterior tibial cortex in the regions of the distal plateau and the ATT were greater than those in the

female patients. This means that even greater care needs to be taken when procedures are performed on female patients.

Pace and Wahl³⁴ analyzed knees from cadavers in order to study the posterior region of the knee and observed that the mean age of the specimens studied was 70 years. However, they reported that they did not know how this might change the anatomical relationships, in comparison with young individuals. Our study correlated the distances between the popliteal artery and the posterior tibial cortex in three anatomical regions of the knee joint with the patients' ages. Using a cutoff line of 36 years, the distances between the popliteal artery and the posterior tibial cortex in the regions 9 mm distally to the tibial plateau and at the level of the ATT showed that the greater the patient's age was, the greater this distance was $r_s = 0.258$; $p = 0.017$; and $r_s = 0.238$; $p = 0.017$, respectively.

Several studies have reported occurrences of iatrogenic neurovascular injuries in the popliteal fossa during arthroscopic reconstruction of the posterior cruciate ligament (PCL), which may have been caused by a guidewire or by a drill bit.^{35,36} Matava et al.³⁷ analyzed 14 knees from cadavers and showed that the popliteal artery was located posteriorly and laterally to the insertion of the PCL and anteriorly to the popliteal vein and sciatic nerve, in all the knees when extended (0° or 180°) and when flexed at 45° , 60° and 90° . Keser et al.²³ reported that at the level of the knee joint, the popliteal artery was located posteriorly to the insertion of the PCL in 19 cases (5.7%). This location may cause injury to the popliteal artery in cases of repair to or excision of the posterior cornu of the lateral meniscus, and also in procedures for PCL reconstruction. Ahn et al.³⁸ performed arthroscopic PCL reconstruction with slight release of the posterior capsule at the level of its insertion. Using angiography, they measured the distance between the tibial insertion of the PCL and the popliteal artery before and after capsule release. They found that the distance from the midpoint of the PCL to the popliteal artery became significantly greater after capsule release: from 4.4 ± 3.2 mm to 14.7 ± 4.1 mm. Cosgarea et al.³⁹ analyzed knees from cadavers and observed that the mean distance from the midpoint of the PCL to the popliteal artery was 29.1 ± 11 mm (range from 18 to 55 mm). Pace and Wahl³⁴ found that the mean distance from the PCL to the popliteal artery was 19 mm, with the knee flexed at 90° at the level of the joint line. In the present study, the means obtained from MRI showed that at the level of the knee joint, the mean distance between the popliteal artery and the posterior tibial cortex was 9.54 mm (range from 2.80 to 17.47 mm). It was also observed that in relation to sex, this distance at the level of the tibial plateau was significantly greater among males than among females (10.1 ± 3.5 mm and 8.8 ± 3.6 mm, respectively).

The incidence of vascular injury after total knee arthroplasty (TKA) is fortunately minimal (estimated at around 0.2%).^{9,40} In the present study, the distance between the popliteal artery and the posterior tibial cortex was analyzed in the region 9 mm distally to the tibial plateau, which is the location where, on average, the cut for placement of the tibial component is made in TKA procedures. Ninomiya et al.⁴¹ conducted a study on cadavers by means of MRI, in order to investigate the mechanism for popliteal artery injury during TKA, and observed that this artery was located laterally to

the tibial plateau in 95% of the specimens. Proximity to the posterior joint capsule makes the artery susceptible to injury during TKA. Takeda et al.⁴² emphasized the importance of greater care in positioning separators, with use of an oscillatory saw and osteotomes in the posterior region of the knee during TKA. They observed that along the arc of knee flexion, the positioning of the popliteal artery varied among individuals who had undergone TKA. Mureebe et al.⁴³ reported two cases of patients who presented injuries to the popliteal artery after TKA and required artery reconstruction surgery to save the limb. Our study demonstrated through MRI that the mean distance between the popliteal artery and the posterior tibial cortex in the region 9 mm distally to the tibial plateau was 6.59 mm (range from 3 to 12.70). This was the location at which the artery was closest to the posterior tibial cortex. We did not find any significant difference between the sexes regarding the distances measured between the popliteal artery and the posterior tibial cortex in the three regions of the proximal tibia that were evaluated. However, in relation to age group, the distance between the popliteal artery and the posterior tibial cortex in the region 9 mm distally to the tibial plateau was significantly greater in the age group over 36 years. This means that the greater the patient's age was ($p = 0.006$), the greater the distance between the popliteal artery and the posterior tibial cortex (age ≤ 36 years, 5.9 ± 2.2 mm and >36 years, 7.2 ± 2.5 mm).

Although rare, injury to the popliteal artery during proximal osteotomy of the tibia at the level of the anterior tuberosity may have devastating consequences. Osteotomy of the tibial tuberosity, which involves violation of the posterior tibial cortex using drill bits and screws, may give rise to injury to the popliteal artery.⁴⁴ Only a few studies in the literature have demonstrated direct injury to the popliteal artery during proximal osteotomy of the tibia.^{6,45} Zaidi et al.⁶ studied the positioning of the popliteal artery in 20 knees, by means of duplex ultrasonography at the level of the region in which the proximal osteotomy would be performed. In 12 knees (60%), the artery was located close to the tibia, with the knee flexed at 90° . Some studies have shown the presence of pseudoaneurysm subsequent to proximal tibial osteotomy.^{46,47} Kim et al.⁴⁸ reported that the popliteal artery became separated from the posterior tibial cortex when the knee was flexed at 90° . However, when the angle of the osteotomy cut was greater than 30° , in the coronal plane, it was seen that there could be a risk of injury to neurovascular structures. Smith et al.²⁴ studied nine volunteers by means of MRI, with the knee completely extended and flexed at 90° , and demonstrated that even with the knee flexed at 90° , this did not mean that the popliteal vessels were safe during the surgical procedure. Our study using MRI showed that at the level of the ATT, the mean distance was 12.97 mm and the range was from 7.61 mm to 19.31 mm. This was the location at which the artery was found to be furthest from the posterior tibial cortex. It was also observed that among males, the distance between the popliteal artery and the posterior tibial cortex at the level of the ATT was significantly greater (13.5 ± 2.5 mm and 12.3 ± 2.9 mm, respectively). In relation to age group, the distance between the popliteal artery and the posterior tibial cortex at the level of the ATT was significantly greater in patients over the age of 36 years. This means that the greater the age was, the more

distant from the posterior tibial cortex the popliteal artery was located.

The greatest limitation of our study was that the measurements on the three regions of the knee were only ascertained with the knee extended. There is major controversy in the literature regarding the extent to which knee flexion may increase the distance between the popliteal neurovascular structures and the posterior tibial cortex. Some authors have argued that in all regions of the knee, the distance between the popliteal artery and the posterior tibial cortex would increase with the knee flexed. However, other authors have maintained that even with the knee flexed, there would not be any change in the distance in the region 9mm from the tibial plateau (TKA level) or at the level of valgus osteotomy of the tibia.^{6,26,28,30}

Conclusion

Knowledge of the anatomical position of the popliteal artery, as demonstrated through MRI, is of great relevance in planning surgical procedures that involve the knee joint. Through this, devastating iatrogenic injuries can be avoided. Thus, procedures closer to the tibial plateau become more dangerous, particularly in young patients.

Conflicts of interest

The authors declare no conflicts of interest.

REFERENCES

- Megalopoulos A, Siminas S, Trelopoulos G. Traumatic pseudoaneurysm of the popliteal artery after blunt trauma: case report and a review of the literature. *Vasc Endovascular Surg*. 2006;40(6):499-504.
- Han KJ, Won YY, Khang SY. Pseudaneurysm after tibial nailing. *Clin Orthop Relat Res*. 2004;(418):209-12.
- Karkos CD, Thomson GJ, D'Souza SP, Prasad V. False aneurysm of the popliteal artery: a rare complication of total knee replacement. *Knee Surg Sports Traumatol Arthrosc*. 2000;8(1):53-5.
- Rubens F, Wellington JL, Bouchard AG. Popliteal artery injury after tibial osteotomy: a report of two cases. *Can J Surg*. 1990;33(4):294-7.
- Yoo JH, Chang CB, Lee TS, Seong SC, Kim TK. Delayed recurrent hemarthrosis after staple fixation of tibial avulsion fracture of the posterior cruciate ligament: a case report. *Knee Surg Sports Traumatol Arthrosc*. 2006;14(9):854-8.
- Zaidi SH, Cobb AG, Bentley G. Danger to the popliteal artery in high tibial osteotomy. *J Bone Joint Surg Br*. 1995;77(3):384-6.
- Aust JC, Bredenberg CE, Murray DG. Mechanisms of arterial injuries associated with total hip replacement. *Arch Surg*. 1981;116(3):345-9.
- Berger C, Anzbock W, Lange A, Winkler H, Klein G, Engel A. Arterial occlusion after total knee arthroplasty: successful management of an uncommon complication by percutaneous thrombus aspiration. *J Arthroplasty*. 2002;17(2):227-9.
- Calligaro KD, Delaurentis DA, Booth RE, Rothman RH, Savarese RP, Dougherty MJ. Acute arterial thrombosis associated with total knee arthroplasty. *J Vasc Surg*. 1994;20(6):927-32.
- Doi S, Motoyama Y, Itoh H. External iliac vein injury during total hip arthroplasty resulting in delayed shock. *Br J Anaesth*. 2005;94(6):866-L869.
- Lewallen DG. Neurovascular injury associated with hip arthroplasty. *Instr Course Lect*. 1998;47:275-83.
- Shoenfeld NA, Stuchin SA, Pearl R, Haveson S. The management of vascular injuries associated with total hip arthroplasty. *J Vasc Surg*. 1990;11(4):549-55.
- Calligaro KD, Dougherty MJ, Ryan S, Booth RE. Acute arterial complications associated with total hip and knee arthroplasty. *J Vasc Surg*. 2003;38(6):1170-7.
- Nachbur B, Meyer RP, Verkkala K, Zürcher R. The mechanisms of severe arterial injury in surgery of the hip joint. *Clin Orthop Relat Res*. 1979;(141):122-33.
- Rand JA. Vascular complications of total knee arthroplasty. Report of three cases. *J Arthroplasty*. 1987;2(2):89-93.
- Barrack RL, Butler RA. Avoidance and management of neurovascular injuries in total hip arthroplasty. *Instr Course Lect*. 2003;52:267-74.
- Barrack RL. Neurovascular injury: avoiding catastrophe. *J Arthroplasty*. 2004;19 4 Suppl. 1:104-L107.
- Smith DE, McGraw RW, Taylor DC, Masri BA. Arterial complications and total knee arthroplasty. *J Am Acad Orthop Surg*. 2001;9(4):253-7.
- Roth JH, Bray RC. Popliteal artery injury during anterior cruciate ligament reconstruction: brief report. *J Bone Joint Surg Br*. 1988;70(5):840-5.
- Potter D, Morris-Jones W. Popliteal artery injury complicating arthroscopic meniscectomy. *Arthroscopy*. 1995;11(6):723-6.
- Williams PL, Warwick R, editors. *Gray's anatomy*. Edinburgh: Churchill Livingstone; 1980.
- McMinn RM, editor. *Last's anatomy. Regional and applied*. 8th ed Edinburgh: Churchill Livingstone; 1990.
- Keser S, Savranlar A, Bayar A, Ulukent SC, Ozer T, Tuncay I. Anatomic localization of the popliteal artery at the level of the knee joint: a magnetic resonance imaging study. *Arthroscopy*. 2006;22(6):656-9.
- Smith PN, Gelinas J, Kennedy K, Thain L, Rorabeck CH, Bourne RB. Popliteal vessels in knee surgery. A magnetic resonance imaging study. *Clin Orthop Relat Res*. 1999;(367):158-64.
- Vernon P, Delattre JF, Johnson EJ, Palot JP, Clément C. Dynamic modifications of the popliteal arterial axis in the sagittal plane during flexion of the knee. *Surg Radiol Anat*. 1987;9(1):37-41.
- Farrington WJ, Charnley GJ, Harries SR, Fox BM, Sharp R, Hughes PM. The position of the popliteal artery in the arthritic knee. *J Arthroplasty*. 1999;14(7):800-2.
- Shetty AA, Tindall AJ, Qureshi F, Divekar M, Fernando KW. The effect of knee flexion on the popliteal artery and its surgical significance. *J Bone Joint Surg Br*. 2003;85(2):218-22.
- Coventry MB. Osteotomy about the knee for degenerative and rheumatoid arthritis. *J Bone Joint Surg Am*. 1973;55(1):23-48.
- Kramer D, Bahk M, Cascio B, Cosgarea AJ. Posterior knee arthroscopy: anatomy, technique, application. *J Bone Joint Surg Am*. 2006;88 Suppl. 4:110-21.
- Yang D, Zhou Y, Tang Q, Xu H, Yang X. Anatomical relationship between the proximal tibia and posterior neurovascular structures: a safe zone for surgeries involving the proximal tibia. *J Arthroplasty*. 2011;26(7):1123-7.
- Small NC. Complications in arthroscopy: the knee and other joints. *Arthroscopy*. 1986;2(4):253-8.
- Tawes RL, Etheridge SN, Webb RL, Enloe LJ, Stallone RJ. Popliteal artery injury complicating arthroscopic meniscectomy. *Am J Surg*. 1988;156(2):136-8.
- DeLee JC. Complications of arthroscopy and arthroscopic surgery: results of a national survey. *Arthroscopy*. 1985;1(4):214-20.

34. Pace J, Wahl C. Arthroscopy of the posterior knee compartments: neurovascular anatomic relationships during arthroscopic transverse capsulotomy. *Arthroscopy*. 2010;26(5):637-42.
35. Dunn PM, Post RH, Jones SR. Thromboembolic complications of knee arthroscopy. *West J Med*. 1984;140(2):291.
36. Simpson LA, Barrett JP. Facts associated with poor results following arthroscopic subcutaneous lateral release. *Clin Orthop Relat Res*. 1984;(186):165-71.
37. Matava MJ, Sethi NS, Totty WG. Proximity of the posteriorcruciate ligament insertion to the popliteal artery as a function of the knee flexion angle: implications for posterior cruciate ligament reconstruction. *Arthroscopy*. 2000;16(8):796-804.
38. Ahn JH, Wang JH, Lee SH, Yoo JC, Jeon WJ. Increasing the distance between the posterior cruciate ligament and the popliteal neurovascular bundle by a limited posterior capsular release during arthroscopic transtibial posterior cruciate ligament reconstruction: a cadaveric angiographic study. *Am J Sports Med*. 2007;35(5):787-92.
39. Cosgarea AJ, Kramer DE, Bahk MS, Totty WG, Matava MJ. Proximity of the popliteal artery to the PCL during simulated knee arthroscopy: implications for establishing the posterior trans-septal portal. *J Knee Surg*. 2006;19(3):181-5.
40. Kumar SN, Chapman JA, Rawlins I. Vascular injuries in total knee arthroplasty. A review of the problem with special reference to the possible effects of the tourniquet. *J Arthroplasty*. 1998;13(2):211-6.
41. Ninomiya JT, Dean JC, Goldberg VM. Injury to the popliteal artery and its anatomic location in total knee arthroplasty. *J Arthroplasty*. 1999;14(7):803-9.
42. Takeda M, Ishii Y, Noguchi H, Sato J. Change in the position of the popliteal artery with knee flexion after total knee arthroplasty. *J Bone Joint Surg Am*. 2011;93(21):e1231-6.
43. Mureebe L, Gahtan V, Kahn MB, Kerstein MD, Roberts AB. Popliteal artery injury after total knee arthroplasty. *Am Surg*. 1996;62(5):366-8.
44. Shetty AA, Tindal AJ, Nickolaou N, James KD, Ignotus P. A safe zone for the passage of screws through the posterior tibial cortex in tibial tubercle transfer. *Knee*. 2005;12(2):99-101.
45. Insall J. *Surgery of the knee*. Edinburgh: Churchill Livingstone; 1984.
46. Rubens F, Wellington JL, Bouchard AG. Popliteal artery injury in tibial osteotomy: report of two cases. *Can J Surg*. 1990;33(4):294-7.
47. Han K, Won Y, Khang S. Pseudaneurysm after tibial nailing. *Clin Orthop Relat Res*. 2004;(418):209-12.
48. Kim J, Allaire R, Harner CD. Vascular safety during high tibial osteotomy: a cadaveric angiographic study. *Am J Sports Med*. 2010;38(4):810-5.