



Case report

Experience of a Brazilian surgeon in a hand transplant case: “What I saw, what I learned”^{☆,☆☆}

João Bosco Rezende Panattoni Filho^a, Tsu-Min Tsai^b, Huey Tien^b, Joseph Kutz^{b,*}

^a Department of Orthopaedic Surgery, Saint Louis University, St. Louis, USA

^b Kleinert Kutz Hand Care Center, Christine M. Kleinert Institute for Hand and Microsurgery, Louisville, Kentucky, USA

ARTICLE INFO

Article history:

Received 30 August 2012

Accepted 9 November 2012

Keywords:

Amputation

Hand

Therapy

Transplantation

ABSTRACT

The Louisville VCA (Vascularized Composite Allograft) Program is one of the largest hand transplant programs in the world. During my hand surgery fellowship at the Christine M. Kleinert Institute, the team performed the eighth hand transplant on the seventh recipient in Louisville. The Louisville VCA Program has done 9 hand transplants in 8 recipients with one bilateral case. Among these are the first 5 hand transplant cases in the United States. The first case was done in 1999 and has the World's longest follow-up. The seventh case was performed in a 36-year-old male on July 10, 2011. The result achieved so far can be considered excellent with a very good patient satisfaction. There is a large multidisciplinary team involved in such procedures with all members playing a crucial role for the achievement of the best result possible. The present paper focuses on the surgical procedure for the seventh recipient, which was unique due to the level of amputation of the recipient's hand, with preservation of nerve to the thumb.

© 2013 Sociedade Brasileira de Ortopedia e Traumatologia. Published by Elsevier Editora Ltda. All rights reserved.

Experiência de um cirurgião brasileiro em cirurgia de transplante de mão: “O que vi, o que aprendi”

RESUMO

O Programa de Enxerto Alográfico Vascularizado Composto (Vascularized Composite Allograft ou VCA Program) de Louisville é um dos maiores de transplante de mão no mundo. Durante o meu *fellowship* em cirurgia da mão no Christine M. Kleinert Institute, o grupo fez o oitavo transplante de mão no sétimo receptor em Louisville. O VCA Program de Louisville já fez nove transplantes de mão em oito receptores (um caso bilateral). Entre esses estão os primeiros cinco casos de transplante de mão nos Estados Unidos da América. O primeiro foi feito em 1999, o que teve o mais longo seguimento em todo o mundo. O sétimo caso foi feito em um paciente do sexo masculino de 36 anos em 10 de julho de 2011. O resultado

Palavras-chave:

Amputação

Mãos

Terapia

Transplante

[☆] Please cite this article as: Panattoni Filho JBR, Tsai T-M, Tien H, Kutz J. Experiência de um cirurgião brasileiro em cirurgia de transplante de mão: “O que vi, o que aprendi”. Rev Bras Ortop. 2013;48:567-573.

^{☆☆} Work performed at the Christine M. Kleinert Institute for Hand and Microsurgery, Louisville, Kentucky, USA.

* Corresponding author.

E-mail: jbrpf@hotmail.com (J. Kutz).

obtido até agora pode ser considerado excelente, com ótimo benefício para o paciente. Em um procedimento como esse, existe uma grande equipe multidisciplinar envolvida, cada um tem uma função crucial para o alcance do melhor resultado possível. O presente artigo será focado no procedimento cirúrgico feito no sétimo receptor, que foi considerado um caso especial, por causa do nível da amputação da mão do paciente, com preservação do nervo para o polegar.

© 2013 Sociedade Brasileira de Ortopedia e Traumatologia. Publicado por Elsevier Editora Ltda. Todos os direitos reservados.

Introduction

Transplantation has a great future in the field of hand surgery and reconstructive microsurgery. So far, 72 hand transplants have been performed on a total of 51 patients around the world (30 patients had one hand transplanted and 21 had both transplanted) (www.handregistry.com).

Hand transplantation surgery is still considered to be an experimental procedure but is a rapidly expanding type of treatment. It is now performed successfully in more than a dozen specialized centers worldwide¹ and in five centers in the United States.²

The postoperative results are very promising, with good patient satisfaction, especially because of recovery of good function in the transplanted hand. The main advantages of hand transplantation, in comparison with a prosthesis, are the recovery of sensitivity, the cosmetic aspect and the "heat" of the transplanted hand.³

The first case of hand transplantation performed in the modern era of immunosuppression was in France in 1998. The transplanted hand had to be amputated two years later, after the patient decided to stop taking immunosuppressant drugs.⁴

Less than a year later, the Louisville VCA (Vascularized Composite Allograft) Program performed the first hand transplantation in the United States, in January 1999. The recipient continues to be well to the present day, with good recovery of function in the transplanted hand. The long-term functional result exceeded the initial expectations.⁵

The Louisville VCA Program is a collaboration between the surgeons and teams of Kleinert Kutz Hand Care Center, Jewish Hospital (now part of Kentucky One Health), Christine M. Kleinert Institute and the University of Louisville. The group has now performed hand transplantation surgery on eight patients (one bilateral case) and has had to deal with complications such as hip osteonecrosis, diabetes (due to use of steroids) and one case of graft loss nine months after the transplantation, due to vasculopathy.⁶ Despite these problems, seven of the eight patients continue to be very well. Even the patient who lost the graft wishes to undergo a second transplantation. Complications relating to immunosuppression have been controlled up to the present day.

In the future, it can be expected that more and more centers will start to perform hand transplantation surgery, and that this procedure will cease to be experimental and will become standard. Moreover, with the economic growth that Brazil is undergoing, we believe that it is important for surgery of this type to be performed in this country, which would make

Brazil the location for the first hand transplantation in South America.

It is important to emphasize that hand transplantation is a procedure that depends largely on a multidisciplinary team for a favorable result to be obtained. This team is composed of hand surgeons, transplantation surgeons, psychiatrists, social workers, occupational therapists, nurses, immunologists and coordinators. However, the present article focuses on the surgical technique used in the case of patient number seven and how the team was organized at the surgical center. Information on the immunosuppression therapy (required for the rest of the patient's life) and the postoperative occupational therapy protocol will be discussed in a separate article.

The seventh Louisville patient received his hand transplant on July 10, 2011. The recipient was a 36-year-old man who had suffered an industrial accident on March 9, 1998. In the accident, both of his arms became trapped in a press (chopping machine). His right hand (dominant hand) was crushed and his left hand was partially amputated, distally to the wrist. The patient was left with part of his left thumb and left wrist with adequate movement (Fig. 1). The right hand suffered sequelae of muscle hypotrophy because of injury to the ulnar nerve, but amputation was not required.

The surgical team was composed of 16 surgeons (seven chiefs and nine fellows). One of the chiefs (Dr. Kutz) was the leading surgeon: he followed up every step of the procedure and also organized how the surgical teams would rotate. The first author, Dr. João Panattoni, from Campinas (SP), Brazil, was present and participated in the procedures as one of the senior fellows.

The anesthesia team was composed of one anesthetist and one nurse who was an anesthesia specialist. General anesthesia was induced, with additional regional brachial plexus block, for greater vasodilatation and postoperative pain control. The nursing team comprised three nurses and two instrument technicians.

At the start of the operation, two surgical teams worked concomitantly in the same surgical room. The team working on the recipient started first, while the second team harvested the limb from the donor. Efficient communication between the teams is important, in order to ensure that the limb from the donor is in a good condition before anesthesia is induced and surgery is performed on the recipient.

Surgical technique

The surgical steps are divided into chronological order. For better comprehension, they are also divided according to anatomical structure.

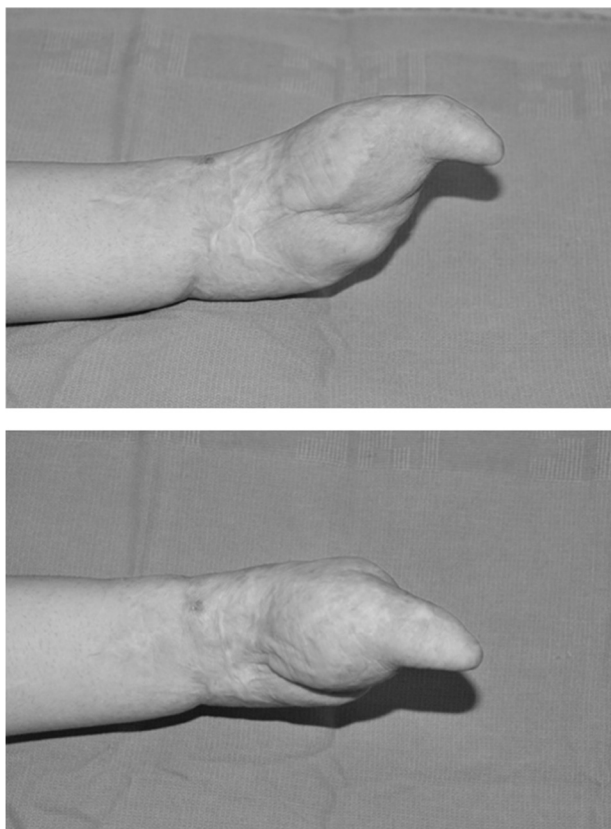


Figure 1 – Preoperative appearance.
Source: Christine M. Kleinert Institute.

Limb harvesting

With the aim of reducing the duration of hot ischemia, harvesting and transportation of the limb from the donor were done as quickly as possible. When possible, the hand harvesting team goes in first and uses a tourniquet to remove the hand or hands before cross-clamping and organ harvesting are performed on the donor.

The brachial artery was identified and protected and the limb was amputated at the elbow joint. Preservation solution (University of Wisconsin solution) at 4 degrees Celsius was infused into the brachial artery and the open area was kept moist using compresses soaked in physiological serum. The limb was then placed in an insulated plastic bag, which was then placed in an insulated box with ice. When the limb arrived at the surgical center, where the recipient was, infusion of preservation solution was stopped and the entire procedure was performed with the transplant piece kept at 0-4 degrees Celsius (ice bags inside sterile gloves) (Fig. 2).

Surgical incision

While the graft from the donor was being prepared on the surgical table, the skin of the donor was raised by means of two incisions: one medially and one laterally. A delicate dissection was performed in order to identify the structures. Depending on the type of injury presented by the recipient, the skin may

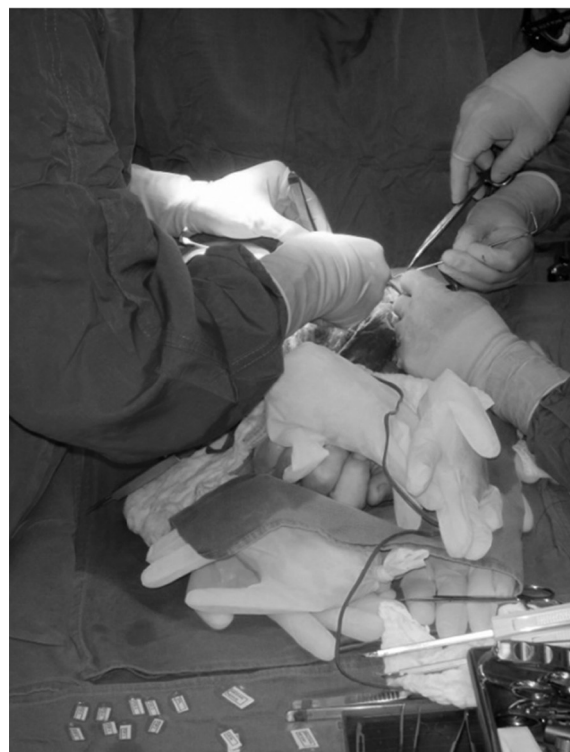
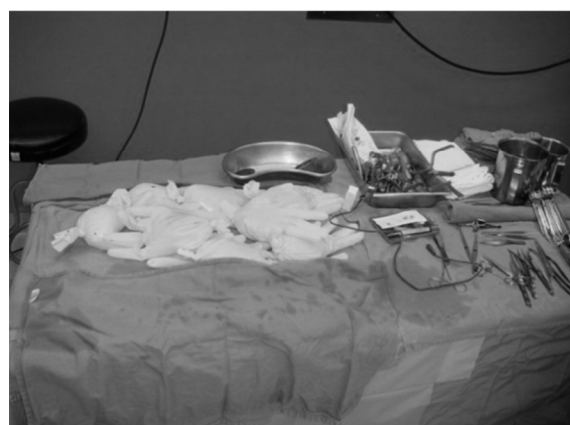

Figure 2 – Maintenance of the limb in ice while the structures were being identified.
Source: Christine M. Kleinert Institute.

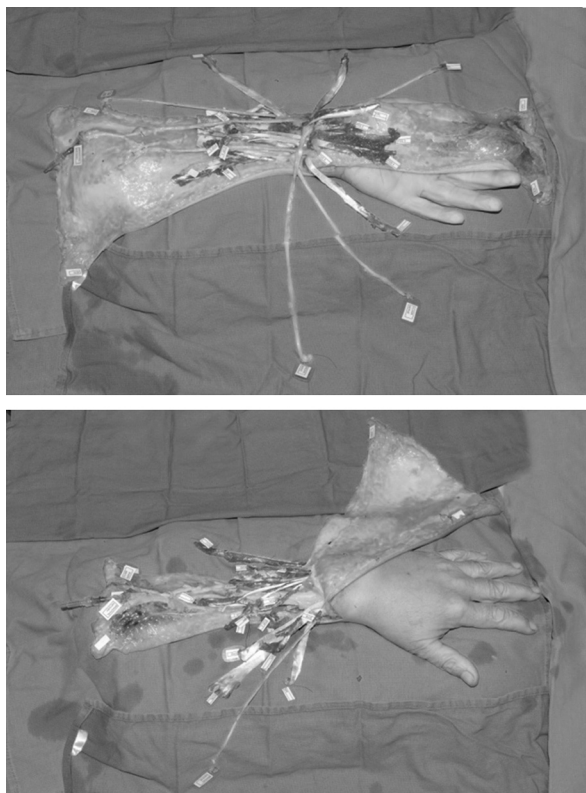


Figure 3 – Identification and labeling of the structures.
Source: Christine M. Kleinert Institute.

be raised so as to form an interposition flap with four stitches (two on the donor and two on the recipient).⁷

One very important initial step was to identify the structures by stitching labels onto them. This is a very valid investment of surgical time, since it makes the procedure less confusing after the limb has been connected by the bone. A good way to do this is have two sets of sterile plasticated labels (one for the donor and one for the recipient) with all the names of the structures (tendons, nerves and vessels) (Fig. 3).

However, depending on the recipient's original injury that caused the amputation, identifying the structures may be very challenging, which may cause confusion and lead to delayed dissection. This is particularly so in cases of patients who are victims of burns or injuries caused by explosives. In our case, delicate exploration of the structures was done, with special attention to preservation of the vessels (volar and dorsal vessels), which potentially could be used in anastomoses.

Bone

The bone needs to be stabilized rapidly and efficiently. Bone fixation was done after finishing identifying all the structures. If the time limit for the tourniquet is approaching, it can be released after good exposure of the bone has been achieved, and the plate is then applied with the tourniquet deflated.

A pediatric nasogastric cannula can be used to connect the recipient's artery to the donated limb, so as to enable greater time for performing bone fixation. In the seventh Louisville case, this was not done because bone fixation was completed

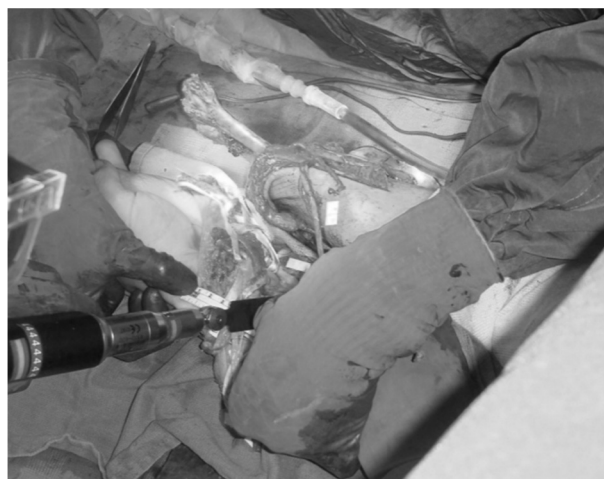


Figure 4 – Measurement of the osteotomy location.
Source: Christine M. Kleinert Institute.

within a good time and the team judged that a shunt was unnecessary.

A microsaw was used to cut the bone transversally in the recipient and in the donor. One advantage in this patient was that he still had his wrist joint. This greatly facilitated the measurements: 6 cm was subtracted from the recipient and the same length was obtained in the part of the donor limb that was to be connected (Fig. 4). In cases in which the patient has lost part of the forearm, careful measurements are made based on the contralateral forearm and elbow joint before proceeding with osteotomy. It is important to note that the idea of cutting one forearm bone at a time does not work well. It is preferable to cut the radius and ulna on both limbs and then perform bone fixation. Another option is to place the plate on the donor before performing the osteotomy, but this was not done on the seventh Louisville case.

A 3.5 mm plate (Low Contact-Dynamic Compression Locking Plate, Synthes) was used for both bones.⁸ In cases of transplantation more distally, a 2.7 mm plate for the distal ulna and radius can be used. A mini-image intensifier was used throughout our procedure, in order to check for adequate plate positioning and bone reduction.

Vessel 1

Just after the bone fixation, anastomosis was performed on the artery so that the limb could be perfused as quickly as possible. This was done with the aim of diminishing the duration of ischemia and hence tissue necrosis and fibrosis.⁹ Careful dissection was performed with the tourniquet inflated, and the radial and ulnar arteries were located. The arteries were separated from their venae comitantes by means of a surgical microscope. The venae comitantes need to be delicately preserved, because they will be used. After the first artery (preferably the dominant one) had been finished, the tourniquet was deflated. Shortly after releasing the tourniquet, 3000 UI of heparin was infused in an endovenous bolus, followed by infusion of 5000 UI of heparin diluted in 500 mL of Ringer

lactate, in an infusion pump at 20 mL/h. Dextran was not used, either during or after the procedure.

The first artery done was the ulnar. The technique used was “back wall first”, with 8-0 monofilament suturing (Ethilon). The vena comitante was then done using 9-0 suturing (Ethilon), by means of the same technique.

The team’s opinion was that once the tourniquet had been released after arterial anastomosis had been performed, it could not be inflated again, since this could put the anastomosis at risk through formation of thrombi. From that time onwards, the limb was kept warmed, with damp compresses, and was intermittently irrigated with warmed physiological serum.

After the anastomosis of the first artery had been completed, it was important to allow some bleeding of the limb for around 15 min, so as to “wash out” the potentially toxic preservation solution that had been infused during harvesting. During this waiting time, the ulnar nerve was sutured under magnification using a surgical microscope, using 8-0 suturing thread (Ethilon), without using fibrin glue. Lastly, the radial artery and its vena comitante were anastomosed using the same technique and same size of suturing thread as that used for the ulnar artery and its vena comitante. The largest of the venae comitantes was used for each artery (radial and ulnar), at the distal level of the forearm. The venae comitantes should not be relied on alone for venous drainage, but they certainly help prevent congestion.

It was important to take care regarding wrist positioning during the anastomosis. Given that, up to that point, no tendons had been repaired, the wrist could easily have been left in a hyperextended position, thereby causing the anastomosis to be redundant, with the risk of kinking.

At this moment, the microscope was removed and the tendon repairs were started. Special attention was given to the patient’s vital signs, especially considering that the dorsal veins (which had not yet been anastomosed) could be potential sites of major blood loss. It is preferable to maintain the patient’s arterial blood pressure higher than 100 × 60 mmHg and the temperature of the operating theater above 25 °C.

Tendon

The flexor and extensor tendons were connected by means of the Pulvertaft technique.¹⁰ All the tendons were repaired proximally to the retinaculum, in order to avoid limitations of mobility and “bowstring” deformity. An interwoven connection was stabilized using X-format sutures with Tycron 4.0 thread (Fig. 5). Since immediate aggressive postoperative therapy was envisaged, the suturing was reinforced using Fiberloop 4.0 thread (Arthrex), similarly to the Becker technique.¹¹ Calibration of the tendons may be difficult and, here, the assistant’s role is important for maintaining adequate tension in the tendons and correctly positioning them on the fingers and wrist.

The extensor tendons were connected after finishing the nerve anastomoses (see below). Just like with the flexors, the same Pulvertaft technique with Becker reinforcement was used for the extensor tendons.^{10,11}

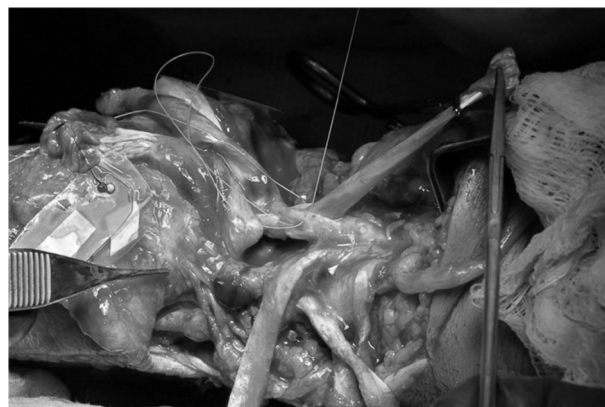

Figure 5 – Pulvertaft technique on the extensor tendon.
Source: Christine M. Kleinert Institute.

Nerve

The median nerve was anastomosed after connecting the flexor tendons. For this patient, one advantage was that he still had part of this thumb. Therefore, it was sought to maintain the maximum length of median nerve possible in the recipient. The motor branch was anastomosed very close to the thenar muscles (target muscles), so as to enable rapid reinnervation. Microscopic surgery was used for this procedure, which was done using 9-0 monofilament suturing thread (Ethilon).

As mentioned earlier, the ulnar nerve was repaired just after performing the first arterial anastomosis, while waiting for the preservation solution to be “washed out”. Following this, the volar skin was brought together without tensioning it and, in order to protect the recently repaired vessels, the forearm was pronated. A dorsal-radial access enabled anastomosis of the sensory branch of the radial nerve, which was done using suturing thread of size 9-0 (Ethilon). The extensor tendons were then connected.

Vessel 2

As many venous anastomoses as possible should be performed, in order to prevent graft congestion. After finishing the extensor tendons, attention was given to repairing the veins. This may be one of the biggest challenges of the hand transplantation procedure. The condition of the recipient and the mechanism of the original injury will define how difficult this part of the operation will be.

At this time, skin flaps were developed. The incisions for the skin flaps were made carefully, so as to preserve as many veins as possible, even the small subcutaneous veins. The veins that potentially could be used were marked with vascular clips.

It is preferable to perform repair on a major vein in the forearm (basilic or cephalic vein). In addition, repairs on one or two additional veins should be attempted. If necessary, an end-to-side anastomosis on a large-diameter vein in the forearm should be performed. Specifically for the seventh Louisville patient, a small subcutaneous volar vein was anastomosed in addition to the ones mentioned above, in order to prevent

congestion of the volar flap in the donor limb. In the end, six venous anastomoses were performed (two venae comitantes, the cephalic vein, two dorsal veins and one subcutaneous volar vein).

All the venous anastomoses were performed under magnification using a surgical microscope, using the “back wall first” technique and monofilament suturing thread (Ethilon). As stated earlier, the venae comitantes were anastomosed using 9-0 suturing thread. Because of the smaller size of the subcutaneous veins, 10-0 suturing thread had to be used. For the cephalic vein, 8-0 suturing thread was good enough.

Lastly, the skin was closed carefully in order to protect the recently anastomosed veins. Non-compressive dressings were applied with gauze, sterile colon wool and a plaster-cast splint extending from the axilla to the palm of the hand.

The operation took 14.5 h and there were no intraoperative complications. There were no signs of arterial insufficiency or venous congestion after the operation and therefore the patient did not have to be taken back to the surgical center (Fig. 6).

Postoperative care

The patient tolerated the operative procedure well and, after post-anesthesia recovery, was taken to the ward. The room was kept heated (at least 25 degrees Celsius). The flap was monitored through observations on its color, capillary perfusion in the fingers and temperature. The interval between checks was hourly on the first postoperative day and spaced out on subsequent days. Furthermore, an oximeter was placed on one of the fingers of the transplanted limb, with control done on the contralateral side.¹²

The patient was kept in hospital for 14 days after the operation, in order to control the pain and continue with the immunosuppressant medication. The occupational therapy service started its work with the patient while he was still in the hospital. The first change of dressings was performed three days after the operation.

Discussion

The possibility of observing and participating in hand transplantation surgery is a rare event and was a special feature of the hand surgery fellowship program at the Christine M. Kleinert Institute. The seventh patient to receive a transplant (eighth transplanted limb) at this center can be considered to have been a great success. Patient selection certainly had an important role in this result. The patient was well-motivated and disciplined. Moreover, the amputation level can also be considered to have been an advantage. Since the transplantation was done at wrist level, the recipient's nerves were kept as long as possible. In addition, the amputation level facilitated the bone work and enabled faster recovery of motor function.

One key component in the success of the Louisville group is the availability of a large group of well-trained specialized surgeons. This enabled rotation during the procedure, so as always to have a surgeon resting for a different part of the surgery. Another advantage is that a surgeon

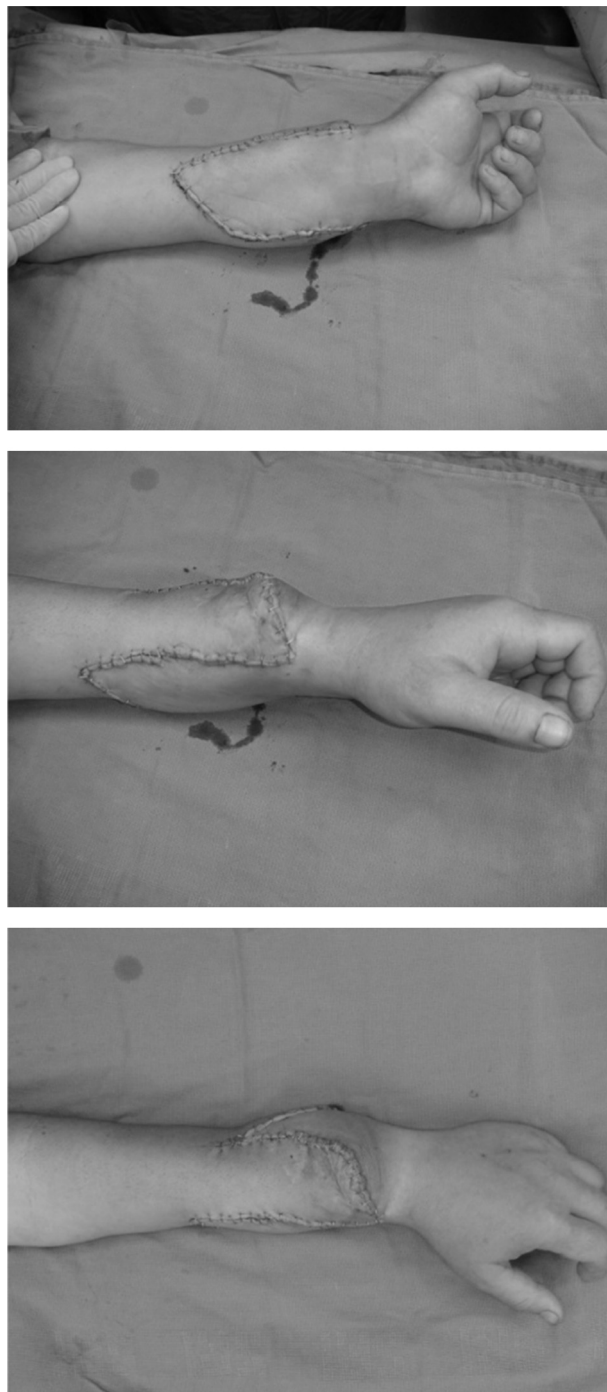

Figure 6 – Immediate postoperative result.
Source: Christine M. Kleinert Institute.

who was more specialized and had an interest in a certain stage of the operation could perform his part and leave another surgeon to continue with the next step of the surgery.

It is also important to mention the role of the leader. He was responsible for coordinating all the teams and for the rotation between them. An experienced leading surgeon was crucial in this procedure with so many details, in which a poorly made decision could have compromised the result or even

the success of the surgery. Being the leader was certainly a very difficult task, since he needed to be present throughout the procedure, which would not necessarily apply to the other surgeons.

Conclusion

Hand transplantation surgery produces very promising results. Therefore, it can be expected that this procedure will start to be performed more and more often around the world.

With regard to the surgical technique, it is important to be attentive to refinements and technical advances of the surgical procedure and make a critical analysis in order to assess whether a given surgical service/country has the conditions required to perform it.

With the current economic growth of the Brazilian economy, the chances that this will be the location for the first hand transplantation in South America are becoming greater.

Funding

The present article was based on work that was partly funded by the Medical Research Department of the United States Army, through funds W81XWH-07-2-0092 and W81XWH-07-1-0185, and by the Navy Research Department, through fund N000140610084. The opinions, interpretations, conclusions and recommendations are those of the authors and do not necessarily represent those of the United States Army and Navy.

Conflicts of interest

The authors declare no conflicts of interest.

REFERENCES

1. Petruzzo P, Lanzetta M, Dubernard JM, Margreiter R, Schuind F, Breidenbach W, et al. The international registry on hand and composite tissue transplantation. *Transplantation*. 2008;86(4):487-92.
2. Ravindra KV, Gorantla VS. Development of an upper extremity transplant program. *Hand Clin*. 2011;27(4):531-8.
3. Kaufman CL, Blair B, Murphy E, Breidenbach WB. A new option for amputees: transplantation of the hand. *J Rehabil Res Dev*. 2009;46(3):395-404.
4. Dubernard JM, Owen E, Herzberg G, Lanzetta M, Martin X, Kapila H, et al. Human hand allograft: report on first 6 months. *Lancet*. 1999;353(9161):1315-20.
5. Jones JW, Gruber SA, Barker JH, Breidenbach WC. Successful hand transplantation. One year follow up. Louisville Hand Transplant Team. *N Engl J Med*. 2000;343(7):468-73.
6. Kaufman CL, Ouseph R, Blair BW, Kutz JE, Tsai TM, Scheker LR, et al. Graft vasculopathy in clinical hand transplantation. *Am J Transplant*. 2012;12(4):1004-16.
7. Hartzell TL, Benhaim P, Imbriglia JE, Shores JT, Goitz RJ, Balk M, et al. Surgical and technical aspects of hand transplantation: is it just another replant? *Hand Clin*. 2011;27(4):521-30.
8. Cavadas PC, Landin L, Ibanez J. Bilateral hand transplantation: result at 20 months. *J Hand Surg Eur Vol*. 2009;34(4):434-43.
9. Landin L, Cavadas PC, Garcia-Cosmes P, Thione A, Vera-Sempere F. Perioperative ischemic injury and fibrotic degeneration of muscle in a forearm allograft: functional follow-up at 32 months post transplantation. *Ann Plast Surg*. 2011;66(2):202-9.
10. Bidic SM, Varshney A, Ruff MD, Orestein HH. Biomechanical comparison between lasso, Pulvertaft weave, and side-by-side tendon repairs. *Plast Reconstr Surg*. 2009;124(2):567-71.
11. Chung KC, Jun BJ, McGarry MH, Lee TQ. The effect of the number of cross-stitches on the biomechanical properties of the modified Becker extensor tendon repair. *J Hand Surg Am*. 2012;37(2):231-6.
12. Chang J, Jones NF. Twelve simple maneuvers to optimize digital replantation and revascularization. *Tech Hand Up Extreme Surg*. 2004;8(3):161-6.