



Original Article

Prevalence of femoroacetabular impingement morphology in asymptomatic youth soccer players: magnetic resonance imaging study with clinical correlation[☆]



Anthony Kerbes Yépez^{a,*}, Marcelo Abreu^b, Bruno Germani^a, Carlos Roberto Galia^c

^a Santa Casa de Porto Alegre, Departamento de Cirurgia Ortopédica, Porto Alegre, RS, Brazil

^b Hospital Mãe de Deus, Departamento de Radiologia, Porto Alegre, RS, Brazil

^c Universidade Federal do Rio Grande do Sul, Hospital de Clínicas de Porto Alegre (HCPA), Departamento de Cirurgia Ortopédica, Porto Alegre, RS, Brazil

ARTICLE INFO

Article history:

Received 30 November 2016

Accepted 26 January 2017

Available online 24 June 2017

Keywords:

Femoroacetabular impingement

Hip joint

Soccer

Magnetic resonance imaging

ABSTRACT

Objective: To determine the prevalence of femoroacetabular impingement morphology (FAIM), cam- or pincer-type, by magnetic resonance imaging (MRI) in asymptomatic adolescent soccer players, and to evaluate the possible correlation between alterations on MRI and clinical examination findings.

Methods: A cross-sectional study was conducted to determine the prevalence of FAIM in asymptomatic youth soccer players aged 13–18 years. A total of 112 hips in 56 players (mean age 15.3 years) were evaluated by MRI. Images were examined by two musculoskeletal radiologists for signs of FAIM. Cam-type (impingement) deformity was diagnosed by alpha angle $\geq 55^\circ$ or head-neck offset < 7 mm. Pincer-type (impingement) deformity was diagnosed by center-edge angle (CEA) $\geq 35^\circ$ or acetabular index $\leq 0^\circ$. Other MRI changes, characteristic of FAIM, were observed. Clinical examination was performed to determine the range of motion (ROM) of the hips. In addition, specific tests for anterolateral and posteroinferior impingement were performed.

Results: The prevalence of MRI findings consistent with FAIM among this young population was 84.8% (95/112). The alpha angle was $\geq 55^\circ$ in 77.7% (87/112) of hips, while the CEA was altered in 10.7% (12/112) of hips. Qualitative MRI findings consistent with FAIM were highly prevalent, and included loss of sphericity of the femoral head (77%), osseous bump (44%), femoral neck edema (21%), and acetabular osteitis (9%). The anterior impingement test was positive in 15% of the hips evaluated.

[☆] Study conducted at the Universidade Federal do Rio Grande do Sul, Faculdade de Medicina, Hospital de Clínicas de Porto Alegre (HCPA), Department of Orthopedic Surgery, Porto Alegre, RS, Brazil.

* Corresponding author.

E-mail: akyeppez@hotmail.com (A.K. Yépez).

<http://dx.doi.org/10.1016/j.rboe.2017.06.005>

2255-4971/© 2017 Published by Elsevier Editora Ltda. on behalf of Sociedade Brasileira de Ortopedia e Traumatologia. This is an open access article under the CC BY-NC-ND license (<http://creativecommons.org/licenses/by-nc-nd/4.0/>).

Conclusion: Youth soccer players have a high prevalence of FAIM as diagnosed by MRI. There is no correlation between physical examination findings and MRI evidence of FAIM in this population.

© 2017 Published by Elsevier Editora Ltda. on behalf of Sociedade Brasileira de Ortopedia e Traumatologia. This is an open access article under the CC BY-NC-ND license (<http://creativecommons.org/licenses/by-nc-nd/4.0/>).

Prevalência da morfologia de impacto femoroacetabular em jogadores de futebol juvenil assintomáticos: estudo de ressonância magnética com correlação clínica

R E S U M O

Palavras-chave:

Impacto femoroacetabular
Articulação do quadril
Futebol
Ressonância magnética

Objetivo: Determinar a prevalência da morfologia de impacto femoroacetabular (MIFA), tipo cam ou pincer, por ressonância magnética (RM) em jogadores de futebol adolescentes e assintomáticos, bem como avaliar a possível correlação entre as alterações observadas na RM e os achados do exame clínico.

Métodos: Este estudo transversal teve como objetivo determinar a prevalência de MIFA em jogadores de futebol juvenil assintomáticos, com idade entre 13 e 18 anos. Um total de 112 quadris de 56 jogadores (idade média 15,3 anos). As imagens foram examinadas por dois radiologistas musculoesqueléticos, com o objetivo de identificar sinais de MIFA. A deformidade (impacto) do tipo cam foi diagnosticada quando o ângulo alfa $\geq 55^\circ$ ou desvio entre a cabeça e o colo femoral <7 mm. A deformidade (impacto) do tipo pincer foi diagnosticada quando o ângulo centro-borda (ACB) $\geq 35^\circ$ ou índice acetabular $\leq 0^\circ$. Outras alterações características de MIFA foram observadas na RM. A amplitude de movimento (ADM) dos quadris foi determinada a partir de um exame clínico. Além disso, foram realizados testes específicos para impactos anterolaterais e posteroinferiores.

Resultados: A prevalência de achados de RM consistentes com MIFA nessa população foi de 84,8% (95/112). O ângulo alfa foi $\geq 55^\circ$ em 77,7% (87/112) dos quadris, enquanto o ACB apresentou alterações em 10,7% (12/112) de quadris. Observou-se uma alta prevalência de achados qualitativos de RM consistentes com MIFA, incluindo perda de esfericidade da cabeça femoral (77%), elevação óssea (44%), edema femoral (21%), e osteíte acetabular (9%). O teste de impacto anterior foi positivo em 15% dos quadris avaliados.

Conclusão: Os exames de RM indicaram uma alta prevalência de MIFA entre jogadores de futebol juvenil. Nesta população, não houve correlação entre os achados do exame físico e a evidência de MIFA observada na RM.

© 2017 Publicado por Elsevier Editora Ltda. em nome de Sociedade Brasileira de Ortopedia e Traumatologia. Este é um artigo Open Access sob uma licença CC BY-NC-ND (<http://creativecommons.org/licenses/by-nc-nd/4.0/>).

Introduction

Femoroacetabular impingement (FAI) is a condition resulting from abnormal contact between the femoral head and the acetabular rim, usually caused by a change in morphology of the proximal femur and/or acetabulum.^{1–4} Ganz et al.² described two basic mechanisms of FAI: cam and pincer. The cam mechanism occurs in patients with a non-spherical femoral head or with a decreased offset between the head and neck of femur. The impingement area is typically located on the anterolateral portion of the femoral head–neck junction. Pincer impingement, in turn, is characterized by acetabular overcoverage caused by an excess of the anterior wall.^{1,2,4,5}

FAI may decrease the range of motion (ROM) of the hip, especially in internal rotation (IR) of the flexed hip.^{2,6} FAI is described as a cause of hip pain exacerbated by physical activity, and occurs mainly in young adult patients.^{4,5} Clinical

symptoms usually do not appear until adulthood; however, detection of FAIM is becoming increasingly common in the pediatric population.⁷ Patients often develop cartilage lesions and injury to the acetabular labrum, which can progress to hip osteoarthritis (OA) if the anatomic changes are not treated or the physical activity modified.^{2,8–10}

Adolescent patients who practice sports often perform high-impact activities that require extreme movements of the hip, which may predispose to more frequent and more intense conflicts between the proximal femur and the acetabulum.¹¹

Physical activity during bone growth seems to be associated with an increased risk of cam-type deformity. Siebenrock et al. suggested that cam impingement in young athletes may be related to an abnormality in the physeal plate. Studies in high-performance adolescent basketball and hockey players found a high incidence of cam type FAI.^{3,12}

The purpose of this study was to determine the prevalence of FAIM (both cam and pincer type) in asymptomatic youth

soccer players as diagnosed by magnetic resonance imaging (MRI) findings. Patients also underwent a clinical evaluation of the hip joints to ascertain possible correlations between changes on MRI and clinical signs of FAI.

Materials and methods

Demographics

From July 2012 to July 2013, 56 athletes from a first-division Brazilian youth soccer team were selected to participate in the study. They practice soccer in competition level, training a mean of five hours per day. All athletes were aged 13–18 years and did not have any symptoms of hip pathology. The dominant side of each athlete was identified. The exclusion criteria for this study were any history of treatment for pain related to the hip joint and contraindications or intolerance to MRI.

Written informed consent was obtained from all athletes and from the parents or guardians of athletes under 18 years old. The informed consent form was approved by the local institutional review board.

Magnetic resonance imaging evaluation

MRI was performed in a 1.5-T scanner using the following parameters: panoramic T1 coronal sequences including both hips (echo times of 10–14 ms and repeat times between 400 and 600 ms) and T2 (echo times of 35–70 ms and repeat times between 2000 and 3500 ms), with a slice thickness of 5 mm and 512×256 line matrix with a field of view of 33–36 cm; T2 sequences focused on the hip joints, with and without fat saturation in the coronal, sagittal, and oblique axial slices, with a thickness of 4 mm and a 384×224 line matrix with a field of view of 22–25 cm.

Based on the radiographic appearance of the capital femoral physis on MRI, participants were stratified into those with open physeal plates and those with closed physeal plates.

Cam morphology was evaluated by measuring the alpha angle and femoral head–neck offset. The alpha angle was measured on an oblique axial sequence as described elsewhere in the literature. Participants with an alpha angle $\geq 55^\circ$ were diagnosed with cam morphology^{13,14} (Fig. 1).

The femoral head–neck offset was measured by drawing a line in the center of the femoral head and neck and two parallel lines, one along the anterior cortex of the femoral neck and the other along the anterior outer part of the femoral head. The distance between the second and third lines corresponds to the head–neck offset, and, when less than 7 mm, is indicative of cam deformity¹⁵ (Fig. 2).

The diagnosis of pincer morphology was established by measuring the center-edge angle (CEA), or Wiberg angle, and the acetabular index (AI), or Tönnis angle. A CEA $\geq 39^\circ$ or AI $\leq 0^\circ$ indicates pincer deformity. The CEA was measured on the coronal plane, between a vertical line passing through the center of the femoral head and another line drawn from the center of the femoral head to the lateral acetabular rim. The AI is defined as the angle between a horizontal line and another line connecting the medial point of the sclerotic zone of the

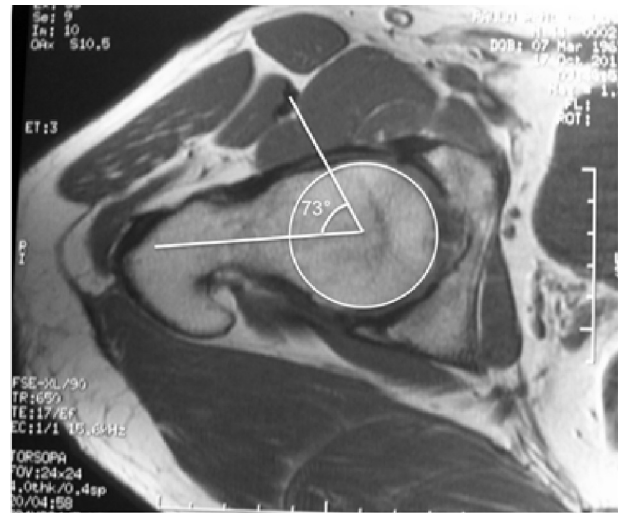


Fig. 1 – MRI of the right hip (axial oblique view) for measurement of the alpha angle. Image representative of altered alpha angle.

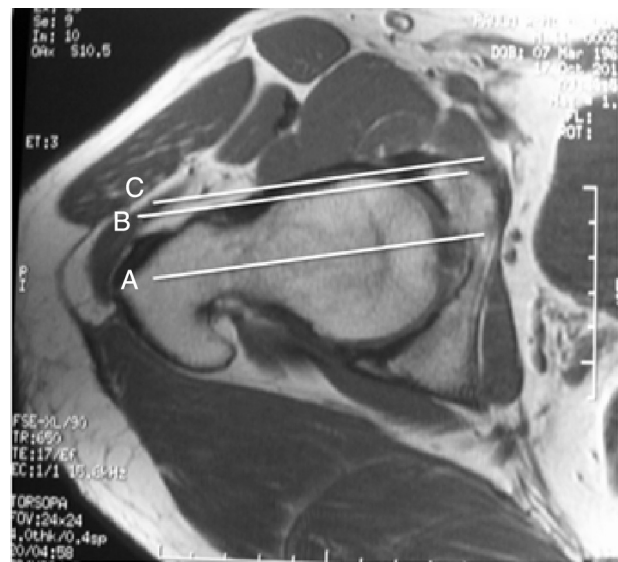


Fig. 2 – Femoral head–neck offset <7 mm indicates cam deformity.

acetabular roof and the lateral edge of the acetabulum^{16,17} (Fig. 3).

Other MRI alterations consistent with FAI considered by the examining radiologists were osseous bump,¹⁸ synovial pit,^{6,7,14,19–22} bone edema in the femoral neck, acetabular osteitis and lesions of the labrum and/or acetabular cartilage.

Physical examination

A physical examination of the hip was performed by an orthopedic surgeon specializing in hip surgery. ROM was measured with a manual goniometer in flexion, extension, IR, external rotation (ER), adduction, and abduction. Specific tests for

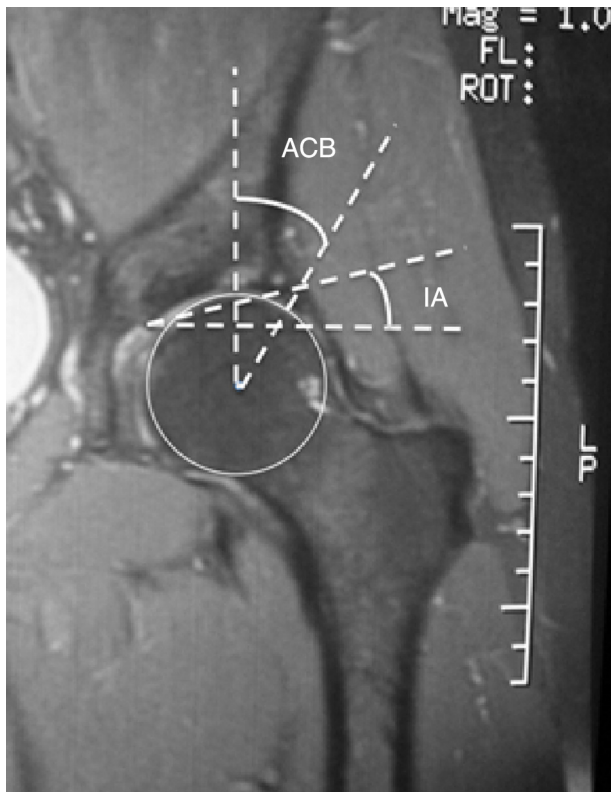


Fig. 3 – CEA and the AI indicative of pincer deformity.

anterolateral and posteroinferior impingement were also performed.

The anterior impingement test was performed with the patient in the supine position, flexing the hip 90°, with adduction and internal rotation. The test was considered positive if it elicited pain.^{2,6}

The posteroinferior impingement test was performed with the patient in the supine position, hanging the leg over the end of the bed while in extension and external rotation. Again, the test was considered positive if the patient reported pain.^{20,23}

Statistical analysis

Two independent musculoskeletal radiologists, blinded to physical examination findings, analyzed the MRI scans. Concordance between their results was assessed using the kappa index, which is considered satisfactory when >0.7 . In case of discrepancy between examiners, a third, experienced radiologist conducted another evaluation.

The results were entered into a Microsoft Excel spreadsheet and exported to PASW Statistics, version 18.0, for analysis. Quantitative variables were described as means and standard deviations, and categorical variables, as absolute and relative frequencies. Prevalence was reported with 95% confidence intervals. Comparisons of continuous variables were performed using the independent samples t-test.

Table 1 – Distribution of patients by age.

Age	n	%
13	7	12.5
14	15	26.8
15	10	17.9
16	11	19.6
17	7	12.5
18	6	10.7
Total	56	100.0

Table 2 – Prevalence of MRI findings indicative of femoroacetabular impingement morphology in the sample (n = 56, 112 hips).

MRI finding	Prevalence (%)	95%CI
Loss of sphericity	73	65–82
Decreased head–neck offset	57	48–66
Alpha angle $\geq 55^\circ$	77.7	69.8–85.5
Acetabular index $\leq 0^\circ$	0	0
Wiberg angle $\geq 39^\circ$	10.7	4.9–16.5
Osseous bump	44	34–53
Sinovial pit	4	0–7
BME at head/neck junction	21	14–29
Labral lesion	8	3–13
Degenerative labral lesion	2	–1 to 4
Acetabular osteitis	9	4–14
Chondral lesion	3	0–6

BME, bone marrow edema; CI, confidence interval; MRI, magnetic resonance imaging.

Results

Baseline demographics

A total of 56 male athletes (112 hips) were included in the study. No athletes were excluded. The mean age was 15.3 years, with a distribution as shown in Table 1. The right side was dominant in 80.3% (45/56) of the athletes. There was no significant difference in the prevalence of FAIM on comparison of the dominant and contralateral hips.

MRI findings

Concordance between the findings of the two examining radiologists was satisfactory; therefore, analysis by a third radiologist was not necessary. The best inter-rater concordance was in the alpha angle, with a kappa coefficient of 0.91.

The prevalence of abnormalities characteristic of FAIM was 84.8% (95/112) (95%CI 78–91.5%). The MRI changes observed, and their respective prevalence, are described in Table 2.

Abnormal alpha angle ($\geq 55^\circ$) was observed in 77.7% (87/112) of hips, while abnormal femoral head–neck offset (<7 mm) was seen in 57% (64/112). The alpha angle was altered in all individuals with reduced offset. The physeal plate was open in 23.2% (13/56) of athletes. There was no significant difference in the prevalence of altered alpha angle between athletes with an open physeal plate and those with a closed physeal plate.

After stratification of athletes by age, the prevalence of altered alpha angle ranged from 63.6% (7/11) in 16-year-olds

Table 3 – Number of MRI changes found in the sample (n = 56, 112 hips).

Number of changes	Frequency	Percentage	Cumulative percentage
0	17	15.2	15.2
1	9	8.0	23.2
2	8	7.1	30.4
3	20	17.9	48.2
4	24	21.4	69.6
5	19	17.0	86.6
6	11	9.8	96.4
7	2	1.8	98.2
8	2	1.8	100.0
Total	112	100.0	

Table 4 – Results of range of motion (ROM) tests in patients with and without MRI evidence of femoroacetabular impingement morphology.

Variable	MRI evidence of FAIM	No MRI evidence of FAIM	p
Flexion	127.9 ± 5.6	126.5 ± 7.8	0.48
Extension	9.9 ± 1.5	10.6 ± 1.7	0.12
Adduction	32 ± 4.5	31.5 ± 3.4	0.64
Abduction	47.4 ± 4.4	48.5 ± 3.8	0.31
IR	43 ± 11.2	46.8 ± 10.7	0.2
ER	49.3 ± 8.2	48.2 ± 4.6	0.43

ER, external rotation; FAI, femoroacetabular impingement; IR, internal rotation; MRI, magnetic resonance imaging.

Results expressed as mean ± standard deviation. p-values from Student's t-test for independent samples.

100% (6/6) in 18-year-olds. There were no significant differences in prevalence across different ages.

Areas of bone marrow edema (BME) were observed in the femoral head-neck junction of 24 hips (21%), all of which exhibited an elevated alpha angle. Acetabular labral lesions were identified in 10 hips and chondral lesions were found in three.

All hips had an AI $\geq 2^\circ$. A CEA $>39^\circ$ was seen in 10.7% (12/112) of the hips, indicating a diagnosis of pincer deformity.

Pooled analysis of MRI findings (Table 3) showed that most of the hips (76.8%) had more than one alteration suggestive of FAI, and $>50\%$ had four or more such changes.

Correlation between MRI and physical examination findings

The results of ROM measurement are presented in Table 4. There was no significant association between ROM and MRI findings consistent with FAI. Concerning the posteroinferior and anterolateral impingement tests, the former was negative in all athletes, while the latter was positive in 17 hips, of which 15 showed findings suggestive of FAI on MRI scans. There was no significant difference in the prevalence of positive impingement test results between hips with and without signs of FAI. Even when an alpha angle $\geq 65^\circ$ was considered diagnostic of cam-type impingement, there was no correlation between alpha angle and positive anterolateral impingement

test. There was no correlation between MRI changes and physical examination findings.

Discussion

Physical activity during bone growth may be associated with an increased risk of FAI deformity, which can progress to hip OA during adulthood. This is the first study to assess the prevalence of MRI changes consistent with FAIM in asymptomatic youth soccer players and analyze the potential correlation between these changes and physical examination findings.

The prevalence of MRI changes indicative of FAIM in the present sample was 84.8%. This is a higher prevalence than that reported in previous studies of soccer players.²⁴⁻²⁶ When comparing the prevalence of pathological alpha angle only ($\geq 55^\circ$, cam-type deformity), the 77.7% rate found in the present study was higher than those reported by Gerhardt et al.²⁵ (68%) and Johnson et al.²⁶ (60%), both studies that evaluated adult soccer players using plain radiography. It was also higher than the 26% prevalence reported by Agricola et al. who evaluated adolescent soccer players using plain radiography, but considering the alpha angle abnormal only if $>60^\circ$.²⁴⁻²⁶ This can be explained by the greater sensitivity of MRI compared to plain radiography in identifying changes that characterize FAI.²⁷⁻²⁹ The excellent concordance between the examining radiologists in measuring the alpha angle, with a kappa coefficient of 0.91, demonstrates the reproducibility of MRI for diagnosis of cam-type impingement.

MRI findings of cam deformity in the present sample were very similar to those reported in previous studies of adolescent athletes in other sports. Siebenrock et al.³⁰ reported an 89% prevalence of cam deformity in basketball players aged 9-25 years, including after physeal closure. Philippon et al. found an alpha angle $\geq 55^\circ$ in 75% of hockey players between the ages of 10 and 18.²¹

Comparing the prevalence of cam deformity in the present study with the results of Frank et al.³¹ in a systematic review about prevalence of FAIM in asymptomatic volunteers, it was higher than the 37-54.8% found in athletes and much higher than the 23.1% in the general population.

A high prevalence of cam-type impingement morphology in young high-level athletes corroborates the hypothesis proposed by Siebenrock et al.,¹² which suggests a direct relationship between physical activity and a higher incidence of cam-type FAIM, probably due to enlargement of the physeal plate. The finding of MRI evidence of BME in the femoral head/neck junction in 21.4% of hips (24/112) in this sample is highly suggestive of stress-related changes, which suggest active FAI and probably precede the development of femoral head-neck bump deformity.

The prevalence of cam deformity was similar between athletes with open and closed physeal plates, which suggest that the cam is formed even before physeal plate growth is completed. If this lesion is caused by stress from bone impaction, the earlier it starts, the greater the potential for damage; the immature skeleton is more complacent, and can easily be remodeled by abnormal forces.

There was no correlation between dominant side and prevalence of FAIM, which suggests there is no specific activ-

ity or movement that causes FAI. Simple stress over the physis during physical activities could explain the high prevalence of cam-type impingement morphology.

The identification of two or more MRI changes indicative of FAI in 76.8% of hips, in an entirely asymptomatic sample, underlines the importance of careful assessment when recommending surgical procedures to patients in whom diagnosis is based solely on MRI findings. Monitoring of athletes could help define how many of these patients would develop symptoms and require surgery. Follow-up of the present sample would allow identification the incidence of chondral and labral lesions in youth soccer players, as well as identification of which level of sports practice intensity could be considered a risk factor for hip OA.

When athletes with signs of impingement on MRI were compared to those with normal hips, no significant differences in ROM or anterolateral and posteroinferior impingement test results were found. This suggests that, in asymptomatic youth soccer players, physical examination findings are inconclusive regarding the diagnosis of FAI. Furthermore, it suggests that MRI can reveal abnormalities consistent with FAIM before they become apparent on clinical examination.

The inverse relationship between increased prevalence of FAI and reduced IR described in the literature was not confirmed in this study, probably because the sample was asymptomatic and very young (i.e., a subclinical population).³² Any decrease in IR or ER could be important, because of the possibility of increased risk of anterior cruciate ligament rupture.³³

Limitations

The limitations of this study include the lack of a control group of adolescents who did not practice physical activities at a high level. We plan to conduct a matched case-control study to evaluate the prevalence of these findings in a normal population. In addition, the age range of the athletes could have been extended down to 10 years, which would have allowed better assessment of the timing of FAIM onset, especially of cam-type FAI.

Conclusion

The youth soccer players who participated in our study had a high prevalence of abnormalities characteristic of FAIM on MRI. Physical examination findings did not correlated with MRI evidence of FAIM.

Conflicts of interest

The authors declare no conflicts of interest.

REFERENCES

- Clohisy JC, Knaus ER, Hunt DM, Leshner JM, Harris-Hayes M, Prather H. Clinical presentation of patients with symptomatic anterior hip impingement. *Clin Orthop Relat Res.* 2009;467(3):638–44.
- Ganz R, Parvizi J, Beck M, Leunig M, Nötzli H, Siebenrock KA. Femoroacetabular impingement: a cause for osteoarthritis of the hip. *Clin Orthop Relat Res.* 2003;(417):112–20.
- Ito K, Minka MA 2nd, Leunig M, Werlen S, Ganz R. Femoroacetabular impingement and the cam-effect. A MRI-based quantitative anatomical study of the femoral head-neck offset. *J Bone Joint Surg Br.* 2001;83(2):171–6.
- Sink EL, Gralla J, Ryba A, Dayton M. Clinical presentation of femoroacetabular impingement in adolescents. *J Pediatr Orthop.* 2008;28(8):806–11.
- Fabricant PD, Heyworth BE, Kelly BT. Hip arthroscopy improves symptoms associated with FAI in selected adolescent athletes. *Clin Orthop Relat Res.* 2012;470(1):261–9.
- Philippon MJ, Maxwell RB, Johnston TL, Schenker M, Briggs KK. Clinical presentation of femoroacetabular impingement. *Knee Surg Sports Traumatol Arthrosc.* 2007;15(8):1041–7.
- Philippon MJ, Yen YM, Briggs KK, Kuppersmith DA, Maxwell RB. Early outcomes after hip arthroscopy for femoroacetabular impingement in the athletic adolescent patient: a preliminary report. *J Pediatr Orthop.* 2008;28(7):705–10.
- Beaulé PE, Kim YJ, Rakhra KS, Stelzeneder D, Brown TD. New frontiers in cartilage imaging of the hip. *Instr Course Lect.* 2012;61:253–62.
- Beck M, Kalhor M, Leunig M, Ganz R. Hip morphology influences the pattern of damage to the acetabular cartilage: femoroacetabular impingement as a cause of early osteoarthritis of the hip. *J Bone Joint Surg Br.* 2005;87(7):1012–8.
- Schmitz MR, Campbell SE, Fajardo RS, Kadrmars WR. Identification of acetabular labral pathological changes in asymptomatic volunteers using optimized, noncontrast 1.5-T magnetic resonance imaging. *Am J Sports Med.* 2012;40(6):1337–41.
- Keogh MJ, Batt ME. A review of femoroacetabular impingement in athletes. *Sports Med.* 2008;38(10):863–78.
- Siebenrock KA, Behning A, Mamisch TC, Schwab JM. Growth plate alteration precedes cam-type deformity in elite basketball players. *Clin Orthop Relat Res.* 2013;471(4):1084–91.
- Johnston TL, Schenker ML, Briggs KK, Philippon MJ. Relationship between offset angle alpha and hip chondral injury in femoroacetabular impingement. *Arthroscopy.* 2008;24(6):669–75.
- Nötzli HP, Wyss TF, Stoecklin CH, Schmid MR, Treiber K, Hodler J. The contour of the femoral head-neck junction as a predictor for the risk of anterior impingement. *J Bone Joint Surg Br.* 2002;84(4):556–60.
- Clohisy JC, Nunley RM, Otto RJ, Schoenecker PL. The frog-leg lateral radiograph accurately visualized hip cam impingement abnormalities. *Clin Orthop Relat Res.* 2007;462:115–21.
- Kutty S, Schneider P, Faris P, Kiefer G, Frizzell B, Park R, et al. Reliability and predictability of the centre-edge angle in the assessment of pincer femoroacetabular impingement. *Int Orthop.* 2012;36(3):505–10.
- Stelzeneder D, Hingsammer A, Bixby SD, Kim YJ. Can radiographic morphometric parameters for the hip be assessed on MRI? *Clin Orthop Relat Res.* 2013;471(3):989–99.
- Fritz AT, Reddy D, Meehan JP, Jamali AA. Femoral neck exostosis, a manifestation of cam/pincer combined femoroacetabular impingement. *Arthroscopy.* 2010;26(1):121–7.
- Leunig M, Beck M, Kalhor M, Kim YJ, Werlen S, Ganz R. Fibrocystic changes at anterosuperior femoral neck: prevalence in hips with femoroacetabular impingement. *Radiology.* 2005;236(1):237–46.

20. Parvizi J, Leunig M, Ganz R. Femoroacetabular impingement. *J Am Acad Orthop Surg.* 2007;15(9):561-70.
21. Philippon MJ, Ho CP, Briggs KK, Stull J, LaPrade RF. Prevalence of increased alpha angles as a measure of cam-type femoroacetabular impingement in youth ice hockey players. *Am J Sports Med.* 2013;41(6):1357-62.
22. Pitt MJ, Graham AR, Shipman JH, Birkby W. Herniation pit of the femoral neck. *AJR Am J Roentgenol.* 1982;138(6):1115-21.
23. Crawford JR, Villar RN. Current concepts in the management of femoroacetabular impingement. *J Bone Joint Surg Br.* 2005;87(11):1459-62.
24. Agricola R, Bessems JH, Ginai AZ, Heijboer MP, van der Heijden RA, Verhaar JA, et al. The development of Cam-type deformity in adolescent and young male soccer players. *Am J Sports Med.* 2012;40(5):1099-106.
25. Gerhardt MB, Romero AA, Silvers HJ, Harris DJ, Watanabe D, Mandelbaum BR. The prevalence of radiographic hip abnormalities in elite soccer players. *Am J Sports Med.* 2012;40(3):584-8.
26. Johnson AC, Shaman MA, Ryan TG. Femoroacetabular impingement in former high-level youth soccer players. *Am J Sports Med.* 2012;40(6):1342-6.
27. Barton C, Salineros MJ, Rakhra KS, Beaulé PE. Validity of the alpha angle measurement on plain radiographs in the evaluation of cam-type femoroacetabular impingement. *Clin Orthop Relat Res.* 2011;469(2):464-9.
28. Masjedi M, Marquardt CS, Drummond IM, Harris SJ, Cobb JP. Cam type femoro-acetabular impingement: quantifying the diagnosis using three dimensional head-neck ratios. *Skeletal Radiol.* 2013;42(3):329-33.
29. Dudda M, Albers C, Mamisch TC, Werlen S, Beck M. Do normal radiographs exclude asphericity of the femoral head-neck junction? *Clin Orthop Relat Res.* 2009;467(3):651-9.
30. Siebenrock KA, Ferner F, Noble PC, Santore RF, Werlen S, Mamisch TC. The cam-type deformity of the proximal femur arises in childhood in response to vigorous sporting activity. *Clin Orthop Relat Res.* 2011;469(11):3229-40.
31. Frank JM, Harris JD, Erickson BJ, Slikker W 3rd, Bush-Joseph CA, Salata MJ, et al. Prevalence of femoroacetabular impingement imaging findings in asymptomatic volunteers: a systematic review. *Arthroscopy.* 2015;31(6):1199-204.
32. Reichenbach S, Jüni P, Werlen S, Nüesch E, Pfirrmann CW, Trelle S, et al. Prevalence of cam-type deformity on hip magnetic resonance imaging in young males: a cross-sectional study. *Arthritis Care Res (Hoboken).* 2010;62(9):1319-27.
33. Gomes JL, de Castro JV, Becker R. Decreased hip range of motion and noncontact injuries of the anterior cruciate ligament. *Arthroscopy.* 2008;24(9):1034-7.