



Original Article

Amputation risk after the revascularization procedures in sarcoma resections[☆]



Luiz Eduardo Moreira Teixeira^{a,b,*}, Thiago Marques Leão^c, Daniel Barbosa Regazzi^c, Cláudio Beling Gonçalves Soares^b

^a Universidade Federal de Minas Gerais (UFMG), Faculdade de Medicina, Belo Horizonte, MG, Brazil

^b Hospital Madre Teresa, Serviço de Ortopedia e Traumatologia, Belo Horizonte, MG, Brazil

^c Universidade Federal de Minas Gerais (UFMG), Hospital das Clínicas, Belo Horizonte, MG, Brazil

ARTICLE INFO

Article history:

Received 2 May 2016

Accepted 30 August 2016

Available online 21 October 2017

Keywords:

Soft tissue sarcoma

Osteosarcoma

Limb salvage

Amputation

Reconstructive surgical procedures

ABSTRACT

Objective: The objective of this study is to evaluate the efficacy of vascular reconstructive surgery after resection of bone and soft tissue tumors in extremities and the risk of progression to amputation.

Methods: This is a retrospective, observational data collection from medical records of patients who underwent resection of bone and soft tissue tumors in the period of 2002–2015. Thirteen patients met the inclusion criteria, which evaluated the correlations between certain factors (gender, tumor type, location, reconstruction, revascularization and patency, infection) with amputation in the postoperative period.

Results: In this study, of the 13 patients undergoing reconstruction, five (38.46%) evolved to amputation. All patients who progressed to amputation had the following in common: presence of bone sarcoma ($p=0.005$), having undergone reconstruction with an orthopedic prosthesis ($p=0.005$), lack of vascular patency in the revascularization site in the postoperative period ($p=0.032$), and surgical site infection ($p=0.001$). None of the patients with soft tissue sarcoma underwent amputation, and the only patient with bone sarcoma who did not undergo amputation had no infection and maintained vascular patency of the graft.

Conclusion: The occurrence of infection appears to be one of the main risk factors for failure of revascularization, especially in cases of bone sarcoma in which vascular reconstruction is performed with placement of a non-conventional joint prosthesis.

© 2016 Sociedade Brasileira de Ortopedia e Traumatologia. Published by Elsevier Editora Ltda. This is an open access article under the CC BY-NC-ND license (<http://creativecommons.org/licenses/by-nc-nd/4.0/>).

[☆] Study conducted at Hospital Madre Teresa, Serviço de Ortopedia Oncológica; and Universidade Federal de Minas Gerais, Hospital das Clínicas, Belo Horizonte, MG, Brazil.

* Corresponding author.

E-mail: luizmteixeira@yahoo.com.br (L.E. Teixeira).

<http://dx.doi.org/10.1016/j.rboe.2017.10.005>

2255-4971/© 2016 Sociedade Brasileira de Ortopedia e Traumatologia. Published by Elsevier Editora Ltda. This is an open access article under the CC BY-NC-ND license (<http://creativecommons.org/licenses/by-nc-nd/4.0/>).

Risco de amputação após procedimento de revascularização nas ressecções de sarcoma

R E S U M O

Palavras-chave:

Sarcoma de tecidos moles
Osteossarcoma
Salvamento de membro
Amputação
Procedimentos cirúrgicos
reconstrutivos

Objetivo: O objetivo deste estudo é avaliar a eficácia da cirurgia de reconstrução vascular após ressecção de tumores ósseos e tecidos moles em extremidades e o risco de evolução para amputação.

Métodos: Estudo retrospectivo, observacional, de coleta de dados em prontuário médico de pacientes submetidos a ressecção de tumores ósseos e de tecidos moles de 2002 a 2015; 13 pacientes preencheram o critério de inclusão, foram avaliadas as correlações de determinados fatores (gênero, tipo de tumor, localização, reconstrução, revascularização e patência, infecção) com amputação no pós-operatório.

Resultados: No presente estudo, dos 13 pacientes submetidos à reconstrução, cinco (38,46%) evoluíram com amputação. Todos os pacientes que evoluíram com amputação tinham em comum o fato de ser portadores de sarcoma ósseo ($p=0,005$), ter sido submetidos a reconstrução com prótese ortopédica ($p=0,005$) e não apresentar patência vascular no local da revascularização no período pós-operatório ($p=0,032$), além de apresentar infecção no local da cirurgia ($p=0,001$). Nenhum dos pacientes portadores de sarcoma de partes moles foi submetido à amputação e o único paciente do grupo com sarcoma ósseo que não sofreu amputação não apresentava infecção e mantinha patência vascular no enxerto.

Conclusão: A ocorrência de infecção parece ser um dos principais fatores de risco para a falência da revascularização, especialmente nos casos de sarcoma ósseo em que a reconstrução vascular é feita juntamente com colocação de próteses articulares não convencionais.

© 2016 Sociedade Brasileira de Ortopedia e Traumatologia. Publicado por Elsevier Editora Ltda. Este é um artigo Open Access sob uma licença CC BY-NC-ND (<http://creativecommons.org/licenses/by-nc-nd/4.0/>).

Introduction

Primary malignant tumors of the musculoskeletal system are rare, accounting for 1% of all types of cancer¹⁻⁹; surgery is the primary method of treatment. Currently, limb preservation is possible in 80% of cases. A few decades ago, involvement of large vessels by tumors was an indication for amputation.^{1,2,7,10,11} However, with the improvement of imaging techniques and adjuvant treatment, it has become possible to use vascular reconstruction techniques without harm regarding relapse or metastatic dissemination of the disease, which increases the limb preservation rate without compromising survival or recurrence of the disease.^{2,8-10}

Vascular reconstruction in patients undergoing surgery for resection of sarcomas has proven to be a viable method in limb salvage procedures; autologous grafts or vascular prostheses made of synthetic materials, such as polytetrafluoroethylene (PTFE), can be used.^{1,3-9,11,12}

Umezawa et al.¹ assessed 23 patients with bone or soft tissue tumors in the lower limbs who underwent extensive resections with vascular structure resection; total amputation was avoided in all patients. Emori et al.³ evaluated patients with soft tissue sarcomas located in the inguinal region who underwent tumor resection and required vascular reconstruction; in nine of the ten patients in their study, preservation of the affected limb was possible. Other authors have shown good results of vascular reconstruction as a limb salvage technique.^{4,6,8}

Based on these data, this study aimed to assess the risk of amputation after arterial reconstruction in bone and soft tissue sarcomas at the extremities, and the factors associated with failure of the salvage procedure.

Material and methods

This is a retrospective, observational study of data collection in medical records of patients who underwent bone and soft tissue tumor resection from 2002 to 2015.

The study included patients who, during tumor resection, required intervention by the vascular surgery team for a vascular reconstruction procedure; the procedure was indicated prior to or during surgery. Patients in whom the vascular procedure did not require reconstruction (such as arteriorrhaphy), those with incomplete data in the medical record, those with less than six months of follow-up, and those who did not agree to participate were excluded from the study.

The studied variables were:

1. Age
2. Gender
3. Reconstruction level (iliofemoral, femoropopliteal, popliteal tibial, brachial)
4. Type of tumor (bone, soft tissue)
5. Type of reconstruction (prosthesis, graft)
6. Postoperative infection
7. Prior chemotherapy or radiation therapy
8. Location of the tumor

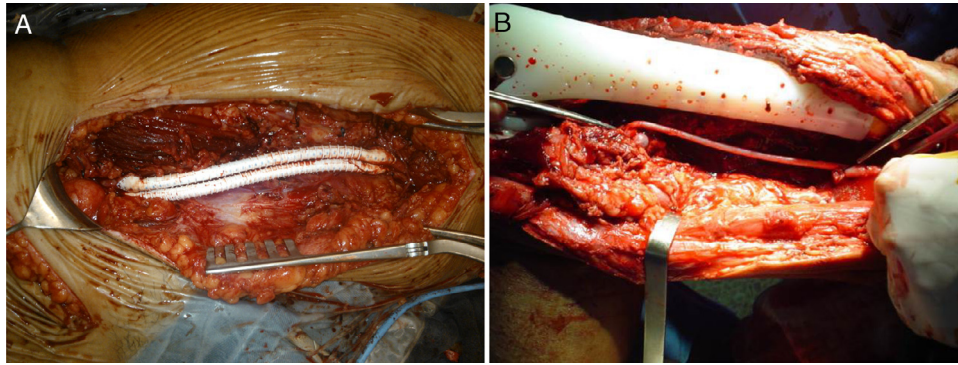


Fig. 1 – (A) Vascular prosthesis; (B) inverted saphenous vein graft.

The statistical analysis was performed initially by a descriptive study of frequencies, expressed as mean and standard deviation (SD). The comparative study was conducted initially by univariate analysis using the chi-squared test with or without correction by Fischer's exact test for qualitative variables. Continuous variables were analyzed using Student's *t*-test. The multivariate analysis was performed using multiple logistic regression, including variables with $p < 0.25$. The study was performed using SPSS® software version 21.0 (Chicago, USA), considering as significant *p*-values ≤ 0.05 .

Results

A total of 279 patients underwent resection of bone and soft tissue sarcomas during the study period. Of these, 13 required vascular reconstruction (12 with inverted saphenous vein graft and one with synthetic graft); all were included in the study. Fig. 1A and B presents images of vascular reconstructions.

The patient's age varied from 12 to 68 years; the mean age was 36.46 years and the median, 35 years. Nine (69.23%) patients were male and four (30.77%), female. Six (46.15%) patients had bone sarcoma (one fibrosarcoma, one pleomorphic sarcoma, one chondrosarcoma, and three osteosarcomas) and seven (53.85%) had soft tissue sarcomas (four malignant fibrous histiocytomas, one soft tissue Ewing's sarcoma, one synovial sarcoma, and one hemangiopericytoma). Seven (53.85%) patients underwent radiation therapy (one in the pre-operative period and six in the postoperative period), and seven (53.85%) chemotherapy (three in the soft tissue sarcoma group and four in the bone sarcoma group). Epidemiological data are summarized in Table 1.

Amputation was required in five (38.46%) of the 13 patients that had revascularization procedures after sarcoma resection. Seven patients (53.85%) had soft tissue sarcomas and six (46.15%) had bone sarcomas. All patients who evolved to amputation had bone sarcoma ($p = 0.005$). Regarding gender, although the five patients who underwent amputation were male, the result was not statistically significant ($p = 0.98$).

Reconstruction with osteoarticular prosthesis of the operated segment was performed in six (46.15%) patients, all with bone sarcoma; of these, five (83.33%) evolved with exigency for amputation, a statistically significant result ($p = 0.005$).

Regarding the level of revascularization, in three (23.08%) patients, it was performed at the iliofemoral level, in two (15.38%) at the femoropopliteal, in seven (53.85%) at the popliteal tibial, and in one (7.69%) at the brachial level. Five cases required amputation, one (20%) case with revascularization at the iliofemoral level, one (20%) at the femoropopliteal, and three (60%) at the popliteal tibial level ($p = 0.843$).

Five (38.46%) of the 13 (100%) cases operated, developed postoperative infection and eight (61.54%) had no infection. A statistically significant association ($p = 0.001$) was observed between the occurrence of postoperative infection and exigency for amputation; of the five infected patients, all underwent amputation, whereas in the group without infection, none of the patients required amputation.

Seven (53.85%) of the 13 patients had undergone prior chemotherapy and six (46.15%) had not. Of the cases that received chemotherapy, three (42.86%) evolved with exigency for amputation, whereas among the cases that did not receive chemotherapy, two (33.33%) progressed with exigency for amputation. No statistically significant correlation was observed between need for amputation and prior chemotherapy ($p = 0.587$).

Similarly, no statistically significant correlation was observed between the need for amputation and tumor location ($p = 0.80$). In the present study, three (23.08%) tumors were located in the popliteal region, two (15.38%) in the femur, four (30.78%) in the tibia, one (7.69%) in the thigh, one (7.69%) in the arm, and two (15.38%) in the inguinal region. Of the five amputations, two (40%) were tumors located in the femur and three (60%) tumors located in the tibia. Table 2 summarizes these results.

Discussion

Vascular reconstruction associated with resection of sarcomas that affect large vessels of a limb has been shown to be a viable method for affected limb preservation.^{1,3-9,11,12}

In the present study, five (38.46%) of the 13 patients who underwent reconstruction, progressed to amputation. All these patients had in common the fact that they had bone sarcoma ($p = 0.005$), had undergone reconstruction with unconventional osteoarticular prosthesis ($p = 0.005$), had

Table 1 – Epidemiological data.

Name	Age/gender	Diagnosis	Location	RTX	QTX
1	26/F	Malignant fibrous histiocytoma	Popliteal	Postop	No
2	38/M	Fibrosarcoma	Femur	No	No
3	27/M	Ewing's sarcoma (soft tissue)	Thigh	Postop	Yes
4	47/F	Synovial sarcoma	Inguinal	Postop	Yes
5	65/F	Pleomorphic sarcoma	Tibia	Preop	Yes
6	63/M	Chondrosarcoma	Proximal femur	No	No
7	35/M	Malignant fibrous histiocytoma	Inguinal	Postop	No
8	12/M	Osteosarcoma	Tibia	No	Yes
9	24/M	Hemangiopericytoma	Popliteal	No	No
10	39/F	Malignant fibrous histiocytoma	Popliteal	Postop	No
11	14/M	Osteosarcoma	Proximal tibia	No	Yes
12	68/M	Malignant fibrous histiocytoma	Arm	Postop	Yes
13	16/M	Osteosarcoma	Tibia	No	Yes

Postop, postoperative; Preop, preoperative; QTX, chemotherapy; RTX, radiotherapy.

Table 2 – Data analysis results.

	Amputation		Total	p
	No	Yes		
Gender				
Male	4 (44.44%)	5 (55.56%)	9 (100%)	0.098
Female	4 (100%)	0 (0%)	4 (100%)	
Diagnosis				
Soft tissue	7 (100%)	0 (0%)	7 (100%)	0.005
Bone	1 (16.66%)	5 (83.34%)	6 (100%)	
Location				
Popliteal	3 (100%)	0 (0%)	3 (100%)	0.080
Femur	0 (0%)	2 (100%)	2 (100%)	
Tibia	1 (25%)	3 (75%)	4 (100%)	
Thigh	1 (100%)	0 (0%)	1 (100%)	
Arm	1 (100%)	0 (0%)	1 (100%)	
Inguinal	2 (100%)	0 (0%)	2 (100%)	
Reconstruction				
Yes	7 (100%)	0 (0%)	7 (100%)	0.005
No	1 (16.67%)	5 (83.33%)	6 (100%)	
Revascularization				
Iliofemoral	2 (66.67%)	1 (33.33%)	3 (100%)	0.843
Femoropopliteal	1 (50%)	1 (50%)	2 (100%)	
Popliteal tibial	4 (57.14%)	3 (42.86%)	7 (100%)	
Brachial	1 (100%)	0 (0%)	1 (100%)	
Infection				
Yes	0 (0%)	5 (100%)	5 (100%)	0.001
No	8 (100%)	0 (0%)	8 (100%)	
Chemotherapy				
Yes	4 (57.14%)	3 (42.86%)	7 (100%)	0.587
No	4 (66.67%)	2 (33.33%)	6 (100%)	
Patency				
Yes	7 (87.5%)	1 (12.5%)	8 (100%)	0.032
No	1 (20%)	4 (80%)	5 (100%)	

no vascular patency at the postoperative revascularization site ($p=0.032$), and presented infection at the surgical site ($p=0.001$). None of the soft tissue sarcoma patients underwent amputation; the only patient in the non-amputated bone sarcoma group did not present infection and maintained vascular patency in the graft.

In their study, Emori et al.³ reported limb preservation in nine out of ten patients with soft tissue sarcoma in the inguinal region; disarticulation was performed two months after the initial procedure in a patient who evolved with local recurrence, graft occlusion, and limb necrosis.

Muramatsu et al.⁴ reported that only one patient required amputation seven months after surgery due to progressive deterioration with ischemic limb pain; nonetheless, no patient presented vascular insufficiency in the immediate postoperative period. Furthermore, three cases of infection were identified; in two of them, a synthetic graft had been used for revascularization, which led the authors to recommend the use of autologous vein graft as first choice, in an attempt to reduce the risk of infection.

Spark et al.⁶ reported a case of exigency for amputation ten months after surgery due to local occlusion of the vascular graft, secondary to compression caused by tumor recurrence. In their study, the authors reported the use of a distal femoral prosthesis in one case and a total femoral prosthesis in another case; in the former, early reassessment was necessary, as the patient evolved with two episodes of graft occlusion in the first 24 h (one due to compression between the prosthesis and the remnants of muscle and the other due to thrombus formation). In that study, no cases of progression to amputation or infection were reported in patients with total and distal femoral prosthesis.

Nishinari et al.⁸ reported that, at 18 months postoperatively, nine of their patients who had undergone resection with venous reconstruction in the lower limbs were alive; one patient evolved to above-the-knee amputation, 11 months after surgery, due to relapse. Among postoperative complications, those authors observed one case of surgical wound infection, which evolved to vascular graft rupture at 21 days after surgery, but did not require an amputation.

Adelani et al.⁹ assessed revascularization after resection of soft tissue sarcomas in the lower limbs; only one of 14 patients underwent amputation due to an acute arterial occlusion. However, the authors reported the presence of surgical wound infection in four cases (of these, two of them evolved with infection of the vascular graft, both made from synthetic material) and the presence of thrombosis in five cases. Two patients presented both thrombosis and infection; nonetheless, it was not possible to estimate the cause/effect relationship between the two. It has been reported that the risk of infection with synthetic vascular grafts appears to be greater.

Nishinari et al.¹¹ evaluated patients with malignant tumors involving large vessels of the lower limbs; only one case evolved with the exigency for amputation due to relapse. No cases of arterial reconstruction occlusion were observed. However, one case of rupture of an arterial reconstruction secondary to infection in a surgical wound was reported; the graft was ligated and satisfactory collateral circulation was observed.

Hohenberger et al.¹² reported a case of amputation due to occlusion of the revascularization graft on the 17th postoperative day. In their study, an infection rate of 21% was observed; in one case of infection, occlusion of the synthetic graft that replaced the femoral vein was reported.

In turn, McKay et al.⁷ reported four cases of patients with soft tissue neoplasias in the groin area, who were submitted to resection and vascular reconstruction; the procedure was successful in preserving the limb in all cases. No postoperative amputation was required during that study and no arterial occlusion or anastomotic failure were observed in the reconstructions.

In the assessed studies, the main risk factors for amputation after tumor resection surgery and vascular reconstruction for limb preservation appear to be local tumor recurrence, occlusion, and loss of graft patency.

However, in the present study, it was observed that, in addition to loss of patency, there appears to be a statistical significance between local infection and amputation. Of the five cases that evolved with exigency for amputation, four (80%) presented infection and loss of patency; one case (20%) presented infection with preserved patency. Therefore, in the present study, infection was a risk factor for the need of amputation. Inadequate vascularization may increase the risk of infection; infection may also compromise graft viability.

Another risk factor observed in the present study was the presence of bone sarcoma, necessitating an unconventional osteoarticular prosthesis to replace the resected bone. Of the six cases treated with prosthesis, only one (16.67%) did not undergo amputation; this patient presented vascular patency and did not evolve with infection. Moreover, all cases requiring amputation had in common the use of unconventional osteoarticular prosthesis due to resection of bone sarcoma and infection. In the group of patients with soft tissue sarcoma, none evolved with amputation or infection; the only case without graft patency did not require amputation, as there was satisfactory collateral circulation.

Loss of patency and infection are risk factors for amputation, as well as tumor recurrence, that were observed in cases of amputation reported in other studies.^{3,6,8,11} The fact that the use of unconventional osteoarticular prosthesis in case of bone sarcomas appears to be a risk factor, may be associated with prolonged surgery time and the presence of more inert biomaterials, with the possibility of infection associated with the implant.

Conclusion

In the present study, the risk of amputation was 38.46%.

The occurrence of infection appears to be one of the main risk factor for revascularization failure, especially in cases of bone sarcoma in which vascular reconstruction is performed together with the use of unconventional joint prostheses.

Conflicts of interest

The authors declare no conflicts of interest.

REFERENCES

1. Umezawa H, Sakuraba M, Miyamoto S, Nagamatsu S, Kayano S, Taji M. Analysis of immediate vascular reconstruction for lower-limb salvage in patients with lower-limb bone and soft-tissue sarcoma. *J Plast Reconstr Aesthet Surg*. 2013;66(5):608-16.
2. Sawaizumi M, Imai T, Matsumoto S. Recent advances in reconstructive surgery for bone and soft tissue sarcomas. *Int J Clin Oncol*. 2013;18(4):566-73.
3. Emori M, Hamada K, Omori S, Joyama S, Tomita Y, Hashimoto N, et al. Surgery with vascular reconstruction for soft-tissue

- sarcomas in the inguinal region: oncologic and functional outcomes. *Ann Vasc Surg.* 2012;26(5):693-9.
4. Muramatsu K, Ihara K, Miyoshi T, Yoshida K, Taguchi T. Clinical outcome of limb-salvage surgery after wide resection of sarcoma and femoral vessel reconstruction. *Ann Vasc Surg.* 2011;25(8):1070-7.
 5. Karakousis CP, Karpaliotis C, Driscoll DL. Major vessel resection during limb-preserving surgery for soft tissue sarcomas. *World J Surg.* 1996;20(3):345-9.
 6. Spark JJ, Charalabidis P, Laws P, Seben R, Clayer M. Vascular reconstruction in lower limb musculoskeletal tumours. *ANZ J Surg.* 2009;79(9):619-23.
 7. McKay A, Motamedi M, Temple W, Mack L, Moore R. Vascular reconstruction with the superficial femoral vein following major oncologic resection. *J Surg Oncol.* 2007;96(2):151-9.
 8. Nishinari K, Wolosker N, Yazbek G, Zerati AE, Nishimoto IN. Venous reconstructions in lower limbs associated with resection of malignancies. *J Vasc Surg.* 2006;44(5):1046-50.
 9. Adelani MA, Holt GE, Dittus RS, Passman MA, Schwartz HS. Revascularization after segmental resection of lower extremity soft tissue sarcomas. *J Surg Oncol.* 2007;95(6):455-60.
 10. Ferguson PC. Surgical considerations for management of distal extremity soft tissue sarcomas. *Curr Opin Oncol.* 2005;17(4):366-9.
 11. Nishinari K, Wolosker N, Yazbek G, Zerati AE, Nishimoto IN, Penna V, et al. Vascular reconstruction in limbs with malignant tumors. *Vasc Endovasc Surg.* 2004;38(5):423-9.
 12. Hohenberger P, Allenberg JR, Schlag PM, Reichardt P. Results of surgery and multimodal therapy for patients with soft tissue sarcoma invading to vascular structures. *Cancer.* 1999;85(2):396-408.