



Case Report

Rare anatomical variation of the musculocutaneous nerve – case report[☆]



Sergio Ricardo Rios Nascimento*, Cristiane Regina Ruiz, Eduardo Pereira, Lilian Andrades, Cristiano Cirqueira de Souza

Centro Universitário São Camilo, São Paulo, SP, Brazil

ARTICLE INFO

Article history:

Received 26 June 2015

Accepted 17 August 2015

Available online 27 April 2016

Keywords:

Arm/anatomy & histology

Musculocutaneous nerve/anatomy & histology

Median nerve/anatomy & histology

Anatomical variation

Upper limb

ABSTRACT

The clinical and surgical importance of anatomical knowledge of the musculocutaneous nerve and its variations is due to the fact that one of the complications in many upper-limb surgical procedures involves injury to this nerve. During routine dissection of the right upper limb of a male cadaver, we observed an anatomical variation of this nerve. The musculocutaneous nerve originated in the lateral cord and continued laterally, passing under the coracobrachialis muscle and then continuing until its first branch to the biceps brachialis muscle. Just after this, it supplied another two branches, i.e. the lateral cutaneous nerve of the forearm and a branch to the brachialis muscle, and then it joined the median nerve. The median nerve followed the arm medially to the region of the cubital fossa and then gave rise to the anterior intermediate nerve of the forearm. The union between the musculocutaneous nerve and the median nerve occurred approximately at the midpoint of the arm and the median nerve. Given that either our example is not covered by the classifications found in the literature or that it fits into more than one variation proposed, without us finding something truly similar, we consider this variation to be rare.

© 2015 Sociedade Brasileira de Ortopedia e Traumatologia. Published by Elsevier Editora Ltda. This is an open access article under the CC BY-NC-ND license (<http://creativecommons.org/licenses/by-nc-nd/4.0/>).

Rara variação anatômica do nervo musculocutâneo – relato de caso

RESUMO

A importância clínica e cirúrgica do conhecimento anatômico do nervo musculocutâneo e de suas variações deve-se ao fato de que uma das complicações em diversos procedimentos cirúrgicos do membro superior envolve sua lesão. Em uma dissecação de rotina do membro superior direito de um cadáver masculino observamos uma variação anatômica desse nervo. O nervo musculocutâneo originou-se no fascículo lateral, seguiu lateralmente, passou sob o músculo coracobraquial e seguiu até seu primeiro ramo para o músculo bíceps braquial. Logo após forneceu mais dois ramos, o nervo cutâneo lateral do antebraço e um ramo para o músculo braquial, e então uniu-se ao nervo mediano. O nervo mediano seguiu medialmente

Palavras-chave:

Braço/anatomia e histologia

Nervo musculocutâneo/anatomia e histologia

Nervo mediano/anatomia e histologia

Variação anatômica

Membro superior

[☆] Study carried out at Centro Universitário São Camilo, Laboratory of Human Anatomy, São Paulo, SP, Brazil.

* Corresponding author.

E-mail: srrnascimento@gmail.com (S.R.R. Nascimento).

<http://dx.doi.org/10.1016/j.rboe.2015.08.019>

2255-4971/© 2015 Sociedade Brasileira de Ortopedia e Traumatologia. Published by Elsevier Editora Ltda. This is an open access article under the CC BY-NC-ND license (<http://creativecommons.org/licenses/by-nc-nd/4.0/>).

no braço até a região da fossa cubital e deu então origem ao nervo intermédio anterior do antebraço. A união do nervo musculocutâneo com o nervo mediano aconteceu aproximadamente no ponto médio do braço e do nervo mediano. Tendo em vista que as classificações encontradas na literatura ou não abrangem nosso exemplo ou o mesmo se adequa a mais do que uma variação proposta, sem que tenhamos encontrado alguma fielmente semelhante, consideramos essa variação como rara.

© 2015 Sociedade Brasileira de Ortopedia e Traumatologia. Publicado por Elsevier Editora Ltda. Este é um artigo Open Access sob uma licença CC BY-NC-ND (<http://creativecommons.org/licenses/by-nc-nd/4.0/>).

Introduction

The musculocutaneous nerve (MCN) originates from the lateral fasciculus (roots C5–C7) where it initially sends a branch to the shoulder and then perforates the coracobrachialis muscle, which it innervates, emerges between the biceps brachii and brachialis muscles and sends a muscular branch to each of these muscles. After supplying all three muscles of the arm anterior compartment, the MCN emerges laterally to the biceps brachii muscle tendon, as the lateral cutaneous nerve of the forearm becomes truly subcutaneous when it perforates the muscle fascia proximal to the cubital fossa to initially follow the cephalic vein and in the subcutaneous tissue and, after crossing the anterior surface of the elbow, it continues to supply the skin of the lateral side of the forearm.¹

The clinical and surgical importance of the anatomical knowledge of this nerve and its variations is due to the fact that many surgical procedures in the upper limb involve mobilization or displacement of the muscles of the anterior arm compartment and one of the complications of these procedures is MCN lesions.²

Therefore, we report an anatomical variation of the musculocutaneous nerve observed during the dissection of a cadaver from the human anatomy laboratory of our university.

Case report

During a routine dissection of the right upper limb of a male cadaver that belonged to the anatomy laboratory collection, we observed an anatomical variation of the musculocutaneous muscle. The corpse, previously preserved in formaldehyde and through the glycerination method of Giacomini, was dissected. All the subcutaneous tissue and superficial fascia were removed. Subsequently, the brachial plexus, starting from its fasciculus, was painted with yellow fabric paint. The trajectory of the MCN was analyzed and measured from its origin in the lateral, up to its union with the median nerve, which was also measured from its origin in the medial and lateral fasciculus, to the cubital fossa region. An Absolute Digimatic® digital caliper of Mitutoyo Sul Americana Ltda was used for the measurements.

In our specimen, the MCN originated in the lateral fasciculus, which provides a component for the origin of the median nerve. The MCN followed laterally for 47.38 mm, passed under the coracobrachialis muscle for 32.73 mm to then emerge on the other side of this muscle and then follow for 55.38 mm

up to its first branch to the biceps brachii muscle. Then it coursed for 29.56 mm longer and provided two more branches: the lateral cutaneous nerve of the forearm and a branch to the brachial muscle. Subsequently, it followed for 29.34 mm longer and joined the median nerve, which was 145.90 mm

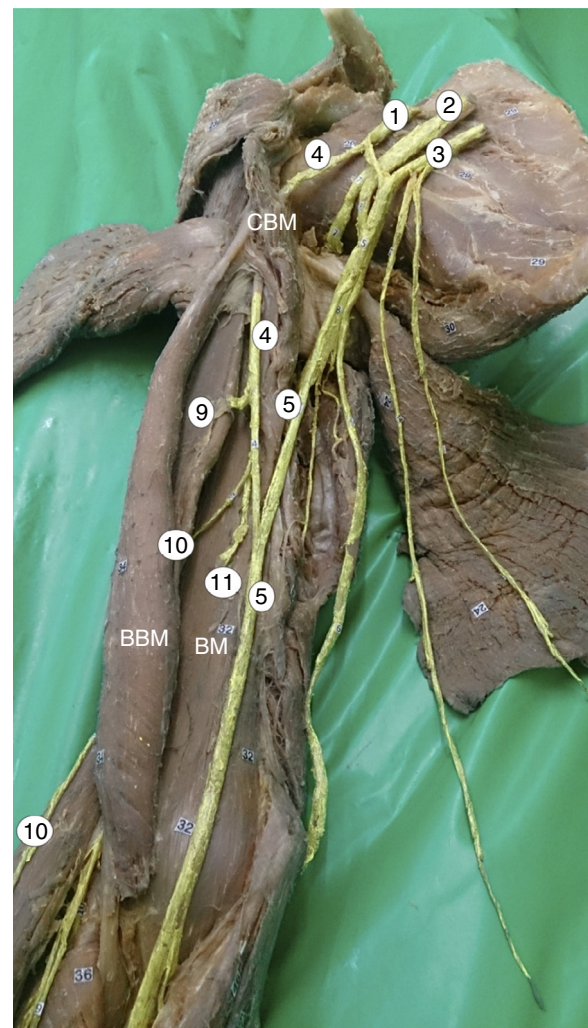


Fig. 1 – Photograph of the anatomical variation of the musculocutaneous muscle in the right upper limb. 1, lateral fasciculus; 2, posterior fasciculus; 3, medial fasciculus; 4, musculocutaneous nerve; 5, median nerve; 9, muscular branch of the biceps brachii; 10, lateral cutaneous nerve of the forearm; 11, muscular branch to the brachial. CBM, coracobrachialis muscle; BBM, biceps brachii muscle; BM, brachial muscle.

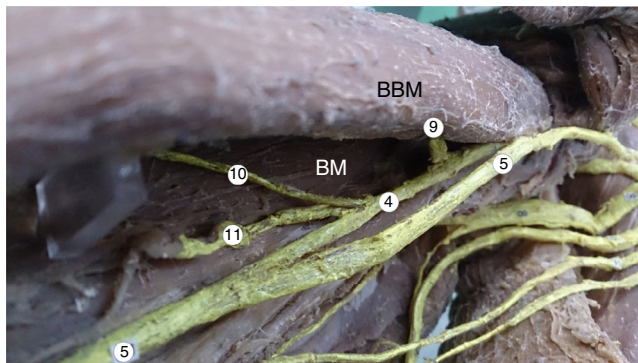


Fig. 2 – Photograph of the anatomical variation of the musculocutaneous nerve in the right upper limb. 4, musculocutaneous nerve; 5, median nerve; 9, muscular branch of the biceps brachii; 10, lateral cutaneous nerve of the forearm; 11, muscular branch to the brachial. BBM, biceps brachii muscle; BM, brachial muscle.

long since its origin up to its union with the musculocutaneous nerve. The median nerve followed medially along the arm for 158.41 mm to the region of the cubital fossa and then gave origin to the anterior intermediate nerve of forearm. The union of the musculocutaneous nerve with the median nerve occurred at approximately the midpoint of the arm and the median nerve (Figs. 1–3).

Discussion

The anatomical associations of MCN have been studied over the past few years aiming to prevent lesions during surgical procedures² and these variations often involve communication between the musculocutaneous and the median nerves through one or more of the communicating branches.^{3–8} The MCN can also send an independent branch to the coracobrachialis muscle instead of perforating, remaining parallel to the median nerve by a variable distance until it passes under the biceps brachii, or some of the median nerve fibers may follow for some length in the MCN before joining its own trunk, or the MCN can send muscular branches to the pronator teres muscle or innervate the dorsum of the thumb in the absence of the radial nerve superficial branch.¹

Considering the large number of variations found in the literature, there have been attempts to classify such variations. The most often used classification criteria in the comparisons of the variation pattern of the MCN and MN is the one proposed by Le Minor, which describes five types of variation.^{9,10} Our example did not fit in any of the five types described by the author. Another classification is the one by Venieratos and Anagnostopoulou,³ that indicates three types of possible variations. In this case, our variation fits into two proposed types: Type II, in which the union of the MCN with the MN occurs distally to the coracobrachialis muscle, and Type III, in which neither the nerve nor the communicant branch perforate the coracobrachialis muscle.^{9,10}

Some authors classify the variations in the MCN taking into account the number of communicating branches and their height.^{3–8} In our finding, the anastomosis of the MCN occurs

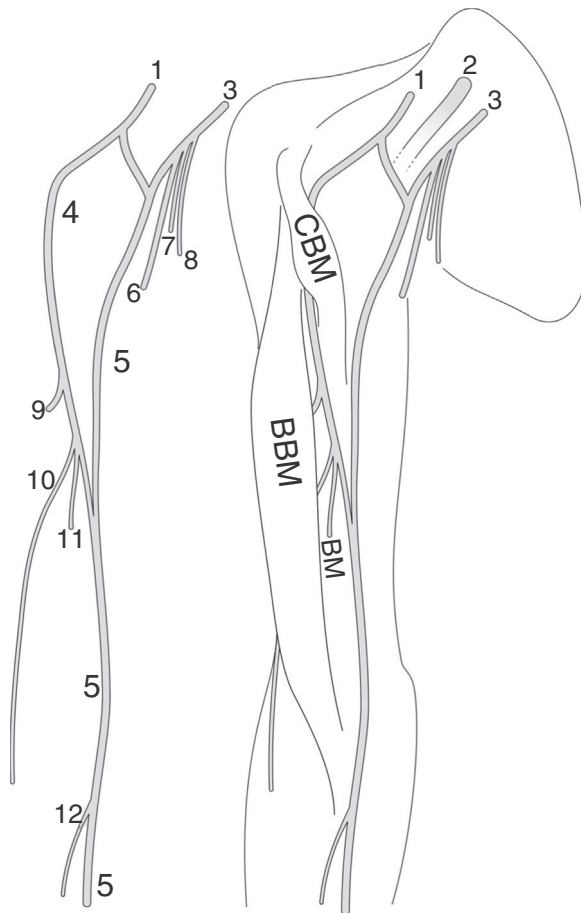


Fig. 3 – Schematic illustration of the anatomical variation of the musculocutaneous nerve in the right upper limb. 1, lateral fasciculus; 2, posterior fasciculus; 3, medial fasciculus; 4, musculocutaneous nerve; 5, median nerve; 6, ulnar nerve; 7, medial cutaneous nerve of the forearm; 8, medial cutaneous nerve of the arm; 9, muscular branch of the biceps brachii; 10, lateral cutaneous nerve of the forearm; 11, muscular branch to the brachial; 12, anterior interosseous nerve. CBM, coracobrachialis muscle; BBM, biceps brachii muscle; BM, brachial muscle.

after the muscular branch to the brachial muscle. Considering that the classifications found in the literature either do not include our example or it fits more than one proposed variation, without our having found another truly similar one, we consider this variation as rare.

Conflicts of interest

The authors declare no conflicts of interest.

REFERENCES

1. Goss CM. *Gray anatomia*. 29^a ed. Rio de Janeiro: Guanabara Koogan; 1977.
2. Rebouças F, Brasil Filho R, Filardis C, Pereira RR, Cardoso AA. *Estudo anatômico do trajeto do nervo musculocutâneo em*

- relação ao processo coracoide. Rev Bras Ortop. 2010;45(4):400-3.
3. Venieratos D, Anagnostopoulou S. Classification of communications between the musculocutaneous and median nerves. Clin Anat. 1998;11(5):327-31.
 4. Sachdeva K, Singla RK. Communication between median and musculocutaneous nerve. J Morphol Sci. 2011;28(4):246-9.
 5. Radunovic M, Vukanovic-Bozanic A, Radojevic N, Vukadinovic T. A new anatomical variation of the musculocutaneous and the median nerve anastomosis. Folia Morphol. 2013;72(2):176-9.
 6. Maeda S, Kawai K, Koizumi M, Ide J, Tokiyoshi A, Mizuta H, et al. Morphological study, by teasing examination, of the communication from the musculocutaneous to median nerves. Anat Sci Int. 2009;84(1-2):41-6.
 7. Guerri-Guttenberg RA, Inglolotti M. Classifying musculocutaneous nerve variations. Clin Anat. 2009;22(6):671-83.
 8. Maeda S, Kawai K, Koizumi M, Ide J, Tokiyoshi A, Mizuta H, et al. Morphological study of the communication between the musculocutaneous and median nerves. Anat Sci Int. 2009;84(1-2):34-40.
 9. Gujar S, Savita G, Shah GV, Bondre KV. Unilateral variation in musculocutaneous nerve – a case report. IJABMS. 2012;14(18):1-6.
 10. Beheiry Eman E. Anatomical variations of the median nerve distribution and communication in the arm. Folia Morphol. 2004;63(3):313-8.