

Nerve Graft and Nerve Transfer for Improving Elbow Flexion in Children with Obstetric Palsy. A Systematic Review*

Enxerto e transferência de nervo para melhora da flexão do cotovelo em crianças com paralisia obstétrica. Uma revisão sistemática

Eduardo Velásquez-Girón¹ James A. Zapata-Copete²

¹ Orthopedic Hand Surgery Section, Department of Surgery, Universidad del Valle, Cali, Colombia

² Department of Surgery, Plastic Surgery Section, Universidad del Valle, Cali, Colombia

Address for correspondence Eduardo Velásquez Girón, MD, MSc, Department of Surgery, Orthopedic Hand Surgery Section, Universidad del Valle, Street 4b # 36-00, Cali, Colombia (e-mail: eduardo.velasquez@correounivalle.edu.co).

Rev Bras Ortop 2021;56(6):705–710.

Abstract

Obstetric brachial plexus palsy is a rather common injury in newborns, caused by traction to the brachial plexus during labor. In this context, with the present systematic review, we aimed to explore the use of nerve graft and nerve transfer as procedures to improve elbow flexion in children with obstetric palsy. For the present review, we followed the Preferred Reporting Items for Systematic Reviews and Meta-Analyses (PRISMA) guidelines. We searched the MEDLINE, EMBASE, LILACS, The Cochrane Central Register of Controlled Trials, Web of Science, Wholis and SCOPUS databases. Predetermined criteria defined the following requirements for inclusion of a study: Clinical trials, quasi-experiments, and cohort studies that performed nerve graft and nerve transfer in children (≤ 3 years old) with diagnosis of obstetric palsy. The risk of bias in nonrandomized studies of interventions assessment tool was used for nonrandomized studies. Out of seven studies that used both procedures, three of them compared the procedures of nerve graft with nerve transfer, and the other four combined them as a reconstructive method for children with obstetric palsy. According to the Medical Research Council grading system, both methods improved equally elbow flexion in the children. Overall, our results showed that both techniques of nerve graft and nerve transfer are equally good options for nerve reconstruction in cases of obstetric palsy. More studies approaching nerve reconstruction techniques in obstetric

Keywords

- ▶ obstetrical brachial plexus palsy
- ▶ nerve transfer
- ▶ allogenic grafts

* Work developed at the Orthopedic Hand Surgery Section, Department of Surgery, Universidad del Valle, Cali, Colombia.

received
August 31, 2020
accepted
December 17, 2020
published online
August 13, 2021

DOI <https://doi.org/10.1055/s-0041-1729586>.
ISSN 0102-3616.

© 2021. Sociedade Brasileira de Ortopedia e Traumatologia. All rights reserved.
This is an open access article published by Thieme under the terms of the Creative Commons Attribution-NonDerivative-NonCommercial-License, permitting copying and reproduction so long as the original work is given appropriate credit. Contents may not be used for commercial purposes, or adapted, remixed, transformed or built upon. (<https://creativecommons.org/licenses/by-nc-nd/4.0/>)
Thieme Revinter Publicações Ltda., Rua do Matoso 170, Rio de Janeiro, RJ, CEP 20270-135, Brazil

palsy should be made, preferably randomized clinical trials, to validate the results of the present systematic review.

Resumo

A paralisia obstétrica do plexo braquial é uma lesão bastante comum em neonatos, sendo causada pela tração do plexo braquial durante o trabalho de parto. A presente revisão sistemática tem como objetivo explorar o uso de enxertos e transferências de nervo como procedimentos para melhora da flexão do cotovelo em crianças com paralisia obstétrica. A presente revisão sistemática seguiu as diretrizes Preferred Reporting Items for Systematic Reviews and Meta-Analyses (PRISMA, na sigla em inglês) e foi baseada em pesquisa nos bancos de dados MEDLINE, EMBASE, LILACS, The Cochrane Central Register of Controlled Trials, Web of Science, Wholis e SCOPUS. De acordo com os critérios pré-determinados, os artigos incluídos eram ensaios clínicos, quase-experimentos, e estudos de coortes sobre enxertos e transferências de nervos em crianças (de até 3 anos de idade) com diagnóstico de paralisia obstétrica. A ferramenta de avaliação Risk of Bias in Non-Randomized Studies of Interventions foi usada em estudos não randomizados. Sete estudos utilizaram os dois procedimentos; três deles compararam os procedimentos de enxerto e transferência de nervo, enquanto os outros quatro os combinaram como método reconstrutivo em crianças com paralisia obstétrica. Segundo o sistema de classificação do Medical Research Council, os dois métodos melhoraram a flexão do cotovelo das crianças de maneira similar. De modo geral, nossos resultados mostraram que o enxerto de nervo e a transferência de nervo são opções igualmente boas para a reconstrução nervosa em casos de paralisia obstétrica. Mais estudos sobre as técnicas de reconstrução nervosa na paralisia obstétrica devem ser realizados, de preferência ensaios clínicos randomizados, para validação dos resultados dessa revisão sistemática.

Palavras-chave

- ▶ paralisia do plexo braquial neonatal
- ▶ transferência de nervo
- ▶ enxertos alogênicos

Introduction

Obstetric brachial plexus injury (OBPI) or obstetric brachial plexus palsy (OBPP) is a rather common injury in newborns that can have a spontaneous recovery,¹ but it varies from 30% to 90%. This injury is caused by traction to the brachial plexus during labor, and the extent of neural damage can only be assessed by evaluating recovery in the course of time.² Its incidence varies between 0.15 and 3 cases per 1.000 live births.² The classical injury is a C5, C6 palsy, but all roots can be involved.¹

Nerve grafting has been performed in neonatal population with brachial plexus palsy for > 30 years, and it is recommended for patients who present with postganglionic rupture of the upper nerve roots of the brachial plexus (C5 and C6).³ On the other hand, nerve transfer surgery is usually indicated in cases of late presentation, failed primary nerve reconstruction, isolated deficit, absence of proximal root for grafting, and multiple nerve root avulsions.³ Nerve transfer surgery involves taking nerve branches from a neighboring nerve and redirecting them to the distal end of the injured nerve.⁴ After the surgery, the body regenerates axons along the new path, and the motor cortex rewires itself to relearn muscle functions.⁴

There are several experimental reports in which allograft nerve has been used as an alternative to nerve autograft to bridge two ends of a nerve together, both in nonhuman and

human primates.⁵ Allograft tissue would serve as a temporary scaffold in which it enhances neural regeneration by providing the essential structural characteristics of the nerve tissue.⁶ Restoration of elbow flexion is of great importance and it is one of the highest priorities of brachial plexus reconstruction,⁷ and one of the most commonly grading system to assess this recovery has been the Medical Research Council (MRC) grading system.^{8,9} In this context, with the present systematic review, we aimed to explore the use of nerve graft and nerve transfer as procedures to improve elbow flexion in children with OBPP.

Methods

The present systematic review was performed according to the Preferred Reporting Items for Systematic reviews and Meta-Analyses (PRISMA).¹⁰ We searched the MEDLINE, EMBASE, LILACS, The Cochrane Central Register of Controlled Trials (CENTRAL), Web of Science, Wholis, and SCOPUS databases. In the search, we included terms in English, Spanish and Portuguese using the search equation: $E = (P1 \text{ AND } P2 \text{ NOT } (P3 \text{ OR } P4)) \text{ AND } I \text{ AND } O$. The Patient/Population, Intervention, Comparison and Outcomes (PICO) question was: What is the evidence of elbow flexion improvement with the nerve graft or nerve transfer technique in children with OBPP? We did not restrict the search by time (Supplementary material 1).

Selection Criteria

Predetermined criteria defined the following requirements for inclusion of a study: clinical trials, quasi-experiments, and cohort studies that performed nerve graft and nerve transfer in children (≤ 3 years old) with diagnosis of OBPP. For all outcomes, the studies had to have at least 6 months of follow-up. All comparative studies of graft versus transfer reported relevant outcomes regarding the muscle strength measured by the MRC.

Data Extraction

Independent and blinded reviewers extracted data from eligible studies. The variables of abstraction included: author, year of the study, study design, number of patients for either procedure, age at surgery, gender, injuries, follow-up period, and donor nerve for either procedure. The primary outcome was to explore the use of nerve graft and nerve transfer in children with OBPP, and the secondary outcome was the recovery of elbow flexion following both procedures, assessed by strength by the MRC after the procedure. The MRC grading system consists of 5 grades: 0 represents no contraction, 1 represents flicker or trace of contraction, 2 represents active movement with gravity eliminated, 3 represents active movement against gravity, 4 represents active movement against gravity and resistance, and 5 represents normal power.⁸ Two researchers reviewed each study found in the databases by title and abstract, selecting the more adequate ones. Subsequently, they reviewed the full texts of previously selected articles and screened them according to the inclusion criteria. With the studies finally selected, we extracted the data. Disagreements were resolved by consensus, and where disagreement could not be solved, one of the two reviewers solved the conflict.

Risk of Bias Assessment

The Risk of Bias in Non-Randomized Studies of Interventions (ROBINS-I) assessment tool¹¹ was used for nonrandomized studies. This tool includes 7 specific bias domains: 1 - confounding; 2 - selection of participants; 3 - classification of intervention; 4 - deviation from interventions; 5 - missing outcome data; 6 - measurement of outcomes; and 7 - selection of reported overall result. Risk of bias was rated as: 0 - no information; 1 - low risk; 2 - moderate risk; 3 - serious risk; and 4 - critical risk. Two authors assessed independently the risk of bias of the included articles. Disagreements were managed by consensus.

Strategy for Data Analysis

The statistical analysis for categorical variables consisted in percentages, frequencies and measures of central tendency.

Results

From our literature search in the different databases, we found 344 records after removal of duplicates. Following the screening of titles and abstracts, 44 studies were eligible for full-text evaluation. Finally, seven studies were included in the systematic review, as presented in the PRISMA Flow Diagram (**► Fig. 1**). Disagreements were managed by consensus.

Study Characteristics

Seven studies were selected, three of which compared the procedures of nerve graft for 59 patients and of nerve transfer for 34 patients, having a total number of 93 patients (**► Table 1**). On the other hand, four of them did not compare procedures, but used them as a reconstructive method for children with OBPP (**► Table 1**). For the studies that compared nerve graft with nerve transfer, the age at surgery ranged from 5.7 to 18 months old, and the follow-up period ranged from 12 to 70 months. Meanwhile, the age at surgery of the studies that combined both procedures ranged from 3.5 to 23 months old, and the follow-up period ranged from 24.3 to 85 months. Only two of the selected studies had all data necessary to compare the elbow flexion outcome evaluated with the MRC after the nerve grafting or nerve transfer surgeries (**► Table 2**).

Risk of Bias Assessment

Risk of bias assessment for the studies was evaluated using the ROBINS-I tool (Supplementary material 2). Only the three studies that compared the procedures of nerve graft with nerve transfer were included in this assessment. In domains 3 and 6, 3 out of 3 studies were rated as low risk; in domain 7, 3 out of 3 studies were rated as moderate; in domains 2 and 4, one-third was rated as moderate; in domains 1 and 5, one-third was rated as serious; overall, two studies were rated as presenting moderate, and one as presenting serious risk of bias.

Discussion

Our objective was to explore the use of nerve graft and nerve transfer as procedures to improve elbow flexion in children with OBPP. Here, we found seven studies that used both procedures, three of them compared the procedures of nerve graft and nerve transfer, as the other four combined them as a reconstructive method for children with OBPP. According to the MRC scale, both methods equally improved the elbow flexion in the children, which is coincident with previous studies.¹²

Chang et al.³ found similar improvement for elbow flexion in abduction and adduction for both groups of infants who underwent Oberlin transfer versus nerve grafting, with no statistical significance. According to the authors, nerve transfer should be considered in cases such as late presentation, failed primary nerve reconstruction, absence of proximal root for grafting, and multiple nerve root avulsions (preganglionic lesion). Likewise, Luszawski et al.¹³ reported the results of children with OBPP lesions operated with the nerve graft or nerve transfer technique. The authors do not show the results of all patients after the follow-up period, but 100% of the patients submitted to nerve transfer (only 1 shown) had biceps muscle recovery to an MRC grade $> M3$. On the other hand, 77% of the patients (10 out of 13 shown) submitted to nerve graft had biceps muscle recovery to an MRC grade $> M3$. On the other hand, Malessy et al.,¹⁴ in their study, divided patients into Group A and Group B, depending on the procedures performed. In group A, 17 infants received transfer of either the C6 anterior root filaments with direct coaptation in 15 of them, or the entire C6 nerve to C5. Likewise, Group B comprised 17 infants;

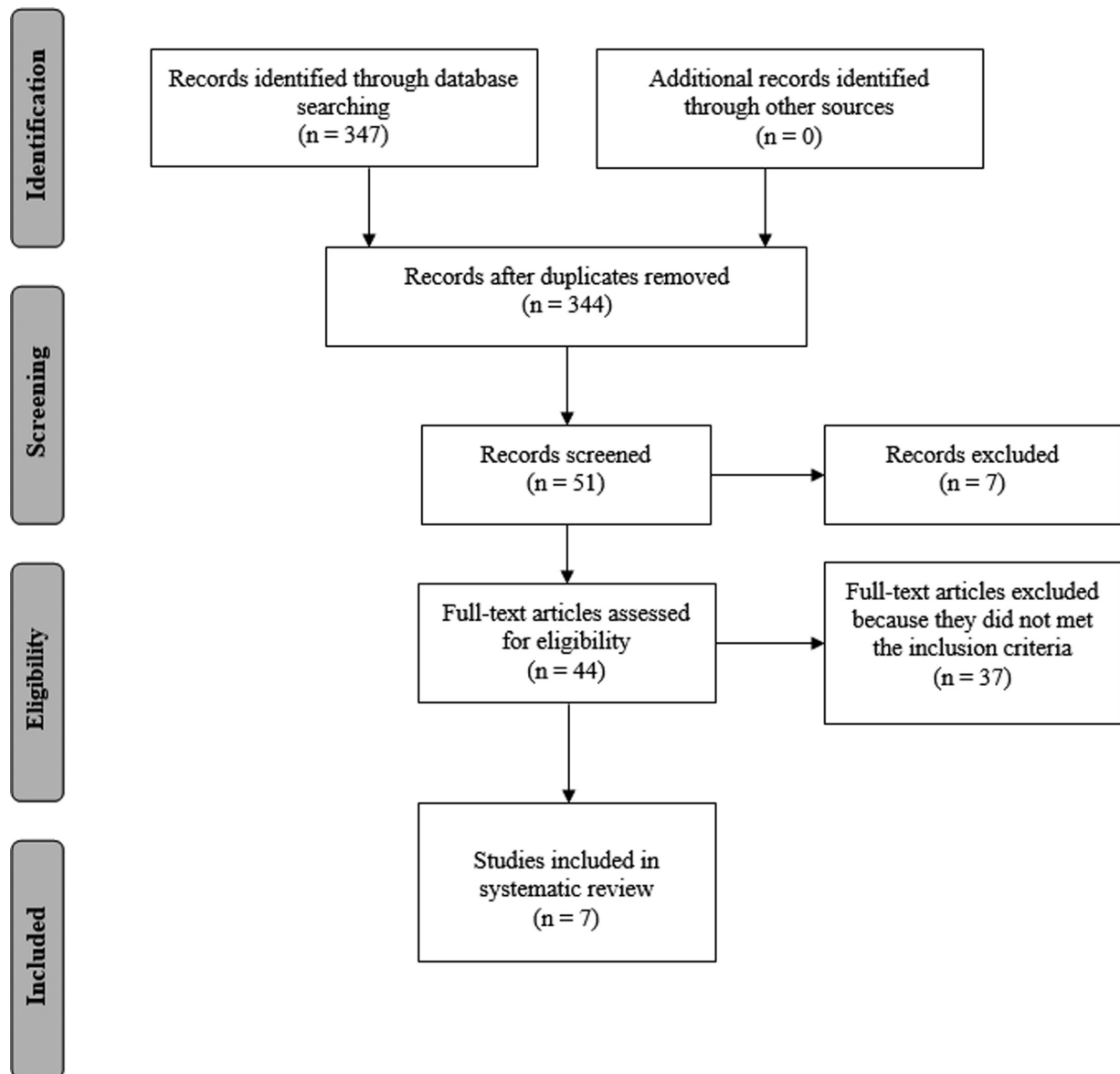


Fig. 1 PRISMA flow diagram of selected studies

in this case, who received grafting from C5 to the anterior division of the superior trunk. According to the authors, all infants, independently of the type of surgery performed, had biceps muscle recovery to a, MRC grade > M4. After this study, another study by Yang et al.¹⁵ also proved the viability of restoring a C5 and C6 avulsion of the brachial plexus with an extradural nerve anastomosis technique.

In the study by Bhandari et al.,¹⁶ the authors used neurolysis and nerve graft combined with nerve transfer as surgical procedures for nerve reconstruction in children with OBPP. Neurolysis was indicated for neuroma-in-continuity,¹⁷ and nerve grafts were used to bridge the nerve defects, once the nonconducting neuromas were resected, and nerve transfers were indicated in avulsion and irreparable nerve root injuries.¹⁸ The patients with total palsy received nerve transfer and nerve graft when the nerve to be transferred was insufficient in length, achieving 70% of biceps recovery. The authors believe that indications for neurolysis in OBPP are very few, and the

results are far superior with resection of neuroma followed by nerve grafting in infants aged between 3 and 4 months old. This statement has been widely confirmed by many studies that showed better results of nerve reconstructions in younger children.^{14,19} Furthermore, Birch et al.²⁰ found no statistical difference between a repair of C5 by graft or by nerve transfer. Moreover, Terzis et al.²¹ found that, overall, 78% of the extremities that underwent nerve reconstruction surgery achieved good and excellent results (M3+). According to the authors, late reconstruction (~ 7 months) of the MCN resulted in inferior results, and infants with C5-C6 palsy achieved significantly stronger elbow flexion than those with global palsy. Xu et al.²² selected patients that had no recovery of biceps contraction by the age of 3 months old. The procedure of nerve transfer and grafting combined was performed in 10 patients with OBPP; excellent and good results in elbow flexion were found in 70% of the patients in the nerve transfer and grafting group. Also, 80% of the infants had biceps muscle

Table 1 Characteristics of the studies included in the systematic review that used nerve graft and nerve transfer

Studies that compared nerve graft versus nerve transfer									
Author, year	Country	Study design	(n) Nerve graft	(n) Nerve transfer	Age at surgery (months old)	Age at surgery (nerve graft) (months old)	Age at surgery (nerve transfer) (months old)	Female %	Follow-up period (months)
Chang et al. 2018, ³	USA	Retrospective cohort study	28	12	6	< 18	7	62%	12
Luszwski et al. 2017, ¹³	Poland	Retrospective study	14	5	< 18	< 18	< 18	NS	> 12
Malessy et al. 2014, ¹⁴	Netherlands	Retrospective study	17	17	5.7	5.7	5.7	56%	70
Studies that used nerve graft and nerve transfer combined									
Author, year	Country	Study design	(n)	Age at surgery (months old)	Female %	Follow-up period (months)			
Bhandari et al. 2015 ¹⁶	India	Retrospective study	32	3.5 to 23	NS	24.3			
Birch et al. 2005 ²⁰	England	Prospective study	100	7	45%	85			
Terzis et al 2009 ²¹	USA	Retrospective study	23	14	44%	78			
Xu et al. 2000 ²²	China	Retrospective study	10	4.5	40%	44.3			

Abbreviation: NS, not specified.

Table 2 Medical Research Council values of studies that compared nerve graft versus nerve transfer

Author	Injury	MRC nerve transfer PO (%)	Injury	MRC nerve graft PO (%)	p-value
Chang et al. 2018 ³	C5-C6, C5-C7, C5-T1, C5-T1+ Horner sign	M3 (NS)	C5-C6, C5-C7, C5-T1, C5-T1+ Horner sign	M2 (NS)	0.77
Luszwski et al. 2017 ¹³	C5-C7	> M3 (100%)	C5-C6, C5-C7, C5-T1	> M3 (77%)	NS
Malessy & Pondaag, 2014 ¹⁴	C5-C6 anterior root filament C5-C6	≥M4 (100%) ≥M4 (100%)	C5-anterior division of superior trunk	≥M4 (100%)	NS

Abbreviations: MRC, Medical Research Council grading system; NS, not specified; PO, postoperative.

recovery to an MRC grade of M3+. According to the authors, the results show that nerve transfer combined with nerve graft is the best option to manage resection of the neuroma and reconstruction of the brachial plexus, that infant nerves have more regeneration capacity,²³ and that a shorter distance for axons to reach the end organ²⁴ results in a better surgery outcome.

Conclusions

Overall, our results showed that both techniques of nerve graft and nerve transfer are good options for nerve reconstruction in cases of OBPP. The present study has various limitations, one of them being that all included studies were nonrandomized studies. In addition, the injury type, the surgical approach, and the follow-up time were inconsistent in the selected studies. More studies approaching the nerve reconstruction techniques in OBPP should be made, preferably randomized clinical trials to validate the results of the present systematic review.

Authors Contributions

Girón E. V. and Zapata-Copete J. A. contributed substantially to the conception, design of the work, acquisition, analysis, and interpretation of data for the work. Girón E. V. and Zapata-Copete J. A. contributed to the drafting of the work and revised it critically for important intellectual content. Girón E. V. and Zapata-Copete J. A. approved the final version to be published. Girón E. V. and Zapata-Copete J. A. agreed to be accountable for all aspects of the work in ensuring that questions related to the accuracy or to the integrity of any part of the work are appropriately investigated and resolved.

Financial Support

There was no financial support from public, commercial, or non-profit sources.

Conflict of Interests

The authors have no conflict of interests to declare.

References

- 1 Thatte MR, Mehta R. Obstetric brachial plexus injury. *Indian J Plast Surg* 2011;44(03):380–389
- 2 Pondaag W, Malessy MJ, van Dijk JG, Thomeer RT. Natural history of obstetric brachial plexus palsy: a systematic review. *Dev Med Child Neurol* 2004;46(02):138–144
- 3 Chang KWC, Wilson TJ, Popadich M, Brown SH, Chung KC, Yang LJS. Oberlin transfer compared with nerve grafting for improving early supination in neonatal brachial plexus palsy. *J Neurosurg Pediatr* 2018;21(02):178–184
- 4 Karamanos E, Rakitin I, Dream S, Siddiqui A. Nerve Transfer Surgery for Penetrating Upper Extremity Injuries. *Perm J* 2018;22:17–156
- 5 Moore AM, MacEwan M, Santosa KB, et al. Acellular nerve allografts in peripheral nerve regeneration: a comparative study. *Muscle Nerve* 2011;44(02):221–234
- 6 Chen S, Chen Z-G, Dai H, et al. Repair, protection and regeneration of peripheral nerve injury. *Neural Regen Res* 2015;10(11):1777–1798
- 7 Siqueira M, Martins R, Fagioni W Junior, Foroni L, Heise C. Restoration of Elbow Flexion in Traumatic Upper Brachial Plexus Palsy in Adults: Outcome with Intraplexus Distal Nerve Transfers in 78 Patients. *Arq Bras Neurocir* 2018;37(04):285–290
- 8 James MA. Use of the Medical Research Council muscle strength grading system in the upper extremity. *J Hand Surg Am* 2007;32(02):154–156
- 9 Bhardwaj P, Bhardwaj N. Motor grading of elbow flexion - is Medical Research Council grading good enough? *J Brachial Plex Peripher Nerve Inj* 2009;4:3
- 10 Urrútia G, Bonfill X. [PRISMA declaration: a proposal to improve the publication of systematic reviews and meta-analyses]. *Med Clin (Barc)* 2010;135(11):507–511
- 11 Sterne JAC, Hernán MA, Reeves BC, et al. ROBINS-I: a tool for assessing risk of bias in non-randomised studies of interventions. *BMJ* 2016;355:i4919
- 12 Tora MS, Hardcastle N, Texakalidis P, Wetzel J, Chern JJ. Elbow flexion in neonatal brachial plexus palsy: a meta-analysis of graft versus transfer. *Childs Nerv Syst* 2019;35(06):929–935
- 13 Luszczawski J, Marcol W, Mander M. The components of shoulder and elbow movements as goals of primary reconstructive operation in obstetric brachial plexus lesions. *Neurol Neurochir Pol* 2017;51(05):366–371
- 14 Malessy MJA, Pondaag W. Neonatal brachial plexus palsy with neurotmesis of C5 and avulsion of C6: supraclavicular reconstruction strategies and outcome. *J Bone Joint Surg Am* 2014;96(20):e174
- 15 Yang KX, Zhang SH, Ge DW, Sui T, Chen HT, Cao XJ. A novel extradural nerve transfer technique by coaptation of C4 to C5 and C7 to C6 for treating isolated upper trunk avulsion of the brachial plexus. *J Biomed Res* 2018;32(04):298–304
- 16 Bhandari P. Functional Outcomes of Nerve Reconstruction in Severe Obstetric Brachial Plexus Palsy. *Indian J Neurotrauma* 2015;12(01):41–48
- 17 Andrišević E, Taniguchi M, Partington MD, Agel J, Van Heest AE. Neurolysis alone as the treatment for neuroma-in-continuity with more than 50% conduction in infants with upper trunk brachial plexus birth palsy. *J Neurosurg Pediatr* 2014;13(02):229–237
- 18 Bhandari PS, Sadhotra LP, Bhargava P, et al. Surgical outcomes following nerve transfers in upper brachial plexus injuries. *Indian J Plast Surg* 2009;42(02):150–160
- 19 Al-Qattan MM, Al-Kharfy TM. Median nerve to biceps nerve transfer to restore elbow flexion in obstetric brachial plexus palsy. *BioMed Res Int* 2014;2014:854084
- 20 Birch R, Ahad N, Kono H, Smith S. Repair of obstetric brachial plexus palsy: results in 100 children. *J Bone Joint Surg Br* 2005;87(08):1089–1095
- 21 Terzis JK, Kokkalis ZT. Elbow flexion after primary reconstruction in obstetric brachial plexus palsy. *J Hand Surg Eur Vol* 2009;34(04):449–458
- 22 Xu J, Cheng X, Gu Y. Different methods and results in the treatment of obstetric brachial plexus palsy. *J Reconstr Microsurg* 2000;16(06):417–420, discussion 420–422
- 23 Donega V, van Velthoven CT, Nijboer CH, Kavelaars A, Heijnen CJ. The endogenous regenerative capacity of the damaged newborn brain: boosting neurogenesis with mesenchymal stem cell treatment. *J Cereb Blood Flow Metab* 2013;33(05):625–634
- 24 Huelke DF. An Overview of Anatomical Considerations of Infants and Children in the Adult World of Automobile Safety Design. *Annu Proc Assoc Adv Automot Med* 1998;42:93–113