

Posterior Atlantoaxial Screw Placement in a Portuguese Population: A Morphometric Analysis Based on Computed Tomography Scan Measurements

Colocação de parafusos atlantoaxiais posteriores em uma população portuguesa: Uma análise morfométrica baseada em medidas de tomografia computadorizada

Rita Santos Martins^{1,2} Catarina Silva Pereira¹ Carolina Lemos^{2,3} Ricardo Rodrigues-Pinto^{1,2,4}

¹Department of Orthopedics, Centro Hospitalar Universitário do Porto, Porto, Portugal

²Instituto de Ciências Biomédicas Abel Salazar, Porto, Portugal

³Instituto de Investigação e Inovação em Saúde, Universidade do Porto, Porto, Portugal

⁴Spinal Unit, Department of Orthopedics, Centro Hospitalar Universitário do Porto, Porto, Portugal

Address for correspondence Ricardo Rodrigues-Pinto, PhD, Spinal Unit (UVM), Department of Orthopaedics, Centro Hospitalar Universitário do Porto, Largo do Prof. Abel Salazar, Porto, 4099-001, Portugal (e-mail: ric_pinto@hotmail.com).

Rev Bras Ortop 2023;58(1):48–57.

Abstract

Keywords

- ▶ atlantoaxial joint
- ▶ bone screws
- ▶ cervical vertebrae
- ▶ joint instability
- ▶ surgical fixation devices

Objective The present study aims to evaluate the screw length and trajectory angles for posterior atlantoaxial fixation in a Portuguese population, through the study of cervical computed tomography (CT) scans.

Methods Cervical CT scans of 50 adults were measured according to predefined screw trajectories of C1-C2 transarticular (C1C2TA), C1 lateral mass (C1LM), C2 pedicle (C2P), C2 pars and C2 laminar (C2L) screws. For each of these trajectories, screw length and angles were measured and compared between males and females.

Results For the C1C2TA screw trajectory, the mean length, medial, and cranial angles were 34.12 ± 3.19 mm, $6.24^\circ \pm 3.06$, and $59.25^\circ \pm 5.68$, respectively, and for the C1LM screw trajectory, they were 27.12 ± 2.15 mm, $15.82^\circ \pm 5.07$, and $13.53^\circ \pm 4.80$, respectively. The mean length, medial, and cranial angles for the C2P screw trajectory

Introduction

Work developed at the Department of Orthopaedics, Centro Hospitalar Universitário do Porto, Porto, Portugal.

The atlantoaxial (C1–C2) joint has a close relationship with several vascular and neural structures, such as the vertebral

received
January 2, 2022
accepted
January 20, 2022

DOI <https://doi.org/10.1055/s-0042-1744502>.
ISSN 0102-3616.

© 2022. Sociedade Brasileira de Ortopedia e Traumatologia. All rights reserved.

This is an open access article published by Thieme under the terms of the Creative Commons Attribution-NonDerivative-NonCommercial-License, permitting copying and reproduction so long as the original work is given appropriate credit. Contents may not be used for commercial purposes, or adapted, remixed, transformed or built upon. (<https://creativecommons.org/licenses/by-nc-nd/4.0/>)

Thieme Revinter Publicações Ltda., Rua do Matoso 170, Rio de Janeiro, RJ, CEP 20270-135, Brazil

were 23.44 ± 2.49 mm, $27.40^\circ \pm 4.88$, and $30.41^\circ \pm 7.27$, respectively; and for the C2 pars screw trajectory, they were 16.84 ± 2.08 mm, $20.09^\circ \pm 6.83$, and $47.53^\circ \pm 6.97$. The mean length, lateral, and cranial angles for the C2L screw trajectory were 29.10 ± 2.48 mm, $49.80^\circ \pm 4.71$, and $21.56^\circ \pm 7.76$, respectively. There were no gender differences except for the lengths of the C1C2TA ($p = 0,020$) and C2L ($p = 0,001$) screws, which were greater in males than in females.

Conclusion The present study provides anatomical references for the posterior atlantoaxial fixation in a Portuguese population. These detailed data are essential to aid spine surgeons to achieve safe and effective screw placement.

Resumo

Objetivo O presente estudo tem como objetivo avaliar o comprimento e os ângulos de trajetória do parafuso para fixação atlantoaxial posterior em uma população portuguesa por meio do estudo de tomografia computadorizada (TC) cervical.

Métodos Tomografias computadorizadas cervicais de 50 adultos foram analisadas quanto às trajetórias pré-definidas dos parafusos transarticulares C1–C2 (C1C2TA), na massa lateral de C1 (C1LM), no pedículo de C2 (C2P) e na *pars* de C2 e C2 laminar (C2L). O comprimento e os ângulos dos parafusos em cada uma destas trajetórias foram medidos e comparados entre homens e mulheres.

Resultados O comprimento médio e ângulos medial e cranial da trajetória do parafuso C1C2TA foram de $34,12 \pm 3,19$ mm, $6,24^\circ \pm 3,06$ e $59,25^\circ \pm 5,68$, respectivamente; as medidas da trajetória do parafuso C1LM foram $27,12 \pm 2,15$ mm, $15,82^\circ \pm 5,07$ e $13,53^\circ \pm 4,80$. O comprimento médio e os ângulos medial e cranial da trajetória do parafuso C2P foram de $23,44 \pm 2,49$ mm, $27,40^\circ \pm 4,88$ e $30,41^\circ \pm 7,27$, respectivamente; as medidas da trajetória do parafuso da *pars* de C2 foram $16,84 \pm 2,08$ mm, $20,09^\circ \pm 6,83$ e $47,53^\circ \pm 6,97$. O comprimento médio e ângulos lateral e cranial da trajetória do parafuso C2L foram de $29,10 \pm 2,48$ mm, $49,80^\circ \pm 4,71$ e $21,56^\circ \pm 7,76$, respectivamente. Não houve diferenças entre os gêneros, à exceção do comprimento dos parafusos C1C2TA ($p = 0,020$) e C2L ($p = 0,001$), que foi maior no sexo masculino do que no feminino.

Conclusão O presente estudo fornece referências anatômicas para a fixação atlantoaxial posterior em uma população portuguesa. Estes dados detalhados são essenciais para ajudar os cirurgiões de coluna a colocar os parafusos de maneira segura e eficaz.

Palavras-chave

- ▶ articulação atlantoaxial
- ▶ parafusos ósseos
- ▶ vértebra cervical
- ▶ instabilidade articular
- ▶ dispositivos de fixação cirúrgica

artery (VA), atlas (C1) and axis (C2) nerve roots, and the vertebral venous plexus.¹

The C1-C2 complex contributes with 50% of the cervical spine rotation capacity and is formed by the atlanto-odontoid joint and the lateral atlantoaxial joints. These joints, together with the cruciform, the alar, and the apical ligaments are responsible for the stability of the atlantoaxial complex. Without this ligament stability, spinal cord compression may occur, which can lead to tetraparesis or even sudden death.²

Trauma, congenital malformations, neoplasms, infections, and inflammatory diseases, such as rheumatoid arthritis³ and ankylosing spondylitis,⁴ have been implicated in the development of C1-C2 instability.³ Even though conservative management can be appropriate for some patients, surgical intervention is often necessary.²

Several posterior atlantoaxial fixation techniques were utilized until the development of the screw-rod technique widely used today.⁵ However, due to the anatomical proximity to neurovascular structures, posterior atlantoaxial fixa-

tion with screws is associated with potentially serious complications, depending on the choice of the surgical technique. The complications that may occur include vascular and neurological injuries, bony nonunion, screw breakage, and surgical site infection.³

Therefore, spine surgeons must be familiar with the different posterior atlantoaxial fusion techniques, along with in-depth anatomical knowledge, to minimize the complications inherent to the surgery.

The goal of the present study was to assess the length and trajectory angles for posterior atlantoaxial screw placement in a Portuguese population, through the study of cervical computed tomography (CT) scans performed at the Centro Hospitalar Universitário do Porto, Porto, Portugal.

Methods

The present single-center retrospective study included all patients in the SECTRA IDS7 (version 17.3.2086) database

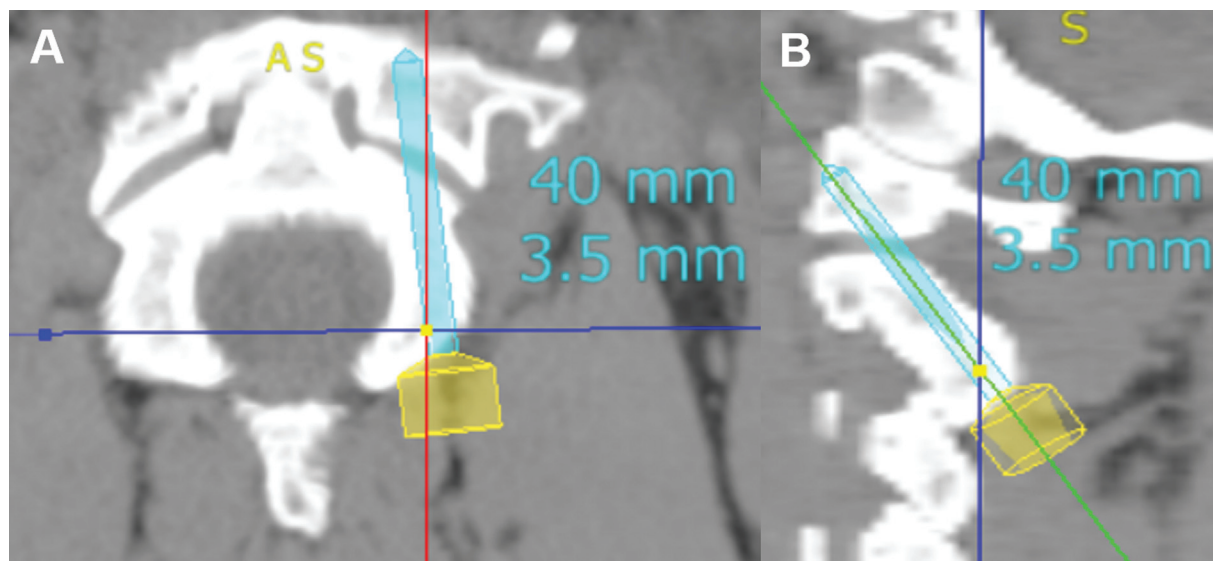


Fig. 1 C1C2TA screw trajectory measurement. C1C2TA screw in the axial plane (A) and in the sagittal plane (B).

who underwent a cervical CT scan from October 10, 2020 to January 11, 2021 and was approved by the local ethics committee (REF. 2021.042(035-DEFI/036-CE)).

A total of 217 clinical files were analyzed and 167 were excluded for having incomplete CT scans, cervical fractures, bone neoplasms, cervical degenerative diseases including disc herniation, presence of osteophytes and spondylolisthesis, cervical scoliosis, history of cervical surgery, and inflammatory diseases such as rheumatoid arthritis and ankylosing spondylitis. The remaining 50 CT scans were analyzed using Surgimap version 2.3.2.1 (Nemaris Inc., New York, NY, USA).

The measurements were performed based on predefined screw trajectories of C1-C2 transarticular (C1C2TA), C1 lateral mass (C1LM), C2 pedicle (C2P), C2 pars, and C2 laminar (C2L) screws. All screw measurements were made by two investigators to reduce bias.

The screw length, medial, lateral, and cranial angles were measured on the right side of C1 and C2 vertebrae. All screws were placed unicortically with the maximum length allowed without crossing the anterior cortex of the vertebrae and it was ensured that the bone height and width could safely accommodate a 3.5-mm diameter screw.

The medial and lateral angles, in the axial plane, were obtained by measuring the angle formed by the intersection of the predefined screw trajectory and the longitudinal midline of the respective vertebra. In the sagittal plane, the cranial angle for the C1LM screw trajectory was the angle between the endplate of C1 and the screw trajectory line. For the C1C2TA, C2P, C2 pars, and C2L screw trajectories, the cranial angle was the angle made by the screw trajectory line and the line parallel to the C2 inferior vertebral body border.

C1-C2 Transarticular Screw

The starting point used for the C1C2TA screw trajectory was 3 mm lateral and 3 mm superior to the medial border of the C2-C3 facet joint. The trajectory was directed medially in the

axial plane and toward the C1 anterior arch in the sagittal plane (►Fig. 1).⁶

C1 Lateral Mass Screw

For the C1LM screw trajectory, the starting point used was at the intersection of the lower edge of the C1 posterior arch with the midpoint of the C1 lateral mass. The trajectory was convergent toward the C1 anterior arch and parallel to the C1 posterior arch in the sagittal plane (►Fig. 2).⁷

C2 Pedicle Screw

For the C2P screw trajectory, the starting point used was the midpoint between the superior and inferior C2 articular processes. The trajectory was directed medially and cranially to the C2 anterior cortex (►Fig. 3).⁸

C2 Pars Screw

The starting point used for C2 pars screw trajectory was 3 mm lateral and 3 mm superior to the medial border of the C2-C3 facet joint. The trajectory was directed medially and cranially, parallel to the C2 pars in the sagittal plane and parallel to the medial border of the pars in the axial plane (►Fig. 4).⁸

C2 Laminar Screw

For the C2LS trajectory, the starting point used was at the junction of the C2 spinous process and the lamina, with the screw trajectory being directed parallel to the downslope of the contralateral lamina (►Fig. 5).⁹

Statistical Analysis

An interobserver reliability analysis using Cohen Kappa statistic was performed to determine the agreement between investigators.

Additionally, descriptive statistics were calculated. To identify statistically significant differences between gender, a statistical analysis of the data was performed using a *t*-test

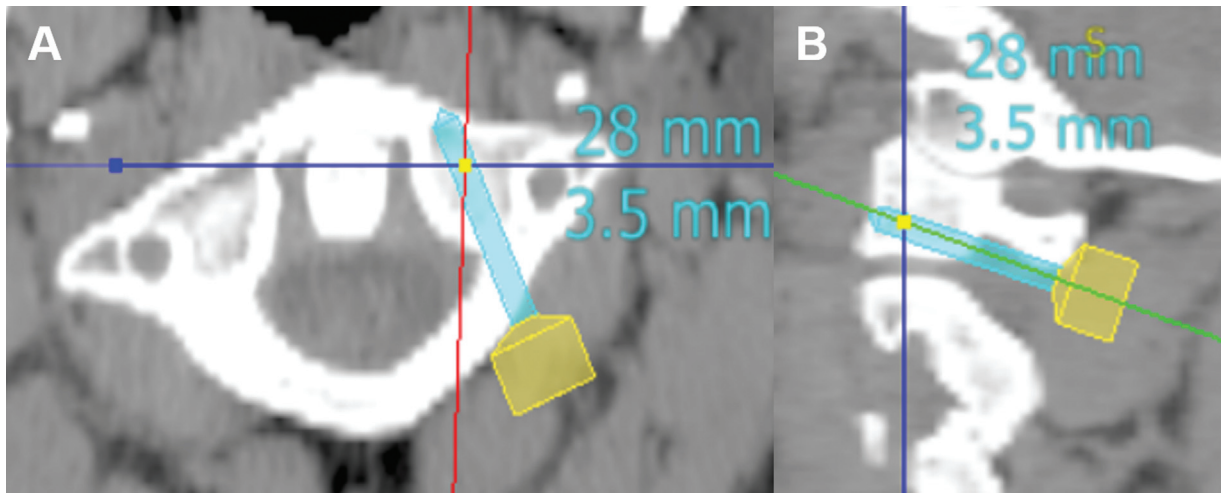


Fig. 2 C1LM screw trajectory measurement. C1LM screw in the axial plane (A) and in the sagittal plane (B).

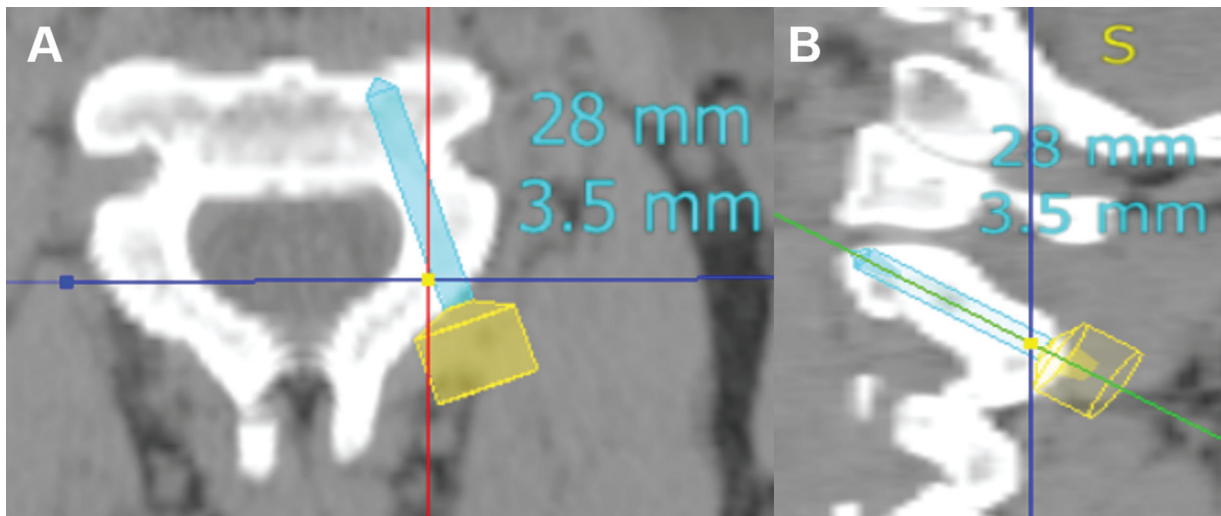


Fig. 3 C2P screw trajectory measurement. C2P screw in the axial plane (A) and in the sagittal plane (B).

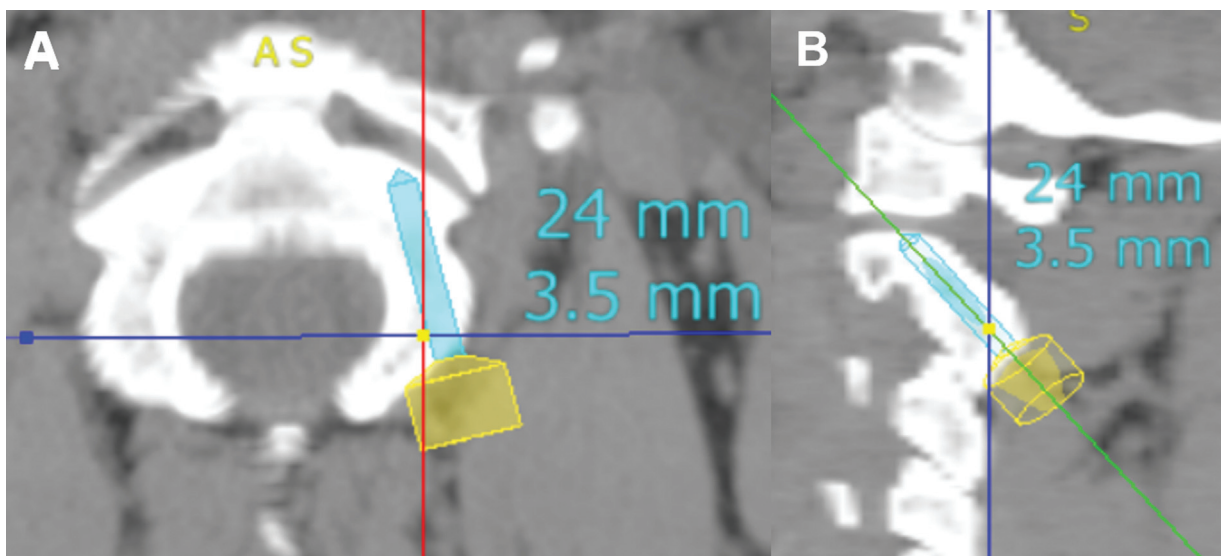


Fig. 4 C2 pars screw trajectory measurement. C2 pars screw in the axial plane (A) and in the sagittal plane (B).

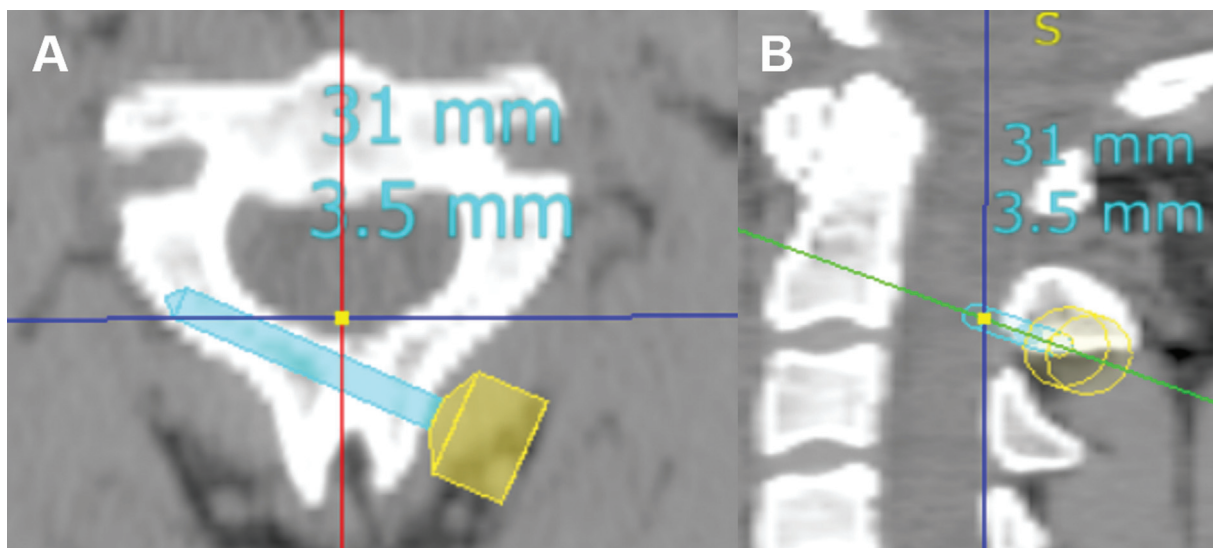


Fig. 5 C2L screw trajectory measurement. C2L screw in the axial plane (A) and in the sagittal plane (B).

for independent samples, considering a p-value < 0.05 as significant.

Data were analyzed using the statistical software IBM SPSS Statistics for Windows, version 26.0 (IBM Corp., Armonk, NY, USA).

Results

The age of the sample by gender is shown in ►Table 1. There was good interobserver agreement ($K > 0.4$) for all measurements except for the C1LM screw length (►Table 2). The mean length and angles for each screw trajectory are shown in ►Table 3. The comparison of screw measurements by gender (►Table 4) demonstrated that the mean screw length in males was higher for the C1C2TA and C2L screw trajectories. There were no significant statistical differences between genders for the C1LM, C2P, and C2 pars screws length ($p > 0.05$). Also, there were no gender significant statistical differences for any trajectory angles.

Discussion

Posterior atlantoaxial fixation is required to provide stability, reduce deformity, and prevent neurological injury. Currently, the more commonly used techniques for posterior atlantoaxial arthrodesis are C1C2TA screws and screw-rod fixations, which include a C1LM screw combined with C2P, C2 pars, or C2L screws.¹⁰ These procedures achieve a high fusion rate

Table 1 Sample age by gender

		Age	
Gender	n	Mean	SD
Male	26	40.08	15.81
Female	24	45.38	14.45
Total	50	42.62	15.25

Abbreviations: SD, standard deviation.

and an immediate rigid fixation, eliminating the need for a postoperative external orthosis.¹¹

The screw constructs are selected based on the osseous and vascular C1-C2 anatomy of the patient, the particular pathological lesion, and the experience and comfort level of the surgeon.¹² Due to the variable anatomy of the C1-C2 complex, a preoperative cervical CT scan or magnetic resonance imaging (MRI) is highly recommended to determine the anatomic feasibility and safe screw trajectory to avoid complications related to the placement of the screw.⁵

Several authors have described the most used screw trajectories for posterior atlantoaxial fixation; however,

Table 2 Interobserver reliability test for each screw length and angulation

Screw trajectory		Interobserver reliability
C1C2TA	Length	0.441
	Medial angle	0.598
	Cranial angle	0.674
C1LM	Length	0.214
	Medial angle	0.691
	Cranial angle	0.427
C2P	Length	0.709
	Medial angle	0.828
	Cranial angle	0.747
C2 pars	Length	0.573
	Medial angle	0.795
	Cranial angle	0.784
C2L	Length	0.593
	Lateral angle	0.605
	Cranial angle	0.651

Abbreviations: C1C2TA, C1-C2 transarticular; C1LM, C1 lateral mass; C2L, C2 laminar; C2P, C2 pedicle.

Table 3 Length and angulation for each screw trajectory

		<i>n</i>	Minimum	Maximum	Mean	SD
C1C2TA	Length	50	28.00	40.00	34.12	3.19
	Medial angle	50	2.00	13.00	6.24	3.06
	Cranial angle	50	45.00	70.00	59.25	5.68
C1LM	Length	50	23.00	33.00	27.12	2.15
	Medial angle	50	4.00	28.00	15.82	5.07
	Cranial angle	50	6.00	25.00	13.53	4.80
C2P	Length	50	19.00	28.00	23.44	2.49
	Medial angle	50	18.00	38.00	27.40	4.88
	Cranial angle	50	18.00	43.00	30.41	7.27
C2 pars	Length	50	14.00	24.00	16.84	2.08
	Medial angle	50	9.00	33.00	20.09	6.83
	Cranial angle	50	31.00	60.00	47.53	6.97
C2L	Length	50	24.00	33.00	29.10	2.48
	Lateral angle	50	36.00	59.00	49.80	4.71
	Cranial angle	50	3.50	34.50	21.56	7.76

Abbreviations: C1C2TA, C1-C2 transarticular; C1LM, C1 lateral mass; C2L, C2 laminar; C2P, C2 pedicle; SD, standard error.

there is a lack of studies analyzing all these screw trajectories in the same population. Besides, there are no reports of anatomical references for these screws in the Portuguese population. Hence, the present study is essential to provide anatomical references, adding to existing knowledge. The comparison between the results in the present study and the international literature for each screw trajectory is shown in ►Table 5.

Transarticular screw fixation, introduced by Magerl, provides high stability and fusion rates ranging from 92% to 100%.⁵ However, this technique requires reduction of the C1-C2 complex before screw placement and is associated with a potential risk of injury to the vertebral artery, particularly in those with a high-riding VA.¹³

Nogueira-Barbosa et al.¹⁴ analyzed 100 CT scans to determine atlantoaxial bone morphometric measurements related to the transarticular screw fixation technique. Their study determined that, in males, the screw length was 39 mm, the medial angle was 8°, and the cranial angle was 59°. In females, the screw length and the medial and cranial angles were 37 mm, 7° and 57°, respectively. In the present study, the results were similar.

To overcome the pitfalls of the transarticular fixation technique, Harms and Melcher introduced a C1-C2 fixation technique using a C1LM screw combined with C2P or C2 pars screws. This technique has good biomechanical strength and allows intraoperative reduction of the atlantoaxial complex.¹⁵ Additionally, the trajectories of the C2P and C2 pars screws are more medial than that of the C1C2TA screw, thus reducing the risk of VA injury.¹⁶ Despite these advantages, the risk of VA or neurological lesion still exists.¹³

Medial angulation of the C1LM screw maximizes the margin of safety, with any lateral angulation being unsafe, risking violation of the vertebral foramen and VA injury.¹⁷ The placement of the C1LM screw may also cause postoper-

ative C2 nerve injury and massive bleeding from the venous plexus below the C1 posterior arch during exposure of the C1LM screw entry point.⁸

Different C1LM screw lengths and angles have been described in earlier anatomic studies, depending on the selected screw entry point and on the anatomy of each patient.^{7,18-21} Also, there is evidence that the trajectory angles have implications on screw lengths. Hu Y et al. conducted a study to determine the optimal entry point, medial angle, and effective length for safe fixation of C1LM screws and concluded that a greater medial angle implies a longer screw length. In their study, it was considered that the optimal entry point was at the middle of the posterior C1 inferior articular process 2 mm above the articular surface. Regarding angles, they used a fixed 15° cephalad angle and determined that the optimal medial angle to reduce the risk of VA and spinal cord injury was 21° with a corresponding screw length of 22 mm inside the C1LM.²¹ Simsek et al.¹⁸ found that the ideal screw cranial angle was 15° using the same entry point as the present study. The screw length inside the lateral mass and the medial angle, measured on the right side of the C1 vertebra, were 20 mm and 14°, respectively. However, due to the overlying C1 posterior arch, the screw length increases to allow the placement of the rod in the polyaxial head of the screw. Rocha et al.²⁰ determined the ideal screw length with the overlying C1 posterior arch as 30 mm with screws placed bicortically. Regarding angulation, the medial and cranial angles were 17° and 22°, respectively.²⁰ In the present study, the C1LM screw length inside and outside the C1LM was 27 mm with 16° medial and 14° cranial angles.

The C2P screw technique has the advantage over the C1C2TA screw of requiring a less acute approach angle.¹⁶ However, the C2 pedicle width and height limit the placement of the screw.²²

Table 4 Length and angulation for each screw trajectory by gender

Screw trajectory		Gender	n	Mean	SD	SED	p-value
C1C2TA	Length	Male	26	35.15	2.66	0.52	0.020
		Female	24	33.00	3.39	0.69	
	Medial angle	Male	26	5.71	2.78	0.55	0.207
		Female	24	6.81	3.30	0.67	
	Cranial angle	Male	26	58.79	5.21	1.02	0.555
		Female	24	59.75	6.23	1.27	
C1LM	Length	Male	26	27.69	2.09	0.41	0.050
		Female	24	26.50	2.09	0.43	
	Medial angle	Male	26	16.46	5.26	1.03	0.357
		Female	24	15.13	4.86	0.99	
	Cranial angle	Male	26	13.12	4.78	0.94	0.531
		Female	24	13.98	4.90	1.00	
C2P	Length	Male	26	23.58	2.58	0.51	0.690
		Female	24	23.29	2.44	0.49	
	Medial angle	Male	26	27.00	4.18	0.82	0.551
		Female	24	27.83	5.59	1.14	
	Cranial angle	Male	26	28.60	7.00	1.37	0.066
		Female	24	32.38	7.18	1.47	
C2 pars	Length	Male	26	17.29	2.27	0.45	0.131
		Female	24	16.38	1.77	0.36	
	Medial angle	Male	26	18.83	6.42	1.26	0.176
		Female	24	21.46	7.12	1.45	
	Cranial angle	Male	26	46.10	6.90	1.35	0.131
		Female	24	49.08	6.85	1.40	
C2L	Length	Male	26	30.15	2.29	0.45	0.001
		Female	24	27.96	2.18	0.44	
	Lateral angle	Male	26	48.96	4.58	0.90	0.193
		Female	24	50.71	4.77	0.97	
	Cranial angle	Male	26	20.92	8.11	1.59	0.551
		Female	24	22.25	7.47	1.52	

Abbreviations: C1C2TA, C1-C2 transarticular; C1LM, C1 lateral mass; C2L, C2 laminar; C2P, C2 pedicle; SD, standard deviation; SED, standard error deviation.

Some studies claim that the C2P screw provides the highest biomechanical stability when compared with C2 pars and C2L screws.²³⁻²⁵ Therefore, the placement of C2 pars or C2L screws is an important alternative when the cervical anatomy of the patient precludes the placement of a C2P screw, such as in C2 pedicle hypoplasia or high-riding VA.^{11,12,26}

Chin et al.²⁷ conducted a similar study using CT scans from 34 patients to evaluate the ideal screw trajectory through each C2 pedicle and concluded that, on the right side, the screw length and the medial and cranial angles were 22 mm, 28° and 23°, respectively. In the current study, the results for C2P screw length and medial angle were similar but with a 30° cranial angle.

Sai Kiran et al.²⁴ evaluated the safety and accuracy of anatomic and lateral fluoroscopic-guided placement of C2 pars screws. They determined that screw placement was safe with a 16 mm screw length with a medial and cranial angulation of 23° and 30°, respectively. Although the screw length and the medial angle were similar to those determined by Sai Kiran et al.,²⁴ the cranial angle was found to be higher in the present study. This difference may result from using a different reference plane.

The bilateral crossing C2L screw, described by Wright, avoids the risk of VA injury since the screws are not positioned near the transverse foramen.⁹ The placement of this screw is safe, easy to perform, and does not require fluoroscopy or spinal navigation. However, C2L screws have an

Table 5 Comparison between the screw measurements of the present study and those described in the international literature

Trajectory	Present study			International literature							
	Gender	n	Mean	Nogueira-Barbosa et al. ¹⁴		Young Hu et al. ²¹	Simsek et al. ¹⁸	Rocha et al. ²⁰	Chin et al. ²⁷	Kiran et al. ²⁴	Dean et al. ²⁸
			Total								
C1C2TA length	Male	26	35.15	34.12	38.86						
	Female	24	33.00		36.99						
C1C2TA medial angle	Male	26	5.71	6.24	7.57						
	Female	24	6.81		7.48						
C1C2TA cranial angle	Male	26	58.79	59.25	58.64						
	Female	24	59.75		57.30						
C1LM length	Male	26	27.69	27.12		21.86	19.59	30.40			
	Female	24	26.50								
C1LM medial angle	Male	26	16.46	15.82		20.86	13.50	16.70			
	Female	24	15.13								
C1LM cranial angle	Male	26	13.12	13.53		15.00	15.20	21.70			
	Female	24	13.98								
C2P length	Male	26	23.58	23.44					22.10		
	Female	24	23.29								
C2P medial angle	Male	26	27.00	27.40					27.90		
	Female	24	27.83								
C2P cranial angle	Male	26	28.60	30.41					23.00		
	Female	24	32.38								
C2 pars length	Male	26	17.19	16.8					16.40		
	Female	24	16.38								
C2 pars medial angle	Male	26	18.83	20.09					22.70		
	Female	24	21.46								
C2 pars cranial angle	Male	26	46.10	47.53					30.00		
	Female	24	49.08								
C2L length	Male	26	30.15	29.10						28.80	
	Female	24	27.96								
C2L lateral angle	Male	26	48.96	49.80						42.45	
	Female	24	50.71								
C2L cranial angle	Male	26	20.92	21.56							
	Female	24	22.25								

Abbreviations: C1C2TA, C1-C2 transarticular; C1LM, C1 lateral mass; C2L, C2 laminar; C2P, C2 pedicle.

increased risk of spinal canal injury from a ventral cortical breach.¹⁵

Dean et al.²⁸ conducted a study to evaluate critical dimensions of the C2 vertebrae for laminar screw placement through CT scan measurements and concluded that the C2L screw length was 29 mm and the lateral angle was 42°. In the present study, the screw length was the same as that determined by Dean et al.²⁸ but with a 50° lateral angle.

To the best of our knowledge, the present study is the first to provide a complete description of the most commonly used screw trajectories for posterior atlantoaxial fixation in the same population. Moreover, it is the first study providing anatomical references for posterior C1-C2 screw placement in a Portuguese population.

Nevertheless, the limitations of the present study should be noted. The screw length and angles were measured only on the right side of the C1 and C2 vertebrae. Additionally, all the measurements were made manually and are investigator-dependent. Therefore, to overcome this limitation, the screw length and angles were measured by two investigators, and a good agreement was obtained for all but one measurement.

Conclusion

Instrumentation in upper cervical spine surgery can lead to catastrophic complications and extreme care must be taken to minimize these events. The present study provides important atlantoaxial references that may help spine surgeons to achieve proper screw placement, especially when intraoperative navigation is not available. However, due to the anatomic variations of the C1-C2 complex, this data can serve only as a rough guide and is not sufficient for safe and effective screw implantation. Therefore, if screw implantation is considered, it is essential to perform preoperative CT imaging with a detailed anatomic analysis to determine the ideal screw trajectory.

Financial Support

The authors have no financial disclosures to declare.

Conflict of Interests

The authors have no conflict of interests to declare.

References

- Lopez AJ, Scheer JK, Leibl KE, Smith ZA, Dlouhy BJ, Dahdaleh NS. Anatomy and biomechanics of the craniovertebral junction. *Neurosurg Focus* 2015;38(04):E2
- Yang SY, Boniello AJ, Poorman CE, Chang AL, Wang S, Passias PG. A review of the diagnosis and treatment of atlantoaxial dislocations. *Global Spine J* 2014;4(03):197–210
- Gautschi OP, Payer M, Corniola MV, Smoll NR, Schaller K, Tessitore E. Clinically relevant complications related to posterior atlantoaxial fixation in atlanto-axial instability and their management. *Clin Neurol Neurosurg* 2014;123:131–135
- Lyons C, Ross M, Elliott R, Tall M. Atlantoaxial instability in a patient with neck pain and ankylosing spondylitis. *Mil Med* 2018;183(9-10):e654–e657
- Chen Q, Brahimaj BC, Khanna R, et al. Posterior atlantoaxial fusion: a comprehensive review of surgical techniques and relevant vascular anomalies. *J Spine Surg* 2020;6(01):164–180
- Jeanneret B, Magerl F. Primary posterior fusion C1/2 in odontoid fractures: indications, technique, and results of transarticular screw fixation. *J Spinal Disord* 1992;5(04):464–475
- Harms J, Melcher RP. Posterior C1-C2 fusion with polyaxial screw and rod fixation. *Spine (Phila Pa 1976)* 2001;26(22):2467–2471
- Huang D-G, Hao D-J, He B-R, et al. Posterior atlantoaxial fixation: a review of all techniques. *Spine J* 2015;15(10):2271–2281
- Wright NM. Posterior C2 fixation using bilateral, crossing C2 laminar screws: case series and technical note. *J Spinal Disord Tech* 2004;17(02):158–162
- Liu S, Song Z, Liu L, et al. Biomechanical evaluation of C1 lateral mass and C2 translaminar bicortical screws in atlantoaxial fixation: an in vitro human cadaveric study. *Spine J* 2018;18(04):674–681
- Sugawara T, Higashiyama N, Kaneyama S, Sumi M. Accurate and Simple Screw Insertion Procedure With Patient-Specific Screw Guide Templates for Posterior C1-C2 Fixation. *Spine (Phila Pa 1976)* 2017;42(06):E340–E346
- Du JY, Aichmair A, Kueper J, Wright T, Lebl DR. Biomechanical analysis of screw constructs for atlantoaxial fixation in cadavers: a systematic review and meta-analysis. *J Neurosurg Spine* 2015;22(02):151–161
- Rajinda P, Towiwat S, Chirappapha P. Comparison of outcomes after atlantoaxial fusion with C1 lateral mass-C2 pedicle screws and C1-C2 transarticular screws. *Eur Spine J* 2017;26(04):1064–1072
- Nogueira-Barbosa MH, Defino HL. Multiplanar reconstructions of helical computed tomography in planning of atlanto-axial transarticular fixation. *Eur Spine J* 2005;14(05):493–500
- Lu X, Xu T. Advantages and Disadvantages of Traditional Atlantoaxial Fusion Techniques. In: Ni B, Guo X, Guo Q, eds. *Atlantoaxial Fixation Techniques*. Translational Medicine Research. Singapore: Springer; 2018:39–48
- Sim HB, Lee JW, Park JT, Mindea SA, Lim J, Park J. Biomechanical evaluations of various c1-c2 posterior fixation techniques. *Spine (Phila Pa 1976)* 2011;36(06):E401–E407
- Blagg SE, Don AS, Robertson PA. Anatomic determination of optimal entry point and direction for C1 lateral mass screw placement. *J Spinal Disord Tech* 2009;22(04):233–239
- Simsek S, Yigitkanli K, Seçkin H, et al. Ideal screw entry point and projection angles for posterior lateral mass fixation of the atlas: an anatomical study. *Eur Spine J* 2009;18(09):1321–1325
- Christensen DM, Eastlack RK, Lynch JJ, Yaszemski MJ, Currier BL. C1 anatomy and dimensions relative to lateral mass screw placement. *Spine (Phila Pa 1976)* 2007;32(08):844–848
- Rocha R, Safavi-Abbasi S, Reis C, et al. Working area, safety zones, and angles of approach for posterior C-1 lateral mass screw placement: a quantitative anatomical and morphometric evaluation. *J Neurosurg Spine* 2007;6(03):247–254
- Hu Y, Dong WX, Spiker WR, et al. An anatomic study to determine the optimal entry point, medial angles, and effective length for safe fixation using posterior C1 lateral mass screws. *Spine (Phila Pa 1976)* 2015;40(04):E191–E198
- Meyer D, Meyer F, Kretschmer T, Börm W. Translaminar screws of the axis – an alternative technique for rigid screw fixation in upper cervical spine instability. *Neurosurg Rev* 2012;35(02):255–261
- Chun DH, Yoon DH, Kim KN, Yi S, Shin DA, Ha Y. Biomechanical Comparison of Four Different Atlantoaxial Posterior Fixation Constructs in Adults: A Finite Element Study. *Spine (Phila Pa 1976)* 2018;43(15):E891–E897
- Sai Kiran NA, Sivaraju L, Vidyasagar K, et al. Safety and Accuracy of Anatomic and Lateral Fluoroscopic-Guided Placement of C2 Pars/Pedicle Screws and C1 Lateral Mass Screws, and Freehand Placement of C2 Laminar Screws. *World Neurosurg* 2018;118:e304–e315

- 25 Lehman RA Jr, Dmitriev AE, Helgeson MD, Sasso RC, Kuklo TR, Riew KD. Salvage of C2 pedicle and pars screws using the intralaminar technique: a biomechanical analysis. *Spine (Phila Pa 1976)* 2008;33(09):960-965
- 26 Dobran M, Nasi D, Esposito DP, Iacoangeli M. Posterior Fixation with C1 Lateral Mass Screws and C2 Pars Screws for Type II Odontoid Fracture in the Elderly: Long-Term Follow-Up. *World Neurosurg* 2016;96:152-158
- 27 Chin KR, Mills MV, Seale J, Cumming V. Ideal starting point and trajectory for C2 pedicle screw placement: a 3D computed tomography analysis using perioperative measurements. *Spine J* 2014;14(04):615-618
- 28 Dean CL, Lee MJ, Robbin M, Cassinelli EH. Correlation between computed tomography measurements and direct anatomic measurements of the axis for consideration of C2 laminar screw placement. *Spine J* 2009;9(03):258-262