



Original Article

Surgical treatment for myelodysplastic clubfoot^{☆,☆☆}

Alexandre Zuccon^{*}, Sérgio Inácio Cristiano Cardoso, Fábio Peluzo Abreu,
Antonio Carlos Fernandes

Associação de Assistência à Criança Deficiente (AACD), São Paulo, SP, Brazil

ARTICLE INFO

Article history:

Received 19 July 2013

Accepted 29 October 2013

Available online 22 October 2014

Keywords:

Myelomeningocele

Clubfoot

Acquired deformities of the foot

ABSTRACT

Objective: To analyze the results from surgical treatment of 69 cases of clubfoot in 43 patients with myelodysplasia according to clinical and radiographic criteria, at our institution between 1984 and 2004.

Methods: This was a retrospective study involving analysis of medical files, radiographs and consultations relating to patients who underwent surgical correction of clubfoot. The surgical technique consisted of radical posteromedial and lateral release with or without associated talectomy.

Results: The patients' mean age at the time of the surgery was four years and two months, and the mean length of postoperative follow-up was seven years and two months. Satisfactory results were achieved in 73.9% of the feet and unsatisfactory results in 26.1% ($p < 0.0001$).

Conclusion: Residual deformity in the immediate postoperative period was associated with unsatisfactory results. Opening of the Kite (talocalcaneal) angle in feet that only underwent posteromedial and lateral release, along with appropriate positioning of the calcaneus in cases that underwent talectomy, was the radiographic parameter that correlated with satisfactory results.

© 2014 Sociedade Brasileira de Ortopedia e Traumatologia. Published by Elsevier Editora Ltda. All rights reserved.

Tratamento cirúrgico do pé equinovaro mielodisplásico

RESUMO

Objetivo: Analisar os resultados entre 1984 e 2004 em nossa instituição do tratamento cirúrgico de 69 pés equinovaros em 43 pacientes portadores de mielodisplasia segundo os critérios clínico e radiográfico.

Métodos: Estudo retrospectivo com análise de prontuário, radiografias e consulta com pacientes portadores de mielomeningocele que foram submetidos a correção cirúrgica de pés equinovaros. A técnica cirúrgica foi a liberação posteromediolateral (LPML) radical associada ou não a talectomia.

Palavras-chave:

Mielomeningocele

Pé torto

Deformidades adquiridas do pé

^{*} Please cite this article as: Zuccon A, Cardoso SIC, Abreu FP, Fernandes AC. Tratamento cirúrgico do pé equinovaro mielodisplásico. Rev Bras Ortop. 2014;49:653-660.

^{☆☆} Work developed at the Association for Disabled Children's Care (AACD), São Paulo, SP, Brazil.

^{*} Corresponding author.

E-mail: alezuccon@hotmail.com (A. Zuccon).

<http://dx.doi.org/10.1016/j.rboe.2014.10.006>

2255-4971/© 2014 Sociedade Brasileira de Ortopedia e Traumatologia. Published by Elsevier Editora Ltda. All rights reserved.

Resultados: A média de idade na época da cirurgia foi de quatro anos e dois meses e o seguimento médio pós-operatório, de sete anos e dois meses. Foram encontrados resultados satisfatórios em 73,9% dos pés e insatisfatórios em 26,1% ($p < 0,0001$).

Conclusão: A deformidade residual no pós-operatório imediato está relacionada com resultados insatisfatórios e a abertura do ângulo de Kite (talocalcaneano) nos pés submetidos somente a LPML, além do posicionamento adequado do calcâneo, nos casos em que foi feita a talectomia, é o parâmetro radiográfico relacionado aos resultados satisfatórios.

© 2014 Sociedade Brasileira de Ortopedia e Traumatologia. Publicado por Elsevier Editora Ltda. Todos os direitos reservados.

Introduction

There are several forms of presentation of neural tube closure defects, such as myelomeningocele, myelocele, meningocele and lipomeningocele. These conditions have the common feature of deficient fusion of posterior elements of the spine, in association with medullary dysplasia.¹

The worldwide incidence of myelomeningocele is 1:1000 live births, on average.¹

Medullary dysplasia, or myelodysplasia, may occur to varying degrees and may compromise various organs and systems, such as the musculoskeletal, genitourinary, digestive and neurological systems. Hydrocephaly occurs during the course of 90% of myelomeningocele cases.^{1,2}

The innervation of the lower limbs is compromised and this gives rise to motor and sensory paralysis, muscle imbalance and deformities.

The feet are frequently affected by deformities in these cases.³⁻⁶ In a study conducted in the myelomeningocele clinic of our hospital, the most prevalent deformity was equinovarus, which was observed in 31% of the 480 feet that were evaluated randomly.¹

Myelodysplastic equinovarus foot is one of the most frequent abnormalities. It is difficult to treat and has high complication rates.³⁻⁵

Conservative treatment of myelodysplastic feet using serial plaster casts in accordance with the Ponseti method has increased in popularity among pediatric orthopedists. However, so far, there is still no scientific evidence regarding long-term maintenance of the correction achieved and therefore surgical treatment is still used.^{1,7-9} In the literature, there are reports on procedures going from soft-tissue release with tendon stretching to bone surgery of a more aggressive nature, such as talectomy.^{3,10-13}

The objective of the present study was to evaluate the results from surgical treatment of myelodysplastic equinovarus feet at our institution from October 1984 to October 2004 and to correlate the deformities, surgical technique used and results obtained.

Material and method

A retrospective study was conducted, with analysis on the medical files of patients presenting myelodysplastic clubfoot. Subsequently, patients who underwent surgical treatment on

their feet at our service between October 1984 and October 2004, as shown in our database, were invited to return for clinical assessment.

No classification regarding the severity of the deformities was made.

The inclusion criteria were that the patients needed to have had the following: (1) myelodysplasia with equinovarus feet from the time of birth that had not been treated surgically prior to the treatment at our institution and (2) a minimum postoperative follow-up of two years.

Patients who we were unable to contact, those whose data were insufficient and those who did not come for clinical evaluation were excluded.

The surgical technique used was posteromedial lateral release (PMLR), with or without associated talectomy. In some feet, shortening of the lateral column was also performed. Two access incisions used (one posteromedial and the other, lateral) and the Cincinnati route was used in feet that presented equinus $\leq 30^\circ$ (24.6%). Tenotomy was performed with resection of around 2 cm of the tendons of the calcaneus, long flexor of the hallux, common flexor of the toes, posterior and anterior tibialis and abductor of the hallux. Posteromedial lateral capsulotomy of the tibiotarsal and subtalar joints was then performed, including the interosseous, talonavicular, calcaneocuboid, naviculocuneiform and cuneometatarsal ligaments. When reduction of the deformity of the hindfoot through these procedures was not possible, or when the talus was very deformed, talectomy was chosen. In cases in which deformity in adduction persisted after the procedures, shortening of the lateral column was also performed (36 feet). The location was at the level of the cuboid in 33 cases and at the level of the calcaneocuboid in three cases. Fixation with Kirschner wires was performed after correction of the deformity, with placement of a retrograde wire in the hindfoot (calcaneus-talus-tibia), a wire in the medial column to keep the medial joints open and another wire in the lateral column to close the joints in this column. The wires were threaded, because upon performing the release and the capsulotomies and reducing the deforming, there was a need to keep the joints in the medial region open.

During the postoperative follow-up, the patients were immobilized for 12 weeks. The wires were removed as outpatient procedures, after six weeks. After this period, polypropylene braces extending from the sural region to the foot were prescribed for daytime and nighttime use, for an indeterminate time.

Table 1 – General distribution of the patients.

No.	Side	Age	Surgical technique	Result	Length of time after operation
1	R/L	1 Y	PMLR	+/+	19 Y+3 M
2	R/L	6 Y	PMLR+ TAL+ SLC	+/+	6 Y
3	L	2 Y+8 M	PMLR+ SLC	+	18 Y
4	R/L	2 Y+2 M	PMLR	+/+	16 Y
5	R/L	3 Y+2 M	PMLR	+/-	11 Y
6	L	5 Y+7 M	PMLR+ TAL	-	9 Y
7	R	6 Y	PMLR+ TAL	+	10 Y+10 M
8	L	4 Y	PMLR+ TAL	-	10 Y
9	L	2 Y+9 M	PMLR+ TAL+ SLC	-	7 Y
10	R/L	3 Y	PMLR+ SLC	-/+	7 Y+6 M
11	R/L	2 Y+5 M	PMLR+ TAL+ SLC	+/-	7 Y
12	R/L	1 Y+8 M	PMLR+ TAL+ SLC	+/+	6 Y+4 M
13	R/L	3 Y+1 M	PMLR	-/-	5 Y
14	R	1 Y+9 M	PMLR+ TAL+ SLC	+/+	4 Y+1 M
15	R/L	9 Y+8 M	PMLR+ TAL+ SLC	+/+	6 Y
16	R/L	3 Y+2 M	PMLR	+/+	8 Y+6 M
17	R/L	7 Y+3 M	PMLR+ TAL+ SLC	+/+	3 Y
18	R	6 Y	PMLR+ TAL+ SLC	+	4 Y+11 M
19	R/L	7 Y+4 M	PMLR	+/+	3 Y+8 M
20	R/L	5 Y+8 M	PMLR+ TAL+ SLC	+/+	7 Y
21	R/L	1 Y+6 M	PMLR+ SLC	+/+	5 Y
22	R/L	1 Y+7 M	PMLR+ TAL+ SLC	+/+	3 Y+10 M
23	L	3 Y+9 M	PMLR+ SLC	-	8 Y+9 M
24	R/L	2 Y+6 M	PMLR+ SLC	-/-	8 Y
25	R/L	2 Y+1 M	PMLR+ TAL+ SLC - D	+/+	8 Y+10 M
26	R	1 Y+2 M	PMLR	-	7 Y
27	R/L	2 Y	PMLR	+/+	3 Y
28	R/L	1 Y+6 M	PMLR+ TAL	+/+	2 Y
29	L	11 Y+5 M	PMLR+ TAL	-	2 Y+2 M
30	R	4 Y+6 M	PMLR+ TAL+ SLC	+	2 Y
31	L	6 Y	PMLR+ SLC	+	9 Y
32	L	2 Y	PMLR+ TAL+ SLC	+	19 Y
33	R/L	4 Y+3 M	PMLR+ TAL - D	+/-	7 Y
34	L	1 Y+5 M	PMLR	+	2 Y
35	R/L	2 Y+6 M	PMLR	+/-	8 Y
36	R/L	2 Y	PMLR	+/+	2 Y
37	R/L	3 Y	PMLR	+/+	2 Y+4 M
38	L	13 Y	PMLR+ SLC	+	2 Y+1 M
39	R	6 Y	PMLR+ TAL+ SLC	+	3 Y+6 M
40	R	7 Y	PMLR	+	3 Y
41	L	7 Y+2 M	PMLR+ SLC	+	2 Y
42	R/L	2 Y	PMLR+ TAL+ SLC	+/-	3 Y+6 M
43	R/L	5 Y+8M	PMLR+ SLC	-/-	4 Y+2 M

Results: (+), satisfactory; (-), unsatisfactory; SLC, shortening of lateral column; TAL, talectomy.

The cases were analyzed using clinical and radiographic criteria. According to the clinical criteria, we divided the results into satisfactory and unsatisfactory, as can be seen in the following:

- **Satisfactory result** – feet that presented the criteria listed below:
 1. Plantigrade feet;
 2. Feet compatible with use of a brace in the neutral position;
 3. Feet without skin lesions or pressure ulcers.
- **Unsatisfactory result** – at least one of the following criteria:
 1. Non-plantigrade feet;
 2. Feet incompatible with use of a brace in the neutral position;
 3. Feet with skin lesions (ulcers) due to pressure;

4. Feet requiring subsequent surgical procedures.

The patients were grouped according to numerical order, initials of their name, side of the body affected, age at the time of the surgery, surgical technique used, result obtained and length of postoperative follow-up (Table 1).

We evaluated the immediate complications (those that occurred during the immediate postoperative period or up to two weeks after the surgical procedure) and the late complications (more than two weeks after the surgery), with regard to frequency and type.

Regarding radiographic analyses, we obtained documentation on 45 feet and, for these feet, we evaluated the talocalcaneal angle in anteroposterior (AP) view or the Kite angle before the operation. We also evaluated the same angle after the operation in the feet that did not undergo talectomy

(given that this measurement would be impossible in cases of talectomy). This angle measures the opening between the talus and calcaneus and normal values are between 20° and 40°. It is greatly used in the literature for evaluating talipes equinovarus and frequently is diminished (<20°) in cases of this deformity.⁵ We also analyzed the position of the calcaneus in the feet that underwent talectomy and considered the radiographic result to be acceptable when the calcaneus was positioned below the tibia, in a neutral position and slightly posteriorized in relation to it, and if no residual fragment of the talus was identified between the calcaneus and the tibia.

Our initial hypothesis was that if the deformities were not completely corrected through the surgical procedure, i.e. if there was some residual deformity after the surgery, the chance of obtaining an unsatisfactory result would be greater.

To assess whether the residual deformity was related to the results, we used the Fisher exact test. Situations of satisfactory results with the presence of residual deformity or unsatisfactory results without residual deformity were taken to be discordant.

Statistical values from the radiographic analyses were obtained using the McNemar test.

In all cases, the rejection level for the nullity hypothesis was set at a value ≤ 0.05 (5%).

When the statistics calculated presented significance, we used an asterisk (*) to denote this. If otherwise, i.e. non-significant, we used the abbreviation NS.

Results

We analyzed 90 medical files and attempted to contact the individuals concerned by means of the telephone, in order to invite them for clinical assessment and final radiography. Out of these 90 patients, we obtained data on and attendance by 43.

We included 69 feet (43 patients) in the study. Thus, deformities in both feet were observed in 26 patients (60.4%). Regarding gender, there were slightly more females: 22 patients (51.1%).

The patients' mean age at the time of the surgery was four years and two months. The minimum age was one year and the maximum was 13 years.

The minimum postoperative length of follow-up was two years and the maximum was 19 years and three months. The mean was seven years and two months.

Out of the 69 feet evaluated, we found that the result was satisfactory in 51 (73.9%) and unsatisfactory in 18 (26.1%), in accordance with the clinical criteria stated in the methods section ($p < 0.0001$).

In 31 feet (44.9%), posteromedial lateral release was performed in association with talectomy, while in 38 (55.1%), posteromedial lateral release alone was performed.

Immediate (I) and late (T) complications were observed in 34 feet (49.2%). Suture dehiscence (16 feet) occurred most frequently and, later on, hypercorrection showing valgus deformity (nine feet) (Table 2).

– Partial or total recurrence occurred in 12 feet (17.4% of the cases).

Table 2 – Frequencies of postoperative complications.

Complication	Number of feet	Percentage
Suture dehiscence ^a	16	39.1%
Superficial infection ^a	6	14.6%
Deep infection ^a	3	7.3%
Migration of wires	3	7.3%
Skin distress ^a (circulatory)	3	7.3%
Hypercorrection	9	22%
Aseptic necrosis of talus	1	2.4%
Total	41	100%

^a Note: In seven feet, more than one complication occurred.

– Reoperation was performed on 12 feet (17.4%).

In analyzing the feet that presented residual deformity, i.e. which presented deformity in the immediate postoperative period (nine feet), we identified unsatisfactory results in eight cases (88.9%). When we analyzed the feet without residual deformities (60), we identified satisfactory results in 50 (83.3%) and unsatisfactory results in only 10 (16.7%) (Table 3).

We observed recurrence of the deformity in 12 feet. Eight (66.6%) had residual deformity in the immediate postoperative period and four (33.3%) did not present this.

Regarding the radiographic evaluation, we obtained complete documentation for 45 feet and, among these, we found that the preoperative AP Kite angle was closed (<20°) in 41 (91.1%). In the feet that underwent PMLR for which satisfactory results were obtained (22), the Kite angle increased in 21 cases (95.4%), while in the feet with unsatisfactory results that underwent PMLR (six), the Kite angle increased in only one (16.6%) (Table 4). In the feet that underwent PMLR + talectomy for which satisfactory results were obtained (15), 14 (93.3%) presented correct positioning of the calcaneus and only one did not. On the other hand, among the feet that underwent

Table 3 – Relationship between the results and residual deformity.

Result	Residual deformity		
	Present	Absent	Total
Unsatisfactory	8 feet*	10 feet	18 feet
Satisfactory	1 foot	50 feet	51 feet
Total	9 feet	60 feet	69 feet

* $p = 0.00004$ (Fisher test).

Table 4 – Relationship between postoperative Kite angle and final result.

Result	Kite		
	Open	Closed	Total
Satisfactory	21 feet	1 foot	22 feet
Unsatisfactory	1 foot	5 feet	6 feet
Total	22 feet	6 feet	28 feet

$p = 0.7500$ NS. Concordance = 92.8% (McNemar test).

Open: Kite angle became normal after surgery.

Closed: Kite angle remained small after the surgery.

Table 5 – Relationship between the position of the calcaneus and the final result.

Result	Radiography		Total
	Position +	Position –	
Satisfactory	14	1	15
Unsatisfactory	1	1	2
Total	15	2	17

$p = 0.7500$ NS. Concordance = 88.23% (McNemar test).
 Position +: correct position for calcaneus.
 Position -: incorrect position for calcaneus.

PMLR + talectomy with unsatisfactory results (two), one presented correct positioning of the calcaneus and one, incorrect positioning (Table 5).

Discussion

Equinovarus deformity of feet in cases of myelodysplasia is difficult to manage, with high rates of complications and recurrence due to the specific characteristics of this pathological condition, which presents paralysis, muscle imbalance, insensitivity and stiffness.^{3-5,8}

The preferred treatment for this deformity has historically been surgical. Thus, the technique used is important, because it may influence the final result.⁷

Although conservative treatment for cases of idiopathic clubfoot is well established in the literature, this treatment is still not completely reproducible and there are still no long-term studies relating to myelodysplastic feet.

More studies and clinical trials using plaster-cast treatment are now appearing, especially using the principles of the Ponseti method for correction of these deformities. However, the recurrence rates in non-idiopathic feet are still high.¹⁴ In analyzing our sample, particularly with regard to age at the time of the treatment, the choice of surgical treatment was more viable.

The patients' age at the time of the surgery was a decisive factor, given that their mean age as four years and two months. This is an advanced age for treating this pathological condition, given that the feet already present greater stiffness, alterations to the bone format and joint incongruence (Figs. 1 and 2).

The incisions used in surgical treatments for clubfoot vary widely. Turco described a straight incision from the base of the first metatarsal to the Achilles tendon, without subcutaneous dissection.¹⁵ Crawford et al. described the incision that had been conceptualized by Giannestras and is known as the Cincinnati route in homage to the place where they worked.¹⁶ In this study, a double route was used (one posteromedial and the other, lateral) in the great majority of the patients and the Cincinnati route was used in the feet that presented an equinus component of less than 30°; in this manner, there was no difficulty in closing the skin.

Some authors have emphasized the importance of using an appropriate surgical technique, with the use of tendon resection rather than simple stretching, and this was also our

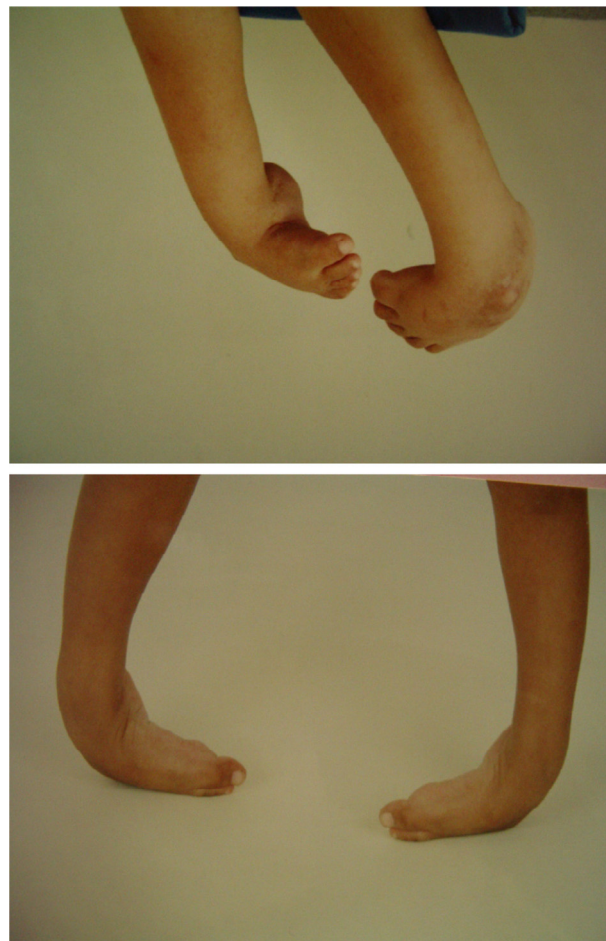


Fig. 1 – Patient with myelodysplasia, presenting stiff clubfoot before operation consisting of PMLR + talectomy.

preference.^{1,4,12} Through doing this, we rebalanced the forces acting on the foot and avoided recurrence.

Posteromedial lateral release is done to treat clubfoot and broad capsulotomy is important, along with tendon release with resection, as already mentioned.^{2,3}

Another point cited in the literature is correction of the rotation of the talus.¹² In our study, there was an increase in the Kite angle in all the radiographically documented feet that evolved satisfactorily and which did not undergo talectomy, which indicates the importance of this technical detail.

Talectomy is a procedure that has been performed for a long time in orthopedic practice, with reports dating back to 1608, from Fabricus.¹⁰ Many authors have reported good results from this technique for surgical treatment of myelodysplastic equinovarus foot.^{6,7,10,17,18}

Some authors have highlighted the importance of correct positioning of the calcaneus in talectomized cases. We also believe that a poorly positioned calcaneus may lead to an unsatisfactory result, although we did not prove this statistically in our study, probably because of the small sample size.^{13,19}

Talectomy was not used as the only procedure for correcting the deformities because although it corrects the deformity of the hindfoot, it does not have any action on the alterations

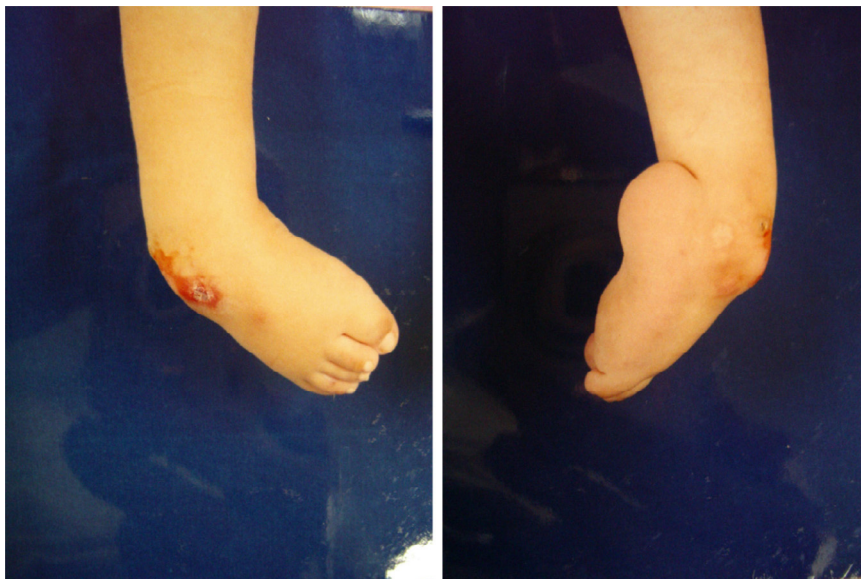

Fig. 2 – Patient with the ability to walk within the community, with myelodysplastic clubfoot with a lesion in the dorsolateral skin (the weight-bearing area of this foot).

of the midfoot and forefoot. Therefore, it does not provide full correction of the deformities and increases the possibility of recurrence.

The surgical correction of the deformities was started in the hindfoot by means of tendon and capsule releases (PMLR). When these were insufficient for complete correction of the deformity of the hindfoot, talectomy was performed. Adduction deformities of the forefoot were corrected by means of capsule and ligament release. When these procedures were insufficient for full correction, shortening of the lateral column was used. Therefore, intraoperative evaluation and knowledge of the pathological anatomy of the deformities is extremely important, since the surgical procedures are performed only as required.²⁰

Thirty-one cases underwent posteromedial lateral release in association with talectomy and 38 without talectomy, and 36 of these feet (52.1%) underwent shortening of the lateral column. We found a rate of satisfactory results similar to that of the literature through these procedures.

Figs. 3 and 4 show illustrative cases of the corrections achieved through the surgical procedures.

Complications in treating this deformity frequently occur, as already highlighted by other authors.^{1,3,5,8} During the post-operative follow-up, complications occurred in 49.2% of the cases, as can be seen in Chart 2.

Valgus deformity was one of the main long-term complications and we attribute this to the wide-ranging releases that were performed, including of the subtalar interosseous ligament. There is controversy regarding whether release of this ligament should be performed, even if only partially.^{21,22}

It was not our objective to evaluate functional level, deformities in other segments of the body or gait prognosis, although there is a study in the literature that correlated deformity in knee flexion and surgical correction of clubfoot among patients with myelodysplasia and arthrogyrosis.⁷

Table 3 shows that, according to the Fisher exact test, the calculated statistical p-value was 0.0004* and that the residual deformities present only appeared infrequently among the satisfactory results. Thus, presence of residual deformities correlated with higher rates of unsatisfactory results. This observation is extremely important because at the end of the surgical procedure, if any deformities still remain to be corrected, these should not be neglected or else there might be a risk of poor results.

Our study presents several limitations, starting with its retrospective case series design.

It was not possible to use a severity classification for the feet that were treated because of insufficient data in the medical files. However, from the high rate of talectomy procedures performed, it can be inferred that difficulty in correcting these feet was encountered.

Another limitation was that there was no correlation with these patients' functional level, given that patients who were able to walk might be more likely to have unsatisfactory results because of the greater likelihood of skin lesions through the body weight borne on a foot with residual deformity, even if this were mild.

We did not use data such as joint mobility and pain, and therefore neither did we use any method nor scale that already exists in the literature, to characterize the results. This was because we were unaware of any specific methods for this analysis on feet presenting associations with neuromuscular diseases such as myelomeningocele, with all the characteristics intrinsic to this pathological condition, as already mentioned earlier. It is known that in feet that undergo extensive release and talectomy, the range of motion decreases substantially. Since most patients with myelomeningocele require braces extending from the sural region to the foot in order to walk, this criterion was not taken into consideration.

We have already highlighted the technical difficulty encountered in correcting the deformities of the feet of these

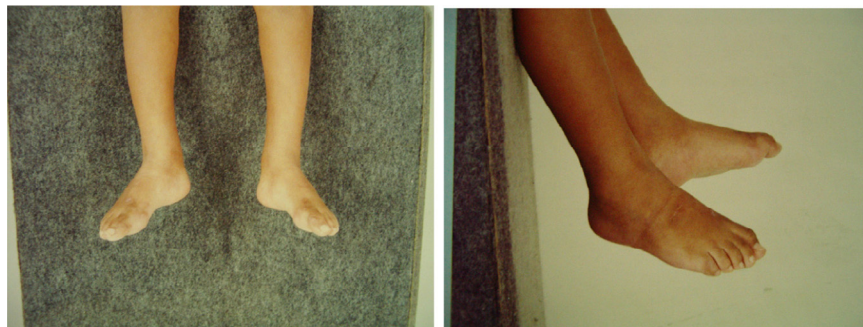

Fig. 3 – Same patient as in Fig. 1, after the operation on the stiff clubfoot consisting of PMLR + talectomy.

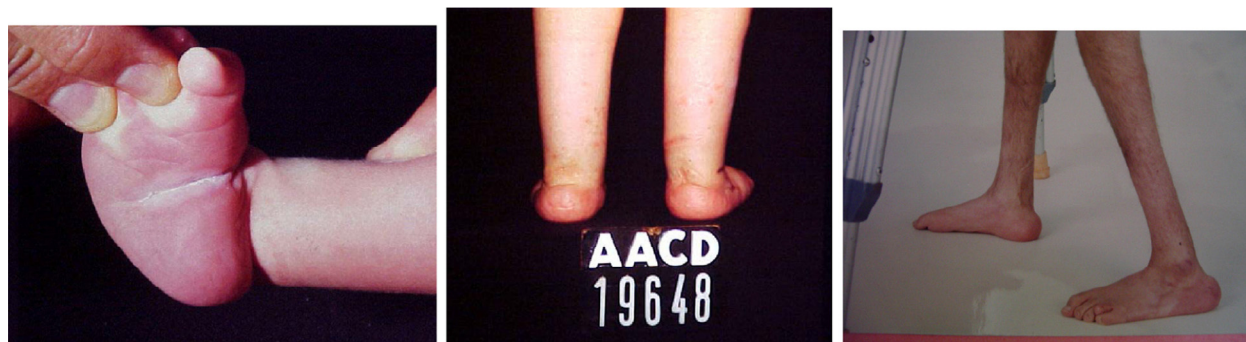

Fig. 4 – Patient with myelodysplastic feet who underwent surgical correction by means of PMLR at the age of nine months. Good evolution, with the ability to walk within the community, presenting plantigrade feet compatible with bracers and without scars. Preoperative situation (pre-op), second year after the operation and 17th year after the operation.

patients with myelodysplasia and that the surgical procedure is extensive. During the operation, if procedures such as talectomy and shortening of the lateral column become necessary, these should be performed during the same operation, so as not to leave residual deformities and thus to diminish the possibility of recurrence.

Conclusion

The surgical treatment instituted in these myelodysplastic feet of patients followed up at our institution was effective in correcting the deformities, with results similar to those found in the literature.

- Postoperative complications occur frequently.
- Residual deformity after the surgical procedure is a factor contributing toward lack of success in treating these feet and therefore should be avoided.
- When posteromedial lateral release is performed without talectomy, it seems to be important to open up the talocalcaneal angle.

Conflicts of interest

The authors declare no conflicts of interest.

REFERENCES

1. Fernandes AC. Malformações do tubo neural. In: Hebert S, Xavier R, Pardini Júnior AG, Barros Filho TEP (org.). *Ortopedia e traumatologia: princípios e prática*. 3rd ed. Porto Alegre: Artmed; 2003. p. 839-57.
2. Mazur JM. Management of foot and ankle deformities in the ambulatory child with myelomeningocele. In: Sarwak JF, editor. *Caring for the child with spina bifida*. Oak Brook: American Academy of Orthopaedic Surgeon; 2002. p. 155-60.
3. Sharrard WJ, Grosfield I. The management of deformity and paralysis of the foot in myelomeningocele. *J Bone Joint Surg Br*. 1968;50(3):456-65.
4. Lindseth RE. Myelomeningocele. In: Wood W, Lovell RB, Winter RT, editors. *Morrissy: Lovell and Winter's pediatric orthopaedics*. 4th ed. Philadelphia: Lippincott Williams & Wilkins; 1996. p. 527-9.
5. Tachdjian MO. Mielomeningocele. In: Tachdjian MO, editor. *Ortopedia pediátrica*. Tradução Ana Paula Tedesco Gabrieli. São Paulo: Manole; 1995. p. 1953-5.
6. Frischhut B, Stöckl B, Landauer F, Krismer M, Menardi G. Foot deformities in adolescents and young adults with spina bifida. *J Pediatr Orthop B*. 2000;9(3):161-9.
7. Svartman C, Fucs PM, Kertzman PF, Nishi RK, Soni JF, Haguiera WJ. Talectomia no tratamento das deformidades rígidas dos pés na artrogripose e seqüela de mielomeningocele. *Rev Bras Ortop*. 1993;28(4):453-7.
8. Menelaus MB. Talectomy for equinovarus deformity in arthrogryposis and spina bifida. *J Bone Joint Surg Br*. 1971;53(3):468-73.

9. Menelaus MB. Leg and foot deformities. In: Menelaus MB, editor. *The orthopaedics management of spina bifida cystic*. New York: Churchill-Livingstone; 1980. p. 92-104.
10. Cooper RR, Capello W. Talectomy. A long-term follow-up evaluation. *Clin Orthop Relat Res*. 1985;(201):32-5.
11. Hsu LC, Jaffray D, Leong JC. Talectomy for club foot in arthrogyposis. *J Bone Joint Surg Br*. 1984;66(5):694-6.
12. Carvalho Neto J, Dias LS, Gabrieli AP. Congenital talipes equinovarus in spina bifida: treatment and results. *J Pediatr Orthop*. 1996;16(6):782-5.
13. Dias LS, Stern LS. Talectomy in the treatment of resistant talipes equinovarus deformity in myelomeningocele and arthrogyposis. *J Pediatr Orthop*. 1987;7(1):39-41.
14. Gerlach DJ, Gurnett CA, Limpaphayom N, Alaei F, Zhang Z, Porter K, et al. Early results of the Ponseti method for the treatment of clubfoot associated with myelomeningocele. *J Bone Joint Surg Am*. 2009;91(6):1350-9.
15. Turco VJ. Surgical correction of the resistant club foot. One-stage posteromedial release with internal fixation: a preliminary report. *J Bone Joint Surg Am*. 1971;53(3):477-97.
16. Crawford AH, Marxen JL, Osterfeld DL. The Cincinnati incision: a comprehensive approach for surgical procedures of the foot and ankle in childhood. *J Bone Joint Surg Am*. 1982;64(9):1355-8.
17. Sherk HH, Ames MD. Talectomy in the treatment of the myelomeningocele patient. *Clin Orthop Relat Res*. 1975;(110):218-22.
18. Legaspi J, Li YH, Chow W, Leong JC. Talectomy in patients with recurrent deformity in club foot. A long-term follow-up study. *J Bone Joint Surg Br*. 2001;83(3):384-7.
19. Salomão O, Carvalho Junior AE, Fernandes TD, Marques J, Yamura M, Freitas RB. Astragalectomia no tratamento de pés equinovaros congênitos (PTC) inveterados e recidivados. *Rev Bras Ortop*. 1993;28(7):449-52.
20. Sodré H, Mestriner LA, Pinto JA, Lourenço AF, Adames MK. Tratamento cirúrgico do pé torto equinovaro congênito idiopático. Avaliação pós-operatória de 164 pés. *Rev Bras Ortop*. 1997;32(1):21-6.
21. Atar D, Lehman WB, Grant AD. Revision surgery in clubfeet. *Clin Orthop Relat Res*. 1982;(283):223-30.
22. Sodré H, Adames MH, Tamanaga F. Hipercorreção pós-operatória no pé torto equinovaro congênito. *Rev Bras Ortop*. 1996;31(7):567-70.