



## Technical Note

# Gluteal pain in athletes: how should it be investigated and treated?☆



Guilherme Guadagnini Falótico\*, Diogo Fernandes Torquato, Ticiane Cordeiro Roim, Edmilson Takehiro Takata, Alberto de Castro Pochini, Benno Ejnisman

Universidade Federal de São Paulo, São Paulo, SP, Brazil

### ARTICLE INFO

#### Article history:

Received 30 April 2014

Accepted 1 July 2014

Available online 18 July 2015

#### Keywords:

Pain

Buttocks

Athletes

#### Palavras-chave:

Dor

Nádegas

Aletas

### ABSTRACT

Gluteal pain is a frequent symptom in athletes, and defining it etiologically is a challenge for orthopedists. In the present study, using an anatomical approach to the posterior region of the pelvis and the proximal femur, divided into four quadrants, systematized investigation is proposed with the aim of optimizing the treatment and accelerating athletes' return to their sport, through correct diagnosis.

© 2014 Sociedade Brasileira de Ortopedia e Traumatologia. Published by Elsevier Editora Ltda. All rights reserved.

### Dor glútea em atletas – como investigar e tratar?

#### R E S U M O

A dor glútea é um sintoma frequente em atletas. Sua definição etiológica é um desafio para o ortopedista. No presente estudo, os autores propõem, por meio de uma abordagem anatômica da região posterior da pelve e do fêmur proximal, dividida em quatro quadrantes, a investigação sistematizada do local, visando, por meio do diagnóstico correto, a aperfeiçoar o tratamento e acelerar o retorno do atleta ao esporte.

© 2014 Sociedade Brasileira de Ortopedia e Traumatologia. Publicado por Elsevier Editora Ltda. Todos os direitos reservados.

## Introduction

Gluteal pain is a common manifestation among athletes, although its investigation is quite challenging in orthopedic

practice because the pain can originate not only from the gluteal structures themselves, but also from the lumbosacral spine, sacroiliac joint and hips.<sup>1</sup>

This issue, although frequent in the daily routine of sports orthopedists, is little discussed in the current literature.

☆ Work developed in the Hip Sector, Centro de Traumatologia do Esporte (Cete), Escola Paulista de Medicina, Universidade Federal de São Paulo, São Paulo, SP, Brazil.

\* Corresponding author.

E-mail: [gxfalotico@yahoo.com.br](mailto:gxfalotico@yahoo.com.br) (G.G. Falótico).

<http://dx.doi.org/10.1016/j.rboe.2015.07.002>

2255-4971/© 2014 Sociedade Brasileira de Ortopedia e Traumatologia. Published by Elsevier Editora Ltda. All rights reserved.

The present study proposes a model for investigating this condition among athletes.

## Description of the method

The area to be studied was delimited by four imaginary lines: superiorly, a horizontal line tangential to the upper border of the iliac crest; inferiorly, a horizontal line tangential to the lower border of the ischial tuberosity; medially, a vertical line that passes through the center of the sacrum; and laterally, a vertical line tangential to the lateral border of the greater trochanter.

Within this imaginary rectangle, four quadrants were delimited starting from the posterosuperior iliac spine (Fig. 1).

### Superomedial quadrant (A)

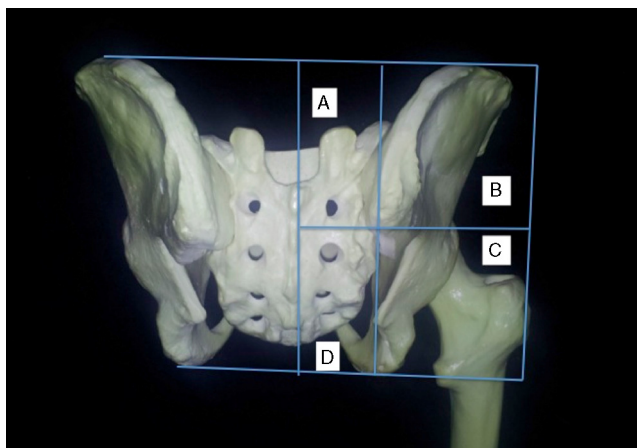
The palpable structures of interest are the spinous processes of L4 and L5 and the joint interline of the sacroiliac joint.

The most frequent disorders of this quadrant are chronic lower back pain due to muscle-ligament injury, radiculopathy due to a herniated disc and pain from the sacroiliac joint.

Other diagnoses include stress fractures of the sacrum, spondylolysis/spondylolisthesis and facet arthropathy.

### Lower back pain due to muscle-ligament injury

This condition accounts for approximately 97% of the chronic lesions in the lumbosacral spine of athletes.<sup>2</sup> Lower back pain is usually caused by vigorous eccentric muscle contraction, and the lesion is usually next to the myotendinous junction.<sup>3</sup> Moreover, injury to the iliolumbar ligament is also a cause of lower back pain and gluteal pain and even simulates sacroiliac disorders.<sup>1</sup>



**Fig. 1 – Posterior photograph of the bone anatomy of the pelvis and right proximal femur with division into four quadrants starting from the posterosuperior iliac spine.**

## Radiculopathy

Approximately 90% of radicular compressions occur at the levels of L4-L5 and L5-S1.<sup>4</sup> This condition has been well studied through magnetic resonance imaging.

In sports that require extreme torsional movements of the lumbosacral spine (e.g. tennis or baseball), larger numbers of participants are affected.<sup>5</sup>

The physical examination may demonstrate neurological alterations in the affected dermatome and Lasègue's test may be positive.

The majority of patients respond to non-surgical treatment. Surgery is indicated in cases of progressive neurological deficit, sphincter dysfunction, sexual dysfunction and refractory pain.<sup>2</sup>

## Sacroiliac pain

The sacroiliac joint is essential for proper load transference from the lower back spine to the pelvis.<sup>6</sup> Hyper- or hypomobility of this joint can lead to painful symptoms.<sup>7,8</sup>

The pain typically affects the superomedial quadrant of the gluteal region, although it can also affect the lower back region, thighs, lateral region of the hips and inguinal region,<sup>7,8</sup> because of the extensive local innervation.<sup>9-11</sup>

Various sports activities can trigger sacroiliac pain. The most frequent ones are those that involve running, jumping and abrupt changes in direction. Approximately 64% of the patients have a history of chronic trauma or microtraumas due to repetition.<sup>12</sup>

The clinical examination may reveal alterations of pelvic inclination and lower back curvature, discrepancy in the lengths of the lower limbs and pelvic hypermotion during gait. The patients often feel pain upon local palpation and there are various trigger points in the adjacent musculature.<sup>13</sup> Provocative maneuvers may be positive. Moreover, the thigh compression test has great diagnostic specificity.<sup>14,15</sup>

Imaging examinations, including radiographs, computed tomography (CT) and magnetic resonance imaging (MRI), can help in the diagnosis, although the gold standard is injection of an anesthetic, guided by means of fluoroscopy, with disappearance of the symptoms.<sup>8</sup>

Treatment should focus on muscle strengthening and pelvis stabilization. Braces to compensate for discrepancies of the lower limbs are useful. Local injections of corticoids should be recommended for cases that are refractory to clinical treatment after 1 month or, if the initial pain is very intense, in order to accelerate rehabilitation.<sup>16-20</sup>

In addition, patients who are refractory to conventional treatment, especially young men who are bilaterally affected and present associated systemic symptoms or morning joint stiffness, should be more thoroughly investigated regarding ankylosing spondylitis.<sup>21</sup>

## Fracture due to sacral stress

This condition represents 1-20% of lesions in sport trauma and is often related to weakness or fatigue of the local musculature in bones that are subjected to high cyclical loads.<sup>22,23</sup>

Young women with a high training load, nutritional deficiency and irregularities in their menstrual cycles are more affected.<sup>7,24-26</sup> This condition has also been described among male soldiers.<sup>23</sup>

Physical examination shows pain due to palpation of the sacrum, exacerbated by provocative tests on the sacroiliac joint.

MRI is an excellent complementary diagnostic method because fractures are already visible within 72h of evolution.<sup>24,27</sup>

Treatment demands protection from loads on the affected side until pain relief has been achieved. After the analgesic phase, a rehabilitation protocol focusing on pelvic and lower back stabilization should be drawn up.

The return to sports practice initially includes low-impact activities. Competitive practice is usually allowed after 12 weeks. Calcium and vitamin D replacement is recommended for women with osteopenia.<sup>25</sup>

### **Spondylolysis/spondylolisthesis**

Spondylolysis is caused by a defect of the pars interarticularis. Its incidence among athletes ranges from 8% to 15%. The most common traumatic form occurs among gymnasts, soccer players, ballerinas and weightlifters.<sup>28</sup>

Spondylolisthesis comprises sliding of one vertebra over another. Bilateral spondylolysis is a risk factor. Sliding greater than 25% is frequently associated with a painful condition.<sup>29</sup>

Conservative treatment is successfully indicated for the majority of cases. The return to the sport usually occurs between 4 and 6 months after the beginning of rehabilitation.

Surgery is indicated among approximately 9-15% of the patients because of refractory pain more than 6 months after the treatment, neurological deficit or vertebral instability.<sup>28</sup>

### **Facet arthropathy**

Facet joints are located in the posterior area of the spine between adjacent vertebrae. Local pain is more frequent among athletes over 40 years of age.

Torsional trauma of the spine, with pain that worsens with lumbar extension and which can irradiate to the upper gluteal area, suggests the disease.<sup>30</sup> Magnetic resonance imaging can be requested to confirm the diagnosis.

In short, pain from the superomedial quadrant of the gluteal region can originate from the lumbosacral spine and the sacroiliac joint. We suggest that, in the routine of the clinical examination for diseases in this quadrant, stress tests on the sacroiliac joint should be included (Gaenslen, thigh compression, sacral compression and Fabere), as well as the straight leg elevation test and Lasègue.

Patients with persistent pain that is refractory to the conventional treatment, i.e. nonsteroidal anti-inflammatory drugs (NSAIDs), reduction of training load and physiotherapy, must undergo imaging investigation. The examination suggested for studying this quadrant is magnetic resonance imaging of the lumbosacral area including the sacroiliac joint. Electromyography is also suggested for patients with neurological symptoms.

## **Superolateral quadrant (B)**

The palpable structure of interest is the posterior border of the iliac crest.

The most frequent disorder in this quadrant is myofascial pain syndrome, which affects the gluteus maximus and gluteus medius and is characterized by the formation of painful trigger points in the muscle mass itself or in the fascia insertion. Trigger points are usually associated with chronic trauma or repeated microtrauma of the muscles involved and lead to muscle fatigue, which favors creation of other trigger points, thus generating a pathological vicious circle.<sup>31</sup>

The diagnosis is clinical, through investigation of trigger points, and the treatment involves reduction of the training load and physiotherapy, with manipulation of the painful spots and subsequent muscle stretching and strengthening and use of drugs: anti-inflammatory drugs, muscle relaxants, tricyclic antidepressants or anticonvulsants (e.g. gabapentin), depending on the duration of the pain and the profile of the patient. Infiltration of trigger points is also very useful in cases that are refractory to the initial measures.<sup>31</sup>

The possible differential diagnoses include chronic muscle lesions and enthesopathy of the origin of the gluteal muscles in the iliac crest.

For patients who are refractory to conventional treatment, the complementary examinations indicated are magnetic resonance imaging of the pelvis, to evaluate the muscle insertions in the iliac crest, and electromyography, to investigate possible pain irradiating from nerve compression that was not clinically suspected.

## **Inferolateral quadrant (C)**

The palpable structures of interest are the ischial tuberosity, ischial spine and greater trochanter.

In this quadrant, the most frequent disorders are injuries at the origin of the hamstrings, greater trochanteric pain syndrome, piriformis syndrome and ischial bursitis.

Other diagnoses are: ischiofemoral impingement/lesion of the quadratus femoris, fracture due to stress in the ischiopubic ramus and ischial tumors. The most frequent diagnoses in this location are osteochondromas and chondrosarcomas.

### **Hamstring injuries**

Tendinopathy of the origin of the hamstrings occurs quite frequently in middle and long-distance runners. Muscle weakness or fatigue, associated with eccentric contraction during the late swing phase of the run, predisposes toward injuries.<sup>32</sup> The pain can be reproduced through palpation of the ischial tuberosity or through passive flexion of the hip associated with active flexion of the knee against resistance. Localized pain distal to the ischium is generally associated with hamstring muscle injuries, while pain proximal to the ischial tuberosity may be related to piriformis syndrome.<sup>1</sup>

Cases of chronic tendinopathy or extensive traumatic lesions (e.g. bone deinsertion/avulsion) may occur with sciatic

pain due to chemical irritation or an extrinsic compression effect on the sciatic nerve caused by hematoma.<sup>33</sup>

Radiography may demonstrate calcification adjacent to the ischium and bone avulsion. However, the preferred examination for the diagnosis is magnetic resonance imaging.<sup>34,35</sup>

The treatment involves anti-inflammatory and analgesic medication, as well as physiotherapy.

In refractory cases, infiltration of corticoid guided by ultrasound, injection of platelet-rich plasma and surgical debridement can be performed.<sup>36</sup>

In cases of bone deinsertion or avulsion, early surgical treatment (4-6 weeks after the injury) presents good results.<sup>3</sup>

### Greater trochanteric pain syndrome

Greater trochanteric pain syndrome is defined as painful palpation of the greater trochanter with the patient positioned in lateral decubitus. It involves various disorders of the peritrochanteric space of the hip, such as trochanteric bursitis, tendinopathy/lesion of the gluteus medius and gluteus minimus and external hip snapping.<sup>37</sup>

Patients often complain about pain in the lateral and posterior areas of the greater trochanter, which became worse during the support phase of the affected limb during walking or running. An association with chronic lower back pain is quite frequent.<sup>37</sup>

In the physical examination, in addition to pain on palpation of the trochanter, the Trendelenburg test can be positive and the pain can be exacerbated through abduction of the affected hip against resistance (Beatty test).<sup>1,37</sup>

The diagnosis is clinical and imaging examinations may be indicated for patients with inadequate responses to treatment. The most useful examinations are ultrasonography and magnetic resonance imaging.

The treatment involves medication, physiotherapy and local infiltration of corticoid. Surgical treatment is indicated in refractory cases, especially when there is a rupture of the gluteus medius/minimus (in these cases, suturing) or external snapping (in these cases, surgical lengthening of the hamstring muscles).<sup>3,37</sup>

### Piriformis syndrome

Piriformis syndrome is described as gluteal pain associated with sciatic pain that was secondary to compression of the sciatic nerve by the piriformis muscle.

Approximately 5% of the cases of lower back pain, gluteal pain and pain radiating from the posterior aspect of the lower limb are associated with the syndrome.<sup>38</sup> However, there is controversy regarding the definition of the syndrome, because a large proportion of the patients with this diagnosis do not present clinical or electromyographic neurological alterations.<sup>39</sup>

It can also be attributed to piriformis myalgia, resulting from its relative weakness in relation to the gluteal musculature.<sup>1</sup>

Clinical examination often shows pain on palpation proximally to the ischial spine, in the area of the greater sciatic notch, over the piriformis muscle, which is frequently hardened in comparison with the unaffected side. The

clinical tests described are the Freiberg, Pace, Beatty and Faduri tests.<sup>40-43</sup>

Because this is a diagnosis through exclusion, other causes of neuropathy need to be investigated.

In this context, magnetic resonance neurography forms an important diagnostic option. In this technique, high-resolution 1 mm slices are used, with T1 and T2-weighted sequences with fat suppression. This enables thorough evaluation of the sciatic nerve, from its formation by the lumbosacral roots to its path through the gluteal region and thigh. In this manner, the exact anatomical structure responsible for compression of the nerve can be shown.<sup>44</sup>

The treatment is based on stretching and strengthening of the external rotator muscles of the hips and gluteal region. Cases that remained refractory after 6 weeks of rehabilitation can undergo infiltration of corticoid, anesthetic or botulinum toxin.<sup>41</sup>

Surgical release of the piriformis (open or endoscopic) has been cited by some authors in small case series and should be indicated with caution after ruling out the more frequent diagnoses for sciatic pain.<sup>45-47</sup>

### Sciatic bursitis

Sciatic bursitis is associated with excess force exerted by the hamstring muscles on the bursa. These patients generally complain of pain when they remain sitting for long periods and the clinical examination reveals pain over the ischial tuberosity. It can appear separately or in association with tendinopathy of the hamstrings.

The diagnostic confirmation can be obtained through ultrasonography or magnetic resonance imaging and most patients evolve well after 6-8 weeks of conservative treatment. Again, refractory cases can undergo local infiltration.

Chronic cases associated with tendinopathy may require surgical treatment for bursectomy and tendon debridement or tenotomy.<sup>26,37</sup>

---

### Ischiofemoral impingement

Some authors have correlated the reduction of the ischiofemoral interval with compression of the quadratus femoris and the emergence of gluteal pain symptoms.

Female morphology, with a broad and shallow pelvis, predisposes these patients toward ischiofemoral impingement. All the cases described in the literature have been among women.

The clinical diagnosis is usually difficult because the complaints are vague and clinical examination is imprecise.

The tests described for evaluating the piriformis syndrome can be painful because the quadratus femoris is also an external rotator of the hip. There is no record of neurological symptoms associated with ischiofemoral impingement.

The main author of the present study, along with other authors, described a maneuver for ischiofemoral impingement. It consists of examining the patient in lateral decubitus at the edge of the examination table, with the symptomatic side up. Next, the hip is extended and adducted, and successive movements of internal and external rotation are performed in

**Table 1 – Diagnoses of gluteal pain.**

Quadrants	Main diagnoses	Clinical examination	Examinations
Superomedial	Chronic lower back pain Radiculopathy Sacroiliac pain	Lasègue Axial compression of the thigh Fabere Gaeslen	Lumbosacral MRI ENMG
Superolateral	Myofascial pain (gluteus maximus and medius)	Investigation of trigger points	MRI of the pelvis (patients refractory to treatment)
Inferolateral	Greater trochanteric pain syndrome Piriformis syndrome Tendinopathy of the hamstrings	Lasègue Freiberg/Beatty Flexion of the knee against resistance	MRI of the hip Dynamic ENMG (Faduri) Neurography of the sciatic nerve
Inferomedial	Coccydynia  Pelvic floor dysfunction  Sacral plexus lesion	Detailed palpation  Neurological examination (sacral roots)	Dynamic radiography of the coccyx MRI of the pelvic floor ENMG

order to reproduce the impact with the tensioned quadratus femoris.

Magnetic resonance imaging is essential for the diagnosis and usually shows alterations in the muscle belly of the quadratus femoris.

Non-surgical treatment has been described as effective and involves a protocol of stretching exercises, corticoid infiltrations, neurostimulation and physiotherapy using percutaneous ultrasound.

Surgical treatment has only been described in cases secondary to femoral deformity or tumors.<sup>48</sup>

### Fracture of the ischiopubic ramus due to stress

Fractures of the ischiopubic ramus are rare injuries. This condition evolves with insidious occurrence of gluteal pain and is generally associated with intensification of training intensity. The diagnosis depends on a high level of suspicion.<sup>23</sup>

Clinical examination can show a worsening of the pain in an upright standing position with weight-bearing on one foot on the affected side, as well as pain in the hop test.<sup>23,49</sup>

Magnetic resonance imaging usually confirms the diagnosis and the treatment includes analgesic drugs and training load reduction for 6–8 weeks.

To standardization disease evaluations in this quadrant, we recommend that, after thorough palpation of the bone points of interest, the clinical tests of Freiberg, Pace, Beatty and Faduri, the test of passive flexion of the hip with active flexion of the knee and the test for ischiofemoral impingement should be performed.

Investigation through examinations, when required, should involve magnetic resonance imaging of the hip and, when neurological symptoms are present, electroneuromyography. If the origin of the sciatic pain is not clarified through these techniques, neurography of the sciatic nerve can be requested.

### Inferomedial quadrant (D)

The palpable structure of interest is the coccyx.

The disorders in this quadrant are coccydynia, chronic dysfunction of the pelvic floor, lesions of the sacral plexus and tumors of the sacrum. Chordomas are the most common type of tumor in this location.

### Coccydynia

The coccyx is frequently involved in chronic perineal pain. In a study involving 208 patients with pain in the coccyx, excessive mobility was the etiological factor in 27% of the cases. The pain was caused by posterior dislocation of the coccyx in 22%; it was related to the presence of bone spicules in 14%; it originated from anterior dislocation in 5%; and its etiology remained undefined (idiopathic) in 31%. Trauma is another etiological factor of considerable importance because it may be associated with instability of the coccyx, especially with posterior subluxation of the coccyx.<sup>50</sup>

The diagnosis can be established by means of dynamic radiography (with the patient sitting and in an upright standing position) and by magnetic resonance imaging, which can present local inflammatory hypersignal, as well as through evaluation of possible neoplasia.<sup>51</sup>

The treatment involves anti-inflammatory drugs, along with mechanical protection of the coccyx with cushions for patients who spend long time sitting. Physiotherapy with pelvic stabilization may aid in this.

Refractory cases can undergo infiltrations of anesthetic and corticoid and also surgical resection (partial or total) of the coccyx.<sup>52</sup>

### Chronic dysfunction of the pelvic floor

Chronic dysfunction of the pelvic floor is a condition that can be present in women after pregnancy, in situations subsequent to pelvic trauma or in cyclists. Usually there is insufficiency of the coccygeus muscle and levator ani (which comprise the pelvic floor) and the pubococcygeus ligament.

In the presence of risk factors, the investigation should include magnetic resonance imaging of the pelvic floor and also electroneuromyography to evaluate the electrical activity of the these muscles.

The treatment involves strengthening and stabilization of the pelvic floor.<sup>53</sup>

### Lesions of the sacral-coccygeal plexus

Lesions of the sacral-coccygeal plexus are rare in athletes. When symptoms are present, extrinsic compression by neoplasia or endometriosis should be suspected. The investigation includes electroneuromyography and magnetic resonance imaging of the pelvis.

Athletes with this condition must halt their sports practice until the investigation is complete and proper treatment has been instituted.<sup>1,54,55</sup>

The main data from the physical examination in this quadrant comes from palpation of the bone structures of interest. Cases without any response to symptomatic treatment should be investigated by means of dynamic radiography to evaluate the coccyx, as well as by means of magnetic resonance imaging of the pelvis. In cases of neurological symptoms, electroneuromyography should be included in the sequence of examinations requested.

A summary of the diagnoses, clinical examinations and complementary examinations required for diagnosing gluteal pain in athletes can be seen in [Table 1](#).

### Final remarks

Investigation of gluteal pain requires wide knowledge of the various possible diagnoses as well as establishment of a routine of clinical examination and complementary examinations.

Through an anatomical approach according to the quadrants, we propose a model for systematizing the evaluation of athletes with gluteal symptoms, thus aiming to ensure proper treatment.

### Conflicts of interest

The authors declare no conflicts of interest.

### REFERENCES

- Vasudevan JM, Smuck M, Fredericson M. Evaluation of the athlete with buttock pain. *Curr Sports Med Rep*. 2012;11(1):35-42.
- Trainor TJ, Trainor MA. Etiology of low back pain in athletes. *Curr Sports Med Rep*. 2004;3(1):41-6.
- Anderson K, Strickland SM, Warren R. Hip and groin injuries in athletes. *Am J Sports Med*. 2001;29(4):521-33.
- Lawrence JP, Greene HS, Grauer JN. Back pain in athletes. *J Am Acad Orthop Surg*. 2006;14(13):726-35.
- Watkins RG. *The spine in sports*. St. Louis: Mosby; 1996.
- Foley BS, Buschbacher RM. Sacroiliac joint pain: anatomy, biomechanics, diagnosis, and treatment. *Am J Phys Med Rehabil*. 2006;85(12):997-1006.
- Brukner P, Khan K. *Clinical sports medicine*. Sydney: McGraw Hill; 2010.
- Chen YC, Fredericson M, Smuck M. Sacroiliac joint pain syndrome in active patients: a look behind the pain. *Phys Sportsmed*. 2002;30(11):30-7.
- Atlihan D, Tekdemir I, Ateş Y, Elhan A. Anatomy of the anterior sacroiliac joint with reference to lumbosacral nerves. *Clin Orthop Relat Res*. 2000;376:236-41.
- Fortin JD, Washington WJ, Falco FJ. Three pathways between the sacroiliac joint and neural structures. *AJNR Am J Neuroradiol*. 1999;20(8):1429-34.
- Fortin JD, Kissling RO, O'Connor BL, Vilensky JA. Sacroiliac joint innervation and pain. *Am J Orthop (Belle Mead NJ)*. 1999;28(12):687-90.
- Slipman CW, Patel RK, Whyte WS. Diagnosing and managing sacroiliac pain. *J Musculoskelet Med*. 2001;18:325-32.
- Brolinson PG, Kozar AJ, Cibor G. Sacroiliac joint dysfunction in athletes. *Curr Sports Med Rep*. 2003;2(1):47-56.
- Solonen KA. The sacroiliac joint in the light of anatomical, roentgenological and clinical studies. *Acta Orthop Scand Suppl*. 1957;27:1-127.
- Laslett M, Williams M. The reliability of selected pain provocation tests for sacroiliac joint pathology. *Spine (Phila PA 1976)*. 1994;19(11):1243-9.
- Broadhurst NA, Bond MJ. Pain provocation tests for the assessment of sacroiliac joint dysfunction. *J Spinal Disord*. 1998;11(4):341-5.
- Dreyfuss P, Cole AJ, Pauza K. Sacroiliac joint injection techniques. *Phys Med Rehabil Clin North Am*. 1995;6:785-814.
- Kinard RE. Diagnostic spinal injection procedures. *Neurosurg Clin North Am*. 1996;7(1):151-65.
- Maigne JY, Aivaliklis A, Pfefer F. Results of sacroiliac joint double block and value of sacroiliac pain provocation tests in 54 patients with low back pain. *Spine (Phila PA 1976)*. 1996;21(16):1889-92.
- Schwarzer AC, Aprill CN, Bogduk N. The sacroiliac joint in chronic low back pain. *Spine (Phila PA 1976)*. 1995;20(1):31-7.
- Harper BE, Reveille JD. Spondyloarthritis: clinical suspicion, diagnosis, and sports. *Curr Sports Med Rep*. 2009;8(1):29-34.
- Delvaux K, Lysens R. Lumbosacral pain in an athlete. *Am J Phys Med Rehabil*. 2001;80(5):388-91.
- Fredericson M, Jennings F, Beaulieu C, Matheson GO. Stress fractures in athletes. *Top Magn Reson Imaging*. 2006;17(5):309-25.
- Bottomley MB. Sacral stress fracture in a runner. *Br J Sports Med*. 1990;24(4):243-4.
- Fredericson M, Salamanca L, Beaulieu C. Sacral stress fractures: tracking down nonspecific pain in distance runners. *Phys Sportsmed*. 2003;31(2):31-42.
- Tibor LM, Sekiya JK. Differential diagnosis of pain around the hip joint. *Arthroscopy*. 2008;24(12):1407-21.
- Johnson AW, Weiss CB Jr, Stento K, Wheeler DL. Stress fractures of the sacrum. An atypical cause of low back pain in the female athlete. *Am J Sports Med*. 2001;29(4):498-508.
- Standaert CJ, Herring SA. Spondylolysis: a critical review. *Br J Sports Med*. 2000;34(6):415-22.
- Saraste H. Long-term clinical and radiological follow-up of spondylolysis and spondylolisthesis. *J Pediatr Orthop*. 1987;7(6):631-8.
- Heck JF, Sparano JM. A classification system for the assessment of lumbar pain in athletes. *J Athl Train*. 2000;35(2):204-11.
- Lavelle ED, Lavelle W, Smith HS. Myofascial trigger points. *Med Clin North Am*. 2007;91(2):229-39.
- Koller A, Sumann G, Schobersberger W, Hoertnagl H, Haid C. Decrease in eccentric hamstring strength in runners in the Tirol Speed Marathon. *Br J Sports Med*. 2006;40(10):850-2.
- Puranen J, Orava S. The hamstring syndrome. A new diagnosis of gluteal sciatic pain. *Am J Sports Med*. 1988;16(5):517-21.
- Verrall GM, Slavotinek JP, Barnes PG, Fon GT, Spriggins AJ. Clinical risk factors for hamstring muscle strain injury: a prospective study with correlation of injury by magnetic resonance imaging. *Br J Sports Med*. 2001;35(6):435-9.

35. Zissen MH, Wallace G, Stevens KJ, Fredericson M, Beaulieu CF. High hamstring tendinopathy: MRI and ultrasound imaging and therapeutic efficacy of percutaneous corticosteroid injection. *AJR Am J Roentgenol.* 2010;195(4):993-8.
36. Fredericson M, Moore W, Guillet M, Beaulieu C. High hamstring tendinopathy in runners: meeting the challenges of diagnosis, treatment, and rehabilitation. *Phys Sportsmed.* 2005;33(5):32-43.
37. Strauss EJ, Nho SJ, Kelly BT. Greater trochanteric pain syndrome. *Sports Med Arthrosc.* 2010;18(2):113-9.
38. Papadopoulos EC, Khan SN. Piriformis syndrome and low back pain: a new classification and review of the literature. *Orthop Clin North Am.* 2004;35(1):65-71.
39. Stewart JD. Focal peripheral neuropathies. 3rd ed. Philadelphia: Lippincott Williams & Wilkins; 2000.
40. Beatty RA. The piriformis muscle syndrome: a simple diagnostic maneuver. *Neurosurgery.* 1994;34(3):512-4.
41. Fishman LM, Dombi GW, Michaelsen C, et al. Piriformis syndrome: diagnosis, treatment, and outcome – a 10-year study. *Arch Phys Med Rehabil.* 2002;83(3):295-301.
42. Freiberg AH, Vinke TH. Sciatica and the sacroiliac joint. *J Bone Joint Surg.* 1934;16:126.
43. Pace JB, Nagle D. Piriform syndrome. *West J Med.* 1976;124(6):435-9.
44. Polesello GC, Queiroz MC, Linhares JPT, Amaral DT, Ono NK. Variação anatômica do músculo piriforme como causa de dor glútea profunda: diagnóstico por neurografia por RM e seu tratamento. *Rev Bras Ortop.* 2013;48(1):114-7.
45. Benson ER, Schutzer SF. Posttraumatic piriformis syndrome: diagnosis and results of operative treatment. *J Bone Joint Surg Am.* 1999;81(7):941-9.
46. Dezawa A, Kusano S, Miki H. Arthroscopic release of the piriformis muscle under local anesthesia for piriformis syndrome. *Arthroscopy.* 2003;19(5):554-7.
47. Mizuguchi T. Division of the pyriformis muscle for the treatment of sciatica. Postlaminectomy syndrome and osteoarthritis of the spine. *Arch Surg.* 1976;111(6):719-22.
48. Yanagishita CMA, Falotico GG, Rosário DVA, Pugina GG, Wever AAN, Takata ET. Impacto Isquiofemoral – uma etiologia de quadril doloroso. *Rev Bras Ortop.* 2012;47(6):780-3.
49. Daniel D, Malcom L, Stone ML, Perth H, Morgan J, Riehl B. Quantification of knee stability and function. *Contemp Orthop.* 1982;5:83-91.
50. Maigne JY, Doursounian L, Chatellier G. Causes and mechanisms of common coccydynia: role of body mass index and coccygeal trauma. *Spine (Phila PA 1976).* 2000;25(23):3072-9.
51. Fogel GR, Cunningham PY 3rd, Esses SI. Coccygodynia: evaluation and management. *J Am Acad Orthop Surg.* 2004;12(1):49-54.
52. Pennekamp PH, Kraft CN, Stütz A, Wallny T, Schmitt O, Diedrich O. Coccygectomy for coccygodynia: does pathogenesis matter? *J Trauma.* 2005;59(6):1414-9.
53. Almeida MBA, Barra AA, Figueiredo EM, et al. Disfunções de assoalho pélvico em atletas. *Femina.* 2011;39(8):395-402. Available from: <http://files.bvs.br/upload/S/0100-7254/2011/v39n8/a2695.pdf>
54. Krivickas LS, Wilbourn AJ. Peripheral nerve injuries in athletes: a case series of over 200 injuries. *Semin Neurol.* 2000;20(2):225-32.
55. Wilbourn AJ, Aminoff MJ. AAEM minimonograph 32: the electrodiagnostic examination in patients with radiculopathies. *American Association of Electrodiagnostic Medicine. Muscle Nerve.* 1998;21(12):1612-31.