



Original Article

Treatment of congenital clubfoot using Ponseti method[☆]



Alceu José Fornari Gomes Chueire*, Guaracy Carvalho Filho, Otto Yosuke Kobayashi, Leonardo Carrenho

Department of Orthopedics and Traumatology, Faculdade de Medicina de São José do Rio Preto (Famerp), São José do Rio Preto, SP, Brazil

ARTICLE INFO

Article history:

Received 30 May 2015

Accepted 18 June 2015

Available online 4 May 2016

Keywords:

Clubfoot

Lower extremity deformities

Congenital

Manipulation

Orthopedic

Treatment outcome

ABSTRACT

Objective: To quantitatively and qualitatively analyze the results from treatment of congenital clubfoot with a mean follow-up of 4.6 years.

Methods: 26 patients who underwent treatment by means of the Ponseti method were analyzed (total of 39 feet). The mean age at the start of the treatment was 5.65 months. The mean length of the follow-up subsequent to tenotomy of the Achilles tendon was 4.6 years. Patients with secondary clubfoot were excluded. Epidemiological data, radiographic measurements on the Kite angle and data from a satisfaction questionnaire and the Laaveg questionnaire were analyzed.

Results: Among the 26 patients treated, one presented recurrence of the deformity and had to return to the beginning of the treatment. The mean score from the questionnaire and physical examination was 89.76 points, and this result was considered good. 99% of the patients responded that their feet never hurt or hurt only upon great activity; 88% said that their feet did not limit their activities; and 96% said that they were very satisfied or satisfied with the results from the treatment. The mean Kite angle in anteroposterior view was 28.14° and it was 26.11° in lateral view.

Conclusion: Treatment for idiopathic congenital clubfoot by means of the Ponseti method brings better results together with less soft-tissue injury, thus confirming the effectiveness and good reproducibility of this method.

© 2015 Sociedade Brasileira de Ortopedia e Traumatologia. Published by Elsevier Editora Ltda. This is an open access article under the CC BY-NC-ND license (<http://creativecommons.org/licenses/by-nc-nd/4.0/>).

[☆] Study conducted at the Department of Orthopedy and Traumatology, Faculdade de Medicina de São José do Rio Preto (Famerp), São José do Rio Preto, SP, Brazil.

* Corresponding author.

E-mail: afchueire@gmail.com (A.J.F.G. Chueire).

<http://dx.doi.org/10.1016/j.rboe.2015.06.020>

2255-4971/© 2015 Sociedade Brasileira de Ortopedia e Traumatologia. Published by Elsevier Editora Ltda. This is an open access article under the CC BY-NC-ND license (<http://creativecommons.org/licenses/by-nc-nd/4.0/>).

Tratamento do pé torto congênito pelo método de Ponseti

R E S U M O

Palavras-chave:

Pé torto
Deformidades congênicas
Das extremidades inferiores
Manipulação ortopédica
Resultado do tratamento

Objetivo: Analisar quantitativa e qualitativamente os resultados do tratamento do pé torto congênito com seguimento médio de 4,6 anos.

Métodos: Foram analisados 26 pacientes que fizeram tratamento pelo método de Ponseti, total de 39 pés. A média da idade do início do tratamento foi 5,65 meses. O tempo de seguimento após a tenotomia do tendão de Aquiles foi em média de 4,6 anos. Foram excluídos pacientes com pé torto secundário. Foram analisados dados epidemiológicos e mensurações radiográficas do ângulo de Kite e aplicados questionário de satisfação e questionário de Laaveg.

Resultados: Dos 26 pacientes tratados, um apresentou recidiva da deformidade, foi necessário retornar ao início do tratamento. A pontuação média do questionário e do exame físico foi de 89,76, resultado considerado bom; 99% dos pacientes responderam que os pés nunca doem ou doem somente aos grandes esforços; 88% responderam que o pé não limita as atividades; 96% responderam que estão muito satisfeitos ou satisfeitos com os resultados do tratamento. A média do ângulo de Kite na incidência anteroposterior foi de 28,14° e no perfil 26,11°.

Conclusão: O tratamento para pé torto congênito idiopático pelo método Ponseti é o que traz melhores resultados associado a menor lesão de partes moles, o que confirma a eficácia e a boa reprodutibilidade do método.

© 2015 Sociedade Brasileira de Ortopedia e Traumatologia. Publicado por Elsevier Editora Ltda. Este é um artigo Open Access sob uma licença CC BY-NC-ND (<http://creativecommons.org/licenses/by-nc-nd/4.0/>).

Introduction

Congenital clubfoot (CCF), also known as congenital talipes equinovarus, is the most common orthopedic deformity that requires intensive treatment¹ and affects approximately 1:1000 live births.²

It is a congenital dysplasia of all musculoskeletal structures (muscles, tendons, ligaments, osteoarticular and neurovascular structures) distal to the knee.¹ The foot presents equinus, cavus, varus and adducted positions, and is supinated.

CCF etiology may be associated with myelodysplasia, arthrogryposis, or multiple congenital abnormalities, but the most common presentation is the isolated deformity, which is considered to be idiopathic. Many theories have been proposed to explain the etiology of idiopathic CCF. They are related with vascular impairment, external factors (intrauterine positioning), abnormal muscle insertions, and genetic factors.³ In normal fetal development of the lower limbs, between the 6th and 8th week of intrauterine life, feet are similar to clubfeet (equinus, cavus, varus, adducted, and supinated), but by the 12th week the feet move to the normal position. This means that the condition may be due to the permanence of the foot position at the beginning of development. It is safe to state that the CCF etiology is multifactorial and modulated by changes in embryonic development.¹

CCF treatment has been a challenge to orthopedic surgeons. The first treatment reports come from the 19th century, with the use of devices for forced manipulations. In the 1980s and 1990s, soft-tissue posteromedial release surgeries were

performed. This procedures yielded poor outcomes, with stiffness, pain, and functional impairment of the foot.⁴

The Ponseti method is widespread worldwide. It consists of a series of manipulations and immobilizations, as well as Achilles tenotomy to correct CCF deformities. After tenotomy, an orthosis is used to maintain the correction obtained and prevent recurrence.^{3,5-7}

This study aimed to quantitatively and qualitatively analyze the results of treatment for CCF performed by the Pediatric Orthopedics team of our service. Data analysis refers to patients on with mean follow-up of 4.6 years. Through the data obtained, the degree of efficiency and satisfaction with the treatment in our service were assessed.

Methods

The research project was approved by the Medical Ethics Committee of the institution.

The study retrospectively evaluated 26 patients undergoing CCF treatment with the technique described by Ponseti,⁵ from August 2003 to May 2012, comprising a total of 39 feet. The mean age of treatment onset was 5.65 months (1 month to 3 years and 10 months). The mean follow-up time after Achilles tenotomy was 4.6 years (3 months to 8.58 years).

The medical records of all patients treated by the Ponseti method for idiopathic CCF were reviewed. Patients with CCF with neurological or other origin were excluded, as well as those undergoing other treatments. During the review of medical records, the following data were collected: age, date of treatment onset, laterality, presence of comorbidities,

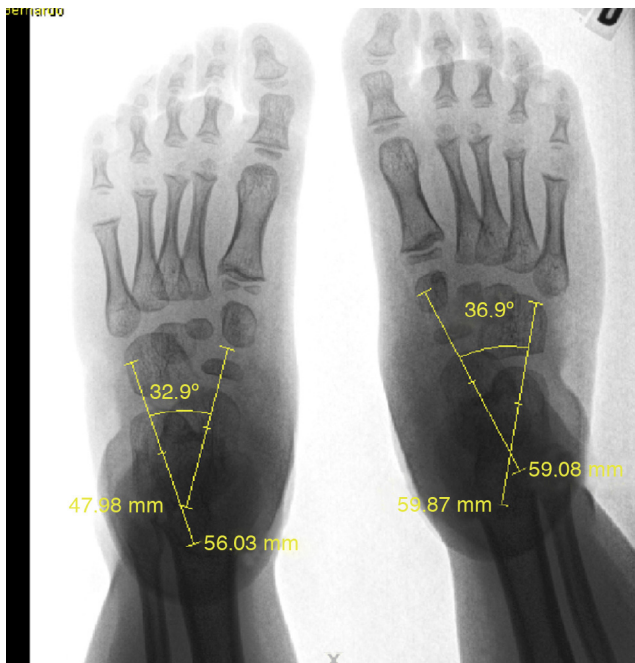


Fig. 1 – Kite angle in anteroposterior view.

number of plaster cast exchanges, age at (and date of) the Achilles tenotomy, and the need for other procedures.

After reviewing the medical records, patients were referred for outpatient follow-up, when gait and range of motion were assessed, and answered the evaluation questionnaire developed by Laaveg and Ponseti⁸ (Appendix 1). Anteroposterior and lateral radiographic imaging of the treated feet were made to measure the Kite angle (talocalcaneal angle; Figs. 1 and 2). Before answering the questionnaire and undergoing physical examination, patients were informed about the study and the parent/guardian signed the informed consent.

Ponseti method

This technique, developed by Ignacio Ponseti, combines manipulation, serial plaster cast immobilizations, percutaneous Achilles tenotomy, and abduction orthosis.

Manipulations and immobilizations were conducted by residents of the Orthopedic Surgery team in an outpatient

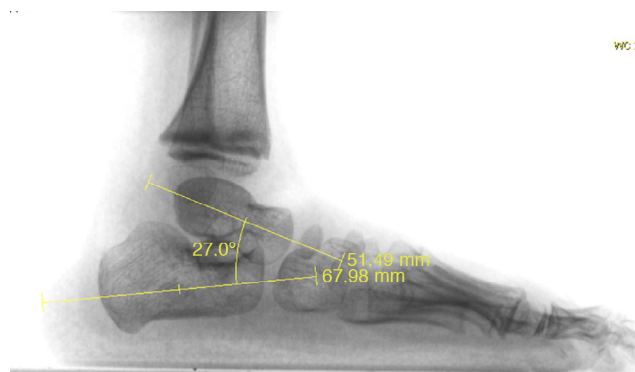


Fig. 2 – Kite angle in lateral view.

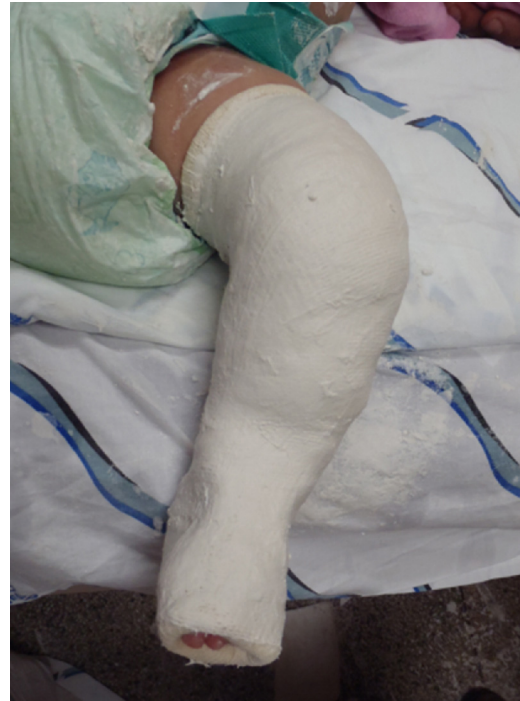

Fig. 3 – Long leg plaster cast correcting cavus, varus, and adduction.

clinic, under the supervision of an experienced pediatric orthopedic surgeon.

The cast changes were made weekly or every two weeks, according to the evolution aspect, and always started by cavus correction, followed by gradual correction of the adduction, supination, and varus (Fig. 3).

After correction of the cavus, varus, adduction and supination, the percutaneous Achilles tenotomy for equinus correction was scheduled.

Achilles tenotomies were performed in the surgery ward with patients under general anesthesia by training residents, under the supervision of an experienced pediatric orthopedic surgeon.

After asepsis and antisepsis of the surgical site, percutaneous Achilles tenotomy was performed with a No. 11 scalpel blade. After suture and dressing, a long leg plaster cast was placed to maintain the correction achieved by surgery.

After three weeks of tenotomy, the plaster cast was removed and the use a Denis-Browne abduction orthosis was initiated, with 70° of external rotation for the pathological foot and 40° for the normal foot, used 23 h/day in the first three months, and then only at night (12–14 h/day) until four years of age.

Results

In the present study, 39 feet from 26 patients were treated: 20 left feet and 19 right feet. The mean age at onset of treatment was 5.7 months (1 month to 3 years and 10 months) and mean age at tenotomy was 10.3 months (4 months to 4 years and 3

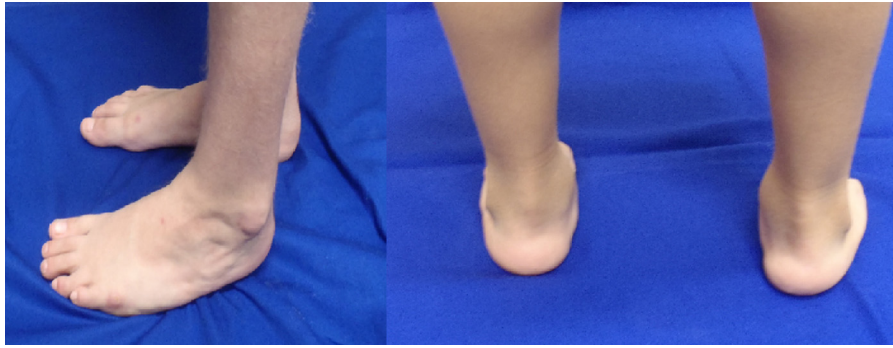


Fig. 4 – Seven-year-old patient, five years after Achilles tenotomy.

months). The mean number of plaster cast used was 8.3 per patient, ranging from 3 to 14.

Of the 26 patients treated, one had deformity recurrence. In this case, it was necessary to resume treatment from the beginning, with new serial casting and new Achilles tenotomy.

The mean score of the questionnaire and physical examination was 89.76, ranging from 69 to 100 (Appendix 2).

The results were classified as excellent when the score was between 90 and 100 points; good, 80–89; fair, 70–79; and poor, lower than 70.

Fifty seven percent of the patients answered that their feet never ached; 42% had pain on exertion; 88% answered that the foot did not limit their activities; 7% reported occasional limitations during activities; 5% reported frequent limitations during activities; 73% said they were very satisfied with the results of treatment; 23% were satisfied; 4% reported being neither satisfied nor dissatisfied (Fig. 4).

The mean passive motion score was 7.61, ranging from 2 to 10.

The mean anteroposterior view Kite angle of right feet was 28.62° and of left feet, 27.68° . Mean lateral view Kite angle of right feet was 27.34° and of left feet, 24.93° . The mean overall anteroposterior view angle was 28.14° , and mean overall lateral view 26.11° .

Discussion

The Ponseti technique for the treatment of CCF has been available and used for over 50 years, but it has gained popularity only in recent decades.⁹

Bor et al.⁹ conducted a study in which 74 patients were treated with the Ponseti method and were followed-up for a mean of 6.3 years. They assessed foot motion and applied a DSI questionnaire, in which all patients showed high satisfaction with the end result and 89% presented good foot motion. In the present study, the mean patient follow-up after tenotomy was 4.6 years, and the questionnaire and physical examination developed by Laaveg and Ponseti were assessed.⁸ The results of the questionnaire and physical examination was 89.76 points, classified as a good score.

In a study that compared the results of surgical treatment by open CCF release with those obtained by Laveeg and Ponseti,⁸ Dobbs et al.¹⁰ observed a mean score of 65.3 points versus 87.5 points, and excellent and good results in 33% of patients versus 74% respectively. They reported that patients treated with open surgery presented weakness in the tibiotarsal and subtalar joints, arthritis, loss of muscle strength (especially the sural triceps), pain and residual deformity. They also reported need of further surgery in 47% of cases.^{11,12} Nonetheless, the authors indicated that this is the only option in case of failure to the Ponseti method.

Ipolito et al.¹³ compared the Ponseti method to another method (Marino-Zuco) and demonstrated the effectiveness of the former in deformity correction using only a simple Achilles tenotomy, in contrast with the latter method, which required more aggressive release surgeries that influenced the outcome of the two groups (78% vs. 43% excellent and good results respectively).

Ponseti et al.⁶ published a study with 322 CCF cases treated by their team, including not only idiopathic CCF, but also patients with neurological diseases and arthrogryposis, in which most had severe clubfeet. Due to the greater severity of deformities, 56% presented recurrences; of these, 18% had a second recurrence and 10% had a third relapse, needing not only Achilles tenotomy, but also medial soft tissue release.⁶ In the present study, all patients had idiopathic CCF, which is considered to be the mildest form, with the best treatment outcomes. In our series, only one patient had deformity recurrence, requiring to restart the treatment, with new serial casting and new Achilles tenotomy.

Conclusion

Currently, the Ponseti method is the treatment for idiopathic CCF that provides the best results, associated with minor soft tissue injury. However, it is a treatment that requires a major commitment from both the family and the orthopedic surgeon, from the period of plaster casting to the essential correct use of the orthosis after the tenotomy. The study presented similar results to those obtained by Laaveg and Ponseti, confirming the effectiveness and good reproducibility of the method.

Conflicts of interest

The authors declare no conflicts of interest.

Appendix 1. CCF Questionnaire – Ponseti method

Patient:

Chart:

Birth date:

Mother's Name:

Telephone:

Age at start of treatment:

Side: ___ Right ___ Left ___ Bilateral

Had been treated in another hospital before: ___ Yes ___ No

Comorbidities: ___ Yes ___ No

If yes, which?

Submitted to another surgical procedure:

Number of casts before tenotomy:

Date of tenotomy:

Age at tenotomy:

Required any other surgical procedures for correction of foot deformity:

___ No

___ Yes

Which? Date?

CCF functional assessment scale – Laaveg, Ponseti.

Satisfaction (20 points)

I'm

- Very satisfied with the end result (20 points)
- Satisfied with the end result (16 points)
- Neither satisfied nor unsatisfied with the end result (12 points)
- Unsatisfied with the end result (8 points)
- Very unsatisfied with the end result (4 points)

Function (20 points)

In my daily life, my clubfoot

- Does not limit my activity (20 points)
- Occasionally limits my strenuous activities (16 points)
- Usually limits me in strenuous activities (12 points)
- Limits me occasionally in routine activities (8 points)
- Limits me in walking (4 points)

Pain (30)

My clubfoot

- Is never painful (30 points)
- Occasionally causes mild pain during strenuous activities (24 points)
- Usually is painful after strenuous activities only (18 points)
- Is occasionally painful during routine activities (12 points)
- Is painful during walking (6 points)

Position of heel when standing (10 points)

- Heel varus 0° or some valgus (10 points)
- Heel varus 0–5° (5 points)
- Heel varus 6–10° (3 points)
- Heel varus greater than 10° (0 points)

Passive motion (10 points)

- Dorsiflexion – (1 point for every 5° (maximum 5 points))
- Total varus–valgus motion of the heel (1 point for every 10° (maximum 3 points))
- Total inversion–eversion of foot (1 point per 25° (maximum 2 points))

Gait

- Normal (6 points)
- Can toe walk (2 points)
- Can heel walk (2 points)
- Limp (–2 points)
- No heel strike (–2 points)
- Abnormal toe-off (–2 points)

Physical exam:

- Dorsiflexion ankle
- Heel varus–valgus
- Inversion and eversion of the forefoot
- Heel orthostatism position
- Metatarsal adduction in orthostatic position

Radiological assessment (AP + lateral)

Anteroposterior:

- Talocalcaneal angle – assesses the varus–valgus of the hind-foot

Lateral:

- Talocalcaneal angle

Appendix 2. Tables of patients

sujeito	nome	nascimento	idade iniciot	lado	comorb	n° gesso	data tenot	idade tenot	necessit outproc	satisfação	função	dor	posição do calc	mov pas	marcha	rx ap D	rx ap E	rx perf D	rx perf E	total
1	gsb	15/11/2007	3a10m	bilat	não	8	14/02/2011	4a3m	não	16	20	24	5	2+2+1=5	4	36,9	32,9	21,3	27	69
2	dhsi	17/10/2011	2m	bilat	não	3	15/02/2012	4m	não	16	20	30	5	3+2+2=7	4	32	30	25	22	82
3	hhcl	24/08/2010	3m	dir	não	5	07/02/2011	6m	não	20	20	30	10	3+2+2=7	10	35		30		97
4	jsj	07/08/2007	2m	bilat	não	6	10/01/2008	5m	não	16	20	30	5	3+3+2=8	10	37,5	29,5	23,8	36,5	89
5	ezop	01/10/2008	1m	dir	não	7	15/03/2009	5m	não	20	20	30	10	5+3+2=10	10	33		42		100
6	pbb	20/08/2007	1m	bilat	não	11	03/03/2008	6m	não	20	20	24	5	5+2+2=9	10	23	21	32	30	88
7	dcr	15/04/2007	3m	bilat	não	10	20/01/2008	9m	não	20	20	24	5	3+1+1=5	10	21	25	21	23	84
8	pnb	06/08/2005	1m	esq	não	6	07/01/2006	5m	não	20	20	24	10	4+2+2=8	10		26		23	92
9	ibl	18/12/2005	1m	dir	não	5	29/04/2006	4m	não	20	20	30	10	5+3+2=10	10	32		43		100
10	krm	21/08/2003	1m	bilat	não	9	18/01/2004	4m	não	20	20	24	10	3+2+1=6	10	20	22	20	24	90
11	rho	20/12/2004	1m	dir	não	7	10/05/2005	4m	não	20	20	30	10	5+3+2=10	10		26	20		100
12	mc	11/07/2005	1m	bilat	não	6	05/11/2005	4m	não	20	16	24	5	3+3+2=8	10	21	20	22	24	83
13	mb	13/03/2008	1m	dir	não	5	29/07/2008	4m	não	20	20	30	10	5+3+2=10	10	32		43		100
14	chbs	11/05/2007	1m	esq	não	10	15/12/2007	7m	não	20	20	24	5	3+2+1=6	10		22		25	85
15	hpb	28/06/2006	1m	esq	não	7	03/12/2006	6m	não	20	20	30	10	5+3+2=10	10		32		29	100
16	ff	10/08/2008	1m	bilat	não	9	02/02/2009	4m	não	20	20	30	5	5+2+2=9	10	28	30	38	42	94
17	gfn	13/01/2009	1m	bilat	não	7	11/06/2009	5m	não	20	20	30	10	5+3+2=10	10	22	28	25	30	100
18	lpv	11/05/2005	1a5m	esq	sim	6	15/07/2007	2a2m	não	20	20	30	10	3+2+1=6	8		35,7		18,9	94
19	kns	13/02/2009	2a3m	bilat	não	14	23/04/2012	3a2m	não	20	20	30	10	3+2+1=6	8	30	32	24	28	94
20	bt	07/07/2003	1m	bilat	não	10	07/01/2004	6m	não	20	20	24	10	5+3+2=10	10	23	26	27	30	96
21	wrg	29/07/2007	2m	bilat	não	14	04/05/2007	11m	não	16	20	24	3	0+1+1=2	6	29,1	36,3	14,1	14,5	71
22	acm	05/04/2004	2m	esq	não	10	09/12/2004	8m	não	20	20	30	10	3+3+2=10	10		29,3		15,8	100
23	gfs	23/01/2007	1m	bilat	não	7	24/05/2007	4m	sim	12	16	30	5	3+3+1=7	6	32	17	28	26	76
24	dms	13/09/2006	2m	esq	não	20	12/03/2007	6m	não	16	12	24	5	2+3+2=7	10		32		15	74
25	pcm	13/04/2007	1m	esq	não	13	23/08/2007	4m	não	16	20	30	10	0+3+2=5	6		27		15	87
26	mpp	26/06/2005	2a3m	dir	não	9	12/01/2008	2a7m	não	20	20	24	10	2+3+2=7	8	30,3		20,4		89
																				2334

REFERENCES

- Herring JB. Congenital talipes equinovarus. In: Tachdjian MO, editor. Tachdjian: pediatric orthopaedics. Philadelphia: W.B. Saunders Company; 2001. p. 922-59.
- Wynne-Davies R. Family studies and aetiology of club foot. J Med Genet. 1965;2:227-32.
- Dobbs MB, Gurnett CA. Update on clubfoot: etiology and treatment. Clin Orthop Relat Res. 2009;467(5):1146-53.
- Aronson J, Puskarich CL. Deformity and disability from treated clubfoot. J Pediatr Orthop. 1990;10(1):109-19.
- Ponseti IV. Treatment of congenital clubfoot. J Bone Joint Surg Am. 1992;74(3):448-54.
- Ponseti IV. Congenital clubfoot: fundamentals of treatment. Oxford: Oxford University Press; 1996.
- Ponseti IV, Smoley EN. Congenital clubfoot: the results of treatment. J Bone Joint Surg Am. 1963;45(2):261-344.
- Laaveg SJ, Ponseti IV. Long-term results of treatment of congenital clubfoot. J Bone Joint Surg Am. 1980;62(1):23-31.
- Bor N, Coplan JA, Herzenberb JE. Ponseti treatment of idiopathic clubfoot: minimum 5-year followup. Clin Orthop Relat Res. 2009;467(5):1263-70.
- Ippolito E, Farsetti P, Caterini R, Tudisco C. Long-term comparative results in patients with congenital clubfoot treated with two different protocols. J Bone Joint Surg Am. 2003;85(7):1286-94.
- Dobbs MB, Nunley R, Schoenecker PL. Long term follow-up of patients with clubfeet treated with extensive soft-tissue release. J Bone Joint Surg Am. 2006;88(5):986-96.
- Cooper DM, Dietz FR. Treatment of idiopathic clubfoot. A thirty-year follow-up note. J Bone Joint Surg Am. 1995;77(10):1477-89.
- Hutchins PM, Foster BK, Paterson DC, Cole EA. Long-term results of early surgical release in club feet. J Bone Joint Surg Br. 1985;67(5):791-9.