



## Case report

# Simultaneous bilateral patellar tendon rupture<sup>☆</sup>



Diogo Lino Moura\*, José Pedro Marques, Francisco Manuel Lucas,  
Fernando Pereira Fonseca

Centro Hospitalar e Universitário de Coimbra, Departamento de Ortopedia, Coimbra, Portugal

### ARTICLE INFO

#### Article history:

Received 22 March 2016

Accepted 28 March 2016

Available online 22 June 2016

#### Keywords:

Patellar ligament

Rupture, spontaneous

Tendon injuries

Steroids

Rehabilitation

### ABSTRACT

Bilateral patellar tendon rupture is a rare entity, often associated with systemic diseases and patellar tendinopathy. The authors report a rare case of a 34-year-old man with simultaneous bilateral rupture of the patellar tendon caused by minor trauma. The patient is a retired basketball player with no past complaints of chronic knee pain and a history of steroid use. Surgical management consisted in primary end-to-end tendon repair protected temporarily with cerclage wiring, followed by a short immobilization period and intensive rehabilitation program. Five months after surgery, the patient was able to fully participate in sport activities.

© 2016 Sociedade Brasileira de Ortopedia e Traumatologia. Published by Elsevier Editora Ltda. This is an open access article under the CC BY-NC-ND license (<http://creativecommons.org/licenses/by-nc-nd/4.0/>).

### Rupturas bilaterais simultâneas dos tendões patelares

#### RESUMO

As rupturas bilaterais dos tendões patelares são uma entidade rara, muitas vezes associadas com doenças sistêmicas e tendinopatia patelar. Apresentamos um caso raro de um homem de 34 anos com rotura bilateral simultânea dos tendões patelares causada por trauma leve. O paciente é um jogador de basquetebol aposentado, sem queixas de dor crônica do joelho e com história de consumo de esteroides. O tratamento cirúrgico consistiu na reparação tendinosa primária de ponta a ponta, protegida temporariamente com banda de cerclage, seguida de curto tempo de imobilização e programa intensivo de reabilitação. Aos cinco meses após a cirurgia, o paciente era capaz de participar sem restrições em atividades desportivas.

© 2016 Sociedade Brasileira de Ortopedia e Traumatologia. Publicado por Elsevier Editora Ltda. Este é um artigo Open Access sob uma licença CC BY-NC-ND (<http://creativecommons.org/licenses/by-nc-nd/4.0/>).

#### Palavras-chave:

Ligamento patelar

Ruptura espontânea

Traumatismos dos tendões

Esteroides

Reabilitação

<sup>☆</sup> Work performed at the Orthopedics Department, Coimbra Hospital and University Center, Coimbra, Portugal.

\* Corresponding author.

E-mails: [dflm12345@gmail.com](mailto:dflm12345@gmail.com), [dflmoura@gmail.com](mailto:dflmoura@gmail.com) (D.L. Moura).

<http://dx.doi.org/10.1016/j.rboe.2016.03.006>

2255-4971/© 2016 Sociedade Brasileira de Ortopedia e Traumatologia. Published by Elsevier Editora Ltda. This is an open access article under the CC BY-NC-ND license (<http://creativecommons.org/licenses/by-nc-nd/4.0/>).

## Introduction

Disruption of knee's extensor mechanism is not unusual and affects the patella bone more frequently.<sup>1,2</sup> Bilateral simultaneous ruptures of the patellar tendons are rarely seen and have only been documented in case reports.<sup>1,3,4</sup>

## Case presentation

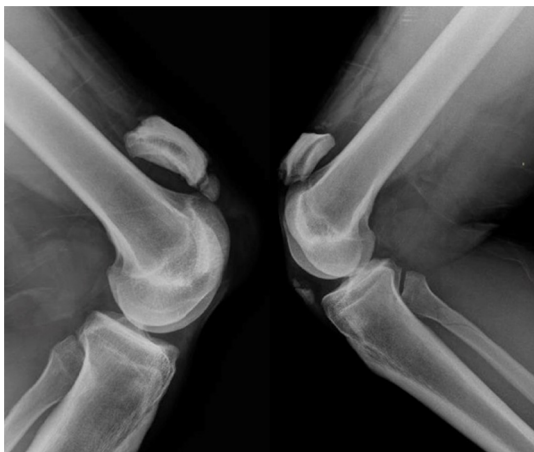We present a 34-year-old black male that after a sudden running stop with both knees in slight flexion associated with a twisting movement, he experienced failure sensation and a severe sharp pain in both knees. He fell to the ground and was unable to stand and walk.

At the emergency orthopedic department the patient referred bilateral knee pain and tenderness. Both knees displayed some superficial abrasions and a mild effusion. A bilateral infrapatellar gap with cephalic migration of both patellae could be felt. Active straight leg raising test was negative for both extremities and the patient was unable to perform active extension of both knees. Neurovascular examination was unremarkable.

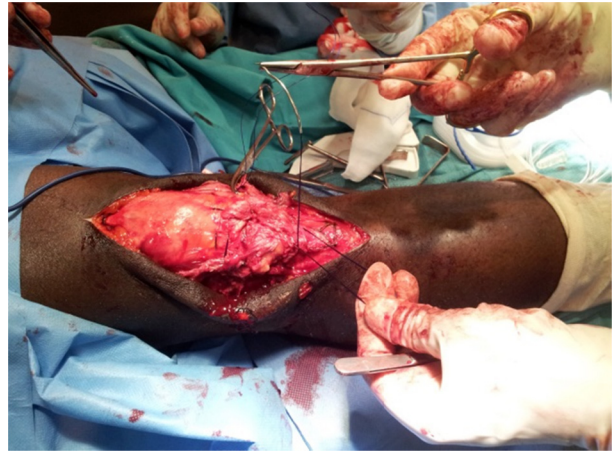The presumptive clinical diagnosis of bilateral rupture of the patellar tendon was made.

The patient had been a professional basketball player from 18 to 25 years old and practiced competitive weightlifting until 30 years old. He admitted having taken a few cycles of oral and injectable steroids during the weightlifting competitive practice time. Currently, he is a bouncer and a recreational weightlifting practitioner. The patient assured not having taken steroids or any other supplements for the last three years. He reported no previous injuries to his knees and denied chronic knee pain. At the time of the trauma, the patient body type was athletic, weighing 120 kg and was 192 cm tall.

The X-rays showed cephalic patellar migration and small calcification avulsions of the inferior poles of both patellae. An isolated undisplaced spiral fracture of the left fibular

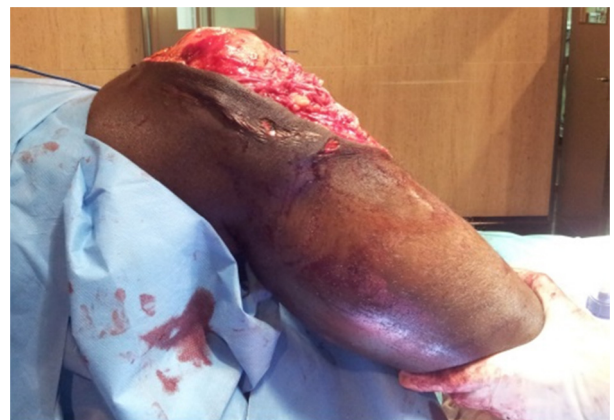

**Fig. 1 – Lateral projection knee radiographs after bilateral patellar tendon rupture, showing cephalic patellar migration (“patella alta”), avulsion fractures of inferior poles of both patellae and an isolated undisplaced spiral fracture of the left fibular neck (left side).**

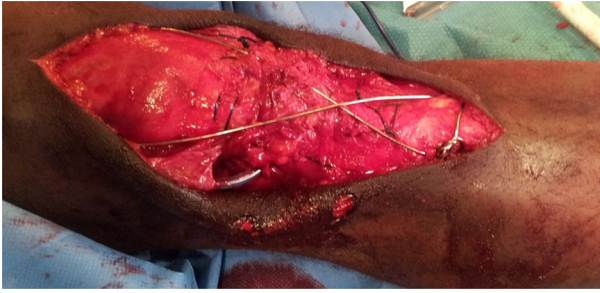


**Fig. 2 – Bilateral patella tendon rupture at surgery: monofilament loop suture that allowed, by its passage in the middle of the loop, a proper tendon suture tension.**

neck was also identified (Fig. 1). Ultrasound confirmed total bilateral rupture of the patellar tendons. Intraoperatively we found both tendons torn in their substance near the inferior patellar poles, with some segments avulsed from the patellar insertion. Lateral and medial retinacula were disrupted bilaterally. An end-to-end primary Kessler-type tendon repair reinforced with intraosseous sutures was performed in both knees. We temporarily protected it with cerclage wiring, followed by immobilization with a leg cylinder cast. We chose a nonabsorbable monofilament loop suture that allowed a proper tendon suture tension, by its second passage through the middle of the loop (Fig. 2). The tension within stitches was carefully adjusted to avoid shortening of infrapatellar length, according to the patellae position. The ruptured retinacula were repaired with Vicryl sutures. The strength of the repair was tested by careful flexion of both knees (Fig. 3). Cerclage wiring was applied in a figure-of-eight tension band running around the superior pole of the patellae, passing in front of the tendon, fixed with a transverse screw through the tibia tubercle and tied at average 60° of knee flexion (Fig. 4).



**Fig. 3 – Flexion knee movement testing the sewing integrity and resistance.**



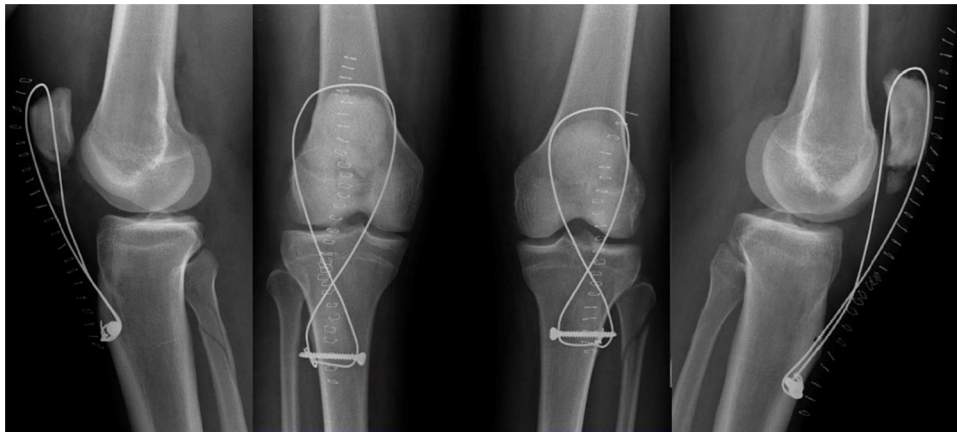
**Fig. 4 – Cerclage wiring application in eight form tension band between the distal quadriceps tendon and a transversal screw in the anterior tibial tuberosity.**

The postoperative course was uneventful and radiographic control was satisfactory (Fig. 5). The cast immobilization was removed at the third postoperative day and the patient began ambulation with crutches using extension knee braces and full weight-bearing allowed as tolerated. At the 2nd postoperative week he began periodic removal of knee braces and a daily rehabilitation program, initially consisting in isometric muscle strengthening and knee flexion exercises restricted to 60°, complemented with peripatellar soft tissue massage. At the 4th week the patient could walk without crutches, had no pain and attained 40° of maximum bilateral active knee flexion. At the 6th week he had 60° of flexion and the knee braces were discontinued. At the 8th postoperative week, the cerclage wire was removed and the patient continued the daily

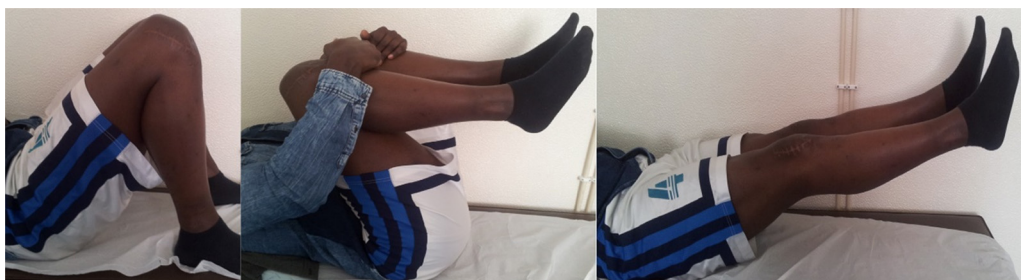physiotherapy program with progression to full knee flexion allowed and emphasis on muscle strengthening exercises. Stationary bicycle was introduced at the 9th week. Eleven weeks after surgery, the patient presented 100° maximum bilateral knee flexion and returned to work. On examination 5 months after surgery, the patient presented a satisfactory range of motion of both knees (135° flexion, 0° extension) good quadriceps strength and no signs of muscular atrophies or extensor lag (fig. 6). He denied any sense of instability or swelling, and therefore he returned to recreational sportive activities. He reported feeling that his knees were as strong as they were prior to the lesions and he was able to run, squat, and hop in place without difficulty.

## Discussion

Patellar tendon ruptures are mostly associated with unhealthy patellar tendons.<sup>1</sup> This patient had anabolic steroid consumption history, which could be held accountable for degenerative changes that weaken the structural tendon integrity with a higher risk for rupture, even in the context of minor trauma.<sup>1,2,4-8</sup> In addition, the patient's heavy body weight and the previous participation in high-level competitive sport activities might have inflicted chronic degenerative changes to his patellar tendons, as we can suppose because of the inferior patella pole calcifications, despite his denial for any chronic knee pain or discomfort compatible with patellar tendinopathy.<sup>9</sup>



**Fig. 5 – Two weeks after surgery: radiographic control.**



**Fig. 6 – Five months after surgery: 135° flexion, 0° extension at both knees.**

Primary tendon repair should be performed as soon as possible to avoid proximal patellar retraction, scarring, complicated repair and diminished long-term function.<sup>1,6</sup> Local repair secured by a tension band wire technique to counteract the forces generated across the extensor mechanism, diminishing tension at the repair sites and permitting an uneventful healing. Although the use of cerclage wiring in bilateral patellar tendon ruptures is still controversial, we believe this allowed all the benefits of a minimal cast immobilization and an early controlled physiotherapy beginning two weeks postoperatively, which was important to avoid quadriceps atrophy. The rehabilitation program prescribed allowed fast amplitude gaining and an earlier return to work and sport activities when compared with reports in the literature.<sup>1,6,9,10</sup>

In conclusion, we present a bilateral patellar tendon rupture case likely associated with anabolic steroids intake and repetitive local stress. The bilateral injury nature can make rehabilitation difficult. We believe the main reasons for the excellent and early functional results were: early tendon repair and proper suture tension and strength; cerclage wire use; minimal cast immobilization time; intensive, controlled and specialized physiotherapy program and a strongly committed patient.

---

### Conflict of interests

The authors declare no conflict of interests.

### REFERENCES

---

1. Kellersmann R, Blattert TR, Weckbach A. Bilateral patellar tendon rupture without predisposing systemic disease or steroid use: a case report and review of the literature. *Arch Orthop Trauma Surg.* 2005;125:127-33.
2. Enad JG. Patellar tendon ruptures. *South Med J.* 1999;92:563-6.
3. Splain SH, Ferenz C. Bilateral simultaneous infrapatellar tendon rupture: support for Davidsson's theory. *Orthop Rev.* 1988;17:802-5.
4. Stinner DJ, Orr JD, Hsu JR. Fluoroquinolone-associated bilateral patellar tendon rupture: a case report and review of the literature. *Mil Med.* 2010;175:457-9.
5. Carson WG Jr. Diagnosis of extensor mechanism disorders. *Clin Sports Med.* 1985;4:231-46.
6. Rose PS, Frassica FJ. Atraumatic bilateral patellar tendon rupture. A case report and review of the literature. *J Bone Joint Surg Am.* 2001;83:1382-6.
7. Van Glabbeek F, De Groof E, Boghemans J. Bilateral patellar tendon rupture: case report and literature review. *J Trauma.* 1992;33:790-2.
8. Kannus P, Józsa L. Histopathological changes preceding spontaneous rupture of a tendon. A controlled study of 891 patients. *J Bone Joint Surg Am.* 1991;73:1507-25.
9. Rosenberg JM, Whitaker JH. Bilateral infrapatellar tendon rupture in a patient with jumper's knee. *Am J Sports Med.* 1991;19:94-5.
10. Muller ME, Allgower M. *Manual of internal fixation: techniques recommended by the AO-ASIF.* Berlin: Springer-Verlag; 1970.