



Original Article

Acetabular revision in total hip arthroplasty with tantalum augmentation and lyophilized bovine xenograft[☆]



Cristiano Valter Diesel^a, Tiango Aguiar Ribeiro^b, Marcelo Reuwsaat Guimarães^a, Carlos Alberto de Souza Macedo^c, Carlos Roberto Galia^{a,c,*}

^a Universidade Federal do Rio Grande do Sul (UFRGS), Programa de Pós-Graduação em Medicina Ciências Cirúrgicas, Porto Alegre, RS, Brazil

^b Universidade Federal de Santa Maria (UFSM), Departamento de Cirurgia, Serviço de Ortopedia e Traumatologia do Hospital Universitário de Santa Maria (SOT-HUSM), Santa Maria, RS, Brazil

^c Universidade Federal do Rio Grande do Sul (UFRGS), Faculdade de Medicina (FAMED), Hospital de Clínicas de Porto Alegre (HCPA), Porto Alegre, RS, Brazil

ARTICLE INFO

Article history:

Received 9 December 2016

Accepted 26 January 2017

Available online 23 August 2017

Keywords:

Hip arthroplasty

Bone transplantation

Surgical instruments

Acetabulum

Trabecular metal

Tantalum

ABSTRACT

Objective: To evaluate a mixed technique of acetabular reconstruction, which uses trabecular metal in the form of tantalum augments associated with lyophilized bovine xenograft.

Methods: Fifteen patients were evaluated prospectively, who underwent acetabular reconstruction with impacted lyophilized bovine xenograft associated with the use of tantalum augments. The main outcome was the failure of the tantalum–bone interface.

Results: The population had a mean age of 58.33 years \pm 14.27; the majority was female, 80%. Of the total subjects, 66.7% were operated for failure in primary arthroplasty. The mean follow-up time was 45.2 months \pm 11.39. The failure rate of the method in the period and population studied was 6.7%.

Conclusion: An extremely high index (93.3%) of success was observed in an average time of 45.2 months of follow-up. Data were comparable to current literature, demonstrating that the technique employed and proposed is adequate for hip reconstruction in young patients.

© 2017 Sociedade Brasileira de Ortopedia e Traumatologia. Published by Elsevier Editora Ltda. This is an open access article under the CC BY-NC-ND license (<http://creativecommons.org/licenses/by-nc-nd/4.0/>).

[☆] Study conducted at Hospital de Clínicas de Porto Alegre (HCPA), Porto Alegre, RS, Brazil.

* Corresponding author.

E-mail: cgalia@hcpa.edu.br (C.R. Galia).

<http://dx.doi.org/10.1016/j.rboe.2017.08.009>

2255-4971/© 2017 Sociedade Brasileira de Ortopedia e Traumatologia. Published by Elsevier Editora Ltda. This is an open access article under the CC BY-NC-ND license (<http://creativecommons.org/licenses/by-nc-nd/4.0/>).

Revisão acetabular em artroplastia total de quadril com cunhas de tântalo associadas a enxerto ósseo bovino liofilizado

R E S U M O

Palavras-chave:

Artroplastia de quadril
Transplante ósseo
Instrumentos cirúrgicos
Acetábulo
Metal trabecular
Tântalo

Objetivo: Avaliar uma técnica mista de reconstrução acetabular que usa metal trabecular na forma de cunhas de tântalo associadas com enxerto ósseo bovino liofilizado.

Métodos: Foram avaliados prospectivamente 15 pacientes submetidos à reconstrução acetabular com enxerto bovino liofilizado impactado associado ao uso de cunhas de tântalo. O principal desfecho avaliado foi a falha da interface tântalo-osso.

Resultados: A população apresentou idade média de 58,33 anos \pm 14,27, a maioria do sexo feminino 80%. Do total, 66,7% foram operados por falha da artroplastia primária. O tempo médio de seguimento foi de 45,2 meses \pm 11,39 meses. A taxa de falha do método no período e na população estudada foi de 6,7%.

Conclusão: Observou-se um índice extremamente elevado (93,3%) de sucesso em um tempo médio de 45,2 meses de seguimento. Os dados são comparáveis à literatura corrente, o que demonstra que a técnica empregada e proposta é adequada para reconstrução de quadril em pacientes jovens.

© 2017 Sociedade Brasileira de Ortopedia e Traumatologia. Publicado por Elsevier Editora Ltda. Este é um artigo Open Access sob uma licença CC BY-NC-ND (<http://creativecommons.org/licenses/by-nc-nd/4.0/>).

Introduction

With the increasing number of hip arthroplasties performed worldwide, a likely proportional increase in the number of arthroplasty revisions is expected.¹ The term revision suggests the simple inspection or discrete adjustment of arthroplasty, and underestimates the actual scope of these procedures. Most of these cases present severe bone defects, which require large reconstructions of the bone structure about the hip, especially the acetabulum.

Several techniques can be used for acetabular reconstruction. Among the most common techniques is the use of Jumbo cups,² reconstructions that use structural homologous graft (allograft)³ or impacted morselized homologous graft, with or without graft protection devices such as on the renowned technique described by Slooff et al.⁴ The use of autograft, although biologically considered ideal, is not possible in most cases due to its insufficient amount and the need for another procedure, which is not risk free.

Other bone substitute alternatives are grafts derived from species other than human (xenograft); those of bovine origin are the most routinely used.⁵ To avoid immunological reactions in the recipient area, animal bone grafts are prepared in various ways in order to eliminate or minimize their antigenicity. One such manner is lyophilization, the process in which the bone is degreased, decellularized, and ultimately sterilized. Regardless of the several manufacturing protocols, the final product should maintain its potential for osseointegration and osteoinduction, as well as being physicochemically similar to human bone.^{6,7}

In the past ten years, the use of trabecular metal has gained ground in hip reconstructions. These metal structures are produced using cutting-edge technology and made of titanium or tantalum; they seek to imitate the bone microstructure, with porosities between 400 and 600 microns, which theoretically facilitates their integration into the host bone.^{8,9}

Reconstructions using large grafts, whether autologous, homologous, or xenologous are those with the highest number of failures.¹⁰ Moreover, the type of acetabular defect also influences the success of the reconstruction. Defects considered as contained, i.e. those in which the acetabular structure (walls, roof, and floor) is preserved, are more likely to have good performance when compared with severe segmental defects (loss of walls and especially loss of acetabular roof)¹¹ or those with pelvic discontinuity.¹²

The authors believe that, whenever possible, bone should be replaced by bone, especially in young individuals. Despite this reconstruction philosophy, failures are observed, particularly in severe defects, especially those involving the loss of the acetabular roof¹¹ and when combined with the need for a large amount of graft. Thus, encouraged by the study by Gerhke et al.,¹³ the authors decided to study a technique that combines the use of trabecular metal in the area of higher shearing force (acetabular roof), associated with the use of graft, replacing the filling of the remaining defects with lyophilized bovine (instead of human) bone graft.

Material and methods

This was a prospective cohort study conducted from September 2011 to November 2016. The project was approved by the Research Ethics Committee of the institution and registered under number 15.0248; the ethical precepts of the Declaration of Helsinki of 1975 were followed.

The study included patients with acetabular roof defect in whom large grafts were expected to be necessary for reconstruction. Patients who had one or more failures in previous acetabular reconstructions were also included.

All patients were operated by the same surgeon and medical team. Only the posterolateral approach was used, followed by removal of the previous acetabulum and inspection of the cavity. The defect was classified preoperatively, in accordance

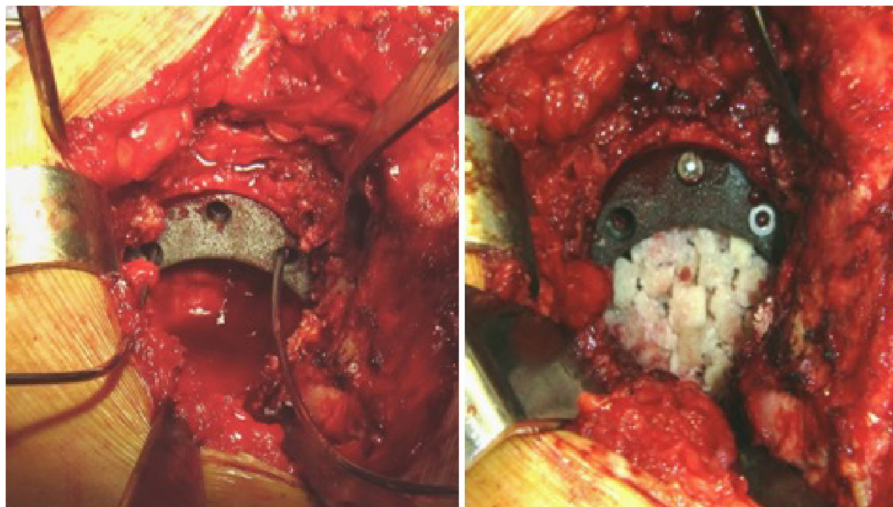


Fig. 1 – On the left, provisional positioning of the tantalum augment with Kirschner wires. On the right, positioning and definitive fixation of the wedge, followed by cavity filling with lyophilized bovine bone graft.

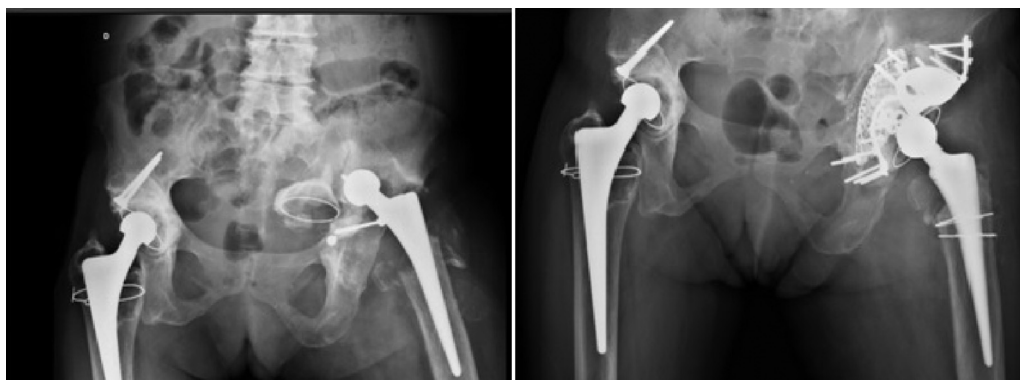

Fig. 2 – Pre- and postoperative radiography of an arthroplasty reconstruction in a patient with acetabular defect classified as d’Antonio type III. Reconstruction plate, tantalum wedge, lyophilized bovine bone graft, and acetabular floor mesh were used.

to d’Antonio *apud* van Haaren et al.,¹⁰ based on radiographic images; patients were reclassified intraoperatively when necessary.

After this stage, the acetabular reconstruction was initiated from the roof; the tantalum wedge (Zimmer Biomet Holding, Inc.) was chosen according to the component test piece. The wedge was fixed with two or three screws, in the most stable position. Then, lyophilized bovine bone graft (Orthogen-Baumer) was morselized and impacted with the use of impactors or with reverse position reaming. Depending on the severity of the acetabular defect, other devices were added, such as an acetabular reinforcement ring, pelvic reconstruction plates, or acetabular meshes. Subsequently, the acetabular component ZCA (Zimmer Biomet Holding, Inc.) or Delta (Baumer) was cemented (Cement Simplex – Howmedica) in accordance to the standard technique (Figs. 1 and 2).

The same antimicrobial prophylaxis (cefazolin, weight-adjusted dose) and the same prophylaxis for thromboembolic events (enoxaparin) was adopted for all patients. At least six culture samples were collected in all cases. In cases of suspected septic loosening, the protocol of choice was

one-stage revision; broad-spectrum intravenous antibiotics (vancomycin and cefepime) were used after collection of intraoperative culture material. These antibiotics were maintained for approximately 15 days, until the culture results described the microbial profile. Then, the antibiotics were withdrawn by the infectology team of this hospital.

Data regarding gender, age, and previous surgeries were analyzed. Acetabular defects were classified preoperatively and intraoperatively by the d’Antonio classification (AAOS).¹⁰ Radiographically, the following aspects were used to define the presence of loosening of the acetabular component and of the wedge in the post-operative period: presence of radiolucent lines (*apud* De Lee and Charnley) and displacement of the wedge or acetabular component.

Statistical analysis

Data were analyzed in SPSS 21.0. Quantitative variables were described as mean and standard deviation. Qualitative variables were presented as absolute and relative frequencies. To

compare the means of normal quantitative variables between genders, the ANOVA test was used; to verify the homogeneity between the groups, the Levine test was used. A level of significance of 5% ($p \leq 0.05$) was adopted.

Results

Fifteen patients underwent the described surgical technique. The mean age was 58.33 ± 14.27 years (mean \pm standard deviation), ranging from 39 to 81. Most patients were female (12; 80%). No differences were observed between genders ($p = 0.96$), and the groups were considered homogeneous ($p = 0.04$).

Of this total, 66.7% (ten) of the patients were operated for primary arthroplasty failure; 26.7% (four) had previously undergone one or more hip reconstructions, and one had undergone the Girdlestone surgery.

As for the classification of the AAOS, type III (mixed) defect was the most prevalent, being identified in 86.7% (13) patients. Pelvic discontinuity (type IV defect) was detected in only 13.3% (two) of the patients. Six reconstructions required association with other orthopedic devices, such as acetabular floor meshes, reinforcement rings, or acetabulum reconstruction plates. Other sample characteristics are described in Table 1.

Follow-up of one patient from the initial sample was terminated due to death caused by complications of a liver transplantation that occurred two years after hip surgery. Until the last follow-up visit, this patient's reconstruction was intact, without failure.

The mean follow-up was 45.2 ± 11.39 months (mean \pm standard deviation), ranging from 14 to 63.

Discussion

A 6.7% failure rate (one case) was observed; therefore, the success rate was high, corresponding to 93.3% in a mean follow-up of 45.2 months.

Total hip arthroplasty was considered the surgery of the century.¹⁴ Due to its success in relieving pain in patients with hip osteoarthritis, it has become accepted and disseminated worldwide. As a direct consequence of the increase in the number of arthroplasties, an increase in the rate of revisions (reconstructions) due to loosening was observed.¹ This increase is usually accompanied by a higher severity of bone defects – especially acetabular – and more particularly in institutionalized patients.

Over the years, several reconstruction techniques have been proposed. Cases in which bone defects were filled only with orthopedic cement were evaluated. Cases of successful implantation of jumbo cups were followed-up, as well as the results of the reconstructions using structural homograft. The authors have subscribed to the school of acetabular reconstruction with impacted morselized graft developed by Slooff et al.⁴ and adopted by the school of Exeter.

Our success rate was similar to results reported in the literature with the technique of impacted graft. Also according to the literature, it was observed that large grafts were more prone to failures, especially when associated to major defects of the acetabular roof or pelvic discontinuity.^{11,12}

In the last ten years, metal implants with similar-to-bone microstructure have been developed, manufactured, and commercialized with a high success rate in hip reconstructions.^{9,15,16} Although bone substitution with trabecular metal appears to be a promising option, it does not reconstruct the bone stock a patient who is sometimes young and may require a new hip replacement. This fact encouraged the authors to continue to search for options that would increase success rates and promote the reconstruction of part of the bone stock.

Given the need for and the unavailability of adequate amounts of homologous graft, for 20 years the authors have been developing research projects for the production of lyophilized bovine bone graft. The result was a final product with physicochemical characteristics similar to those of human bone,^{6,7} presenting a biological potential and being easy to obtain.¹⁷ After over 16 years of following-up patients who received this graft, its use has become commonplace in the institution.¹⁸

Few articles in the literature have assessed the technical combination of augmentation wedges and bone graft. Gehrke et al.¹³ used wedges associated with homologous bone graft in 46 cases. They observed a good evolution in 44 of these patients, in a mean follow-up of 46 months.

Visually, when the tantalum acetabulum is compared with tantalum wedges, there is clearly a smaller contact surface between the implant and the host bone. This factor has raised concern about its osseointegration capacity, as well as its stability. In cases with lateral coverage deficiency, the tantalum wedge could undergo a great shear force, similar to the graft.¹¹ In these cases, or in those with medial wall loss, protection devices were used in addition to the bone graft, such as Kerboul acetabular reinforcement, reconstruction plates, and/or acetabular reconstruction meshes.

In cases where the acetabulum adopts an oblong morphology, there is usually a need for reconstruction of the roof and lowering of the joint's center of rotation. In such cases, although the literature suggests the use of jumbo cups in trabecular metal, with or without augmentation wedges, the authors believe that a more biological reconstruction is possible, especially seeking the restitution of bone stock in young patients, in whom future reconstructions may be necessary.

The present results, albeit with a small sample, are similar to those of Gehrke et al.,¹³ even regarding the mean follow-up time. To date, only one isolated release of the acetabular component that required further surgery has been observed in this sample. In that case, however, the tantalum wedge remained fixated at its original site. The authors believe that this event occurred due to technical failure caused by insufficient coverage of the acetabular component.

In six reconstructions, other orthopedic devices were also used, such as reconstruction plates, Kerboul acetabular reinforcement rings, or acetabular reconstruction plates. Two of these reconstructions were in pelvic discontinuities. The goal of these combinations was to reconstruct the acetabular floor or to assist wedge fixation, especially when screw fixation was not considered adequate.

One patient, who had undergone two previous reconstructive surgeries, presented early (within the first year) wedge

Table 1 – Sample characteristics.

Patient	Age	Gender	Side	Prior surgery	Classification of the acetabular defect	Surgery date	Wedge size	Acetabular size	Use of other devices	Presence of radiolucency at follow-up	Presence of migration at follow-up
MZFS	81	F	R	THA	III	May 7, 2012	58 × 20	47 × 28		No	No
AL	54	F	R	THA	III	April 19, 2012	54 × 10	43 × 22		No	No
JEC	54	M	L	THA	III	October 3, 2012	58 × 10	53 × 32		No	No
OPB	80	F	R	THA	III	March 21, 2013	54 × 15	55 × 28		No	No
FA	54	F	R	THA	III	February 27, 2013	50 × 10	51 × 28		No	No
NJOA	76	F	R	THA	III	April 1, 2013	58 × 10	49 × 28	Reconstruction plate	No	No
LSC	77	F	L	THA	III	September 28, 2014	62 × 10	49 × 32		No	No
JACCT	63	M	R	THA	IV	March 18, 2013	54 × 20	47 × 28	Reconstruction cage	No	No
OCF	57	M	R	RTHA (3)	III	September 5, 2011	66 × 20	47 × 28		No	No
DW	39	F	R	RTHA	III	October 29, 2012	54 × 15	51 × 28	Reconstruction plate	No	No
LMC	41	F	L	RTHA (2)	III	June 2, 2014	54 × 10	51 × 28	Reconstruction mesh	Yes	Yes
GMSP	53	F	L	Girdlestone	III	October 8, 2012	58 × 20	51 × 28	Reconstruction mesh	No	No
ATVP	40	F	L	RTHA	IV	November 26, 2012	58 × 20	55 × 28	Reconstruction plate + mesh	No	No
IS	57	F	R	THA	III	December 18, 2012	50 × 15	46 × 28		No	No
EMS	49	F	L	THA	III	July 20, 2013	54 × 14	46 × 28		No	No

THA, total hip arthroplasty; R, right; L, left; F, female; M, male; RTHA, revision total hip arthroplasty.

loosening and reconstruction failure. No other patient underwent further surgery exclusively due to augmentation wedge failure. Moreover, no cases of acute infection or cases with intermediate infection signs were observed in any patient operated with this technique.

The preliminary results are encouraging. A high success rate was observed in a mean follow-up time that is comparable to the current literature. Nonetheless, these results are still early and require a greater sample size. However, reconstruction using tantalum augment associated with bone graft (xenologous or homologous) appears to be a promising option for young patients with associated partial loss of the acetabular roof.

Conflicts of interest

The authors declare no conflicts of interest.

REFERENCES

- Dixon T, Shaw M, Ebrahim S, Dieppe P. Trends in hip and knee joint replacement: socioeconomic inequalities and projections of need. *Ann Rheum Dis.* 2004;63(7):825-30.
- Von Roth P, Abdel MP, Harmsen WS, Berry DJ. Uncemented jumbo cups for revision total hip arthroplasty: a concise follow-up, at a mean of twenty years, of a previous report. *J Bone Joint Surg Am.* 2015;97(4):284-7.
- Garbuz D, Morsi E, Gross AE. Revision of the acetabular component of a total hip arthroplasty with a massive structural allograft study with a minimum five-year follow-up. *J Bone Joint Surg Am.* 1996;78(5):693-7.
- Slooff TJ, Schimmel JW, Buma P. Cemented fixation with bone grafts. *Orthop Clin North Am.* 1993;24(4):667-77.
- Levai JP, Boisgard S. Acetabular reconstruction in total hip revision using a bone graft substitute. Early clinical and radiographic results. *Clin Orthop Relat Res.* 1996;(330):108-14.
- Galia CR, Lourenço AL, Rosito R, Souza Macedo CA, Camargo LM. Physicochemical characterization of lyophilized bovine bone grafts. *Rev Bras Ortop.* 2015;46(4):444-51.
- Galia CR, Macedo CA, Rosito R, Mello TM, Camargo LM, Moreira LF. In vitro and in vivo evaluation of lyophilized bovine bone biocompatibility. *Clinics (São Paulo).* 2008;63(6):801-6.
- Issack PS. Use of porous tantalum for acetabular reconstruction in revision hip arthroplasty. *J Bone Joint Surg Am.* 2013;95(21):1981-7.
- Flecher X, Appy B, Parratte S, Ollivier M, Argenson JN. Use of porous tantalum components in Paprosky two and three acetabular revision. A minimum five-year follow-up of fifty one hips. *Int Orthop.* 2017;41(5):911-6.
- Van Haaren EH, Heyligers IC, Alexander FG, Wuisman PI. High rate of failure of impaction grafting in large acetabular defects. *J Bone Joint Surg Br.* 2007;89(3):296-300.
- García-Rey E, Madero R, García-Cimbrelo E. THA revisions using impaction allografting with mesh is durable for medial but not lateral acetabular defects. *Clin Orthop Relat Res.* 2015;473(12):3882-91.
- García-Cimbrelo E, García-Rey E. Bone defect determines acetabular revision surgery. *Hip Int.* 2014;24 Suppl. 10:S33-6.
- Gehrke T, Bangert Y, Schwantes B, Gebauer M, Kendoff D. Acetabular revision in THA using tantalum augments combined with impaction bone grafting. *Hip Int.* 2013;23(4):359-65.
- Learmonth ID, Young C, Rorabeck C. The operation of the century: total hip replacement. *Lancet.* 2007;370(9597):1508-19.
- Del Gaizo DJ, Kancharla V, Sporer SM, Paprosky WG. Tantalum augments for Paprosky IIIA defects remain stable at midterm followup. *Clin Orthop Relat Res.* 2012;470(2):395-401.
- Flecher X, Paprosky W, Grillo JC, Aubaniac JM, Argenson JN. Do tantalum components provide adequate primary fixation in all acetabular revisions? *Orthop Traumatol Surg Res.* 2010;96(3):235-41.
- Ribeiro TA, Coussirat C, Pagnussato F, Diesel CV, Macedo FC, Macedo CA, et al. Lyophilized xenograft: a case series of histological analysis of biopsies. *Cell Tissue Bank.* 2015;16(2):227-33.
- Rosito R, Galia CR, Macedo CA, Quaresma LM, Moreira LF. Mid-term follow-up of acetabular reconstruction using bovine freeze-dried bone graft and reinforcement device. *Rev Col Bras Cir.* 2009;36(3):230-5.