



Original article

Rotator cuff arthropathy: what functional results can be expected from reverse arthroplasty?☆



Rodrigo Caldonazzo Fávaro, Michel Abdulahad*, Salim Mussi Filho, Rafael Valério, Mauro José Superti

Hospital Universitário Cajuru, Curitiba, PR, Brazil

ARTICLE INFO

Article history:

Received 17 September 2014

Accepted 10 November 2014

Available online 20 August 2015

Keywords:

Rotator cuff

Arthroplasty

Shoulder

Evaluation of results

ABSTRACT

Objective: To evaluate the functional results from reverse arthroplasty and its complications and relationships with types of injury.

Methods: Twenty-seven shoulders (26 women and one man) were treated. The patients were assessed using the UCLA functional scale. The implant used was the Delta Xtend DePuy® model. The injuries were classified using the Seebauer method for the degree of arthroplasty and the Nerot method for notching.

Result: The mean age was 77.4 years (range: 67–89) and the follow-up was 25.8 months (range: 6–51). The preoperative UCLA score was 10.1 (range: 6–15) and the postoperative UCLA score was 29.8 (range: 22–35), which was a statistically significant improvement ($p < 0.001$). According to the Seebauer classification, five patients were 1B, 19 were 2A and three were 2B. Fifteen cases presented complications (55.5%) and notching was the commonest of these, occurring in 14 patients (nine with grade 1 and five with grade 2), but this did not cause instability in any of them. Only one patient (3.7%) had a major complication, consisting of dislocation in the immediate postoperative period. Two patients (7.4%) said that they would undergo the procedure again. One patient (3.7%) underwent a revision procedure.

Conclusion: Reverse arthroplasty was shown to be an excellent option for treating patients with rotator cuff arthropathy, with a low rate of major complications. Notching was a frequent complication, but in the majority of the cases, it did not present clinical repercussions.

© 2015 Sociedade Brasileira de Ortopedia e Traumatologia. Published by Elsevier Editora Ltda. All rights reserved.

Artropatia de manguito: o que esperar do resultado funcional da artroplastia reversa?

RESUMO

Objetivo: Avaliar o resultado funcional da artroplastia reversa, suas complicações e relações com os tipos de lesões.

Palavras-chave:

Bainha rotadora

☆ Work performed by the Shoulder and Elbow Group, Orthopedics and Traumatology, Hospital Universitário Cajuru, Curitiba, PR, Brazil.

* Corresponding author.

E-mail: michelabduhad@yahoo.com (M. Abdulahad).

<http://dx.doi.org/10.1016/j.rboe.2015.08.005>

2255-4971/© 2015 Sociedade Brasileira de Ortopedia e Traumatologia. Published by Elsevier Editora Ltda. All rights reserved.

Artroplastia
Ombro
Avaliação de resultados

Métodos: Foram tratados 27 ombros, de 26 mulheres e um homem. Os pacientes foram avaliados pela escala funcional de UCLA. O modelo de implantes usado foi o Delta Xtend Depuy®. As lesões foram classificadas segundo Seebauer para o grau de artropatia e Nerot para o *notching*.

Resultado: A idade média foi de 77,4 (67-89), o seguimento foi de 25,8 meses (6-51), o UCLA pré era de 10,1 (6-15) e o UCLA pós foi de 29,8 (22-35), com uma melhoria estatisticamente significativa ($p < 0,001$). Pela classificação de Seebauer, cinco eram 1B, 19 eram 2A e três eram 2B. Tivemos 15 complicações (55,5%), o *notching* foi o mais comum e ocorreu em 14 pacientes, nove deles grau I e cinco grau II, mas nenhum deles gerou instabilidade. Apenas uma paciente (3,7%) teve complicação maior, com luxação no pós-operatório imediato. Dois pacientes (7,4%) alegaram que não repetiriam o procedimento. Uma paciente (3,7%) foi submetida a revisão.

Conclusão: A artroplastia reversa mostrou-se uma excelente opção para o tratamento de pacientes com artropatia do manguito rotador com baixo índice de complicações maiores. O *notching* é uma complicação frequente, mas que na maioria dos casos não apresenta repercussão clínica

© 2015 Sociedade Brasileira de Ortopedia e Traumatologia. Publicado por Elsevier Editora Ltda. Todos os direitos reservados.

Introduction

The first cases of glenohumeral arthrosis resulting from rotator cuff injuries were described by Adams and Smith, in 1850, *apud* Feeley et al.,¹ but it was Neer et al.,² in 1983, who used the term "arthropathy of the rotator cuff" for the first time to describe a combination of massive rotator cuff injury together with upward migration and femoralization of the femoral head and erosion of the acromion with possible acetabularization.

Regarding etiology, Garancis et al.³ proposed the name "Milwaukee shoulder" for this pathological condition and suggested that it might be caused through accumulation of hydroxyapatite crystals inside the joint, which would then be phagocytized by synovial cells, thereby releasing proteolytic enzymes and leading to joint destruction. Neer et al.² put forward the hypothesis that mechanical and nutritional alterations would interact in the etiology of the disease. Mechanically, the presence of massive injury to the rotator cuff would cause an imbalance in the pairs of forces and would result in upward migration of the head and erosion of the acromion. The uncovering of the head would lead to unsealing of the joint with loss of negative pressure and extravasation of the synovial fluid to the soft tissues. The quality of the remaining fluid would diminish and this would lead to degeneration of the joint cartilage and osteopenia through disuse.²

This disease affects women more often, and particularly between the sixth and seventh decades of life. The dominant limb is more commonly affected and bilaterality occurs in 10-25% of the cases. The natural evolution leads to progressive chronic pain and limitation of activities. In physical evaluations, supraspinatus tests are positive. The subscapularis can be evaluated through the Gerber or lift-off test, and patients may present pseudoparalysis and test positively for the Hornblower sign. Nighttime pain and loss of range of motion are common, especially with regard to elevation and external rotation. Recurrent anterior edema (geyser sign or fluid sign)

resulting from increased fluid pressure on the subacromial bursa may also be observed.^{1,4}

The forms of treatment range from conservative treatment,^{5,6} which is always indicated initially, to arthroscopic debridement,⁷⁻⁹ hemiarthroplasty,¹⁰⁻¹² reverse arthroplasty¹³⁻¹⁵ and salvage procedures such as arthrodesis^{16,17} and resection arthroplasty.¹⁸ Currently, anatomical total arthroplasty is proscribed for treating this pathological condition because of the low success rate, high rate of loosening, high attrition and instability generated through the phenomenon known as rocking horse.¹⁹

Recently, the popularity of reverse arthroplasty has increased. The concept of the current models is based on the principles of Grammont, with medialization and inferiorization of the center of rotation, which boosts the action of the deltoid.^{13,20}

The objective of the present study was to evaluate the functional result from reverse arthroplasty for treating arthropathy of the rotator cuff, the complications from this procedure and relationships with types of injury.

Materials and methods

Between January 2010 and November 2013, the Shoulder and Elbow Group of the Department of Orthopedics and Traumatology of our institution conducted a retrospective epidemiological study that involved reviewing the medical files.

This study was approved by the Ethics Committee of the institution at which it was conducted.

The inclusion criteria were: (1) arthroplasty of the rotator cuff already established; (2) imaging examinations that demonstrated massive tearing of the rotator cuff; and (3) trophic deltoid presenting strength grade 5.

The exclusion criteria were: (1) permanent injury to the axillary nerve; (2) arthrosis of other etiologies; and (3) previous fractures of the glenohumeral joint.

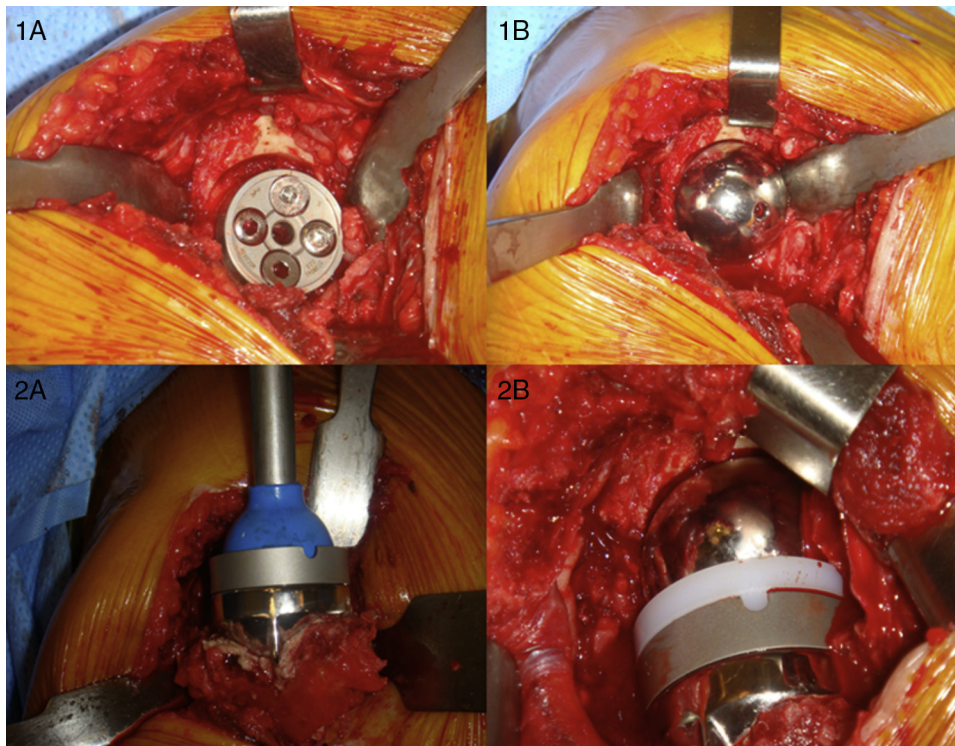


Fig. 1 – During the operation: (1A) insertion of baseplate with locking screws and cortical screws; (1B) fitting of glenosphere; (2A) insertion of cemented humeral component; (2B) fitting of polyethylene piece and reduction of the components.

Using these criteria, 27 shoulders in 24 patients were included in our sample.

All the patients were operated by the senior surgeon of the group, and all operations were performed with the patient in the deckchair position. The approach used was a trans-deltoid superolateral access (Fig. 1). The implant model used was the Delta Xtend Depuy®. The injuries were classified in accordance with Seebauer²¹ for the degree of arthropathy and Valenti et al.²² for the notching.

After the procedure, a suction drain was installed and this was kept in place for 24h. The patients were released on the second postoperative day. Between the times of the surgery and release, the patients received 3 g of cefazolin intravenously, divided into three doses of 1 g each.

The patients were followed up (Fig. 2) two weeks, six weeks, three months and six months after the operation and annually thereafter. For all of the consultations, the patients underwent trauma series radiological examinations on the scapulohumeral joint. At the consultations, the patients were evaluated using the UCLA score and a questionnaire on complications and the degree of satisfaction with the procedure was filled out.

Statistical analysis

The results relating to quantitative variables were described using means, medians, minimum values, maximum values and standard deviations. Qualitative variables were described using frequencies and percentages. To compare groups defined using the classifications of Seebauer²¹ and

Table 1 – Arthropathy of the rotator cuff according to Seebauer classification.

Seebauer	Frequency	Percentage
2A	19	70.4
1B	5	18.5
2B	3	11.1
Total	27	100

Valenti et al.,²² in relation to the UCLA score, the nonparametric Mann-Whitney and Kruskal-Wallis tests were used. A p -value <0.05 indicated statistical significance. The data were analyzed using the SPSS v. 20.0 computer software.

Results

The data registered in relation to 27 shoulders in 24 patients who underwent shoulder surgery were analyzed. These patients were evaluated before and after the operation in relation to the UCLA score. Their mean age was 77.4 years (range: 60–89). The mean length of follow-up among the patients analyzed was 25.8 months (range: 6–51).

Among the 24 patients, only one (3.7%) was male and the other 23 (96.3%) were female. In relation to the side affected, 14 (51.9%) of the cases were on the right side and 13 (48.1%) were on the left side.

According to the Seebauer²¹ classification for arthropathy of the rotator cuff, 19 (70.4%) of the shoulders were classified as 2A, five (18.5%) as 1B and three (11.1%) as 2B (Table 1).

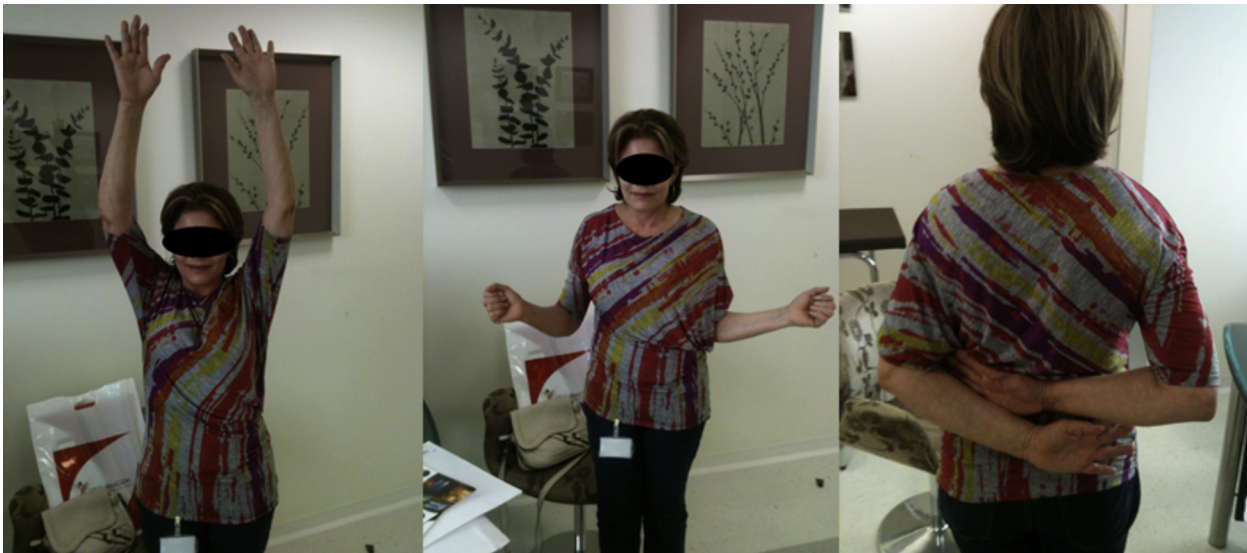

Fig. 2 – Elevation and external and internal rotation in a patient, 12 months after the operation.

There were 15 cases of complications, 14 of notching and one of dislocation of the components during the immediate postoperative period, in which revision with exchange of the polyethylene piece was necessary. Up to the time of the most recent follow-up, only this patient has undergone revision.

In relation to the presence of notching, 13 (48.1%) of the patients did not present this complication, while nine (33.3%) presented grade 1 according to Nerot and five (18.5%) presented grade 2 (Fig. 3).

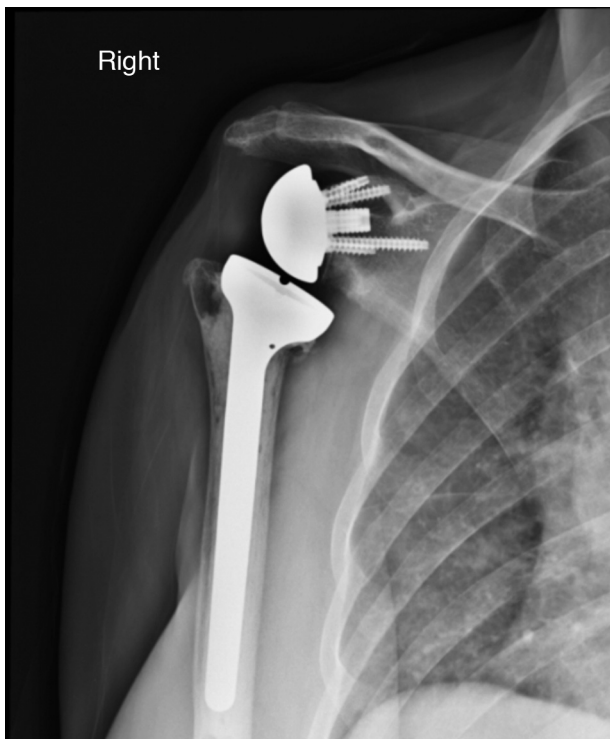

Fig. 3 – Notching: reabsorption of the lower portion of the scapular neck.

The preoperative and postoperative UCLA scores were compared and analyzed. The postoperative UCLA scores were compared with the presence and degree of notching and its severity according to Nerot.

The mean preoperative UCLA score was 10.1 (range: 6–15). The mean postoperative UCLA score was 29.8 (range: 20–35).

The mean increase in UCLA score from before to after the operation was 19.7 ($p < 0.001$), thus showing that the patients attained a statistically significant functional improvement (Table 2).

The null hypothesis that there was no correlation between the pre- and postoperative UCLA scores (correlation coefficient equal to 0) was tested versus the alternative hypothesis that a correlation existed (correlation coefficient differing from 0). Spearman's correlation coefficient was estimated as 0.18, without statistical significance ($p = 0.360$). This meant that although there was a significant increase in UCLA score subsequent to the operation, there was no relationship between lower preoperative UCLA scores and postoperative UCLA scores that were also lower. Thus, we cannot affirm that there was a correlation between a poor functional score before the operation and its postoperative result.

In the analysis on the correlation between the postoperative UCLA score and the presence of notching and its severity according to the Nerot classification, the null hypothesis that the results would be equal for the groups of patients with notching of grades 0, 1 and 2 was tested versus the alternative hypothesis that at least one group would have results that differed from those of the other groups. In this analysis, the nonparametric Kruskal–Wallis test was used.

The patients without the presence of bone erosion (Nerot = 0) presented a mean postoperative UCLA score of 29.5 (range: 23–35). The patients with notching of grade 1 according to Nerot presented a mean UCLA score of 31.1 (range: 22–35), while those who presented notching of grade 2 presented a mean UCLA score of 28.2 (range: 20–35). In evaluating the difference in postoperative UCLA score and its correlation with the presence and degree of notching, we found that the

Table 2 – UCLA score before and after the operation.

Variable	n	Mean	Median	Minimum	Maximum	Standard deviation	p-Value ^a
UCLA before	27	10.1	11	6	15	2.8	<0.001
UCLA after	27	29.8	31	20	35	4.2	
Diff UCLA (after-before)	27	19.7	19	11	29	4.6	

^a $p < 0.001$ and therefore showing statistical significance for comparison of UCLA scores from before to after the operation.

Table 3 – Correlation of notching with difference in UCLA score from before to after the operation.

Notching	n	Diff UCLA (after-before)				Standard deviation	p-Value ^a
		Mean	Median	Minimum	Maximum		
0	13	19.2	17	14	29	4.7	0.225
1	9	21.3	23	11	26	4.6	
2	5	18.0	18	12	24	4.3	

^a $p = 0.225$ and therefore showing that the correlation of notching with UCLA score did not present statistical significance.

presence and severity of notching did not have any correlation with the functional result obtained ($p = 0.446$) (Table 3).

Only two patients said that they would not undergo the procedure again.

Discussion

Although the initial treatment should always be conservative, consisting of changes to activities, oral analgesics, physiotherapy and intra-articular infiltrations, surgical treatment generally becomes necessary. Glenohumeral arthrodesis has the aim of pain relief, but absence of this joint leads to overloading of the acromioclavicular joint and may cause pain in this joint. However, this technique is also a salvage alternative for patients who have already undergone other surgical procedures and for those presenting irreparable rotator cuff defects, histories of infection or deficiencies of the deltoid.^{16,17}

Another salvage procedure that is possible is resection arthroplasty. This is indicated as a salvage option and last treatment option in cases of chronic infection subsequent to osteosynthesis with bone loss, or after infected arthroplasty procedures.¹⁸

Conventional arthroplasty is a technique that has been greatly used, but without the lower compression force vectors, the humeral head would become displaced upwards and would lead to an eccentric load on the glenoid component, which is an effect known as the rocking horse. Thus, this technique is proscribed today.^{19,20}

Hemiarthroplasty is a viable option with good results, especially in patients who still present satisfactory preoperative range of motion. The risk of reabsorption of the glenoid and acromion, which is a complication related to this treatment method, is associated with previous acromioplasty and resection of the coracoacromial ligament. Studies have shown that resection of this ligament and a history of previous acromioplasty are related to worse results because of instability and upward migration of the prosthesis.^{10,11}

The patients' mean age was 77.4 years, which was slightly greater than the mean in the worldwide literature, in which the majority of the patients were still completing their

seventh decade of life. The dominant side was more often affected (55%) and females were affected in much greater numbers (96.3%). These data were similar to the findings of other studies.²³

The complications from reverse arthroplasty include notching (the commonest complication), infection, instability, hematomas, loosening of the glenoid component, loosening of the humeral component, dissociation of the components, fractures of the acromion, other fractures and neurovascular lesions. In the present study, there were 14 cases of scapular notching (51.9%) and one of dislocation of the components. There were no cases of infection or other complications. The notching rate was similar to that of the literature, while the general complication rate was lower.^{6,23-25}

The complication most frequently encountered in the literature is notching. This is characterized as attrition or reabsorption in the inferoposterior portion of the scapular neck. Its severity was stratified and classified by Valenti et al.²² There is still some controversy in the literature regarding its clinical relevance. In our study, notching was the commonest complication. We found that its incidence was 51.9%, a percentage that was within the range in the literature, which has been from 19% to 100%.^{23,26,27} The factors that contribute to the presence of this bone erosion include the learning curve, position of the glenoid component, diminished acromial-humeral space and fatty infiltration of the infraspinatus. Inferiorization of the baseplate is the factor that contributes most toward this complication.²⁷ The presence and severity of notching as classified by Nerot did not present any relationship with the functional result, i.e. the presence or absence of this complication did not affect the result from the reverse arthroplasty or the patient's satisfaction with it.

There were no cases of infection in this group. According to the literature, this is the second most frequent complication, with a rate of around 5%.^{23,28} The absence of soft tissues around the rotator cuff that is associated with elderly patients, with formation of hematoma and large numbers of previous surgeries, contributes toward infection in reverse arthroplasty. The agent most commonly isolated in infections, according to the literature, is *Propionibacterium acnes*, followed by *Staphylococcus epidermidis*.²⁸ When present, the infectious condition

has an insidious nature, with nonspecific pain, and it may lead to loosening of the humeral and glenoid components. This may lead to unsatisfactory results and greater numbers of subsequent surgical procedures needed to treat it.

In the literature, there are few studies on periprosthetic fractures in arthroplasty procedures involving the glenohumeral joint.²⁹ We were unable to find any specific articles on humeral fractures from reverse prostheses in our survey, and we also did not have this complication in our sample.

Instability of the “ball and socket” interface of the component of the prosthesis leads to dislocation. Its incidence ranges from 0% to 14%.²³ The lack of compressive forces associated with a shallow humeral component is the factor most correlated with dislocation. This complication tends to occur within the first months, and closed reduction is the immediate treatment. When it is recurrent, new surgery becomes necessary in order to correct the possible technical failures. We only had one case of dislocation (3.7%), which occurred during the immediate postoperative period, while the patient was being transferred to a bed. The humeral component became loosened and the patient then underwent revision surgery in which the polyethylene component was exchanged for a larger one. This patient evolved satisfactorily, without recurrence of the instability.

When there is an indication for reverse arthroplasty, erosion of the acromion by the humeral head is already present. With this prosthesis, the length of the arm increases by 2.5 cm on average and the tension on the deltoid also increases. In addition, the medialization of the center of rotation increases the tension on the acromion. This leads to the risk of fracturing the acromion, which may occur in up to 3% of the cases after reverse arthroplasty.³⁰ In our group, we did not have any cases of this complication. Preoperative lesions of the acromion do not contraindicate arthroplasty, but when fractures occur after the operation, there is a correlation with worse prognosis and functional results from reverse arthroplasty.³⁰ Their diagnosis may go unnoticed and there needs to be a high degree of suspicion according to the clinical condition that the patient presents, with confirmation by means of radiography and tomography when necessary.

The mean preoperative UCLA score of 10.1 showed that the shoulders evaluated presented poor functional capacity in relation to daily activities, with limitation of the range of motion and presence of pain. Comparison with the mean postoperative UCLA score of 29.8 shows that there was a statistically significant improvement ($p < 0.05$), with a mean difference of 19.7 on this scale. Among all the patients, only one of them (3.7%) declared that he would not undergo this surgery again. This demonstrates that the rate of satisfaction with the surgery was high among these patients. In comparing the postoperative UCLA score with the presence of notching, it was noted that there was no correlation between these two parameters.

Conclusion

Reverse arthroplasty was shown to be an excellent option for treating patients with arthropathy of the rotator cuff, with satisfactory functional results. Notching was a frequent

complication. However, in our sample, this did not present any clinical repercussion, even though our series may have been limited by its small sample size.

Conflicts of interest

The authors declare no conflicts of interest.

REFERENCES

1. Feeley BT, Gallo RA, Craig EV. Cuff tear arthropathy: current trends in diagnosis and surgical management. *J Shoulder Elbow Surg.* 2009;18(3):484-94.
2. Neer CS 2nd, Craig EV, Fukuda H. Cuff-tear arthropathy. *J Bone Joint Surg Am.* 1983;65(9):1232-44.
3. Garancis JC, Cheung HS, Halverson PB, McCarty DJ. Milwaukee shoulder – association of microspheroids containing hydroxyapatite crystals, active collagenase, and neutral protease with rotator cuff defects. III. Morphologic and biochemical studies of an excised synovium showing chondromatosis. *Arthritis Rheum.* 1981;24(3):484-91.
4. Nam D, Maak TG, Raphael BS, Kepler CK, Cross MB, Warren RF. Rotator cuff tear arthropathy: evaluation, diagnosis, and treatment: AAOS exhibit selection. *J Bone Joint Surg Am.* 2012;94(6):e34.
5. Jensen KL, Williams GR Jr, Russell IJ, Rockwood CA Jr. Rotator cuff tear arthropathy. *J Bone Joint Surg Am.* 1999;81(9):1312-24.
6. Walch G, Wall B, Mottier F. Complications and revision of the reverse prosthesis, a multicenter study of 457 cases. In: Walch G, Boileau P, Mole D, Favard L, Levigne C, Sirveaux F, editors. *Reverse shoulder arthroplasty: clinical results, complications, revision.* Montpellier, France: Sauramps Medical; 2006. p. 335-52.
7. Hockman DE, Lucas GL, Roth CA. Role of the coracoacromial ligament as restraint after shoulder hemiarthroplasty. *Clin Orthop Relat Res.* 2004;(419):80-2.
8. Boileau P, Baqué F, Valerio L, Ahrens P, Chuinard C, Trojani C. Isolated arthroscopic biceps tenotomy or tenodesis improves symptoms in patients with massive irreparable rotator cuff tears. *J Bone Joint Surg Am.* 2007;89(4):747-57.
9. Klinger HM, Steckel H, Ernstberger T, Baums MH. Arthroscopic debridement of massive rotator cuff tears: negative prognostic factors. *Arch Orthop Trauma Surg.* 2005;125(4):261-6.
10. Brasil Filho R, Ribeiro FR, Tenor Junior AC, Filardi Filho CS, Costa GBL, Storti TM, et al. Resultados do tratamento cirúrgico da artropatia degenerativa do manguito rotador utilizando hemiartroplastia-CTA®. *Rev Bras Ortop.* 2012;47(1):66-72.
11. Visotsky JL, Basamania C, Seebauer L, Rockwood CA, Jensen KL. Cuff tear arthropathy: pathogenesis, classification, and algorithm for treatment. *J Bone Joint Surg Am.* 2004;86 Suppl. 2:35-40.
12. Williams GR Jr, Rockwood CA Jr. Hemiarthroplasty in rotator cuff-deficient shoulders. *J Shoulder Elbow Surg.* 1996;5(5):362-7.
13. Boileau P, Watkinson DJ, Hatzidakis AM, Balg F. Grammont reverse prosthesis: design, rationale, and biomechanics. *J Shoulder Elbow Surg.* 2005;14 1 Suppl. S:147S-61S.
14. Frankle M, Levy JC, Pupello D, Siegal S, Saleem A, Mighell M, et al. The reverse shoulder prosthesis for glenohumeral arthritis associated with severe rotator cuff deficiency. A minimum two-year follow-up study of sixty patients surgical technique. *J Bone Joint Surg Am.* 2006;88 Suppl. 1 Pt 2:178-90.

15. Sirveaux F, Favard L, Oudet D, Huquet D, Walch G, Molé D. Grammont inverted total shoulder arthroplasty in the treatment of glenohumeral osteoarthritis with massive rupture of the cuff. Results of a multicentre study of 80 shoulders. *J Bone Joint Surg Br.* 2004;86(3):388-95.
16. Scalise JJ, Iannotti JP. Glenohumeral arthrodesis after failed prosthetic shoulder arthroplasty. *J Bone Joint Surg Am.* 2008;90(1):70-7.
17. Cofield RH, Briggs BT. Glenohumeral arthrodesis. Operative and long-term functional results. *J Bone Joint Surg Am.* 1979;61(5):668-77.
18. Godinho GG, Freitas JMA, Franca FO, França FO, Fernandes LFD, Carvalho B. Artroplastia de ressecção da cabeça umeral como procedimento de salvação em complicações pós-cirúrgicas. *Rev Bras Ortop.* 2006;41(9):361-5.
19. Franklin JL, Barrett WP, Jackins SE, Matsen FA 3rd. Glenoid loosening in total shoulder arthroplasty. Association with rotator cuff deficiency. *J Arthroplasty.* 1988;3(1):39-46.
20. Grammont PM, Baulot E. Delta shoulder prosthesis for rotator cuff rupture. *Orthopedics.* 1993;16(1):65-8.
21. Seebauer L. Total reverse shoulder arthroplasty: European lessons and future trends. *Am J Orthop (Belle Mead NJ).* 2007;36 12 Suppl. 1:22-8.
22. Valenti PH, Boutens D, Nerot C. Delta 3 reversed prosthesis for osteoarthritis with massive rotator cuff tear: long-term results (5 years). In: Walch G, Boileau P, Mole D, editors. *Shoulder prosthesis: two to ten year follow-up.* Montpellier, France: Sauramps Medical; 2001. p. 253-9.
23. Farshad M, Gerber C. Reverse total shoulder arthroplasty – from the most to the least common complication. *Int Orthop.* 2010;34(8):1075-82.
24. Wierks C, Skolasky RL, Ji JH, McFarland EG. Reverse total shoulder replacement: intraoperative and early postoperative complications. *Clin Orthop Relat Res.* 2009;467(1): 225-34.
25. Simovitch RW, Zumstein MA, Lohri E, Helmy N, Gerber C. Predictors of scapular notching in patients managed with the Delta III reverse total shoulder replacement. *J Bone Joint Surg Am.* 2007;89(3):588-600.
26. Levigne C, Boileau P, Favard L. Scapular notching. In: Walch G, Boileau P, Molé D, editors. *Reverse shoulder arthroplasty: clinical results, complications, revision.* Montpellier, France: Sauramps Medical; 2006. p. 353-72.
27. Lévine C, Boileau P, Favard L, Garaud P, Molé D, Sirveaux F, et al. Scapular notching in reverse shoulder arthroplasty. *J Shoulder Elbow Surg.* 2008;17(6):925-35.
28. Zeller V, Ghorbani A, Strady C, Leonard P, Mamoudy P, Desplaces N. *Propionibacterium acnes*: an agent of prosthetic joint infection and colonization. *J Infect.* 2007;55(2): 119-24.
29. Andersen JR, Williams CD, Cain R, Mighell M, Frankle M. Surgically treated humeral shaft fractures following shoulder arthroplasty. *J Bone Joint Surg Am.* 2013;95(1):9-18.
30. Walch G, Mottier F, Wall B, Boileau P, Molé D, Favard L. Acromial insufficiency in reverse shoulder arthroplasties. *J Shoulder Elbow Surg.* 2009;18(3):495-502.