



## Original Article

# Posterior four-part fracture-dislocations of the proximal humerus: clinical and functional evaluation of osteosynthesis treatment<sup>☆</sup>



Carla Teresa Barbosa de Oliveira<sup>a,\*</sup>, Elpídio da Graça<sup>a</sup>, Vânia Aparecida Fanelli<sup>b</sup>

<sup>a</sup> Universidade de Ribeirão Preto, Ribeirão Preto, SP, Brazil

<sup>b</sup> Clínica Ortohealth, Ribeirão Preto, SP, Brazil

## ARTICLE INFO

## Article history:

Received 1 February 2017

Accepted 6 April 2017

Available online 5 April 2018

## Keywords:

Humeral fractures

Shoulder dislocation

Internal fracture fixation

## ABSTRACT

**Objective:** To evaluate patients diagnosed with posterior four-part fracture-dislocations of the proximal humerus, that were surgically treated with osteosynthesis, regarding their clinical and functional outcomes.

**Methods:** A prospective observational study of eight patients from the same hospital institution in the interior of São Paulo State (Brazil), through individual interviews using the UCLA, DASH, and Constant international scores. The active movements included in the scores plus the range of motion of the affected and non-affected limb were measured. The affected shoulder's radiographs were requested to verify bone conditions and the fixation of the osteosynthesis.

**Results:** The rating of eight patients by the international scores indicated that seven of the eight patients presented good clinical and functional evolution of the affected limb; this represents 87.5% of the evaluated individuals.

**Conclusion:** Surgical treatment with osteosynthesis performed during the acute period (<four weeks) leads to good results in most cases.

© 2017 Sociedade Brasileira de Ortopedia e Traumatologia. Published by Elsevier Editora Ltda. This is an open access article under the CC BY-NC-ND license (<http://creativecommons.org/licenses/by-nc-nd/4.0/>).

## Fraturas-luxações posteriores do úmero proximal em quatro partes: avaliação clínico-funcional do tratamento por osteossíntese

## RESUMO

**Objetivo:** Avaliar os pacientes com diagnóstico de fratura-luxação posterior da extremidade proximal do úmero em quatro partes que foram tratados cirurgicamente com osteossíntese, do ponto de vista clínico e funcional.

## Palavras-chave:

Fraturas do úmero

Luxação do ombro

Fixação interna de fraturas

<sup>☆</sup> Study conducted at Hospital Santa Lydia, Ribeirão Preto, SP, Brazil.

\* Corresponding author.

E-mail: [carla.teresa@hotmail.com](mailto:carla.teresa@hotmail.com) (C.T. Oliveira).

<https://doi.org/10.1016/j.rboe.2018.03.010>

2255-4971/© 2017 Sociedade Brasileira de Ortopedia e Traumatologia. Published by Elsevier Editora Ltda. This is an open access article under the CC BY-NC-ND license (<http://creativecommons.org/licenses/by-nc-nd/4.0/>).

**Métodos:** Estudo observacional prospectivo de oito pacientes de um mesmo serviço de ortopedia e traumatologia do interior do Estado de São Paulo, por meio de entrevistas individuais, com os scores internacionais de UCLA, DASH e Constant. Mediram-se os movimentos ativos incluídos nos scores e a amplitude de movimentos do membro acometido e do não acometido. Solicitaram-se radiografias do ombro acometido para verificar as condições ósseas e de fixação dos materiais de síntese.

**Resultados:** A avaliação de oito pacientes por meio dos scores usados indicou que sete apresentaram uma boa evolução clínico-funcional do membro acometido, ou seja, 87,5% dos avaliados.

**Conclusão:** O tratamento cirúrgico com osteossínteses feito no período agudo (< quatro semanas) apresenta bons resultados na maioria dos casos.

© 2017 Sociedade Brasileira de Ortopedia e Traumatologia. Publicado por Elsevier Editora Ltda. Este é um artigo Open Access sob uma licença CC BY-NC-ND (<http://creativecommons.org/licenses/by-nc-nd/4.0/>).

## Introduction

The shoulder joint is prone to dislocation due to its anatomical structure and its biomechanics, which allow an extensive range of movement.<sup>1</sup> It is believed that, among the major joints of the human body, the shoulder suffers most dislocations, with an incidence of 8.2 to 23.9 per 100,000 inhabitants.<sup>2</sup>

According to Cooke and Hackney,<sup>3</sup> of all dislocations, 4% are posterior and only 1% are associated with fractures. Fractures of the proximal humerus account for 4% to 10% of all fractures; the most common trauma mechanism is a fall from the patient's own height.<sup>4</sup>

Posterior fracture-dislocation of the shoulder (PFDS) is an uncommon orthopedic entity,<sup>5-10</sup> and bilateral PFDS is even rarer, initially described by Mynther in 1902.<sup>5,11,12</sup> The most frequent causes described in the literature are epilepsy, extreme trauma, and electric shock, hence it is known as triple E syndrome. The imbalance of muscle strength between the medial and lateral rotator groups accounts for the trauma mechanism, attributed to adduction and medial rotation (MR) of the affected limb.<sup>5,13</sup> In addition to the high-energy trauma, the intense muscle contraction forces the humeral head against the glenoid edge, causing fracture with possible comminution.<sup>5</sup>

The infrequent diagnosis of PFDS and its non-specific symptoms, such as pain and limitation of movement with the limb in MR and adduction, contribute to the underdiagnosis and delayed treatment of this condition. This may increase the number of complications, including osteonecrosis and collapse of the humeral head, inverted Hill-Sachs injury, posterior instability, and the inevitable arthrosis.<sup>6</sup> The diagnosis of PFDS can be made through imaging tests, such as shoulder radiographs, in anteroposterior, scapular, and especially lateral axillary views.<sup>14</sup>

Moreover, dislocation and PFDS have been described since the last century, but to date, the literature features few articles with a sufficient numbers of cases.<sup>15</sup>

In the present study, the authors evaluated patients diagnosed with PFDS classified according to Neer as four-part fractures, that were surgically treated with osteosynthesis material, all of whom were followed-up by the same surgeon

at an orthopedics and traumatology unit in the interior of São Paulo State (Brazil).

## Material and methods

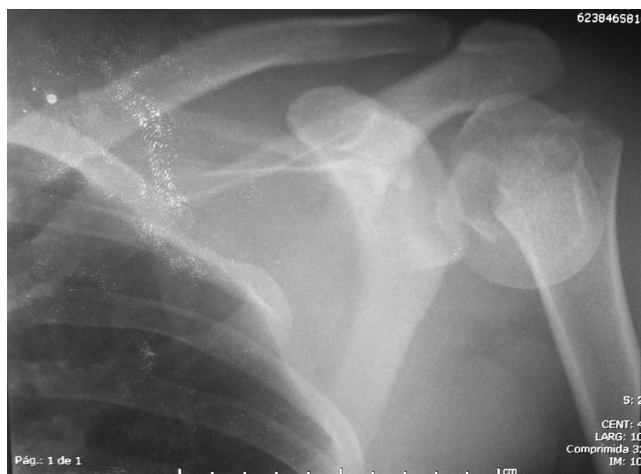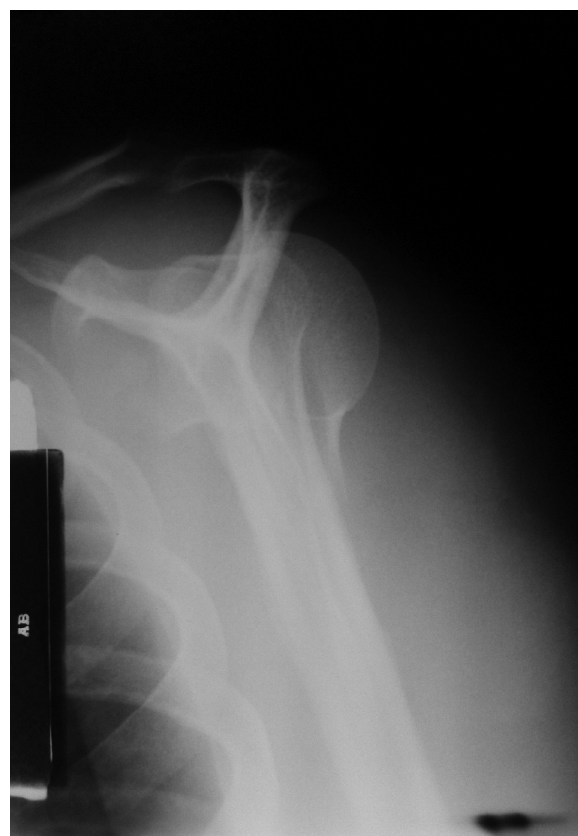Between July 2001 and June 2013, eight patients were diagnosed with posterior fracture of the proximal humerus, classified as four-part fractures by the Neer classification. Posterior fracture-dislocations of the proximal humerus in three or less parts, anterior fracture-dislocation, and posterior four-part fracture-dislocation of the proximal humerus treated conservatively or with arthroplasty were not included. Patients were diagnosed and treated by the staff of an orthopedics and traumatology unit in the interior of São Paulo, State (Brazil), and are currently in outpatient follow-up. Eight shoulders were treated in eight patients (seven males and one female), with mean age of 47 years (range: 37-59). Five patients reported motorcycle accident as cause of the injury, one reported seizure crisis, and two reported electric shock. Four patients presented injury to the dominant limb, and four on the non-dominant side (Table 1). All patients in the study were diagnosed and treated in the acute phase (up to four weeks after the event),  $\Delta t$  of 11.5 days (range: 1-28 days). Five patients presented injuries associated with blunt force trauma in the contralateral hand, compound fracture of ipsilateral leg bones, contralateral patellar fracture and ipsilateral third-finger fracture, and posterior contralateral shoulder dislocation.

For all eight patients, radiographs of the affected shoulder were made in anteroposterior (AP; Fig. 1), scapular profile (P; Fig. 2), and lateral axillary views (Fig. 3); in four cases, computed tomography (CT) scans were performed (Fig. 4A and B).

Patients were treated through open surgery and internal fixation with osteosynthesis. In one patient, Ethibond sutures were used, and in the other, fixation with Kirschner wire (KW) and securing sutures were used. Six shoulders were secured with locking plate (LP) and screws associated with securing sutures (Fig. 5A-C). All patients were immobilized with a lateral rotation (LR) thoraco brachial (TB) plaster cast for 45 days, followed by outpatient and radiological follow-up. No patient evolved with acute complications. Four patients underwent

**Table 1 – Patient profile.**

Patient	Age	Gender	Dominant side	Affected side	Cause	Associated lesion
1	59	M	R	L	Convulsion	Posterior Right shoulder dislocation
2	49	M	R	L	Motorcycle accident	
3	48	M	R	R	Motorcycle accident	Left hand wound
4	38	M	R	L	Motorcycle accident	Compound Left leg fracture
5	51	M	R	R	Motorcycle accident	Left patellar fracture
6	37	M	R	L	Electric shock	
7	56	M	R	R	Motorcycle accident	Fracture of the 3rd and 5th fingers
8	40	F	R	L	Motorcycle accident	

**Fig. 1 – Radiograph of the left shoulder on an anteroposterior view.****Fig. 2 – Radiograph of the left shoulder on a lateral view.**

physical therapy and four, home exercises under medical supervision. One patient admitted to not adhering to the physical therapy or exercises with the prescribed frequency, giving preference to the treatment of associated injuries (Table 2).

For clinical and functional assessment, a prospective observational study was conducted through individual interviews. The UCLA, Disabilities of the Arm, Shoulder and Hand (DASH), and Constant scored were used; the active movements included in the Constant score were performed under the supervision of a physical therapist. The range of motion of active movements of the affected and contralateral limb were measured with the use of a goniometer, considering elevation, LR, and MR as comparative parameters. The modified UCLA score evaluates pain, function, range of active flexion, anterior flexion strength of the shoulder, and patient satisfaction. Pain and function are graded on a scale of up to 10 points each. Active flexion, anterior flexion strength, and patient satisfaction range from 0 to 5, totaling 35 points. A score from 34 to 35 points is considered excellent; from 28 to 33, good; from 21 to 27, fair; and 0 to 20, poor, according to Oku et al.<sup>16</sup>

The DASH score measures the symptoms and physical function of individuals with musculoskeletal disorders in the upper limbs. The assessment of functional status is subdivided into physical, social, and psychological categories. There are 30 items, whose scores range from 1 to 5 each; and a minimum of 27 of the 30 items must be answered. In the social category, two areas are optional: musical and sports performance or work. Each area includes four items, whose scores

also range from 1 to 5. In these areas, all questions must be answered.

To calculate the functional status score, the following formula should be used:

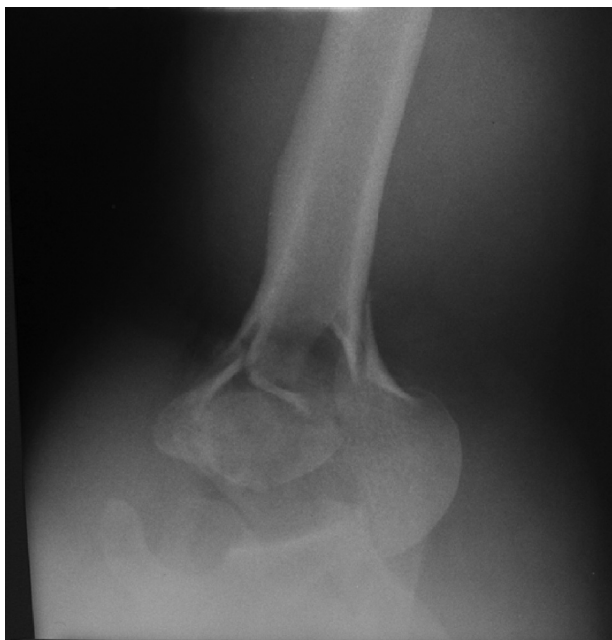$$\left[ \left( \frac{\text{sum of answers}}{\text{No. of items answered}} \right) - 1 \right] \times 25$$

To obtain the score of the optional areas, a similar formula should be used:

$$\left[ \left( \frac{\text{sum of answers}}{4} \right) - 1 \right] \times 25$$

In both scores, a total of 100 points will be obtained; the higher the value, the greater the degree of dysfunction of the limb.<sup>17</sup>

The last score evaluates the functional ability of the affected shoulder through the Constant-Murley clinical protocol, which scores four parameters: pain, performance in daily



**Fig. 3 – Radiograph of the left shoulder on lateral axillary view.**

activities, joint mobility, and isometric muscle strength. To calculate the score, the protocol must be applied bilaterally. The maximum score is 100 points; the closer to 100, the better the functional capacity.<sup>18</sup>

The interviews were scheduled at the institution itself, according to the patients' availability. Radiographs of the affected shoulder were requested to assess the bone and fixation of the osteosynthesis material. The study was approved by the institution's Ethics Committee under CAAE No. 32955113.3.0000.5440 – opinion No. 774166. All eight patients attended the reassessment consultation. An Informed Consent Form was signed by all participants.

## Results

In the UCLA score, two patients presented excellent results; three, good; and three, fair.

In the DASH score, four patients had scores of 0 or <1; two patients, <20; and two patients, between 24 and 50 points.

In the Constant score, five patients scored above 90, which is interpreted as an excellent result. Two patients scored 73 and 77 points, interpreted as fair results; and one obtained a score of 61 points (Table 3).

## Discussion

This study evaluated patients who suffered posterior fracture-dislocation of the proximal humerus, classified as four-part fractures by the Neer classification, who were surgically treated with open reduction and internal fixation with osteosynthesis material. This pathology is a rare group among glenohumeral injuries<sup>19</sup>; of all dislocations, 1.7% to 4.3% are posterior and only 0.9% are associated with fractures.<sup>8-10</sup>

Fukuda et al.<sup>8</sup> also indicated that PFDS is an extremely rare injury, accounting for 0.9% of proximal humeral fractures, occurring annually in 0.6/100,000 people. Thus, in 13 years, only eight patients from an orthopedic and traumatology unit in the interior of São Paulo State met the inclusion criteria adopted.

The patients studied presented triple E syndrome as the trauma mechanism. The causes for these types of injuries are forced MR, flexion, and adduction of the shoulder joint.<sup>7</sup> In 2012, O'Neil et al.<sup>11</sup> reported that 50% of all cases are caused by seizures, 45% by trauma, and less than 5% by electric shock.

Robinson<sup>19</sup> describes the profile of patients as relatively young and middle-aged, and predominantly male. Likewise, the mean age of the patients in the present study was 42 years, and 87.5% were male. Therefore, they represent patients with good bone quality, capable of sustaining osteosynthesis material.

The internal fixation with LP and screws offers greater stability, favoring early mobility of the affected limb.<sup>4</sup> However, various other methods of osteosynthesis are also capable of providing stability and allowing early mobility.<sup>20</sup> Different osteosynthesis methods provide different degrees of stability, but show similar functional clinical results.<sup>21</sup>

It is important to have the possibility of partial arthroplasty in the surgical therapeutic arsenal for cases where a satisfactory reduction and stabilization of the bone fragments is not possible, due to fracture comminution.<sup>22</sup>

In the present study, different osteosynthesis techniques were used, such as securing sutures,<sup>23,24</sup> KW and tension-band,<sup>25</sup> and LP,<sup>4</sup> depending of the material available for each case, which is related to financial cost. However, all patients underwent surgical treatment in accordance with the concepts of minimally invasive osteosynthesis, i.e., early surgical intervention, minimal soft tissue injury, careful manipulation of the fragments, fracture stabilization, and early rehabilitation.<sup>8,26</sup>

Among the assessed patients, seven presented a good long-term evolution, while one presented scores that characterized mild to moderate musculoskeletal dysfunction. This patient admitted to not having undergone physical therapy nor performed domestic rehabilitation of the upper limb due to giving preference to treatment of associated injuries.

Vastamaki and Solonem<sup>9</sup> state that early reduction is of extreme importance, and that the primary results of late treatment are good; however, in the long term, it leads to painful post-traumatic arthrosis. Cooke and Hackey<sup>3</sup> report that good outcomes depend not only on early diagnosis and treatment, but also on early and continuous physical therapy. The authors insist on and draw attention to the fact that diagnosis and treatment should be made early in order to prevent complications and to recover joint mobility and function.<sup>14</sup>

According to Oakes and McAllister,<sup>10</sup> the possible complications of PFDS include the development of osteonecrosis of the humeral head. Anatomic neck fractures are associated with a high risk of avascular necrosis and four-part fracture-dislocations; the risk can be as high as 90%.<sup>3</sup>

Conservative treatment presents an incidence of avascular necrosis of between 3% and 14% in cases with three fragments

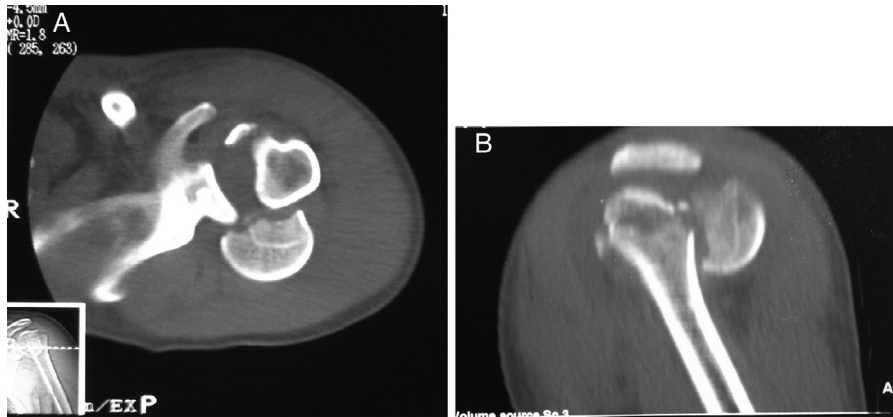


Fig. 4 - (A) Computed tomography in axial section; (B) computed tomography in sagittal section.

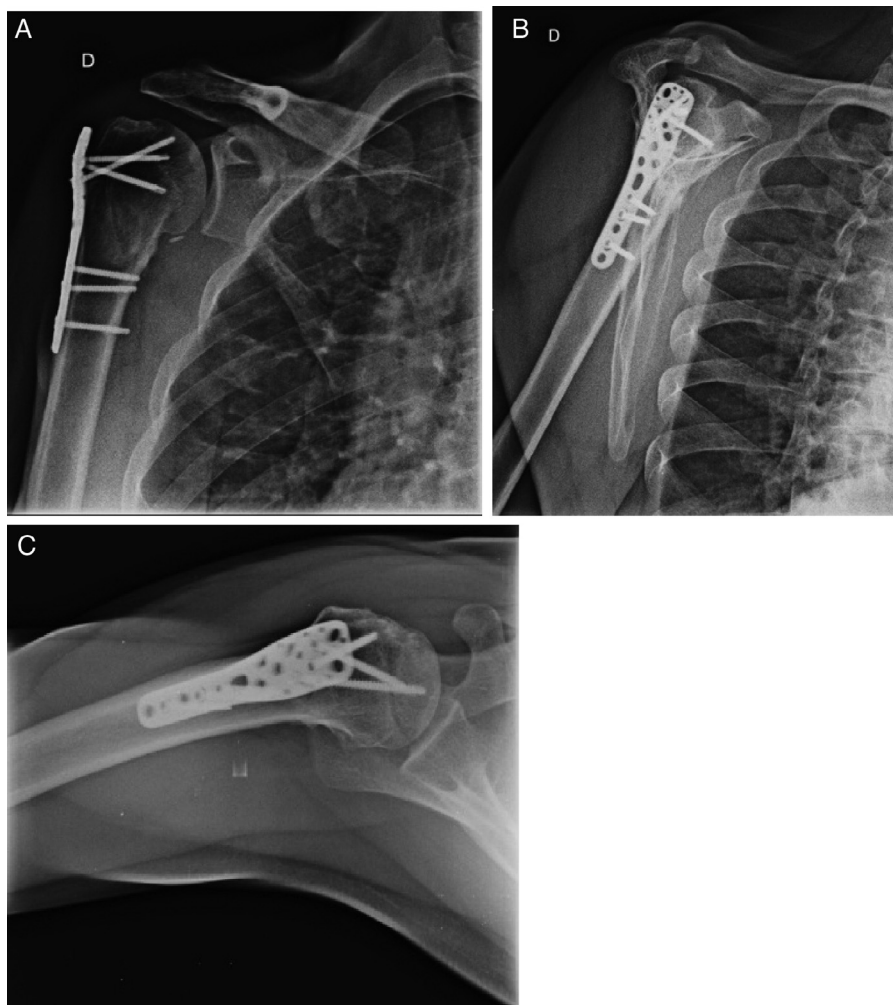


Fig. 5 - (A) Radiograph on anteroposterior view showing consolidated fracture treated with fixation with a locking plate; (B) radiograph lateral view showing consolidated fracture treated with fixation with a locking plate; (C) radiograph on axial view showing consolidated fracture treated with fixation with a locking plate.

and between 13% and 34% in cases with four fragments. This rate increases in the presence of dislocated fractures. Plate osteosynthesis may also lead to avascular necrosis, presenting rates above 35% in complex joint fractures.<sup>27</sup>

According to Robinson,<sup>19</sup> complications include osteonecrosis of the humeral head and tubercles, pseudoarthrosis, malunion, infections, neurological lesions, movement limitation, and complications related to the

**Table 2 – Treatment data.**

Patient	Δt (days)	Type of osteosynthesis	Type of immobilization	Rehabilitation
1	01	Securing sutures	TB in LR	Yes
2	03	KW and securing sutures	TB in LR	Yes
3	03	PB and Ethibond suture	TB in LR	Yes
4	06	PB and Ethibond suture	TB in LR	No
5	05	PB and Ethibond suture	TB in LR	Yes
6	01	PB and Ethibond suture	TB in LR	Yes
7	09	PB and Ethibond suture	TB in LR	Yes
8	28	PB and Ethibond suture	TB in LR	Yes

**Table 3 – Result of the scores.**

Patient	UCLA	DASH	Constant	ROM affected side	ROM non-affected side
1	34	0.83 0 0	92	180 40° T10	180 35° Gluteus
2	29	6.6 DNA 0	73	150° 45° L1	180 60° T10
3	27	0 DNA 0	96	140° 45° T7	160° 60° T7
4	21	24.16 50 43.75	61	90° 20° L4	170° 60° T10
5	35	0 DNA 0	98	180 90° T3	180 90° T10
6	33	0 DNA 0	96	180 45° T7	180 90° T10
7	30	13.33 6.25 12.5	92	115° 45° T7	180 60° T7
8	26	42.5 DNA DNA	77	110° 20° L2	180 60° T7

Interpretation: Constant, the closer to 100, the better the function; DASH, the closer to 100, the greater the dysfunction; UCLA, excellent, 34–35; good, 28–33; fair, 21–27; poor, 0–20.  
DNA, did not answer.

osteosynthesis material. In case of movement limitation, the initial treatment is conservative, with rehabilitation with stretching exercises. If conservative treatment fails, treatment with hydraulic distension is indicated to promote capsular stretching and rupture.

To date, the only complication presented by the patients studied was the reduction in the range of some movements; however the patients declared to be satisfied with the results. This complication did not lead to disabilities, and all patients were able to adapt to their limitation.

## Conclusion

In general, the final results of the evaluation of the eight patients using the three scores indicated that seven of them

(87.5%) had a good clinical-functional evolution of the affected limb.

## Conflicts of interest

The authors declare no conflicts of interest.

## REFERENCES

1. Szyluk KJ, Jasiński A, Mielnik M, Koczy B. Incidence of posttraumatic shoulder dislocation in Poland. *Med Sci Monit*. 2016;22:3967–74.
2. Kwon YW, Kulwicki KJ, Zuckerman JD. Subluxações luxações e instabilidade da articulação glenoumeral. In: Buchholz RW,

- Court-Brown CM, Heckman JD, Tornetta P, editors. *Fraturas em adultos de Rockwood e Green*. 3rd ed. São Paulo: Manole; 2013. p. 1165-204.
3. Cooke SJ, Hackney RG. Bilateral posterior four-part fracture-dislocations of the shoulders following electric shock. *Injury Extra*. 2005;36(4):90-5.
  4. Monteiro GC, Ejnisman B, Andreoli CV, Pochini AC, Olympio E. Resultados do tratamento das fraturas do terço proximal do úmero com placas de bloqueio. *Acta Ortopédica Bras*. 2011;19(2):69-73.
  5. Agarwal M, Khan WS, Trehan R, Syed AA, Giannoudis PV. Bilateral posterior fracture-dislocation of the shoulder presenting as a dissecting aneurysm of the thoracic aorta: an uncommon presentation of a rare injury. *J Emerg Med*. 2008;35(3):265-8.
  6. Chalidis BE, Papadopoulos PP, Dimitriou CG. Reconstruction of a missed posterior locked shoulder fracture-dislocation with bone graft and lesser tuberosity transfer: a case report. *J Med Case Rep*. 2008;2:260.
  7. Chang CC, Pao JL, Chang CH. Posterior shoulder dislocation associated with proximal humeral comminuted fracture. *Formosan J Musculoskelet Dis*. 2012;3:70-5.
  8. Fukuda A, Nishimura A, Kato K, Sudo A. Arthroscopically assisted minimally invasive plate osteosynthesis for posterior fracture-dislocation of the shoulder. *J Orthop Sci*. 2014;19(1):194-7.
  9. Vastamäki M, Solonen KA. Posterior dislocation and fracture-dislocation of the shoulder. *Acta Orthop Scand*. 1980;51(3):479-84.
  10. Oakes DA, McAllister DR. An atypical appearance of a posterior dislocation of the shoulder with a fracture of the proximal humerus. *J Shoulder Elbow Surg*. 2001;10(2):182-5.
  11. O'Neill D, Nair JR, Binymin KA. Simultaneous bilateral posterior fracture dislocation of the shoulders in a young man with unexpected severe vitamin D deficiency. *Int J Gen Med*. 2012;5:399-402.
  12. Trollegaard A, Nygaard M, Madsen B. Bilateral posterior shoulder fracture dislocation - a diagnostic challenge. *Internet J Orthop Surg*. 2009;17(1):1-5.
  13. Claro R, Sousa R, Massada M, Ramos J, M Lourenço J. Bilateral posterior fracture-dislocation of the shoulder: report of two cases. *Int J Shoulder Surg*. 2009;3(2):41-5.
  14. Paim AE, Paim A, Torres CML, de Castro RCR. Luxação posterior traumática do ombro: diagnóstico e tratamento precoce. *Rev Bras Ortop*. 1997;32(9):731-6.
  15. Checchia SL, S Doneux P, Miyazaki AN. Fratura-luxação posterior permanente do ombro: experiência após 86 casos. *Rev Bras Ortop*. 1996;31(9):705-12.
  16. Oku EC, Andrade AP, Stadiniky SP, Carrera EF, Tellini GG. Tradução e adaptação cultural do Modified University of California at Los Angeles Shoulder Rating Scale para a língua portuguesa. *Rev Bras Reumatol*. 2006;46(4):246-52.
  17. Orfale AG, Araújo PMP, Ferraz MB, Natour J. Translation into Brazilian Portuguese, cultural adaptation and evaluation of the reliability of the Disabilities of the Arm, Shoulder and Hand Questionnaire. *Braz J Med Biol Res*. 2005;38(2):293-302.
  18. Santos MC, Lancman S. Avaliação da função do ombro em técnicos de trânsito pelo protocolo de Constant-Murley. *Fisioter Pesquisa*. 2008;15(3):259-65.
  19. Robinson CM. Fraturas do terço proximal do úmero. In: Bucholz RW, Court-Brown CM, Heckman JD, Troneta P 3rd, editors. *Fraturas em adultos de Rockwood e Green*. 7ª ed. São Paulo: Manole; 2013. p. 1015-39.
  20. da Graça E, Okubo R, Shimano AC, Mazzer N, Barbieri CH. Biomechanics of four techniques for fixation of the four-part humeral head fracture. *Acta Ortop Bras*. 2013;21(1):34-9.
  21. Morelli RSS, Travizano RES. Fraturas da extremidade proximal do úmero: estudo comparativo entre dois métodos de fixação. *Acta Ortopédica Bras*. 2010;18(2):79-84.
  22. Antunes J, Nascimento H, Miranda A. Hemiarthroplastia do ombro no tratamento de fraturas proximais do úmero. *Rev Port Ortop Traumatol*. 2015;23(1):40-9.
  23. Ferreira Neto AAF, Ferreira Filho AAF, Zoppi Filho A, Benegas E, Negri JH, Machado LFM, et al. Osteossíntese das fraturas em duas e três partes da extremidade proximal do úmero com hastes de Ender modificadas associadas com amarrilhos de Ethibond. *Rev Bras Ortop*. 1997;32(9):707-12.
  24. Atalar AC, Demirhan M, Uysal M, Seyahi A. Treatment of Neer type 4 impacted valgus fractures of the proximal humerus with open reduction, elevation, and grafting. *Acta Orthop Traumatol Turc*. 2007;41(2):113-9.
  25. Jakob RP, Miniaci R, Anson PS, Jaberg H, Osterwalder A, Ganz R. Four-part valgus impacted fractures of the proximal humerus. *J Bone Jt Surg*. 1991;73(2):295-8.
  26. Schutz M, Ruedi TP. Princípios da fixação interna. In: Bucholz RW, Court-Brown CM, Heckman JD, Tornetta P 3rd, editors. *Fraturas em adultos de Rockwood e Green*. 8ª ed. São Paulo: Manole; 2013. p. 162-87.
  27. Jansen H, Frey SP, Doht S, Meffert RH. Simultaneous posterior fracture dislocation of the shoulder following epileptic convulsion. *J Surg Case Rep*. 2012;(11), pii: rjs017 2012.