

# Twisted Plating – A Method of Distal Fibula Fixation\*

## Uso de placa retorcida – Um método de fixação da fíbula distal

Sanjay Agarwala<sup>1</sup>  Aditya Menon<sup>1</sup> Ravi Bhadiyadra<sup>1</sup>

<sup>1</sup>Department of Orthopaedics, Hinduja Hospital and Medical Research Centre, Veer Savarkar Marg, Mahim (West), Mumbai, Maharashtra, India

Address for correspondence Sanjay Agarwala, MS, Hinduja Hospital and Medical Research Centre, Veer Savarkar Marg, Mahim (West), Mumbai- 400016, Maharashtra, India (e-mail: drsa2011@gmail.com).

Rev Bras Ortop 2020;55(1):33–39.

### Abstract

**Objective** The literature entails various intramedullary and extramedullary methods for distal fibula fracture fixation; with no consensus yet over the ideal method of fixation. We have retrospectively analyzed the results of using a twisted and contoured 3.5 mm locking compression plate (LCP) as a posterior buttress plate.

**Methods** Of the 62 cases with ankle fractures managed at our institute by the senior author from 1<sup>st</sup> January 2012 to 31<sup>st</sup> December 2015, 41 patients met our inclusion criteria (Danis-Weber types B and C).

**Results** All 41 distal fibular fractures healed uneventfully, at a mean of 10.4 weeks (8–14 weeks) (Figs. 6, 7, 8 to 9) with no complications. The mean American Orthopaedic Foot & Ankle Society (AOFAS) score was 92.6 (86–100) at a mean follow-up of 31.5 months (14–61 months).

**Conclusions** We have achieved excellent clinical and radiological outcomes using a twisted 3.5 mm LCP as a posterior buttress by combining the advantages of posterior antilid plate and lateral LCP.

### Keywords

- ▶ ankle fractures
- ▶ fracture fixation, internal
- ▶ fractures, bone
- ▶ fibula
- ▶ bone plates

### Resumo

**Objetivo** A literatura discute diversos métodos intramedulares ou extramedulares para fixação de fraturas da fíbula distal, mas não há consenso acerca do método ideal de fixação. Analisamos retrospectivamente os resultados do uso de uma placa bloqueada de compressão (LCP) de 3,5 mm retorcida e com contorno como placa de apoio posterior.

**Métodos** Dos 62 casos de fraturas de tornozelo tratadas em nosso instituto pelo autor sênior entre 1º de janeiro de 2012 e 31 de dezembro de 2015, 41 pacientes atenderam aos critérios de inclusão (tipos B e C de Danis-Weber).

**Resultados** Todas as 41 fraturas fibulares distais cicatrizaram sem intercorrências, em uma média de 10,4 semanas (8–14 semanas) (Figuras 6 a 9) e sem complicações. A pontuação American Orthopaedic Foot & Ankle Society (AOFAS) média foi de 92,6 (86–100) em um período médio de acompanhamento de 31,5 meses (14–61 meses).

**Conclusões** Obtivemos excelentes resultados clínicos e radiológicos com uso de LCP retorcida de 3,5 mm como apoio posterior ao combinar as vantagens da placa antideslizante posterior e a LCP lateral.

### Palavras-chave

- ▶ fraturas de tornozelo
- ▶ fixação interna de fraturas
- ▶ fraturas ósseas
- ▶ fíbula
- ▶ placas ósseas

\* Study conducted at the Hinduja Hospital and Medical Research Centre, Veer Savarkar Marg, Mahim (West), Mumbai, Maharashtra, India.



## Introduction

Ankle fracture is one of the most common injuries encountered, more so because of the increasing incidence of osteoporosis and a more active elderly population.<sup>1-3</sup> The spectrum varies from a relatively stable isolated lateral malleolus fracture to unstable bimalleolar/trimalleolar fracture dislocations. Distal fibula fractures, although they may seem relatively innocuous, require a thorough clinical and radiological examination (external rotation stress test) to avoid overlooking medial ankle instability.<sup>4-7</sup> The importance of the lateral malleolus in stabilizing ankle injuries has been highlighted almost 40 years ago by Yablon et al.<sup>8</sup>

Studies have shown that the incidence of highly unstable pronation abduction injuries has increased.<sup>9</sup> Anatomic reduction and surgical stabilization have improved outcomes in displaced distal fibula fractures, thereby minimizing the risk of posttraumatic arthritis.<sup>10-13</sup> Traditionally, they have been fixed with an interfragmentary screw and a lateral neutralization plate or by posterior plating using the antiglide principle; with an increasing trend toward locking plates and newer anatomical precontoured plates; especially in osteoporotic fractures, where they offer greater pull out strength and a higher number of screws in the distal segment.<sup>10,14,15</sup> So far, there is no consensus over the ideal method of fixation.

We have used a twisted and contoured 3.5 mm locking compression plate (LCP) (Synthes, Westchester, PA, USA) as a posterior buttress plate for the management of distal fibula fractures. Theoretically, it combines the strength of an LCP with the biomechanical advantage of posterior antiglide plating. The present paper analyses the outcomes of this method of fixation.

## Materials and Methods

We retrospectively analyzed our data from 1<sup>st</sup> January 2012 to 31<sup>st</sup> December 2015 for patients with Danis-Weber types B and C distal fibular fracture, fixed with a 3.5 mm twisted LCP, with or without fixation/ repair of the medial malleolus/deltoid ligament and/or of the posterior malleolus and/or of the syndesmotom fixation and/or of the distal tibia by a single surgeon. We included only those patients with a minimum follow-up of 12 months. We excluded cases with Danis-Weber type A fracture, open injuries, and pediatric fractures (patients with an open physis). A total of 41 out of the 62 ankle fractures managed at our institute by the senior author met the inclusion criteria. Patient demography and fracture patterns were as described in ►Table 1.

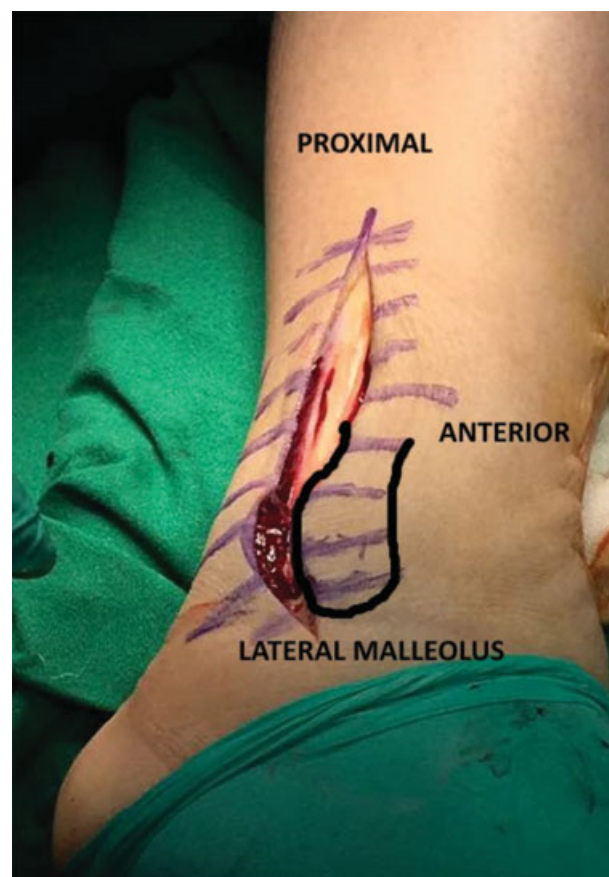
## Surgical Technique

Surgery was undertaken based on the clinical judgement of the senior author after analyzing the swelling and the condition of the soft tissue. A 5- to 7-cm longitudinal skin incision was made along the posterolateral aspect of the distal fibula and deepened up to the periosteum to obtain thick skin flaps (►Fig. 1) after inflating the tourniquet. The fracture site was exposed by sharp subperiosteal dissection, without exposing the peroneal tendons or tendon sheaths.

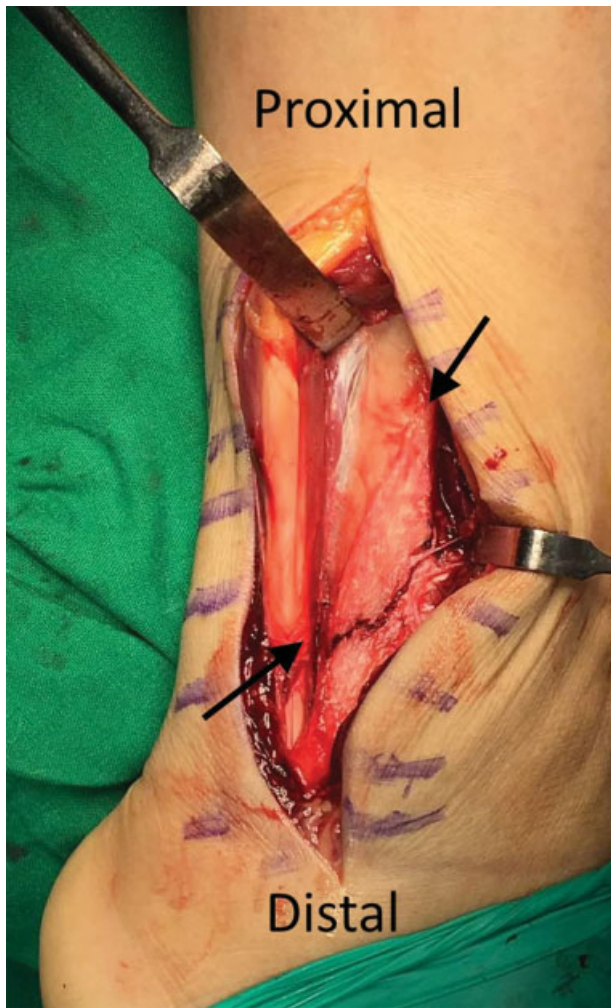
**Table 1** Patient demography and fracture pattern

Sex	Male: 17; Female: 24
Mean Age (years old) (range)	48 (26–76)
Side	Right: 20; Left: 21
Isolated lateral malleolus fracture	11
Bimalleolar fracture	18
Trimalleolar fracture	11
Distal tibia mortise with lateral malleolus fracture	1
Danis-Weber Type B	32
Danis-Weber Type C	9
Associated deltoid ligament injury	6
Associated syndesmotom injury	4

After anatomical reduction, a metallic template was twisted to match the contour of distal fibular anatomy where the lateral surface spirals posterolaterally in the lower one fourth to become continuous with the posterior groove of the lateral malleolus<sup>16</sup> (►Figs. 2 and 3). A 3.5mm LCP (Synthes, Westchester, PA, USA) of appropriate length was twisted with plate bending iron (Synthes, Westchester, PA, USA) so as to match the template with the distal part of the plate being twisted in a posterolateral direction (►Fig. 4). This ensured that the LCP was held along the lateral surface proximally

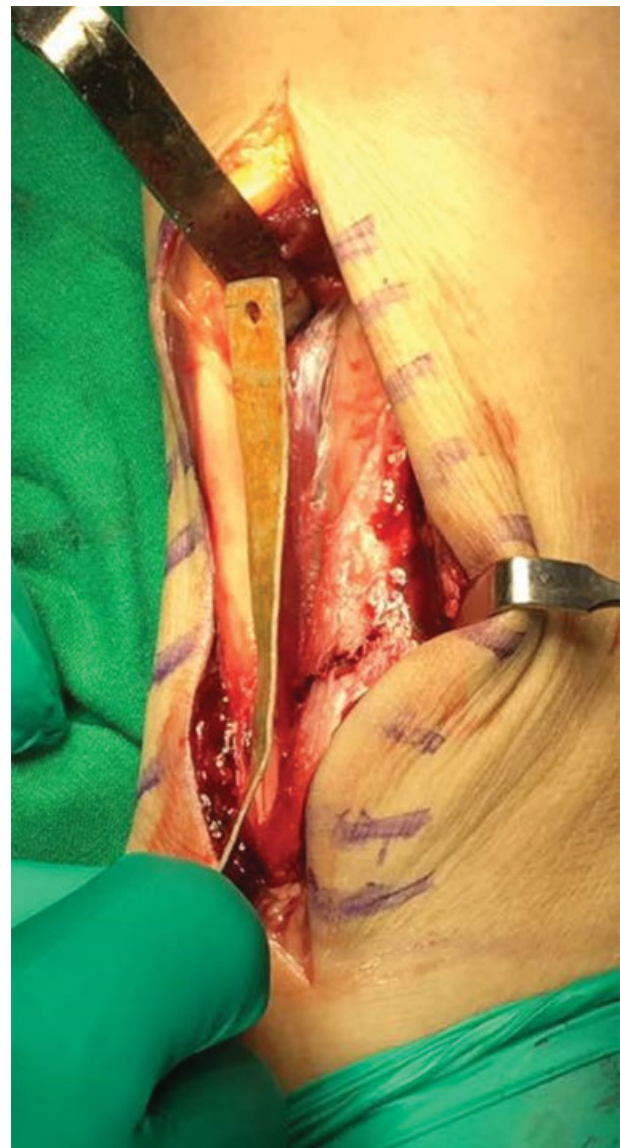

**Fig. 1** Posterolateral skin incision.



**Fig. 2** Spiral nature of distal fibula.

and the posterior surface of lateral malleolus distally with plate holding clamps, matching the distal fibular anatomy (► **Fig. 5**). The plate was used as a posterior buttress by first engaging the hole closest to the fracture site in the proximal fragment, abutting the plate to the lateral malleolus. The distal fragment was then fixed with bicortical screws in posterior to anterior direction; followed by bicortical lateral to medial screws in the proximal fragment. The syndesmosis was fixed with a tricortical 3.5mm screw through the plate where indicated. After fixation, we confirmed that the peroneal tendons and tendon sheaths were not in direct contact with the hardware. The fracture reduction, screw position and lengths were checked intraoperatively with an image intensifier. Medial fixation/repair and/or distal tibia plating were done where necessary. After layered wound closure and bandaging, all of the patients were given a posterior slab/sugar tong splint for 48 hours followed by an ankle brace for 4 to 6 weeks. Active ankle range of motion was encouraged after removal of the slab at 48 hours. Patients were mobilized nonweight bearing with a walker/crutches. Full body weight bearing was permitted according to the clinical and radiographic recovery.

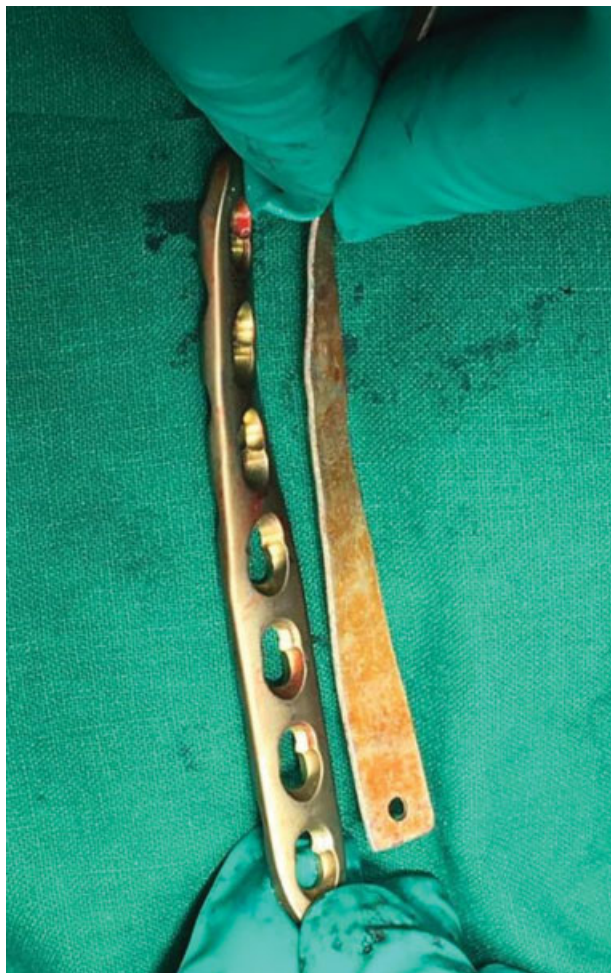

**Fig. 3** Template contoured to match the distal fibula anatomy.

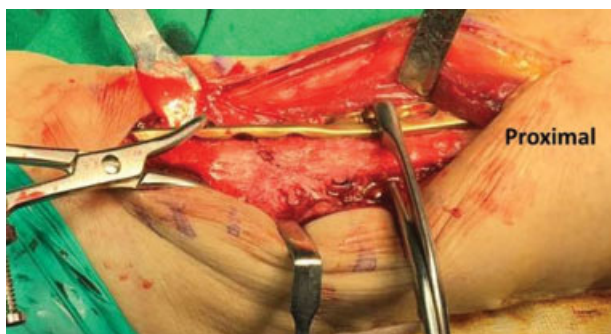### Clinical and Radiological Assessment

After confirmation of wound healing, patients were seen at 2 weeks, 6 weeks, 3 months, 6 months, 12 months, and annually for clinical and radiographical evaluation. Clinical and radiographic data was reviewed, and the functional results were evaluated with the American Orthopedic Foot and Ankle Society (AOFAS) hind foot-ankle score<sup>17,18</sup> at each stage until the last follow-up. Healing was defined by the presence of bony trabeculae crossing the fracture on radiographs with the absence of pain or tenderness at the fracture site. Postoperative complications and the time to bony union were recorded. Peroneal tendinopathy was suspected if there was associated pain and swelling along the peroneal tendons, along with lateral ankle pain during tendon excursion. Implant removal was done if the patients complained of hardware related discomfort or signs suggestive of peroneal tendinopathy or requested removal even in the absence of any such discomfort.





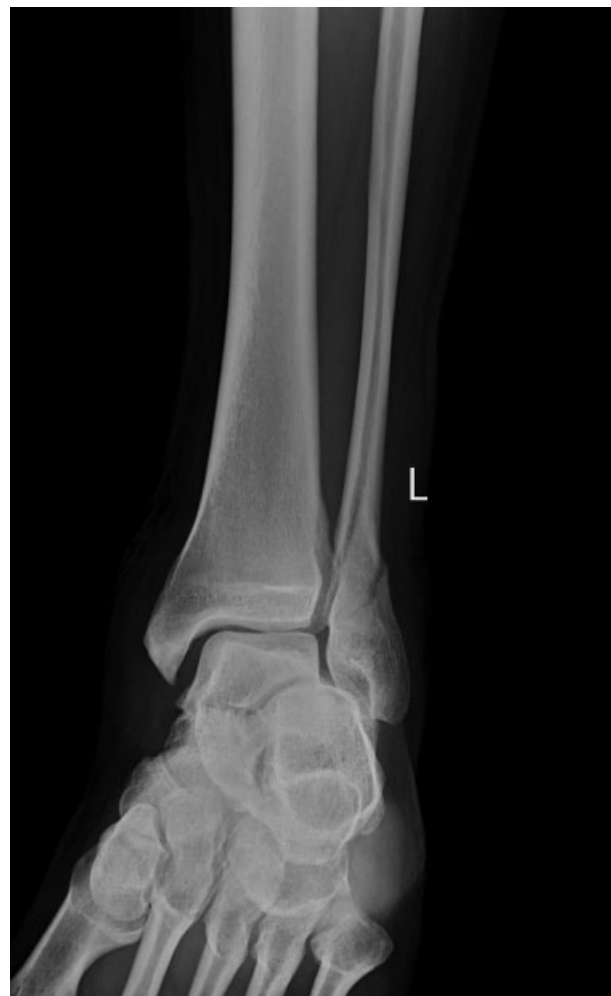**Fig. 4** Locking compression plate twisted to match the template.



**Fig. 5** Twisted locking compression plate applied after fracture reduction.

## Results

The medial malleolus was fixed with tension band wiring in 4 cases, and with cancellous screw fixation in 21 cases, while 2 were fixed with 3.5 mm medial distal tibia LCP. Posterior malleolus fixation was performed in two cases with cancellous screws. Deltoid ligament was reconstructed in two patients, while three of the four syndesmotic injuries were fixed with a syndesmotic screw.



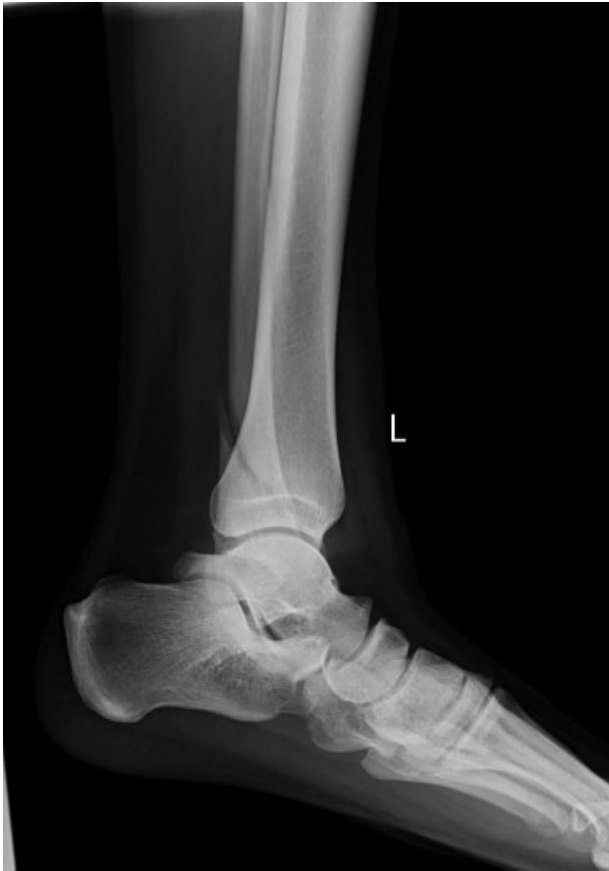**Fig. 6** Preoperative anteroposterior radiograph of a left ankle with Danis-Weber type B lateral malleolus fracture.

The mean length of distal fibula twisted LCP was 7.9 holes (6–12 holes). All 41 distal fibular fractures healed uneventfully, at a mean of 10.4 weeks (8–14 weeks) (→ **Figs. 6–9**). No soft tissue complication, skin necrosis, superficial or deep infection, or injury to the superficial peroneal nerve was observed. There were no cases with hardware related complications, peroneal impingement or nonunion. One patient insisted on plate removal 20 months after the primary surgery, in spite of no evidence of hardware-related discomfort or peroneal impingement. The mean AOFAS score was 92.6 (86–100) at a mean follow up of 31.5 months (14–61 months).

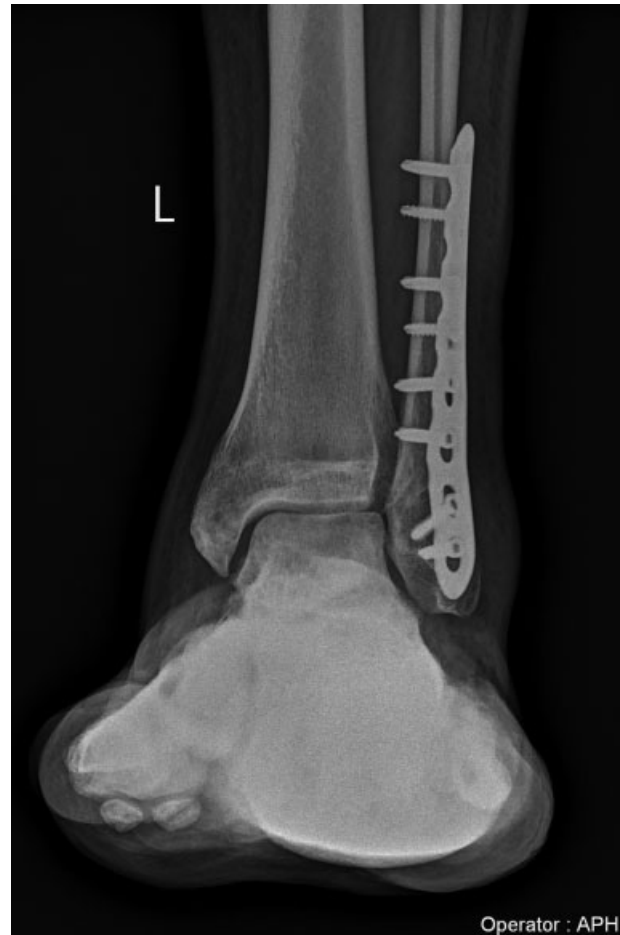## Discussion

The aim of ankle fracture fixation is to achieve stable anatomic reduction, thereby ensuring a good functional outcome by enabling early rehabilitation and reducing the long term sequelae of posttraumatic arthritis. The literature has shown successful outcomes for both intramedullary and extramedullary fixation strategies.<sup>3,10,19–23</sup>

Studies have shown that posterior antiglide fixation provides stronger fixation than lateral locking plates, which in



**Fig. 7** Preoperative lateral radiograph of a left ankle with Danis-Weber type B lateral malleolus fracture.



**Fig. 8** 34-month follow-up radiograph showing union.

turn are stronger than lateral nonlocking neutralization plates.<sup>24-28</sup> Locking plates are being increasingly used for periarticular and metaphyseal fracture fixation, including distal fibula fractures.<sup>14,26</sup> The posterolateral antiglide plate allowed for longer bicortical screws through the distal fragment, on account of its position, thereby improving fixation.<sup>28</sup>

The biomechanical superiority of posterior fibular antiglide plate compared with a lateral fibular plate, as well as the positive effect of locked compared with conventional plating in ankle fractures, has been demonstrated by various authors.<sup>9,15,25,27,28</sup> Switaj et al<sup>14</sup> have demonstrated the biomechanical superiority of anatomically contoured distal fibula plates, which offer a greater number of screws in the distal fragment over antiglide plates.

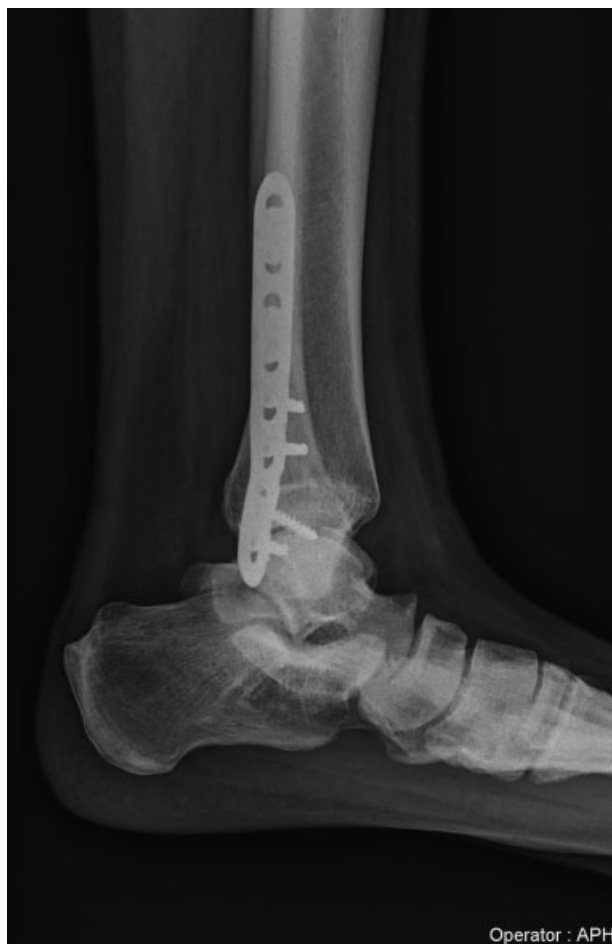These studies show that posterior placement of an LCP could possibly combine the advantages of an antiglide plate and an LCP. The author's technique of using a twisted LCP as a posterior buttress gives bicortical posterior to anterior fixation in the distal fragment, and lateral to medial fixation in the proximal fragment; thereby combining the advantages of both the posteriorly placed antiglide plating and a laterally placed LCP. This method conforms the LCP to the distal fibula where the lateral surface spirals posterolaterally and becomes the posterior surface of the lateral malleolus. We

had 100 percent union with an excellent mean AOFAS score in all our cases.

Peroneal tendinopathy secondary to posterior fixation has been described with varying incidences in the literature.<sup>23,24,29</sup> There were no cases of peroneal tendinopathy in our series, possibly due to sharp periosteal dissection, accurate measurement of the screw length and plates that did not traverse the peroneal groove or reach the distal tip.

The weakness of our study is its retrospective nature, with no control group. All varieties of ankle injuries, such as isolated medial malleolus, syndesmotic and distal tibial have been included, reducing the strength of the impression drawn. It is not a comparative analysis between various fixation strategies, which would enable us to statistically conclude the superiority of one method over the others, if any. Moreover, a biomechanical analysis would be required to analyze the strength of this construct and compare it with other modes of fixation.

Although this technique has been described in the literature, there are no long-term clinical studies analyzing the results. This is the first clinical study in the literature highlighting the outcomes of twisted plating for distal fibula fractures. A longer clinical follow-up of > 10 years will give us a better outcome analysis about our construct.



**Fig. 9** 34-month follow-up radiograph showing union.

## Conclusion

Numerous fixation strategies have been described for the management of distal fibula fractures, each one having their own merits and demerits. Our study highlights a technique that combines the advantages of posterior antiglide and lateral locked plating using a twisted, contoured 3.5 mm LCP, which has shown excellent clinical and radiological outcomes.

### Conflict of Interests

The authors have no conflict of interests to declare.

## References

- 1 Court-Brown CM, McBurnie J, Wilson G. Adult ankle fractures—an increasing problem? *Acta Orthop Scand* 1998;69(01):43–47
- 2 Kannus P, Palvanen M, Niemi S, Parkkari J, Järvinen M. Increasing number and incidence of low-trauma ankle fractures in elderly people: Finnish statistics during 1970–2000 and projections for the future. *Bone* 2002;31(03):430–433
- 3 Dingemans SA, Lodeizen OAP, Goslings JC, Schepers T. Reinforced fixation of distal fibula fractures in elderly patients; A meta-analysis of biomechanical studies. *Clin Biomech (Bristol, Avon)* 2016;36(01):14–20
- 4 DeAngelis NA, Eskander MS, French BG. Does medial tenderness predict deep deltoid ligament incompetence in supination-exter-

- nal rotation type ankle fractures? *J Orthop Trauma* 2007;21(04):244–247
- 5 McConnell T, Creevy W, Tornetta P 3rd. Stress examination of supination external rotation-type fibular fractures. *J Bone Joint Surg Am* 2004;86(10):2171–2178
- 6 Park SS, Kubiak EN, Egol KA, Kummer F, Koval KJ. Stress radiographs after ankle fracture: the effect of ankle position and deltoid ligament status on medial clear space measurements. *J Orthop Trauma* 2006;20(01):11–18
- 7 Schock HJ, Pinzur M, Manion L, Stover M. The use of gravity or manual-stress radiographs in the assessment of supination-external rotation fractures of the ankle. *J Bone Joint Surg Br* 2007;89(08):1055–1059
- 8 Yablon IG, Heller FG, Shouse L. The key role of the lateral malleolus in displaced fractures of the ankle. *J Bone Joint Surg Am* 1977;59(02):169–173
- 9 Hartwich K, Lorente Gomez A, Pyrc J, Gut R, Rammelt S, Grass R. Biomechanical analysis of stability of posterior antiglide plating in osteoporotic pronation abduction ankle fracture model with posterior tibial fragment. *Foot Ankle Int* 2017;38(01):58–65
- 10 Vance DD, Vosseller JT. Double plating of distal fibula fractures. *Foot Ankle Spec* 2017;10(06):543–546
- 11 Eckel TT, Glisson RR, Anand P, Parekh SG. Biomechanical comparison of 4 different lateral plate constructs for distal fibula fractures. *Foot Ankle Int* 2013;34(11):1588–1595
- 12 Milner BF, Mercer D, Firoozbakhsh K, Larsen K, Decoster TA, Miller RA. Bicortical screw fixation of distal fibula fractures with a lateral plate: an anatomic and biomechanical study of a new technique. *J Foot Ankle Surg* 2007;46(05):341–347
- 13 Klos K, Sauer S, Hoffmeier K, et al. Biomechanical evaluation of plate osteosynthesis of distal fibula fractures with biodegradable devices. *Foot Ankle Int* 2009;30(03):243–251
- 14 Switaj PJ, Wetzel RJ, Jain NP, et al. Comparison of modern locked plating and antiglide plating for fixation of osteoporotic distal fibular fractures. *Foot Ankle Surg* 2016;22(03):158–163
- 15 Zahn RK, Frey S, Jakubietz RG, et al. A contoured locking plate for distal fibular fractures in osteoporotic bone: a biomechanical cadaver study. *Injury* 2012;43(06):718–725
- 16 Spinner RJ, Howe BM. Leg. In: Standring S. *Gray's anatomy: the anatomical basis of clinical practice*. 41st ed. New York: Elsevier; 2016:1400–1417
- 17 Kitaoka HB, Alexander IJ, Adelaar RS, Nunley JA, Myerson MS, Sanders M. Clinical rating systems for the ankle-hindfoot, mid-foot, hallux, and lesser toes. *Foot Ankle Int* 1994;15(07):349–353
- 18 Ibrahim T, Beiri A, Azzabi M, Best AJ, Taylor CJ, Menon DK. Reliability and validity of the subjective component of the American Orthopaedic Foot and Ankle Society clinical rating scales. *J Foot Ankle Surg* 2007;46(02):65–74
- 19 Chiang CC, Tzeng YH, Lin CC, Huang CK, Chang MC. Minimally invasive versus open distal fibular plating for AO/OTA 44-B ankle fractures. *Foot Ankle Int* 2016;37(06):611–619
- 20 Rehman H, McMillan T, Rehman S, Clement A, Finlayson D. Intramedullary versus extramedullary fixation of lateral malleolus fractures. *Int J Surg* 2015;22:54–61
- 21 Huang Z, Liu L, Tu C, et al. Comparison of three plate system for lateral malleolar fixation. *BMC Musculoskelet Disord* 2014;15(01):1–9
- 22 Tsukada S, Otsuji M, Shiozaki A, et al. Locking versus non-locking neutralization plates for treatment of lateral malleolar fractures: a randomized controlled trial. *Int Orthop* 2013;37(12):2451–2456
- 23 Lamontagne J, Blachut PA, Broekhuysse HM, O'Brien PJ, Meek RN. Surgical treatment of a displaced lateral malleolus fracture: the antiglide technique versus lateral plate fixation. *J Orthop Trauma* 2002;16(07):498–502
- 24 Ahn J, Kim S, Lee JS, Woo K, Sung KS. Incidence of peroneal tendinopathy after application of a posterior antiglide plate for

- repair of supination external rotation lateral malleolar fractures. *J Foot Ankle Surg* 2016;55(01):90–93
- 25 Schaffer JJ, Manoli A 2nd. The antiglide plate for distal fibular fixation. A biomechanical comparison with fixation with a lateral plate. *J Bone Joint Surg Am* 1987;69(04):596–604
- 26 Bariteau JT, Fantry A, Blankenhorn B, Lareau C, Paller D, Digiovanni CW. A biomechanical evaluation of locked plating for distal fibula fractures in an osteoporotic sawbone model. *Foot Ankle Surg* 2014;20(01):44–47
- 27 Kim T, Ayturk UM, Haskell A, Miclau T, Puttlitz CM. Fixation of osteoporotic distal fibula fractures: A biomechanical comparison of locking versus conventional plates. *J Foot Ankle Surg* 2007;46(01):2–6
- 28 Minihane KP, Lee C, Ahn C, Zhang L-Q, Merk BR. Comparison of lateral locking plate and antiglide plate for fixation of distal fibular fractures in osteoporotic bone: a biomechanical study. *J Orthop Trauma* 2006;20(08):562–566
- 29 Ostrum RF. Posterior plating of displaced Weber B fibula fractures. *J Orthop Trauma* 1996;10(03):199–203