



Original Article

Epidemiological study on talus fractures^{☆,☆☆}



Marcos Hideyo Sakaki^{*}, Guilherme Honda Saito, Rafael Garcia de Oliveira, Rafael Trevisan Ortiz, Jorge dos Santos Silva, Túlio Diniz Fernandes, Alexandre Leme Godoy dos Santos

Instituto de Ortopedia e Traumatologia, Hospital das Clínicas, Faculdade de Medicina, Universidade de São Paulo (IOT-HCFMUSP), São Paulo, SP, Brazil

ARTICLE INFO

Article history:

Received 13 June 2013

Accepted 31 July 2013

Available online 5 August 2014

Keywords:

Talus

Epidemiology

Bone fractures

ABSTRACT

Objective: to analyze the characteristics of patients with talus fractures and the injuries that they present.

Methods: retrospective analysis on patients hospitalized in the Institute of Orthopedics and Traumatology, Hospital das Clínicas, School of Medicine of the University of São Paulo, between 2006 and 2011, with talus fractures. Patient profile parameters, risk factors, fracture characteristics, treatment data and acute complications were analyzed.

Results: analysis on 23 cases showed that men were more affected than women, with a ratio of 4.8:1. The most frequent trauma mechanism was traffic accidents, followed by falls from a height. The most frequent type of fracture was at the neck of the talus, with 17 cases. Among the 23 cases, seven had peritalar dislocation at the time of presentation, four had exposed fractures and 11 presented other associated fractures. The mean length of time between the trauma and the definitive treatment was six days, while the mean length of hospital stay was 11 days. Three patients presented acute postoperative complications.

Conclusion: talus fractures occurred most commonly in the region of the talar neck and most frequently in young males who suffered high-energy trauma. In almost half of the cases, there were other associated fractures. The length of hospital stay was 11 days.

© 2014 Sociedade Brasileira de Ortopedia e Traumatologia. Published by Elsevier Editora Ltda. All rights reserved.

[☆] Please cite this article as: Sakaki MH, Saito GH, de Oliveira RG, Ortiz RT, Silva JS, Fernandes TD, et al. Estudo epidemiológico das fraturas do tálus. Rev Bras Ortop. 2014;49:334-339.

^{☆☆} Work developed at the Institute of Orthopedics and Traumatology, Hospital das Clínicas, University of São Paulo Medical School (IOT-HCFMUSP), São Paulo, SP, Brazil.

^{*} Corresponding author.

E-mail: sakakimh@terra.com.br (M.H. Sakaki).

<http://dx.doi.org/10.1016/j.rboe.2013.07.002>

2255-4971/© 2014 Sociedade Brasileira de Ortopedia e Traumatologia. Published by Elsevier Editora Ltda. All rights reserved.

Estudo epidemiológico das fraturas do tálus

R E S U M O

Palavras-chave:
Tálus
Epidemiologia
Fraturas ósseas

Objetivo: Analisar as características dos indivíduos e das lesões encontradas em pacientes com fraturas de tálus.

Métodos: Análise retrospectiva dos pacientes internados no Instituto de Ortopedia e Traumatologia do Hospital das Clínicas da Faculdade de Medicina da Universidade de São Paulo de 2006 a 2011 com fratura de tálus. Foram estudados parâmetros associados ao perfil do paciente e fatores de risco, características da fratura, dados do tratamento e complicações agudas.

Resultados: A análise dos 23 casos mostrou que os homens foram mais afetados do que as mulheres, com uma relação de 4.8:1. O mecanismo de trauma mais frequente foram os acidentes de trânsito, seguido pelas quedas de altura. O tipo de fratura mais frequente foi a do colo do tálus, com 17 casos. Dos 23 casos, sete apresentavam luxação peritalar no momento da apresentação, quatro tinham fratura exposta e 11 apresentavam outras fraturas associadas. O tempo médio entre o trauma e o tratamento definitivo foi de seis dias, enquanto o tempo médio de permanência hospitalar foi de 11 dias. Houve três pacientes que apresentaram complicações pós-operatórias agudas.

Conclusão: A fratura do tálus foi mais comum na região do colo e mais frequente em jovens do gênero masculino que sofreram traumatismos de alta energia. Em quase metade dos casos houve fraturas associadas e o tempo de permanência hospitalar foi de 11 dias.

© 2014 Sociedade Brasileira de Ortopedia e Traumatologia. Publicado por Elsevier Editora Ltda. Todos os direitos reservados.

Introduction

Talus fractures are known to be difficult and challenging pathological conditions. There are several factors contributing towards this reputation: the incidence of complications with severe functional limitation, the unusual anatomy of the talus, the great variability of fracture patterns and the role of the talus in the functionality of the lower limb.¹ However, over recent decades, surgical techniques, synthesis materials and even knowledge relating to the biology of bone repair and vascular supply of the talus have evolved greatly and have changed the panorama of this type of fracture.

The diagnosis is made initially by means of radiographic evaluation, which includes a series of view of the ankle (anteroposterior, lateral and mortise) and a series of view of the foot (anteroposterior, lateral and oblique). The view described by Canale and Kelly^{2,3} makes it possible to observe the medial aspect of the talar neck well. Furthermore, the true lateral view of the subtalar joint and the oblique view of the talus can provide additional information about the fracture.⁴ Computed tomography plays an important role in diagnosing talar fractures: it has the capacity to detect fractures that are difficult to view on ordinary radiographs and provides a good view of the talar joint congruence, as well as contributing towards surgical planning.⁵ Magnetic resonance imaging has an important role in viewing osteonecrosis of the talus, which is one of the commonest and most feared complications of this type of fracture.^{6,7}

The classification of talar fractures takes into account the location (body, neck, head and processes),⁸ the associated dislocations (subtalar, ankle and talonavicular) and the degree

of comminution. The two classifications most used are the Hawkins classification,⁹ which is used to categorize talar neck fractures, and the AO classification.¹⁰

The treatment should generally be aimed towards rapidly reestablishing joint congruence and towards achieving anatomical reduction of the fracture, in view of the high rates of osteonecrosis and associated fractures. Non-deviated fractures and those without joint incongruence can be treated non-surgically, whereas deviated fractures usually require open reduction. Nevertheless, closed reduction can be attempted and may be particularly useful as an initial step.¹¹⁻¹⁴

Despite the evolution achieved over recent years, the complication rates remain extremely high. The osteonecrosis rate in talar neck fractures ranges from 21 to 58%,^{3,9} while in the talar body, 88% of the patients present evidence of osteonecrosis and/or post-traumatic arthritis.¹⁵⁻¹⁹

There are very few studies in the Brazilian literature on the epidemiology of talar fractures. Debieux et al.²⁰ studied 387 patients who had suffered motorcycle accidents in the municipality of São Paulo between January 2001 and July 2002 and observed that the commonest injuries, in order of frequency, were wounds (31.8%), bruises (15.8%) and fractures (8.7%). The most frequent location for the fractures was the foot, in 16.0% of the patients with fractures, but that study did not specify which bone was most affected.

Fonseca Filho et al.²¹ studied 52 cases of talar fracture between February 1972 and March 1995. They analyzed age, gender, occupation, laterality, trauma mechanism, exposure, associated injuries and fracture classification. They concluded that talar fractures were most frequent in young male adults; generally unilateral and closed; and most commonly observed

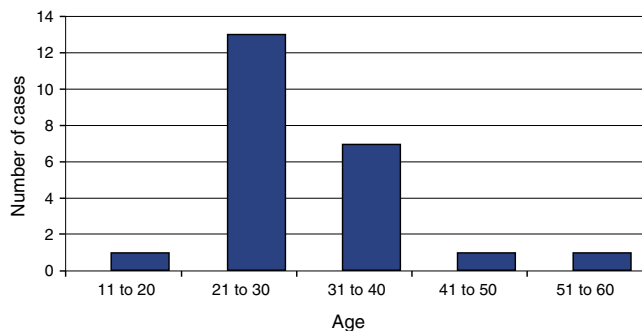


Fig. 1 – Age group.

in the neck and body regions. Moreover, they found that fractures of the ipsilateral medial malleolus were the commonest associated injury, present in 21.2% of the cases.

Because of the scarcity of information regarding the epidemiology of talar fractures in our setting, we decided to conduct the present study.

Objective

To evaluate the characteristics of patients and their injuries, among those admitted to hospital for surgical treatment of talar fractures between 2006 and 2011, at the Institute of Orthopedics and Traumatology, Hospital das Clínicas, University of São Paulo Medical School.

Materials and methods

The medical files of all the patients admitted to the hospital with fractures of the foot and ankle between 2006 and 2011 were surveyed. Through making a detailed review of these medical files, 23 cases of talar fractures that were treated surgically were identified.

The parameters analyzed were: age; gender; laterality; exposure; smoking; trauma mechanism; type of fracture; classification; associated injuries; treatment administered at the emergency service; definitive treatment; length of time between the trauma and the definitive treatment; length of hospital stay; and acute postoperative complications.

Results

Among the 23 patients evaluated, the ration of men to women was 4.8:1 (19 men and four women). Their mean age was 30.4 years, ranging from 18 to 49 years (Fig. 1). The right side was affected in 13 patients and the left side in 10. Among these 23 patients, three were smokers (incidence of 13%).

The most frequent trauma mechanism was falling from a height, with eight cases, followed by motorcycle and car accidents, with five each. The other mechanisms were torsional trauma, with three cases, and sports trauma, with two (Fig. 2).

In relation to the type of fracture, talar neck fractures were the most prevalent type, with 17 cases. There were also three cases of fractures of the body, two of the talar processes and

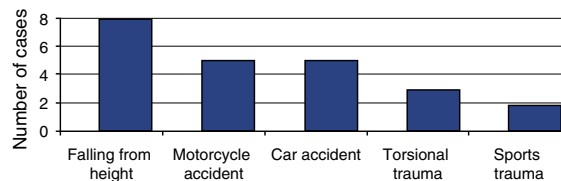


Fig. 2 – Trauma mechanism.

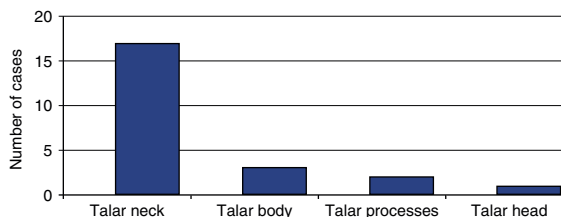


Fig. 3 – Fracture location.

one of the head (Fig. 3). Out of the 17 fractures of the talar body, 16 were classified as Hawkins 2 and one as Hawkins 3.

Four patients suffered an exposed fracture (17.4%), of which two were classified as Gustilo type II, one as type IIIA and one as type IIIB.

Out of the 23 cases analyzed, seven (30.4%) had peritalar dislocation at the time of presentation.

In relation to treatment at the emergency service, 16 cases were immobilized by means of a plaster cast splint covering the foot and lower leg. Among the seven cases with associated dislocation, it was possible to reduce the dislocation by means of closed maneuvers in five cases, while the other two cases underwent surgical reduction followed by placement of an external fixator.

The definitive treatment consisted of osteosynthesis in 20 cases and resection of the intra-articular bone fragments in the other three patients.

The mean length of time between the trauma and the definitive treatment was six days, ranging from 0 to 29 (Fig. 4). The mean length of hospital stay was 11 days, ranging from 2 to 44 (Fig. 5).

Associated injuries were present in 11 patients (47.8%): four with malleolar fractures, two with fractures of leg bones, two with fractures of the base of the fifth metatarsal, two with fractures of the lumbar spine, two with acetabular fractures,

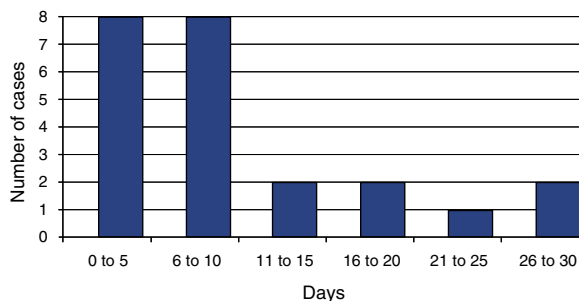


Fig. 4 – Length of time between the trauma and the definitive treatment.

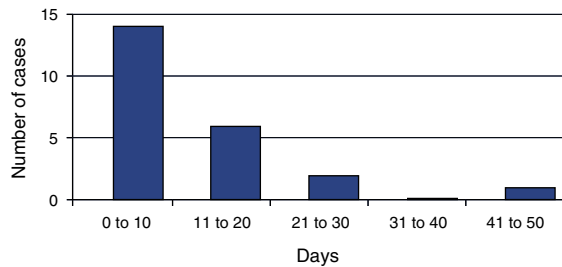


Fig. 5 - Length of hospital stay.

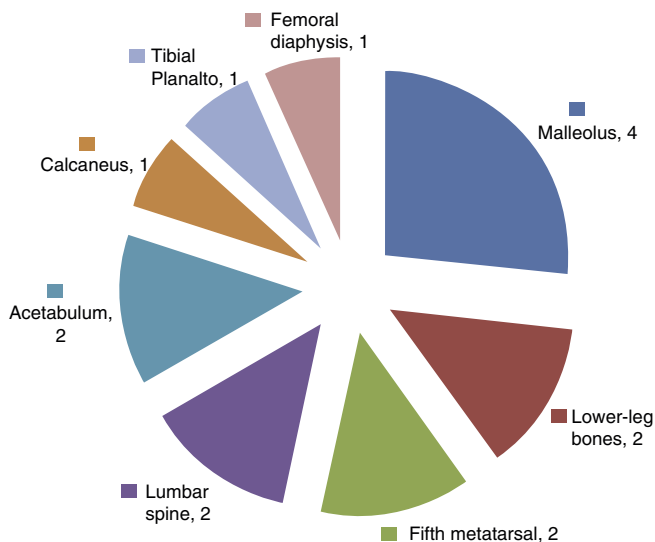


Fig. 6 - Associated fractures.

one with a calcaneal fracture, one with a tibial plateau fracture and one with a femoral diaphysis fracture (Fig. 6).

In relation to acute complications, there were three cases of postoperative infection: one associated with compartmental syndrome of the foot consequent to a closed fracture of the talar neck; one resulting from a Gustilo IIIB exposed fracture that evolved with loss of the microsurgical flap that had been constructed to cover it; and one due to a Gustilo II fracture associated with a lumbar spine fracture.

Discussion

Over this five-year period, 23 patients with talar fractures were operated at our service, i.e., an incidence of 4.6 cases per year, while Fonseca Filho et al.²¹ treated 52 cases over 23 years, which was a mean of 2.3 per year. Since both of these studies were conducted in large-sized hospitals that provide tertiary-level orthopedic traumatology care, it is evident that this type of fracture has low frequency of occurrence within the total number of fractures that are treated surgically. This means that for orthopedists who provide fracture treatment care in the various centers in Brazil, a long time is needed for them to acquire experience in therapeutic management for talus fractures. Medical centers of smaller size will probably have great difficulty in training traumatologists with the skills to operate

on this type of fracture. The study by Fonseca Filho et al.²¹ covered a time period (from 1972 to 1995) during which the city of São Paulo had not yet felt the effects of the growing numbers of motorcycle accidents that have been seen over the last decade. The present study thus serves to update the epidemiology of talus fractures, with data relating to a more recent period (from 2006 to 2011).

The greater prevalence of male patients (4.8:1) and young patients (mean of 30.4 years) shows the importance of correct treatment for this type of fracture, which presents high rates of late complications, with sequelae that are often incapacitating and may require arthrodesis of the ankle and hindfoot to control these conditions. Comparing our findings with those of Fonseca Filho et al.²¹ the mean age in their study (31 years and 4 months) was very similar, but there was greater predominance of male gender in our study (4.8 men for each woman versus 2.9 men for each woman in the earlier study). This finding may have been related to the greater exposure of the young male population to traffic accidents.

In 18 cases (78.3%), high-energy trauma was responsible for the fracture. Ten fracture cases (43.8% of the total) resulted from traffic-related accidents, which was similar to the findings of Fonseca Filho et al.²¹ (42.3%). Likewise, falling from a height was the second most frequent mechanism, and this, together with the traffic accidents, accounted for 78.3% of our cases and 71.2% of those of Fonseca Filho et al.²¹ These data serve to guide the choice of preventive measures against talus fractures, such as stiff boots that limit dorsal flexion movements of the foot, which is the mechanism relating to these fractures. Such boots, for motorcyclists and people working at heights, would need to be sturdy and have high impact absorption capacity.

Although smoking has been correlated with complications in the evolution of fractures and surgical procedures on feet, the three patients who were smokers did not present any postoperative complications up to the time of discharge from hospital. We believe that if a larger number of patients were to be studied, the negative influence of smoking on surgical treatment of talus fractures might become evident.²²

Central fractures (of the neck and body) were much more frequent than other types and accounted for 87.0% of the 23 cases studied, which is similar to what was described by Fonseca Filho et al.²¹ (78.8%). This prevalence may have resulted from the fact that a large proportion of peripheral fractures of the talus (including those of the posterior and lateral processes) often go unnoticed and, even when correctly diagnosed, frequently can be treated non-operatively.^{1,11}

The high incidence of Hawkins type 2 fractures (16 out of 17 cases) and the absence of type 1 fractures contrasts with what was found by Fonseca Filho et al.²¹ who had nine cases of Hawkins 2 fractures and five of Hawkins 1 fractures among their total of 21 cases of talar neck fractures. This difference was probably due to our use of multislice computed tomography for fracture investigation, for all of our patients. This technology was introduced at the end of the 1990s and enables detailed evaluation of fractures and small displacements, but it was not available at the time of the study by Fonseca Filho et al.²¹ Moreover, in their study, although it was stated that "axial computed tomography was performed

whenever possible”, the total number of patients who underwent this examination was not stated.

The incidence of exposed fractures was 17.4%, and this rate was practically identical to what was found by Fonseca Filho et al.²¹ which was 17.3%. It should be highlighted that, in our survey, two of the four cases of exposed fracture evolved with acute infection: one with Gustilo II and the other with IIIB.

Among the seven cases of fractures associated with dislocation, two (28.6%) required surgical reduction of the dislocation at the emergency service, one of these was the case of Hawkins type 3, and this also presented Gustilo IIIB exposure. Except for these two cases operated at the emergency service, all of the others were immobilized at the emergency service using plaster cast splints and none of them evolved with formation of phlyctenae before the definitive surgical treatment. Although high-energy trauma caused the majority of these fractures, nonuse of external fixation as a means of immobilization before the operation did not give rise to soft-tissue complications, in comparison with what occurs in cases of the fractures of the tibial pilon. If a central fracture of the talus is intracapsular, this may contribute towards non-infiltration of bleeding into the surrounding tissues and may thus lead to less elevation of the adjacent pressure levels.

The mean waiting time for the definitive surgical treatment was six days and mean length of hospital stay was 11 days. The fact that 47.8% of the patients presented associated fractures contributed towards making these periods long and had a direct influence on the cost of treatment. Although blood irrigation of the talus is critical in cases of talar neck fractures with displacement, the wait for the definitive surgical treatment seemed not to increase the risk of avascular necrosis of the talar body. This complication is much more connected with the length of time between the accident and the reduction of the dislocation, when the latter is present.^{19,23} In any event, measures that might reduce the length of the preoperative period should be sought in this type of patient.

Fifteen associated fractures (Fig. 6) were found in 11 patients (47.8%), which showed the high-energy trauma to which these patients were subjected. This rate was practically identical to what was found in the study by Fonseca Filho et al.²¹ (46.2%).

From combined analysis on all these results, we can say that although talus fractures epidemiologically represent a small proportion of the total number of fractures treated in orthopedic hospitals, their importance lies in the fact that they affect young individuals at the peak of their work activities, often with associated injuries, thus necessitating long hospital stays. The pattern of talus fractures is severe, with a high risk of complications such as avascular necrosis. Preventive measures should be created based on the commonest mechanisms that have been identified: traffic accidents and falling from a height.

Conclusions

Patients with talus fractures who were attended and operated in a tertiary-level hospital in the city of São Paulo were young, with a mean age of 30.4 years. Most of them were male (4.8:1) and they had suffered traffic accidents or falls from a height.

The talar neck was the region most affected and, at the time when the cases were first attended, peritalar dislocation was present in 30.4% and the talus fractures were exposed in 17.4%. Almost half of these patients presented associated fractures and the mean length of hospital stay was 11 days.

Conflicts of interest

The authors declare no conflicts of interest.

REFERENCES

- Murphy GA. Talar fractures. In: Campbell's., editor. *Operative orthopaedics*. Philadelphia: Mosby Elsevier; 2007. p. 4851-66.
- Canale ST. Fractures of the neck of the talus. *Orthopedics*. 1990;13(10):1105-15.
- Canale ST, Kelly Jr FB. Fractures of the neck of the talus long-term evaluation of seventy-one cases. *J Bone Joint Surg Am*. 1978;60(2):143-56.
- Ebraheim NA, Patil V, Frisch NC, Liu X. Diagnosis of medial tubercle fractures of the talar posterior process using oblique views. *Injury*. 2007;38(11):1313-7.
- Chan G, Sanders DW, Yuan X, Jenkinson RJ, Willits K. Clinical accuracy of imaging techniques for talar neck malunion. *J Orthop Trauma*. 2008;22(6):415-8.
- Kerr R, Forrester DM, Kingston S. Magnetic resonance imaging of foot and ankle trauma. *Orthop Clin N Am*. 1990;21(3):591-601.
- Munk PL, Vellet AD, Levin MF, Helms CA. Current status of magnetic resonance imaging of the ankle and the hindfoot. *Can Assoc Radiol J*. 1992;43(1):19-30.
- Inokuchi S, Ogawa K, Usami N. Classification of fractures of the talus: clear differentiation between neck and body fractures. *Foot Ankle Int*. 1996;17(12):748-50.
- Hawkins LG. Fractures of the neck of the talus. *J Bone Joint Surg Am*. 1970;52(5):991-1002.
- Fracture and dislocation compendium Orthopaedic Trauma Association Committee for Coding and Classification. *J Orthop Trauma*. 1996;10 Suppl. 1:1-154.
- Sanders DW. Talus fractures. In: Rockwood CA, Green DP, editors. *Fractures in adults*. Philadelphia: Lippincott Williams & Wilkins; 2010. p. 2022-63.
- Adelaar RS. The treatment of complex fractures of the talus. *Orthop Clin N Am*. 1989;20(4):691-707.
- Sangeorzan BJ, Wagner UA, Harrington RM, Tencer AF. Contact characteristics of the subtalar joint: the effect of talar neck misalignment. *J Orthop Res*. 1992;10(4):544-51.
- Daniels TR, Smith JW, Ross TI. Varus malalignment of the talar neck its effect on the position of the foot and on subtalar motion. *J Bone Joint Surg Am*. 1996;78(10):1559-67.
- Vallier HA, Nork SE, Benirschke SK, Sangeorzan BJ. Surgical treatment of talar body fractures. *J Bone Joint Surg Am*. 2003;85(9):1716-24.
- Lindvall E, Haidukewych G, DiPasquale T, Herscovici Jr D, Sanders R. Open reduction and stable fixation of isolated, displaced talar neck and body fractures. *J Bone Joint Surg Am*. 2004;86(10):2229-34.
- Sanders DW, Busam M, Hattwick E, Edwards JR, McAndrew MP, Johnson KD. Functional outcomes following displaced talar neck fractures. *J Orthop Trauma*. 2004;18(5):265-70.

18. Vallier HA, Nork SE, Barei DP, Benirschke SK, Sangeorzan BJ. Talar neck fractures: results and outcomes. *J Bone Joint Surg Am.* 2004;86(8):1616-24.
19. Elgafy H, Ebraheim NA, Tile M, Stephen D, Kase J. Fractures of the talus: experience of two level 1 trauma centers. *Foot Ankle Int.* 2000;21(12):1023-9.
20. Debieux P, Chertman C, Mansur NSB, Dobashi E, Fernandes JA. Musculoskeletal injuries in motorcycle accidents. *Acta Ortop Bras.* 2010;18(6):353-6.
21. Fonseca Filho FF, Santin RAL, Ferreira RC, Sanmartin M, Guerra A. Epidemiological aspects of fractures of the talus. *Rev Bras Ortop.* 1996;31(6):481-4.
22. Kwiatkowski TC, Hanley Jr EN, Ramp WK. Cigarette smoking and its orthopedic consequences. *Am J Orthop (Belle Mead NJ).* 1996;25(9):590-7.
23. Frawley PA, Hart JA, Young DA. Treatment outcome of major fractures of the talus. *Foot Ankle Int.* 1995;16(6):339-45.