





Evaluation of Histological Properties of Human Meniscal Grafts Stored in a Tissue Bank*

Avaliação das propriedades histológicas de enxertos meniscais humanos armazenados em banco de tecido

Alfredo dos Santos Netto¹ Uri Antebi² Carolina Esteves de Morais³ Leonardo Sementilli³
 Nilson Roberto Severino¹ Ricardo de Paula Leite Cury¹

¹Department of Orthopedics and Traumatology, Faculdade de Ciências Médicas da Santa Casa de São Paulo, São Paulo, SP, Brazil

²Musculoskeletal Tissue Bank, Irmandade da Santa Casa de Misericórdia de São Paulo, São Paulo, SP, Brazil

³Pathological Anatomy, Irmandade da Santa Casa de Misericórdia de São Paulo, São Paulo, SP, Brazil

Address for correspondence Alfredo dos Santos Netto, MD, Rua Doutor Cesário Mota Júnior, 112, Vila Buarque, São Paulo, SP, 01221-020, Brazil (e-mail: alfredo.santos@fcmstacasasp.edu.br).

Rev Bras Ortop 2020;55(6):778–782.

Abstract

Objectives The present paper aims to evaluate and compare the histological features of fresh and frozen menisci stored in a tissue bank for 1 month and for 5 years.

Methods The meniscal grafts were subjected to a histological study. A total of 10 menisci were evaluated; 2 were frozen for 5 years, 4 were frozen for 1 month, and 4 were fresh, recently harvested specimens. Histological properties were evaluated in sections stained with hematoxylin and eosin and Masson trichrome methods.

Results The menisci frozen for 1 month showed partially preserved collagen fiber structure and no significant hydropic tissue degeneration. The menisci frozen for 5 years presented an evident dissociation of collagen fibers and multiple foci of hydropic degeneration.

Discussion Degeneration was much more significant in menisci stored for 5 years, indicating that a long freezing period results in substantial progression of tissue deterioration. This may suggest that the 5-year period, considered the maximum time for graft storage before transplant, is too long.

Conclusion Grafts stored for 1 month showed a slight degenerative change in collagen fibers, whereas menisci frozen for 5 years presented significant tissue degeneration.

Keywords

- ▶ meniscus
- ▶ tibial menisci
- ▶ transplantation
- ▶ tissue bank

Resumo

Objetivos Avaliar e comparar as características histológicas de meniscos frescos e meniscos congelados armazenados em banco de tecidos por 1 mês e por 5 anos.

* Study performed by the Knee Group from the Departamento de Ortopedia e Traumatologia, Irmandade da Santa Casa de Misericórdia de São Paulo - "Pavilhão Fernandinho Simonsen", São Paulo, SP, Brazil.

Palavras-chave

- ▶ transplante
- ▶ menisco
- ▶ meniscos tibiais
- ▶ banco de tecidos

Métodos Foi feito um estudo histológico com enxertos meniscais. Avaliamos 10 meniscos, sendo 2 que ficaram armazenados sob congelamento por 5 anos, 4 armazenados congelados por 1 mês, e 4 frescos, recém captados. Foram feitos cortes histológicos corados com hematoxilina e eosina e Tricrômico de Masson, para avaliação das propriedades histológicas.

Resultados Os meniscos congelados por 1 mês apresentaram preservação parcial da estrutura das fibras colágenas, sem degeneração hidrópica significativa do tecido. Nos meniscos congelados por 5 anos, observamos dissociação evidente das fibras colágenas, com presença de múltiplos focos de degeneração hidrópica.

Discussão Encontramos degeneração bem mais significativa nos meniscos armazenados por 5 anos, o que indica que o longo período de congelamento leva à progressão significativa da degeneração do tecido. Isto pode sugerir que o período de 5 anos, considerado período máximo que o enxerto pode permanecer armazenado antes de ser transplantado, é um período muito longo.

Conclusão Nos enxertos armazenados por 1 mês, existiu apenas discreta alteração degenerativa das fibras colágenas, enquanto que nos meniscos com 5 anos de congelamento foi observada degeneração significativa do tecido.

Introduction

Treatment of meniscal injuries evolved continuously over the past few decades. Meniscal injury suture is the technique of choice to treat unstable meniscus damages in favor of a partial or total meniscectomy because it spares meniscal tissue.^{1,2} Unfortunately, not all meniscal injuries can be repaired, especially if extensive tissue damage has occurred.^{3,4}

Patients usually experience a period of pain relief after a meniscectomy; over time, however, complaints can return, accompanied by a recurrent joint effusion mainly related to impact activities. In young, active patients, knee pain after meniscectomy can be a challenge.⁴ Homologous meniscal transplantation is a therapeutic option for young, active patients who have undergone meniscectomy and present activity-limiting symptoms.³

The success of homologous meniscal transplantation depends on a number of factors, including graft storage and availability. The most used preservation method is freezing of fresh menisci.^{3,5} According to the standards set forth by the Brazilian National Sanitary Surveillance Agency (ANVISA, in the Portuguese acronym) and the Ministry of Health, the meniscal tissue can remain stored in a tissue bank for 5 years until transplantation.⁶

Few studies have compared the histological properties of menisci stored for < 1 year or up to 5 years to assess whether biological features change significantly. Our objective was to compare the histological properties of fresh, nonfrozen meniscal grafts and frozen menisci stored for 1 month or 5 years in a tissue bank.

Material and Method

Meniscal grafts stored in the tissue bank of our institution were submitted to a histological study. A total of 10 meniscal grafts were evaluated. Two grafts remained stored, under freezing at - 80°C, in the tissue bank for 5 years;

another 4 grafts were stored, also frozen at -80°C, for 1 month; and another 4 grafts were studied while fresh, right after harvest. All of the grafts included in the study were taken from donors, whose families allowed their use for both transplantation and research purposes according to a Donation Term filled in before harvesting. The present study was approved by the Ethics Committee in Research from our institution.

The menisci were sent to the Department of Pathological Anatomy in 10% formaldehyde for evaluation of their histological properties and comparison with fresh, nonfrozen, recently harvested menisci.

The menisci were embedded in paraffin and sectioned in a rotating microtome at 5 µm thickness. Two slides were made for each of the 10 menisci; 1 sample was obtained through a perpendicular section at the transition between the anterior horn and the meniscus body, whereas the other sample was obtained through a perpendicular section at the posterior horn region. For all 20 samples, tissue was obtained from both central and peripheral meniscal regions.

The samples were stained with hematoxylin-eosin (H&E), which is the standard staining for histological evaluation of nucleus, cytoplasm and tissue fundamental amorphous substance, and with Masson trichrome, a histochemistry method to analyze collagen fibers and complement the H&E assessment. Analysis was carried out by counting random points on each region of the meniscus and recording the coincident points on chondrocytes and fibroblasts/fibrocytes, under 10x magnification. The expressed results assessed the distribution and cell viability in these two regions, as well as the integrity of fibrocartilaginous tissue.

Results

When compared with fresh, nonfrozen, recently harvested meniscal tissue, menisci frozen for 1 month showed partial

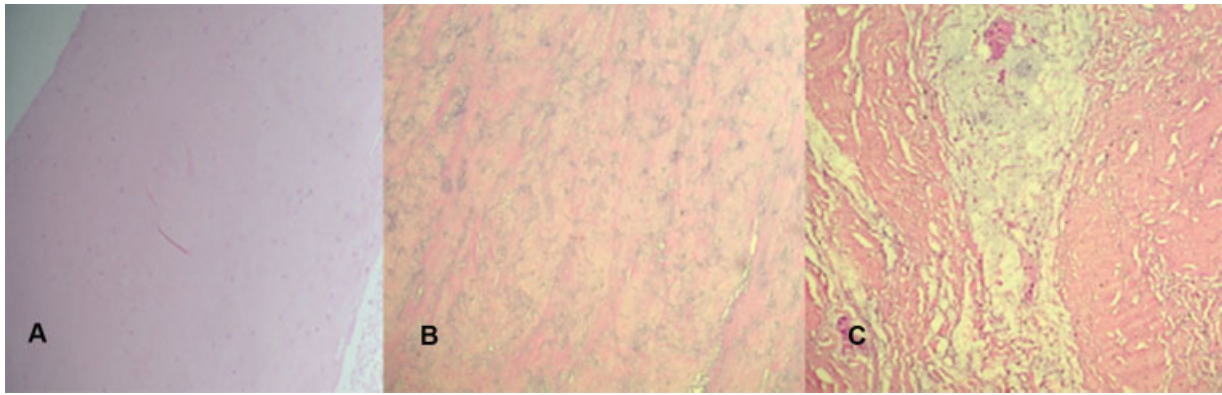


Fig. 1 (A) Fresh meniscus with its usual eosinophilic color. (B) Meniscus preserved for 1 month presenting basophilic discoloration and collagen fibers fragmentation. (C) Meniscus preserved for 5 years showing more accentuated changes, extensive hyaline degeneration and interstitial accumulations due to edema. (Hematoxylin & Eosin, 10x magnification).

structural disorganization of their collagen fibers, which were more compact in the central portion and presented a slight dissociation at the periphery, but no significant hydropic tissue degeneration. A change in basophilic appearance (hematoxylin color) revealed tissue degeneration. Two of these menisci presented collagen fibers condensation and homogenization, while the other two showed slight fragmentation of collagen fibers, with the formation of small vacuolized areas of hydropic aspect.

The menisci frozen for 5 years showed more significant changes, resulting in evident dissociation of collagen fibers throughout their length and the presence of multiple foci of hydropic degeneration, sometimes forming vacuolar accumulations (→ **Figures 1** and **2**).

Discussion

Human meniscus transplantation is no longer considered an experimental treatment, since several clinical studies, with hundreds of cases and a high percentage of good and excellent outcomes, have been published in the international literature.⁷⁻¹⁰ The ideal candidate for meniscal transplantation is an active patient, < 50 years old, with an aligned limb, a stable knee, who underwent a total or subtotal meniscec-

tomy, and presents with pain in the involved knee compartment and no significant degenerative changes.³

Several factors make homologous meniscal transplantation a technical and logistical challenge, including graft storage and availability, costs, risk of disease transmission and graft remodeling after implantation.^{3,5} The main factors associated with the medical team are the choice of appropriate sized meniscal grafts, their precise positioning and stable fixation.^{3,7,9} The meniscal graft must accurately match the dimensions of the recipient knee to increase the chance of restoration of normal biomechanical function.¹¹⁻¹³ Proper graft implantation and its fixation affect the load transmission function around the knee, and the choice of a graft corresponding morphologically to the recipient knee is essential to optimize the conformity between the meniscus and the femoral condyle.^{12,14}

Grafts can be preserved fresh, fresh frozen, cryopreserved and lyophilized. However, since lyophilized grafts tend to shrink significantly after implantation, this method of preservation is no longer recommended. The use of fresh grafts presents obvious logistical problems, such as finding a recipient within 7 days of harvesting, before the beginning of graft cell deterioration; in addition, there is an increased risk of disease transmission. Fresh frozen grafts are the most

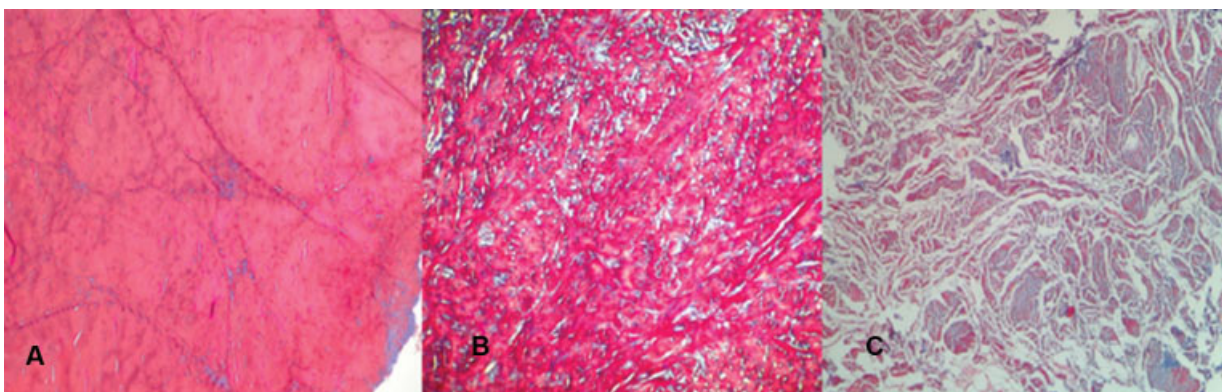


Fig. 2 (A) Fresh meniscus with no fiber fragmentation. (B) Meniscus preserved for 1 month showing fiber discontinuity and accumulated hyaline material stained in blue. (C) Meniscus preserved for 5 years exhibiting severe fiber fragmentation and marked interstitial dissociation due to edema (Masson's trichrome, 10x magnification).

used today, with higher success rates and the lowest risk of disease transmission or biomechanical degradation.^{3,5}

Animal studies have shown that transplanted menisci present proper peripheral incorporation and healing, with no inflammatory reaction or evident rejection aspect.^{5,15-17} Cury et al.¹⁷ evaluated the viability of frozen meniscal grafts transplanted into rabbits. The medial meniscus from 12 rabbits were harvested, frozen at - 80°C for 30 days, and then reimplanted in other rabbits. After 60 days, the menisci were macroscopically and histologically evaluated and compared to a control group, which consisted of the undamaged, contralateral knee. The authors observed that transplanted frozen menisci maintained the biological features from the original menisci regarding size and appearance, with good peripheral healing in the synovial membrane and no apparent immunological rejection.

The ANVISA and the Ministry of Health state that meniscal tissue can remain stored in a tissue bank for 5 years until transplantation.⁶ The biomechanical behavior of the menisci depends on the organization of their collagen fibers; as such, the ideal preservation method should not lead to significant changes in tissue microstructure, regardless of its cellularity.¹⁸ Our study revealed marked histological degeneration of menisci stored under freezing for 5 years, while menisci frozen for just 1 month showed milder degeneration.

Both human and animal studies show that deep freezing alters the normal architecture of collagen fibers and increased water tissue content, similarly to what was observed in our study.^{5,16,18-20} Gelber et al.¹⁹ found changes in meniscus collagen fibers frozen for 7 days, suggesting that deep freezing, regardless of the storage period, leads to structural changes in the graft. Our study showed that even menisci stored for just 1 month presented architectural changes when compared to nonfrozen menisci.

However, the significant progression of tissue degeneration in grafts stored for extended periods may suggest that the 5-year time point, considered the maximum amount of time a graft can remain stored before being transplanted, is too long.

Nevertheless, degeneration was much more pronounced in menisci stored for a longer time, indicating that not only freezing itself, but the extended storage period, leads to significant progression of meniscal tissue deterioration. Our findings suggest that the 5-year period, considered the maximum amount of time a graft can remain stored before being transplanted, is excessive. We did not find any case series of meniscus transplant with fresh frozen grafts describing the maximum period of storage before the procedure. In a biochemical, biomechanical and histological study, Lewis et al.²⁰ showed that menisci submitted to multiple freezing cycles presented decreased resistance to compression, with higher microstructure compromise. Verdonk et al.⁹ performed a series of homologous meniscus transplantation with viable fresh, nonfrozen grafts arguing that this not only contributes to cell survival but also to the production of extracellular matrix. Although the authors did not focus on the ultrastructural aspect of the grafts, we can assume that the use of nonfrozen grafts has the advantage of no significant change in the structure of meniscal collagen fibers.

The main limitation of our study is the small sample size. Our limiting factor was the small number of menisci in the tissue bank available for study. Our sample did not allow definitive conclusions regarding the optimal maximum storage period for meniscal tissues. However, we hypothesize that the 5-year period, currently accepted as the limit, may be too long. Further studies are required to assess this hypothesis and also to determine whether histological changes are associated with tissue biomechanical changes. Studies with a larger sample and analyzing an intermediate storage time (1 or 2 years of freezing) would be important to ascertain what would be the maximum ideal freezing time.

Treatment of knee ligament, meniscal and osteochondral lesions with homologous grafts has become progressively more popular in recent decades all over the world. The low availability of grafts in musculoskeletal tissue banks is associated with the difficulty in popularizing these techniques in our country, Brazil. Stimulus policies for musculoskeletal tissue harvesting and storage are critical.

Conclusion

Meniscal grafts stored under freezing for 1 month showed variable, slight degenerative change in collagen fibers, but with no large intercellular accumulations. Menisci frozen for 5 years presented significant tissue degeneration in its entire length, in addition to marked fiber fragmentation and dissociation by interstitial edema.

Authors Contribution

- Netto A. S. – Study conceptualization and design, data analysis and interpretation, manuscript preparation.
- Antebi U. – Data analysis and interpretation.
- Moraes C. E. – Data analysis and interpretation.
- Sementilli L. – Data analysis and interpretation.
- Severino N. R. – Critical review of the article.
- Cury R. P. L. – Critical review of the article and approval of the final version for publication.

Conflict of Interests

The authors have no conflict of interests to declare.

References

- 1 Beaufils P, Becker R, Kopf S, Matthieu O, Pujol N. The knee meniscus: management of traumatic tears and degenerative lesions. *EFORT Open Rev* 2017;2(05):195-203
- 2 Beaufils P, Pujol N. Management of traumatic meniscal tear and degenerative meniscal lesions. *Save the meniscus. Orthop Traumatol Surg Res* 2017;103(8S):S237-S244
- 3 Noyes FR, Heckmann TP, Barber-Westin SD. Meniscus repair and transplantation: a comprehensive update. *J Orthop Sports Phys Ther* 2012;42(03):274-290
- 4 Crook TB, Ardolino A, Williams LA, Barlow IW. Meniscal allograft transplantation: a review of the current literature. *Ann R Coll Surg Engl* 2009;91(05):361-365
- 5 Samitier G, Alentorn-Geli E, Taylor DC, et al. Meniscal allograft transplantation. Part 1: systematic review of graft biology, graft shrinkage, graft extrusion, graft sizing, and graft fixation. *Knee Surg Sports Traumatol Arthrosc* 2015; 23(01):310-322

- 6 Brasil. Resolução da Diretoria Colegiada - RDC nº 55 de 11/12/2015. Dispõe sobre as Boas Práticas em Tecidos humanos para uso terapêutico. Disponível em: http://portal.anvisa.gov.br/documents/10181/2718376/RDC_55_2015_.pdf/57eb6007-b35e-4d15-992d-51118966450c
- 7 Vundelinckx B, Vanlauwe J, Bellemans J. Long-term subjective, clinical, and radiographic outcome evaluation of meniscal allograft transplantation in the knee. *Am J Sports Med* 2014;42(07):1592-1599
- 8 Zaffagnini S, Grassi A, Marcheggiani Muccioli GM, et al. Survivorship and clinical outcomes of 147 consecutive isolated or combined arthroscopic bone plug free meniscal allograft transplantation. *Knee Surg Sports Traumatol Arthrosc* 2016;24(05):1432-1439
- 9 Verdonk PC, Verstraete KL, Almqvist KF, et al. Meniscal allograft transplantation: long-term clinical results with radiological and magnetic resonance imaging correlations. *Knee Surg Sports Traumatol Arthrosc* 2006;14(08):694-706
- 10 Samitier G, Alentorn-Geli E, Taylor DC, et al. Meniscal allograft transplantation. Part 2: systematic review of transplant timing, outcomes, return to competition, associated procedures, and prevention of osteoarthritis. *Knee Surg Sports Traumatol Arthrosc* 2015;23(01):323-333
- 11 Kaleka CC, Netto AS, Silva JC, et al. Which are the most reliable methods of predicting the meniscal size for transplantation? *Am J Sports Med* 2016;44(11):2876-2883
- 12 Netto ADS, Kaleka CC, Toma MK, et al. Should the meniscal height be considered for preoperative sizing in meniscal transplantation? *Knee Surg Sports Traumatol Arthrosc* 2018;26(03):772-780
- 13 Pollard ME, Kang Q, Berg EE. Radiographic sizing for meniscal transplantation. *Arthroscopy* 1995;11(06):684-687
- 14 Haut Donahue TL, Hull ML, Rashid MM, Jacobs CR. The sensitivity of tibiofemoral contact pressure to the size and shape of the lateral and medial menisci. *J Orthop Res* 2004;22(04):807-814
- 15 Arnoczky SP, DiCarlo EF, O'Brien SJ, Warren RF. Cellular repopulation of deep-frozen meniscal autografts: an experimental study in the dog. *Arthroscopy* 1992;8(04):428-436
- 16 Jackson DW, McDevitt CA, Simon TM, Arnoczky SP, Atwell EA, Silvino NJ. Meniscal transplantation using fresh and cryopreserved allografts. An experimental study in goats. *Am J Sports Med* 1992;20(06):644-656
- 17 Cury RP, Camargo OP, Prospero JD, et al. Transplante homólogo de menisco: estudo experimental em coelhos. *Rev Bras Ortop* 2002;37(08):341-349
- 18 Gelber PE, Gonzalez G, Torres R, Garcia Giralt N, Caceres E, Monllau JC. Cryopreservation does not alter the ultrastructure of the meniscus. *Knee Surg Sports Traumatol Arthrosc* 2009;17(06):639-644
- 19 Gelber PE, Gonzalez G, Lloreta JL, Reina F, Caceres E, Monllau JC. Freezing causes changes in the meniscus collagen net: a new ultrastructural meniscus disarray scale. *Knee Surg Sports Traumatol Arthrosc* 2008;16(04):353-359
- 20 Lewis PB, Williams JM, Hallab N, Viridi A, Yanke A, Cole BJ. Multiple freeze-thaw cycled meniscal allograft tissue: A biomechanical, biochemical, and histologic analysis. *J Orthop Res* 2008;26(01):49-55