

# Postoperative Evaluation of Patients Submitted to Arthroscopic Repair of Anterior Shoulder Instability

## *Avaliação pós-operatória de pacientes submetidos a reparo artroscópico de instabilidade anterior do ombro*

Thiago Medeiros Storti<sup>1,2</sup> Renato de Almeida Lima<sup>1</sup> Eloíse de Barros e Silva Costa<sup>2,3</sup>  
João Eduardo Simionatto<sup>1</sup> Carolina Simionatto<sup>1</sup> Alexandre Firmino Paniago<sup>1,2</sup>

<sup>1</sup>Instituto do Ombro de Brasília, Brasília, DF, Brazil

<sup>2</sup>Shoulder Group, Instituto de Pesquisa e Ensino HOME (IPE HOME), Brasília, DF, Brazil

<sup>3</sup>Orthopedic Department, Centro Universitário de Brasília (UnICEUB), Brasília, DF, Brazil

**Address for correspondence** Thiago Medeiros Storti, MD, Quadra 102 norte, praça Perdiz, Lote 05, Condomínio Residencial Matisse Antares, Águas Claras, DF, 71.907-000, Brasil (e-mail: thiago\_storti@hotmail.com).

Rev Bras Ortop 2020;55(3):339–346.

### Abstract

**Objective** To clinically evaluate the results of patients undergoing arthroscopic surgical treatment of anterior shoulder instability.

**Methods** A retrospective study of 94 patients. With a minimum follow-up of 24 months, we sought to correlate the characteristics of the patients and the surgery, such as age, gender, type of injury (traumatic or atraumatic) and the patient's position during surgery (lateral decubitus and beach chair) with the results obtained, the recurrence rate, the lateral rotation loss, the residual pain, and the functional scores of Carter-Rowe, University of California at Los Angeles (UCLA), and Constant-Murley.

**Results** We observed a recurrent dislocation rate of 11.7%, lateral rotation loss in 37.23% of the patients, and some degree of residual pain in 51.6% of them. We obtained a mean Carter Rowe score of 85.37, representing 86% of good/excellent results. In the UCLA score, we obtained 88% of good/excellent results, similar to those obtained in the Constant-Murley score (86%).

**Conclusion** The arthroscopic treatment of the anterior instability of the shoulder presents satisfactory results and low index of important complications, being the method of choice for most patients.

### Keywords

- ▶ arthroscopy
- ▶ articular instability
- ▶ shoulder
- ▶ retrospective studies

### Resumo

**Objetivo** Avaliar clinicamente os resultados de pacientes submetidos a tratamento cirúrgico artroscópico de instabilidade anterior do ombro.

**Métodos** Estudo retrospectivo de 94 pacientes. Com seguimento mínimo de 24 meses, buscamos correlacionar as características dos pacientes e da cirurgia, como idade, sexo, tipo de lesão (traumática ou atraumática) e posição do paciente na cirurgia (decúbito lateral e cadeira de praia) com os resultados obtidos, avaliando o índice de recidivas de luxação, a perda de rotação lateral, a dor residual, e os escores funcionais de Carter-Rowe, da University of California at Los Angeles (UCLA) e de Constant-Murley.

### Palavras-chave

- ▶ artroscopia
- ▶ instabilidade articular
- ▶ ombro
- ▶ estudos retrospectivos

received  
April 4, 2018  
accepted  
February 5, 2019

DOI <https://doi.org/10.1055/s-0039-3402467>.  
ISSN 0102-3616.

Copyright © 2020 by Sociedade Brasileira de Ortopedia e Traumatologia. Published by Thieme Revinter Publicações Ltda, Rio de Janeiro, Brazil

License terms



**Resultados** Observamos uma taxa de recidiva de luxação de 11,7%, perda de rotação lateral em 37,23% dos pacientes, e algum grau de dor residual em 51,6%. Obtivemos uma pontuação média no escore de Carter Rowe de 85,37, representando 86% de resultados bons/excelentes. No escore da UCLA, obtivemos 88% de resultados bons/excelentes, índice semelhante aos encontrados no escore de Constant-Murley (86%).

**Conclusão** O tratamento artroscópico da instabilidade anterior do ombro apresenta resultados satisfatórios e baixo índice de complicações importantes, podendo ser o método de escolha para a maioria dos pacientes.

## Introduction

Anterior glenohumeral dislocation is the most common kind of shoulder dislocation. It results from damage to the capsulolabral complex in the anteroinferior portion of the glenoid, and is also referred to as Bankart lesion or essential lesion.<sup>1-4</sup>

Surgical repair, either open or arthroscopic, is indicated for recurrent dislocations. Among the surgical treatments for shoulder stabilization, arthroscopic repair has become increasingly popular due to reduced movement loss, milder surgical aggression, subscapularis preservation and low morbidity compared to open surgery.<sup>5</sup>

Several patient-related factors contributing to the recurrence risk following the Bankart arthroscopic repair have been reported, including younger age at surgery, male gender, bilateral instability, ligamentous hyperlaxity, participation in collision sports, and early return to contact sports.<sup>6</sup> Injury-associated risk factors, such as erosion or glenoid deficiency, Hill-Sachs lesion size, and anterior glenoid border involvement were also implicated.<sup>7</sup> Accurate identification of the risk factors associated with Bankart arthroscopic repair failure and capsular dislocation helps the surgeon stratify the risk for an individual patient, enabling proper counseling.

Therefore, the present study aims to perform a functional assessment and to analyze the factors influencing the outcome of patients with anterior shoulder instability submitted to the arthroscopic treatment of anterior shoulder instability.

## Materials and Methods

From March to May 2017, 94 patients were retrospectively analyzed through a review of medical records and subsequent clinical evaluation. All patients underwent arthroscopic surgical treatment for anterior shoulder instability in two private hospitals and by four independent surgeons between January 2010 and December 2014. Ten patients operated on during this period were excluded due to non-attendance at the follow-up.

The medical records had the following information: patient identification, clinical history characterizing the cause of the instability (traumatic or atraumatic), functional limitation, preoperative physical examination, preoperative imaging, and surgical description. The postoperative follow-up

time ranged from 24 to 72 months, with a mean period of 40 months, to assess the functional limitation, decreased lateral rotation, instability, pain, and functional scores of Carter-Rowe, University of California at Los Angeles (UCLA) and Constant-Murley through clinical and physical examinations performed by an external physician.

The present study included patients with recurrent anterior shoulder instability (dislocation or subluxation) and Bankart lesion, all operated arthroscopically and with a minimum postoperative follow-up time of 24 months. The exclusion criteria were traumatic dislocation associated with neurovascular injury, fracture on other sites of the shoulder girdle, glenoid bone loss greater than 25%, Hill-Sachs fracture involving more than 1/4 of the humeral head, previous surgeries at the involved shoulder, and multidirectional instability.

Two surgeons performed the procedures with the patients in lateral position. The surgical procedure was performed under general anesthesia and brachial plexus block. The limb was kept at approximately 70° of abduction and 20° of flexion, and fixed and vertical longitudinal traction with 4- to 7-kg weights was applied.

The other two surgeons performed the procedures with the patients in the beach chair position, that is, with a trunk elevation of at least 70°, around 30° of knee flexion, and gentle lateral inclination opposite to the operated side.

The surgeons used conventional arthroscopic portals (posterior, anterosuperior and anteroinferior). During the procedure, the joint was inspected to assess the presence of associated lesions. Subsequently, the anteroinferior labral lesion and its extension were observed, followed by capsulolabral release and glenoid border scarification; next, the labral lesion was fixed with two to four bioabsorbable anchors.

Postoperatively, the patients remained with continuous immobilization on a Velpeau sling for three weeks. Pendular motion and passive self-motion were then initiated over the following two weeks; lateral rotation movements beyond 20° were allowed from the 6th week onwards. Muscle strengthening was dependent on the range of motion of the operated shoulder, and usually began in the third postoperative month. Return to contact or collision sports activities was allowed from the sixth month onwards.

In the descriptive analysis, the observed data were presented as tables; the continuous and quantitative variables were expressed as medians and interquartile ranges (IQRs), whereas the categorical and qualitative variables were expressed as frequencies (n) and percentages (%).

The inferential analysis employed the following methods:

- the association of the Carter-Rowe, UCLA and Constant-Murley scores with the clinical variables (age, gender, type of injury and surgical position) was assessed by the Mann-Whitney test for categorical data and the Spearman correlation coefficient for numerical data; and
- the association of dislocation recurrence, residual pain, loss of lateral rotation and apprehension with the clinical variables was analyzed by the Chi-squared ( $\chi^2$ ) or Fisher exact test for categorical data and by the Mann-Whitney test for numerical data.

A nonparametric method was applied because the variables under study did not present normal (Gaussian) distribution due to the rejection of the normality hypothesis by the Shapiro-Wilks test. The significance was determined as a 5% level. The statistical analysis was performed using Statistical Analysis System (SAS, SAS Institute, Inc., Cary, North Carolina, US) software, version 6.11.

All patients signed the Informed Consent Form. The present study was approved by the Committee of Ethics in Research with Human Beings under Opinion no. 2,197,472, CAAE 70807917.6.0000.0023.

### Results

In total, 94 patients were evaluated in the present study, with a follow-up period of 2 to 6 years after surgery; 74 subjects (78,7%) were male, and 20 (21,3%) were female, with ages at the surgical procedure ranging from 17 to 62 years (► **Table 1**). A total of 11 (11,7%) patients presented dislocation recurrence, 35 (37,23%) had decreased lateral rotation, 48 (51,06%) reported some degree of residual pain, and 23 (24,46%) were positive at the apprehension test (► **Table 2**).

Traumatic instability was prevalent, representing 90,4% of cases (85 patients). The most common surgical positioning was that of lateral decubitus, with 71 of the operated patients (75,5%) of patients underwent surgery in this position. At the clinical evaluation, the median Carter-Rowe score was of 95 (► **Table 3**), with 67 excellent outcomes (71,3%), 14 good outcomes (14,9%), 2 regular outcomes (2,1%) and 11 bad outcomes (11,7%) (► **Figure 1**). Bad outcomes were associated with dislocation recurrence, and they occurred in 9 male patients (81,8%) and in 2 female patients (18,2%). Although more prevalent in male patients, our study found no statistically significant difference between gender and dislocation recurrence. Similarly, there was no significant correlation between the Carter-Rowe score and age at the time of surgery ( $r_s = 0.162$ ;  $p = 0.011$ ).

In the UCLA score evaluation, there were 83 patients (88,3%) with good/excellent outcomes and 11 patients (11,7%) with bad/regular outcomes (► **Figure 2**). There was a significant direct correlation between the UCLA score and the patient's age at the time of surgery ( $r_s = 0.250$ ;  $p = 0.015$ ). Therefore, the older the age, the higher the expected score.

In the Constant-Murley score evaluation, there were 65 patients (69,2%) with excellent outcomes, 18 (19,1%) good outcomes, 10 (10,7%) regular outcomes and 1 poor outcome (1%) (► **Figure 3**). None of the three scores presented a

**Table 1** General description of the variables

Variable	N	%
Gender		
Male	74	78.7
Female	20	21.3
Age at surgery (years)		
Median value (Q1-Q3)	34 (28-43)	
Injury type		
Traumatic injury	85	90.4
Atraumatic injury	9	9.6
Position		
Beach chair	23	24.5
Lateral recumbency	71	75.5
Carter-Rowe score (points)		
Median value (Q1-Q3)	95 (80-100)	
University of California at Los Angeles (UCLA) score (points)		
Median value (Q1-Q3)	33 (31-35)	
Constant-Murley score (points)		
Median value (Q1-Q3)	95 (87-100)	

statistically significant correlation with gender, type of injury or surgical position.

In addition, there was no statistically significant correlation between the clinical variables (gender, age, type of injury and surgical position) and dislocation recurrence, residual pain, loss of lateral rotation and apprehension (► **Tables 4, 5, 6, 7**). The subgroup with residual pain, however, was significantly younger than the subgroup without residual pain ( $p = 0.016$ ).

### Discussion

The surgical treatment for anterior shoulder instability must be chosen based on factors such as age, previous dislocations,

**Table 2** General description of the variables

Redislocation	N	%
Yes	11	11.7
No	83	88.3
Residual pain		
Yes	48	51.1
No	46	48.9
External rotation loss		
Yes	35	37.2
No	59	62.8
Apprehension		
Yes	23	24.5
No	71	75.5

**Table 3** Functional scores

Variable	n	Median value	Interquartile range			Minimum	Maximum
Age at surgery (years)	94	34	27.8	-	43	17	62
Score (points)							
Carter-Rowe	94	95	80	-	100	15	100
University of California at Los Angeles (UCLA)	94	33	31	-	35	23	35
Constant-Murley	94	95	87	-	100	68	100

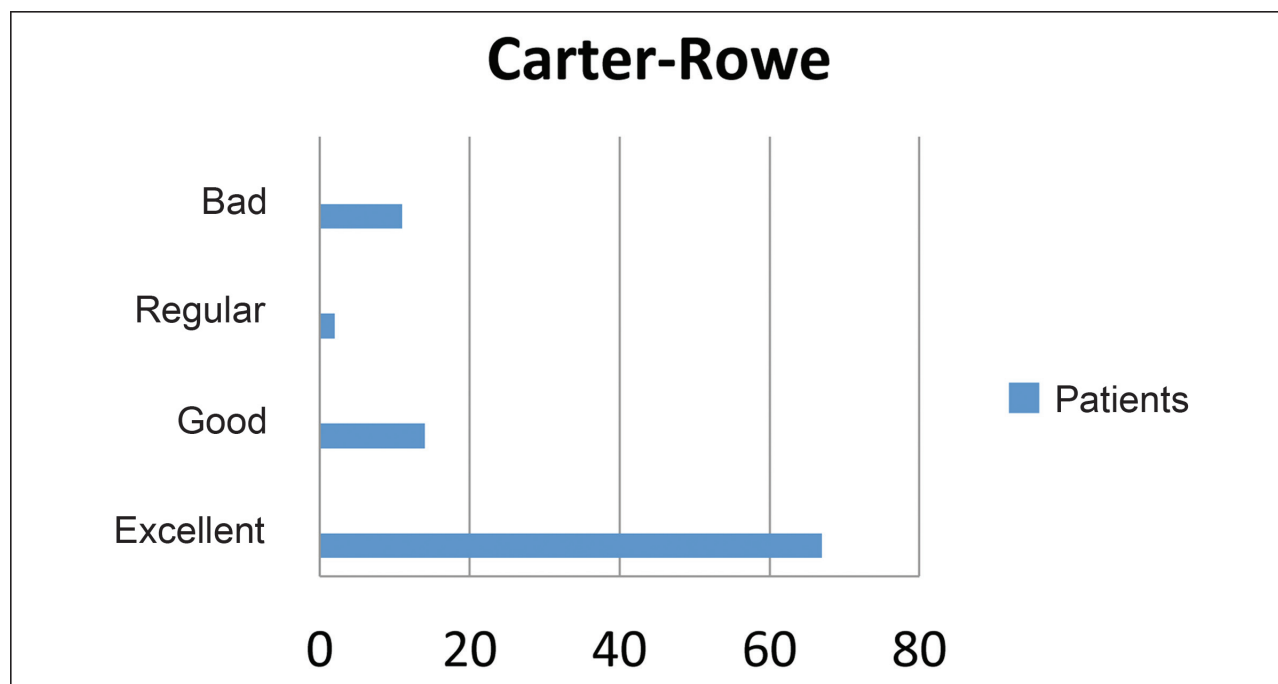
occupation, level of physical activity, ligament laxity, overall health status of the patient, degree of humeral head and glenoid bone involvement, and the presence of associated conditions, such as upper labral (superior labral tear from anterior to posterior, SLAP) injuries and rotator cuff tendon rupture.<sup>8</sup> Choosing the most appropriate treatment for each patient can influence the outcomes and minimize the risk of complications.

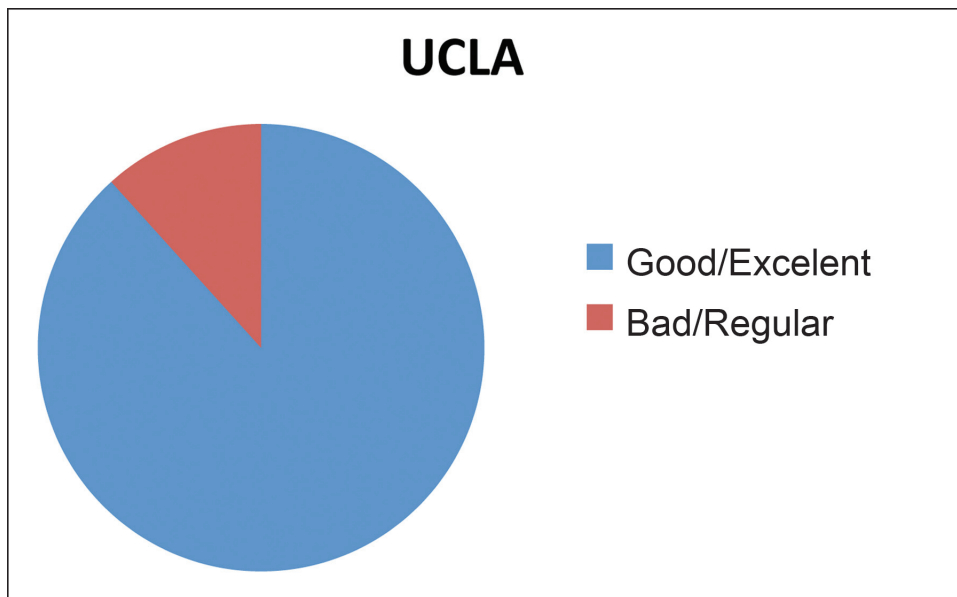
The best method for labral lesion repair is still debatable.<sup>9</sup> The anatomical procedures include open and arthroscopic Bankart surgeries, which aim to restore the original shoulder anatomy and involve labral lesion repair.<sup>10</sup> Bankart open surgery, which is performed with labrum mobilization and fixation, is still considered the gold standard for anterior instability treatment.<sup>11</sup> However, conditions such as incision size, risk of subscapularis muscle weakness, loss of shoulder range of motion (especially lateral rotation) and difficulty in accessing other intra-articular injuries have favored the choice for the arthroscopic procedure. Other advantages of arthroscopy are reduced blood loss, shorter surgery duration and greater esthetic satisfaction.<sup>12</sup>

The dislocation recurrence rates after arthroscopic surgery have been decreasing due to technological advances and a better understanding of previous errors. In 2007, Balg and Boileau<sup>13</sup> described a 14.5% recurrence rate after Bankart arthroscopic surgery. Castagna et al.<sup>14</sup> obtained a 23% recurrence rate in a 10-year follow-up of 43 patients submitted to arthroscopy. In a meta-analysis, Petrera et al.<sup>15</sup> compared the open Bankart and arthroscopic surgeries and found a dislocation recurrence rate 6.3% lower in the arthroscopy group.

Ahmed et al<sup>6</sup> also reported better results with arthroscopic techniques, with a dislocation recurrence rate of 13.2% in a total of 302 patients. In our study, all recurrence cases were associated with traumatic instability, with an 11.7% rate.

As for loss of lateral rotation, Bottoni et al<sup>16</sup> demonstrated that the decrease in range of motion was of 2° to 3° in the arthroscopic group, and of 6.5° in the open surgery group. In our study, loss of lateral rotation was observed mostly in patients with traumatic instability, which is similar to the results reported by Ferreira Neto et al,<sup>17</sup> who also found a greater lateral rotation limitation in patients with such a

**Fig. 1** Carter-Rowe score.



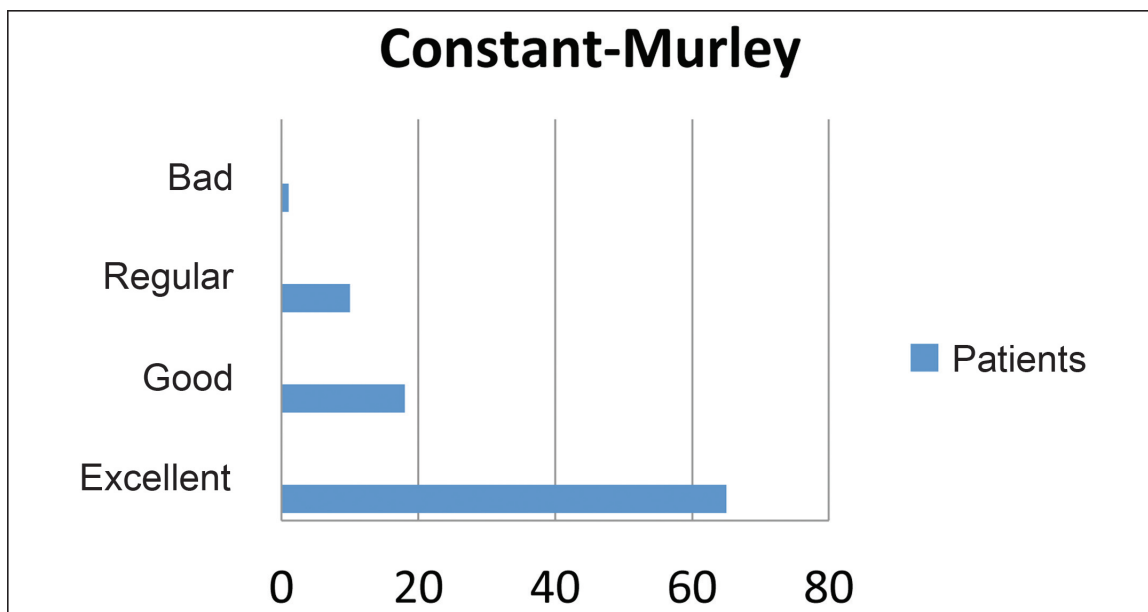
**Fig. 2** University of California at Los Angeles (UCLA) score.

feature. These results may be justified by the better capsular ligament accommodation in patients with atraumatic injuries when compared to patients with traumatic instability.<sup>17-19</sup> Almeida Filho et al.,<sup>20</sup> after performing postoperative clinical and radiographic evaluations of 49 patients, observed that despite the arthrosis-related lateral rotation decrease, it was not possible to ascertain a cause-effect relationship between them.

Residual pain is a common postoperative complaint in patients surgically treated for anterior shoulder instability. Several authors<sup>21-23</sup> attribute this complication to injuries associated with instability and that may not be diagnosed at first, especially partial rotator cuff tears, SLAP injuries, and joint degenerative changes. In our study, approximately

51% of the patients had some degree of postoperative residual pain, and there was an inverse association between age and pain. The younger the age at surgery, the greater the occurrence of postoperative pain, which may be justified by the higher level of activity of this group of patients. In addition, as noted by Almeida Filho et al,<sup>20</sup> there is a significant relationship between postoperative glenohumeral arthrosis development and younger age at the time of surgery and first dislocation, corroborating our observation.

Some studies<sup>13,24-27</sup> have shown that younger patients are at an increased risk of recurrence after arthroscopic surgical stabilization, but no age has been defined. According to Ahmed et al,<sup>6</sup> age alone is not sufficient to determine the



**Fig. 3** Constant-Murley score.

**Table 4** Association between the clinical variables and redislocation

Variable	With redislocation		Without redislocation		p-value
Gender					
Male	9	81.8	65	78.3	0.57
Female	2	18.2	18	21.7	
Age at surgery (years)					
Median value (Q1–Q3)	32 (23–38)		34 (28–43)		0.10
Injury type					
Traumatic injury	11	100	74	89.2	0.31
Atraumatic injury	0	0	9	10.8	
Surgical position					
Beach chair	4	36.4	19	22.9	0.26
Lateral recumbency	7	63.6	64	77.1	

Note: The categorical data were expressed as frequencies and percentages, and they were compared using the Chi-squared test or the Fisher exact test; age was expressed as medians and interquartile ranges and was compared using the Mann-Whitney test.

**Table 5** Association between the clinical variables and residual pain

Variable	With residual pain		Without residual pain		p-value
Gender					
Male	41	85.4	33	71.7	0.085
Female	7	14.6	13	28.3	
Age at surgery (years)					
Median value (Q1–Q3)	32 (25–38)		37 (30–44)		0.016
Injury type					
Traumatic injury	43	89.6	42	91.3	0.52
Atraumatic injury	5	10.4	4	8.7	
Surgical position					
Beach chair	12	25.0	11	23.9	0.9
Lateral recumbency	36	75.0	35	76.1	

**Table 6** Association between the clinical variables and lateral rotation loss

Variable	With external rotation loss		Without external rotation loss		p-value
Gender					
Male	29	82.9	45	76.3	0.45
Female	6	17.1	14	23.7	
Age at surgery (years)					
Median value (Q1–Q3)	35 (25–44)		34 (28–40)		0.53
Injury type					
Traumatic injury	30	85.7	55	93.2	0.20
Atraumatic injury	5	14.3	4	6.8	
Surgical position					
Beach chair	6	17.1	17	28.8	0.20
Lateral recumbency	29	82.9	42	71.2	



**Table 7** Association between clinical variables and apprehension

Variable	With apprehension		Without apprehension		p-value
Gender					
Male	19	82.6	55	77.5	0.42
Female	4	17.4	16	22.5	
Age at surgery (years)					
Median value (Q1–Q3)	31 (25–40)		34 (28–43)		0.29
Injury type					
Traumatic injury	23	100	62	87.3	0.070
Atraumatic injury	0	0	9	12.7	
Surgical position					
Beach chair	5	21.7	18	25.4	0.72
Lateral recumbency	18	78.3	53	74.6	

treatment offered to younger patients, but it is clearly an important factor to predict the risk of recurrence. In our series, there was no statistically significant correlation between age and dislocation recurrence; the median age of patients with and without recurrence was similar (32 versus 34 years old).

Three functional scores, the UCLA, Carter-Rowe and Constant-Murley scores, were used for outcome evaluation. The median Carter-Rowe score was 95, with 67 excellent outcomes, 14 good outcomes, 2 regular outcomes and 11 poor outcomes. As for the UCLA score, there were 83 patients with good/excellent outcomes and 11 patients with bad/regular outcomes. Using the Constant score, 65 patients presented excellent outcomes, 18 had good outcomes, 10 had regular outcomes, and 1 had a poor outcome. Regarding the three scores, all patients with regular/poor outcomes were those with dislocation recurrence.

The results reported by Boileau et al<sup>28</sup> in 91 patients showed a mean Carter-Rowe score of 77.8 points (ranging from 15 to 100 points). Balg and Boileau<sup>13</sup> observed an average Carter-Rowe score of 81.5 points (range: 10–100 points) after evaluating 131 operated patients. Neri et al,<sup>29</sup> analyzing 11 patients, found a Carter-Rowe score of 74.5 points (range: 35–100 points), and an average UCLA score of 29.6 points (ranging from 24 to 35 points), with good/excellent outcomes in 8 patients (72.7%) and regular/poor outcomes in 3 subjects (27.3%). In a study evaluating 314 shoulders from 302 patients, Godinho et al<sup>30</sup> demonstrated an average Carter-Rowe score of 91.8, ranging from 25 to 100 points, and an UCLA score of 33.8 points, with 97.6% of good/excellent outcomes. Our series presented a significant direct correlation between the UCLA score and age ( $r_s = 0.250$ ;  $p = 0.015$ ), indicating that, the older the age, the higher the expected UCLA score.

Regardless of the method used, the main postoperative complication is dislocation recurrence, which is associated with the previously mentioned risk factors. Thus, the use of scores such as the Instability and Severity Index Score (ISIS) may indicate the technique that provides the greatest benefits for patients. The score includes age at time of

surgery, degree of sports participation, type of sport practiced, ligamentous laxity, presence of Hill-Sachs lesion, and loss of glenoid contour to generate a total of 10 points. According to Balg and Boileau,<sup>13</sup> patients with scores of up to six points benefit most from the arthroscopic technique, while lower scores are indications for open surgeries, especially the Latarjet procedure.

The main limitations of the study include its retrospective nature, which did not enable a rigorous preoperative functional assessment, the short follow-up period, and the non-normal data distribution, requiring the use of nonparametric tests.

### Conclusions

We conclude that the arthroscopic repair of anterior shoulder instability has satisfactory outcomes in the functional scores at the short/medium-term, with a low rate of severe, limiting complications, and it can be a method of choice for most patients. Bad/regular outcomes were associated with dislocation recurrence. Postoperative pain was associated with younger age at surgery, whereas lateral rotation limitation was related to the type of instability (traumatic injury).

### Conflict of Interests

The authors have no conflict of interests to declare.

### References

- 1 Veeger DH. "What if": the use of biomechanical models for understanding and treating upper extremity musculoskeletal disorders. *Man Ther* 2011;16(01):48–50
- 2 Perthes G. Uber Operationen bei tabitueller Schulterluxation. *Dtsch Z Chir* 1906;56:149–151
- 3 Bankart AS. Recurrent or habitual dislocation on the shoulder joint. *BMJ* 1923;2(3285):1132–1133
- 4 Bankart AS. The pathology and treatment of recurrent dislocation of the shoulder joint. *Br J Surg* 1938;26:23–29
- 5 Neviasser RJ, Benke MT, Neviasser AS. Mid-term to long-term outcome of the open Bankart repair for recurrent traumatic anterior dislocation of the shoulder. *J Shoulder Elbow Surg* 2017;26(11):1943–1947

- 6 Ahmed I, Ashton F, Robinson CM. Arthroscopic Bankart repair and capsular shift for recurrent anterior shoulder instability: functional outcomes and identification of risk factors for recurrence. *J Bone Joint Surg Am* 2012;94(14):1308–1315
- 7 Murray IR, Ahmed I, White NJ, Robinson CM. Traumatic anterior shoulder instability in the athlete. *Scand J Med Sci Sports* 2013;23(04):387–405
- 8 Pulavarti RS, Symes TH, Rangan A. Surgical interventions for anterior shoulder instability in adults. *Cochrane Database Syst Rev* 2009;(04):CD005077
- 9 Rosa JR, Checchia CS, Miyazaki AN. Instabilidade anterior traumática do ombro. *Rev Bras Ortop* 2017;52(05):513–520
- 10 Randelli P, Ragone V, Carminati S, Cabitza P. Risk factors for recurrence after Bankart repair a systematic review. *Knee Surg Sports Traumatol Arthrosc* 2012;20(11):2129–2138
- 11 Grumet RC, Bach BR Jr, Provencher MT. Arthroscopic stabilization for first-time versus recurrent shoulder instability. *Arthroscopy* 2010;26(02):239–248
- 12 Virk MS, Manzo RL, Cote M, et al. Comparison of Time to Recurrence of Instability After Open and Arthroscopic Bankart Repair Techniques. *Orthop J Sports Med* 2016;4(06):2325967116654114
- 13 Balg F, Boileau P. The instability severity index score. A simple pre-operative score to select patients for arthroscopic or open shoulder stabilisation. *J Bone Joint Surg Br* 2007;89(11):1470–1477
- 14 Castagna A, Markopoulos N, Conti M, Delle Rose G, Papadakou E, Garofalo R. Arthroscopic bankart suture-anchor repair: radiological and clinical outcome at minimum 10 years of follow-up. *Am J Sports Med* 2010;38(10):2012–2016
- 15 Petrera M, Patella V, Patella S, Theodoropoulos J. A meta-analysis of open versus arthroscopic Bankart repair using suture anchors. *Knee Surg Sports Traumatol Arthrosc* 2010;18(12):1742–1747
- 16 Bottoni CR, Smith EL, Berkowitz MJ, Towle RB, Moore JH. Arthroscopic versus open shoulder stabilization for recurrent anterior instability: a prospective randomized clinical trial. *Am J Sports Med* 2006;34(11):1730–1737
- 17 Ferreira Neto FAA, Camanho GL, Felix AM, et al. Tratamento artroscópico da instabilidade anterior do ombro: estudo retrospectivo de 159 casos. *Acta Ortop Bras* 2011;19(01):41–44
- 18 Kim SH, Ha KI, Cho YB, Ryu BD, Oh I. Arthroscopic anterior stabilization of the shoulder: two to six-year follow-up. *J Bone Joint Surg Am* 2003;85(08):1511–1518
- 19 Hayashida K, Yoneda M, Nakagawa S, Okamura K, Fukushima S. Arthroscopic Bankart suture repair for traumatic anterior shoulder instability: analysis of the causes of a recurrence. *Arthroscopy* 1998;14(03):295–301
- 20 Almeida Filho IA, Veado MA, Fim M, Corrêa LV, Júnior AE. Avaliação funcional do reparo artroscópico da instabilidade anterior recidivante do ombro. *Rev Bras Ortop* 2012;47(02):214–221
- 21 Larrain MV, Montenegro HJ, Mauas DM, Collazo CC, Pavón F. Arthroscopic management of traumatic anterior shoulder instability in collision athletes: analysis of 204 cases with a 4- to 9-year follow-up and results with the suture anchor technique. *Arthroscopy* 2006;22(12):1283–1289
- 22 Enad JG, Gaines RJ, White SM, Kurtz CA. Arthroscopic SLAP repair in military patients. *J Shoulder Elbow Surg* 2007;16(03):300–305
- 23 Buscayret F, Edwards TB, Szabo I, Adeleine P, Coudane H, Walch G. Glenohumeral arthrosis in anterior instability before and after surgical treatment: incidence and contributing factors. *Am J Sports Med* 2004;32(05):1165–1172
- 24 Porcellini G, Campi F, Pegreff F, Castagna A, Paladini P. Predisposing factors for recurrent shoulder dislocation after arthroscopic treatment. *J Bone Joint Surg Am* 2009;91(11):2537–2542
- 25 Flinkkilä T, Hyvönen P, Ohtonen P, Leppilahti J. Arthroscopic Bankart repair: results and risk factors of recurrence of instability. *Knee Surg Sports Traumatol Arthrosc* 2010;18(12):1752–1758
- 26 Voos JE, Livermore RW, Feeley BT, et al; HSS Sports Medicine Service. Prospective evaluation of arthroscopic bankart repairs for anterior instability. *Am J Sports Med* 2010;38(02):302–307
- 27 Calvo E, Granizo JJ, Fernández-Yruegas D. Criteria for arthroscopic treatment of anterior instability of the shoulder: a prospective study. *J Bone Joint Surg Br* 2005;87(05):677–683
- 28 Boileau P, Villalba M, Héry JY, Balg F, Ahrens P, Neyton L. Risk factors for recurrence of shoulder instability after arthroscopic Bankart repair. *J Bone Joint Surg Am* 2006;88(08):1755–1763
- 29 Neri BR, Tuckman DV, Bravman JT, Yim D, Sahajpal DT, Rokito AS. Arthroscopic revision of Bankart repair. *J Shoulder Elbow Surg* 2007;16(04):419–424
- 30 Godinho GG, França FO, Freitas JM, et al. Tratamento artroscópico da instabilidade anterior traumática do ombro: resultados a longo prazo e fatores de risco. *Rev Bras Ortop* 2008;43(05):157–166