







Weight Discharge in Postoperative of Plateau Fracture Tibialis: Systematic Review of Literature*

Descarga de peso no pós-operatório de fratura de planalto tibial: Revisão sistemática da literatura

Débora Pinheiro Lédio Alves¹ Paloma Yan Lam Wun¹ Andréia Lima Alves¹
Ralph Walter Christian¹ Marcelo Tomanik Mercadante¹ José Octávio Hungria¹

¹Department of Rehabilitation, Faculdade de Ciências Médicas, Santa Casa de Misericórdia de São Paulo, São Paulo, SP, Brazil

Address for correspondence Andréia de Lima Alves, Rua Doutor Cesário Mota Junior, 112, São Paulo, SP, 01221-020, Brazil (e-mail: andreidelimalves@gmail.com).

Rev Bras Ortop 2020;55(4):404–409.

Abstract

Tibial plateau fractures are a risk to the functional integrity of the knee, affecting the axial alignment and capable of leading to pain and disability of the individual. Early weight bearing and joint mobilization can prevent these functional deficits. The goal of the present study was to conduct a systematic review of the literature about studies that quote the beginning, evolution, and progression criteria for weight-bearing in postoperative period of tibial plateau fractures. We selected articles published in the last 12 years, in Portuguese and English, that described the time of onset and progression of weight-bearing, considering the severity of the fracture. Thirty-six articles were selected. There is no consensus in the literature as to the beginning and evolution of weight-bearing in the postoperative period of tibial plateau fractures; however, a relationship between the severity of the fracture and the fixation method has been observed.

Keywords

- ▶ tibial fractures
- ▶ weight-bearing
- ▶ rehabilitation
- ▶ physical therapy

Resumo

As fraturas do planalto tibial constituem risco à integridade funcional do joelho, afetando o alinhamento axial e podendo levar à dor e à incapacidade do indivíduo. O suporte de carga e a mobilização articular precoce podem prevenir esses déficits e acelerar o processo de reabilitação. O objetivo do presente trabalho foi realizar uma revisão da literatura sobre estudos que citam o início, evolução e critérios de progressão do suporte de carga no pós-operatório das fraturas de planalto tibial. Foram selecionados artigos publicados nos últimos 12 anos, nos idiomas português e inglês, que descrevessem o tempo de início e progressão do suporte de carga, considerando a gravidade da fratura. Foram selecionados 36 artigos na literatura. Não há consenso na literatura quanto ao início e evolução do suporte de carga no pós-operatório das fraturas do planalto tibial. Contudo, observa-se relação entre a gravidade da fratura e o tempo de início da carga.

Palavras-chave

- ▶ fraturas da tíbia
- ▶ suporte de carga
- ▶ reabilitação
- ▶ fisioterapia

* Work developed at Santa Casa de Misericórdia de São Paulo, Faculdade de Ciências Médicas, São Paulo, SP, Brazil.

Introduction

Tibial plateau fractures (TPFs) are severe intra-articular lesions that correspond to approximately 1% of all fractures and total 8% of the fractures that affect the elderly. They are an important risk to the functional integrity of the knee, especially when it affects the axial alignment, congruence and/or joint stability, which may result in premature osteoarthritis, ligament injuries, pain and disability.¹

The majority of the lesions affect the lateral condyle (55-70%), and they are related to low- and medium-energy traumas. Isolated, fractures of the medial plateau correspond to from 10 to 23% of proximal tibial joint fractures. Those that affect the tibial plateau in a complex way, characterized as bicondylar fractures, represent 10 to 30%, resulting from high-energy traumas, and are associated with severe injury of soft tissues.²

This type of fracture resulted in the application of compressive axial forces combined with varus or valgus stresses in the knee joint and are mostly related to automobile accidents and falls.³ The prognosis of TPFs depends directly on five factors: degree of joint depression, extension and separation of the tibial condyles fracture line, degree of fragmentation, metaphyseal dissociation, and soft tissue integrity.^{3,4}

The Schatzker classification is the most commonly used in TPFs.³ Another system is the one proposed by the *Arbeitsgemeinschaft für Osteosynthesefragen* (AO) classification.⁵ -Figure 1 illustrates the association between these two classifications, Schatzker and AO.⁴

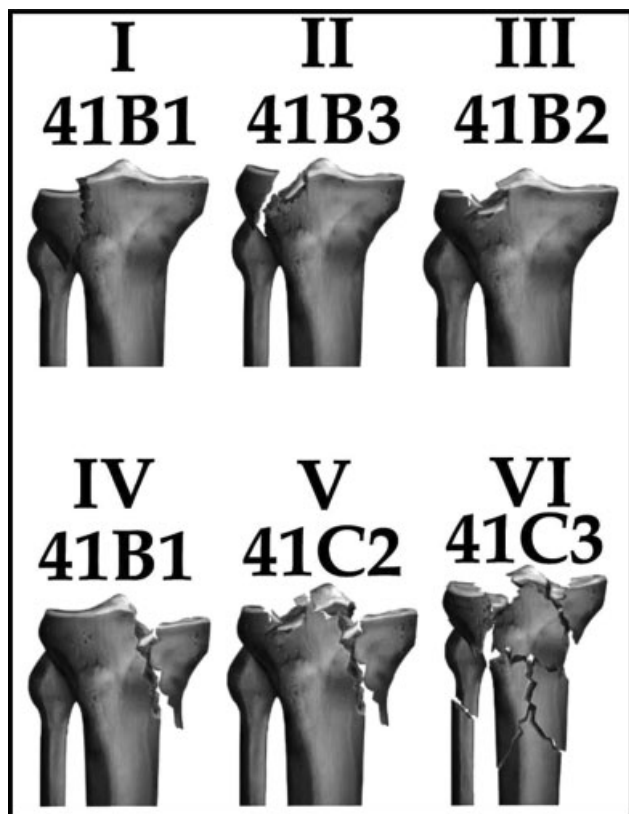


Fig. 1 Correlation between Schatzker and AO classifications. Source: Kfuri M, Fogagnolo F, Bitar R, Freitas R, Salim R, Paccola CA. Fraturas do planalto tibial. *Rev Bras Ortop.* 2009;44(6):468-74.

The main objective in the fixation of TPFs is to obtain a stable, congruent, and aligned articulation, preserving joint mobility of the knee and without pain, allowing the early return of the patient to functional activities.⁶ The literature describes several fixation methods for proximal tibial fractures, such as open reduction and internal fixation (ORIF);^{6,7} closed reduction and external fixation (CREF);^{8,9} percutaneous compression screw;¹⁰ use of subchondral graft;¹¹ use of graft substitutes (calcium phosphate cement);¹²⁻¹⁴ and arthroscopy,^{10,11,15} with the possibility of association between methods. Also, for fractures with minimal deviation, it is indicated to use conservative treatment with articulated orthoses or braces.¹⁶

The chosen surgical fixation method should achieve the anatomical reduction of bone fragments, promoting absolute stability in the fracture focus in order to create conditions for the direct consolidation of the fracture. Thus, it allows articular mobilization and early weight-bearing in the lower limb affected, promoting the nutrition of the cartilage and preventing the formation of arthrofibrosis in the knee.^{6,16,17}

There are controversies in the literature regarding the period to start and the evolution of weight-bearing in the lower limb after TPFs. Some studies mention periods varying between 10 and 12 weeks,^{9,17} while others report 6 to 8 weeks without weight-bearing.^{10,18} There are also studies that release immediate partial weight-bearing,^{16,19} and, yet, others report that the start of weight-bearing is case-dependent.²⁰

The present study aims to conduct a systematic review of the literature in order to ascertain the onset time for weight-bearing in the postoperative period of TPFs, considering the severity, the fixation method, and the determining criteria for the evolution of the weight.

Method

A systematic review of the literature was carried out in the electronic databases Embase and PUBMED, relative to the last 18 years (2000-2018), in order to obtain the analysis of the most recent publications on the theme. The searches were performed from the intersection of the following text descriptors, and their respective terms: *tibial plateau fracture*, *weight-bearing*, *rehabilitation*, and *physical therapy*.

The inclusion criteria adopted were articles published between 2000 and 2018, which were in the Portuguese language, and articles related to postoperative rehabilitation of TPFs, regardless of its classification (Schatzker/AO) and possibly presenting associated lesions in the ipsilateral lower limb (anterior cruciate ligament, meniscus), and that mentioned the time of weight release in the affected lower limb.

The exclusion criteria followed were: conservatively-treated TPFs, systematic reviews, experimental studies in animals, in cadavers and also in biomechanical models.

The data extracted from the articles included in the present study were the time to start and the evolution of weight-bearing, as well as the determining criteria for its progression. The fracture fixation methods and their respective classifications were also recorded.

Results

From the intersection of the text descriptors, 616 articles were identified in the Embase, MEDLINE, and PUBMED databases. The dynamics of inclusion and exclusion of the articles is shown in ►Table 1^{6-15,17-28} and ►Figure 2.

When submitted to the first analysis by reading the title and abstract, 569 articles were excluded for not presenting postoperative rehabilitation issues of TPFs (comparison among the fixation methods, description of surgical techniques, treatment for fractures that did not involve the tibial plateau, conservative treatment, gonarthrosis as a sequel to fracture),

175 per duplicate, 28 per language (17 in German, 6 in Chinese, 2 in Polish, 1 in Japanese, and 3 in Turkish), 12 for being laboratory studies in biomechanics or cadaveric models, and, finally, 4 articles were excluded for being experimental studies in animals.

The first analysis was completed, and 47 articles were selected and submitted to the second analysis by integral reading. From these, 25 were excluded, 18 because they did not present definition regarding the onset of TPF postoperative weight-bearing, others were studies in the form of a bibliographic review that did not specify the fracture classification and the weight-bearing time. In two studies, the evolution of

Table 1 Main studies selected according to author/year of publication, method of fixing, grading, starting weight unloading and load progression

Author	Fixation method	Schatzker	Touch	Partial load	Total load	Load evolution criterion
Wang et al. ²⁵ (2016)	Several	I, II, III	_____	8 weeks	12 weeks	_____
Thewlis et al. ²³ (2015)	ORIF (plate)	I, II, III, IV, V	POi	2 weeks	12 weeks	Radiological evidence
Benea et al. ²¹ (2015)	ORIF (arthroscopic reduction and internal fixation)	I, III	_____	8 weeks	12 weeks	Radiological evidence
Chen et al. ⁷ (2015)	ORIF (plate and screw)	I, II, III, IV, V	_____	12 weeks	_____	Radiological evidence
Giannotti et al. ²⁶ (2016)	ORIF (plate)	I, II, IV, V, VI	_____	5-6 weeks	_____	As tolerable.
Spanish et al. ¹⁷ (2011)	Internal fixation (LISS/ZPLT)	VI	_____	10-12 weeks	16 weeks	Bone callus Metaphysis
Malakasi et al. ⁶ (2013)	Hybrid ORIF/CREF	I, II, III, IV, V, VI	_____	ORIF: 9.8w Hybrid CREF: 12.9 W	_____	Radiological evidence
Solomon et al. ²⁰ (2011)	ORIF (plate and screw)	II	_____	POi	6 weeks	Radiological evidence
Gupta et al. ⁹ (2010)	JESS and percutaneous screw	V, VI	_____	12 weeks	13-19 weeks	Radiological evidence (cortical and deviation)
Mahajan et al. ¹⁹ (2009)	Several	I, II, III, IV, V, VI	_____	8 weeks	_____	Radiological evidence
Duan et al. ¹⁸ (2008)	ORIF + arthroscopy	I, II, III, IV, V	POi (brace)	8 weeks	12 weeks	_____
Kayali et al. ¹⁰ (2008)	Percutaneous screw + arthroscopy	I, II, III	_____	6 weeks	10 weeks	Radiological evidence.
Venkatesh et al. ¹⁴ (2006)	Arthroscopy and percutaneous screws	I, II, III, IV, V, VI	_____	_____	6 weeks	_____
Faldini et al. ⁸ (2005)	Hybrid CREF	VI	_____	POi	8-12 weeks	Radiological evidence.
Ali et al. ²⁴ (2003)	Circular CREF and percutaneous screw	V, VI	POi	3 weeks	3-6 weeks	As tolerable.
Horstmann et al. ¹² (2003)	Calcium phosphate cement/percutaneous screw/plate	II, III, VI	PO2	2-6 weeks	6-12 weeks	Radiological evidence
Van Glabbeek et al. ¹⁵ (2002)	Internal fixation via arthroscopy	I, II, IV, V	_____	6 weeks	8 weeks	_____
Larson et al. ²⁷ (2002)	Calcium phosphate Cement and ORIF	Review	_____	_____	6 weeks	Radiological evidence
Lobenhoffer et al. ¹³ (2002)	Calcium phosphate Cement and ORIF	I, II, III, VI	_____	PO2	_____	I, II, III: 2w. VI: 6w.
Kiefer et al. ¹¹ (2001)	Arthroscopic and graft/percutaneous screw/plate	I, II, III, VI	_____	POi	6 weeks	_____
Sament et al. ²⁸ (2012)	Closed reduction and clamping by percutaneous screw	I, II, IV, V	_____	6 weeks	12 weeks	Radiological evidence
Shen et al. ²² (2009)	Open reduction and internal fixation + B-TCP	II, V, VI	_____	6 weeks	_____	Radiological evidence

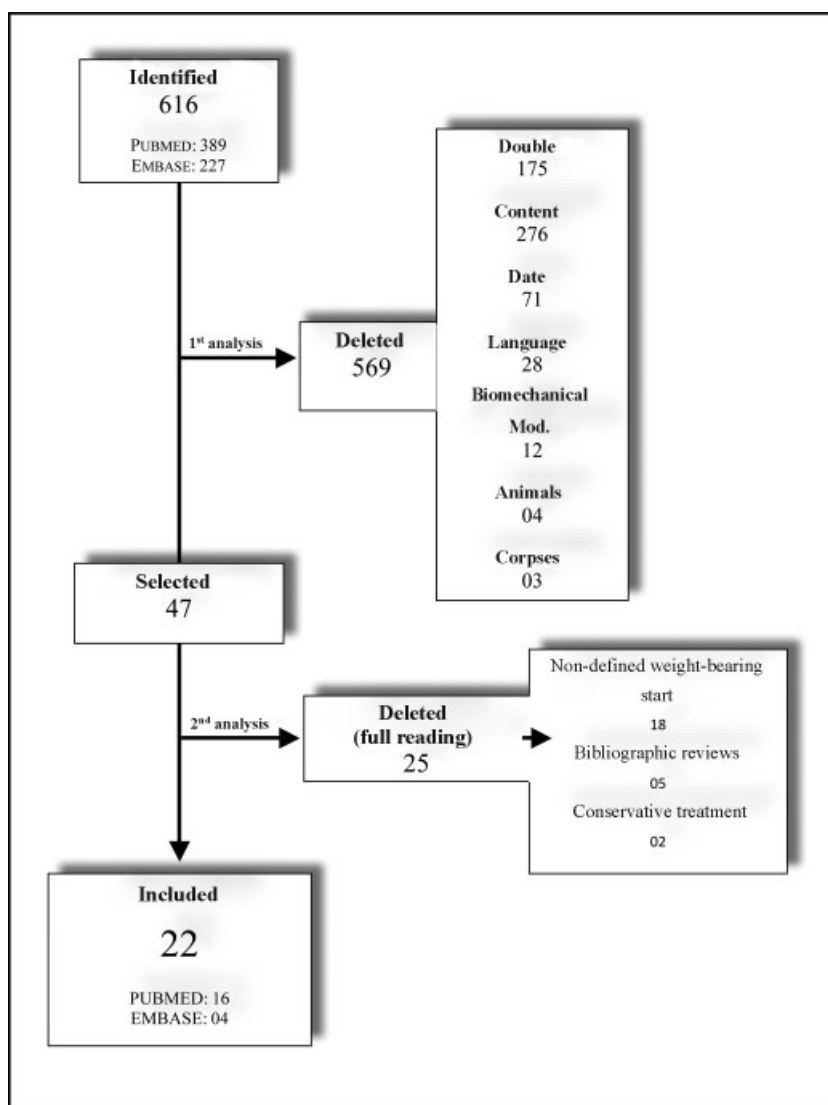


Fig. 2 Flowchart illustrating the dynamics of inclusion and exclusion of previously identified articles.

weight-bearing was described only in cases treated conservatively.

Therefore, 22 articles addressing the previously determined inclusion criteria were included in the present study.

Discussion

Tibial plateau fractures may evolve with complications, such as instability, axial deviation, joint incongruence, infection of the surgical wound, and soft tissue necrosis. Several fixation methods are used for the treatment of these fractures in order to achieve absolute stability between fragments and primary consolidation, enabling rehabilitation mobilization and weight-bearing in the lower limb affected by the first postoperative days.^{4,17}

According to the AO Manual,⁵ the release of 50% of weight-bearing should occur between 6 and 8 weeks following radiographic evidence, independently of the fracture type. Weight progression in low-energy fractures evolves to total progressive load between 8 and 12 weeks, and in the case of high-energy fractures, between 12 and 16 weeks.⁵

The method of arthroscopic fixation with percutaneous screws and/or support plates seems to be to achieve greater success in type I, II, and III Schatzker fractures, which are lower energy traumas.^{10,11,15,18} This technique provides anatomical reduction of the articular surface, allows repair of ligamental and meniscal lesions, and, because it is minimally invasive, it also presents low rates of complications (thromboembolism, infections), lower morbidity and shorter hospitalization time,¹⁵ and allows joint mobilization and early ambulation.^{18,21}

As for weight discharge in the arthroscopic approach, van Glabbeek et al.¹⁵ and Kayali et al.¹⁰ started the partial weight discharge in the 6th postoperative week, with the aid of the articulated brace, evolving to total weight discharge between the 8th and 20th postoperative weeks. It is important to note that when the Schatzker classification was higher or the fracture more comminuted, the results were not as satisfactory with the arthroscopic procedure.¹⁵ However, in cases of Schatzker's low-energy (I, II, and II) fractures arthroscopy is an alternative and effective method.¹⁰ Kiefer et al.¹¹ also in an arthroscopic approach, initiated partial weight discharge still

in the immediate postoperative period, and total progressive discharge beginning in the 6th week. According to the author, there was no harm to the stability and deviation of the fracture. However, Duan et al.¹⁸ released proprioceptive weight discharge associated with the use of an articulated brace in order to maintain the alignment and stability of the fracture, and the evolution of weight discharge occurred only after the 8th week.

An alternative to fractures is the use of calcium phosphate cement associated with percutaneous screws and support plates. Horstmann et al.¹² and Lobenhoffer et al.¹³ approached Schatzker fractures II, III, and VI with this technique and performed proprioceptive gait in the second postoperative period, evolving to partial load in the 2nd week and total weight discharge on the 6th week. In both studies, there was no loss of fracture reduction with calcium phosphate cement associated with early weight discharge, showing this method to be more resistant than other grafts (spongybone, cortical bone, and hydroxyapatite), tolerating torsional and compressive load forces. However, high cost for the material was presented as a disadvantage.^{12,13}

There is also a study that uses B-TCP ceramics, or tricalcium phosphate, for the purpose of transporting growth factors or structures for mesenchyme stem cells, acting as a resorbable osteoconductor.^{22,29} The use of the method is aimed at correcting depression in the tibial plateau for Schatzker II, V, and VI; its disadvantage is that the release of the partial weight starts in the 6th week and the B-TCP ceramics have weak stiffness when compared to calcium phosphate cement. According to the author, longer time without discharge weight can contribute to more satisfactory results of this technique.²⁰

Another widely described surgical technique is ORIF, which presents itself as a more invasive method, as the route of access harms soft tissues and exposes the fracture focus, which becomes more susceptible to infections.^{6,19} However, it allows the visualization and anatomical reduction of the fracture, and is often the most suitable method for comminuted fractures.¹⁵

One of the issues related to ORIF involves fracture stability and the best time to start unloading weight. Thinking about it, Solomon et al.²⁰ and Thewlis et al.²³ conducted studies in order to quantify the movements of bone fragments by radioesterometric analysis during the period of partial load or no load in the postoperative,³⁰ and in both studies it was observed that the migration of the fracture fragments was between groups (with and without load), showing that deviations of up to 3.0 mm do not present clinical alterations with immediate partial weight discharge and that this would give the necessary stimulus for bone consolidation, without interfering with fracture alignment and stability, contributing to rehabilitation.

In the case of bicondylar fractures (Schatzker V and VI), traumas are of greater energy and usually present significant soft tissue injury. In this case, hybrid CREF, associated with fixation of joint fragments with percutaneous screws is the option.^{8,9,24}

Some techniques are alternatives for most severe cases of fracture and Schatzker (IV, V, and VI), and Joshi's external

stabilization system (JESS) technique is one of them. It is recommended when the fractures are very comminuted and have great injury of soft tissues. It is a temporary external fixation associated with the fixation of a definitive screw.⁹ Another option is the less invasive stabilization system (LISS) technique with Zimmer periarticular locking plate system (ZPLT), which is an indirect reduction to obtain reduction without damaging the adjacent soft tissues, or without directly operating at the site of the fracture, considering the periosteal vascularization and favoring the healing process.¹⁷ One of the limitations of both techniques is the time to start the weight discharge, that occurs only between the 10th and 12th weeks.

The ORIF technique has the advantage of allowing early discharge of partial weight as demonstrated in the studies of Faldini et al.⁸ and Ali et al.²⁴ The limitation of this technique is the reduction in the accuracy of articular surface. The results obtained in these studies diverge from the results of the study performed by Malakasi et al.⁶ who compared ORIF with hybrid CREF for treatment of fractures of the tibial plateau and showed that although ORIF has greater morbidity, it allows the initiation of weight discharge earlier than CREF, irrespective of the type of Schatzker, with partial weight-bearing starting in average of 9.8 weeks for ORIF and 12.9 for CREF.

Taking into account the time of weight discharge and the severity of the fracture, it is observed that the onset and evolution to the total weight-bearing is related to the severity of the fracture, or whether or not the longer Schatzker will take to progress with the weight carrier in the affected lower limb.^{6,31}

Lobenhoffer et al.¹³ progressed in the weight carrier also as tolerated in Schatzker II, III, and VI fractures, and, like other studies,^{8,24,32} were based on the Rasmussen scoring system—considering the radiographs degree of depression and plateau width, in addition to possible deviations in valgus/lower limb varus. As for the clinical aspects, pain, capacity of ambulating, range of motion and stability in the affected lower limb are considered in the analysis.³² Still, three other studies^{11,12,33} do not mention their cargo support evolution criteria.

An important limitation of this review is that in all the studies included there was no consensus among the ideal time to discharge weight in TPFs. Some authors have already demonstrated that the early proprioceptive weight discharge is indicated and is also associated with success in consolidation and rehabilitation of these patients.^{20,23} Another limitation of the study relates to the time of weight progression. Some studies argue that the partial weight discharge initiated in the 6th week is an effective measure, since it respects the period of bone consolidation,^{10,15} but there are authors who argue that more comminuted fractures should have a slower load progression.^{9,16} In addition, the diversity of techniques used in the treatment of TPFs may lead to a bias in the results, since there are techniques that favor the process of consolidation and discharge of early weight^{12,13} and others that, although they present good results, delay the release of weight discharge.²²

Final Considerations

There is no consensus in the literature regarding weight-bearing in the postoperative period of TPFs, even though a relationship between fracture severity, use of graft, stability type and time to start and progress on the load bracket is observed. However, we have shown that most authors initiate partial load around the 6th week and full charge in the 12th week.

Through this literature review, it was possible to observe that there is a need for new randomized and controlled clinical studies regarding weight discharge in TPFs in the various surgical techniques.

Conflict of Interests

The authors declare that have no conflicts of interests.

Referências

- Weigel DP, Marsh JL. High-energy fractures of the tibial plateau. Knee function after longer follow-up. *J Bone Joint Surg Am* 2002; 84(09):1541-1551
- Hohl M, Part I. Fractures of the proximal tibia and fibula. In: Rockwood C, Green D, Bucholz R, editors. *Fractures in adults*. 3rd ed. Philadelphia: Lippincott; 1991
- Fenton P, Porter K. Tibial plateau fractures: a review. *Trauma* 2011;13(03):181-187
- Júnior MK, Fogagnolo F, Bitar RC, Freitas RL, Salim R, Jansen Paccola CA. Tibial plateau fractures. *Rev Bras Ortop* 2015;44(06):468-474
- Ruedi TP, Murphy WM. *AO principles of fracture management*. New York: Thieme Stuttgart; 2000
- Malakasi A, Lallo SN, Chronopoulos E, Korres DS, Efstathopoulos NE. Comparative study of internal and hybrid external fixation in tibial condylar fractures. *Eur J Orthop Surg Traumatol* 2013;23(01):97-103
- Chen HW, Chen CQ, Yi XH. Posterior tibial plateau fracture: a new treatment-oriented classification and surgical management. *Int J Clin Exp Med* 2015;8(01):472-479
- Faldini C, Manca M, Pagkrati S, et al. Surgical treatment of complex tibial plateau fractures by closed reduction and external fixation. A review of 32 consecutive cases operated. *J Orthop Traumatol* 2005;6(04):188-193
- Zahid M, Sherwani MKA, Siddiqui YS, Abbas M, Asif N, Sabir AB. The role of the JESS (Joshi's external stabilization system) fixator in the management of tibial plateau fractures which are associated with severe soft tissue injuries. *J Clin Diagn Res* 2010;4:3356-3361
- Kayali C, Oztürk H, Altay T, Reisoglu A, Agus H. Arthroscopically assisted percutaneous osteosynthesis of lateral tibial plateau fractures. *Can J Surg* 2008;51(05):378-382
- Kiefer H, Zivaljevic N, Imbriglia JE. Arthroscopic reduction and internal fixation (ARIF) of lateral tibial plateau fractures. *Knee Surg Sports Traumatol Arthrosc* 2001;9(03):167-172
- Horstmann WG, Verheyen CC, Leemans R. An injectable calcium phosphate cement as a bone-graft substitute in the treatment of displaced lateral tibial plateau fractures. *Injury* 2003;34(02):141-144
- Lobenhoffer P, Gerich T, Witte F, Tscherne H. Use of an injectable calcium phosphate bone cement in the treatment of tibial plateau fractures: a prospective study of twenty-six cases with twenty-month mean follow-up. *J Orthop Trauma* 2002;16(03):143-149
- Venkatesh R. Minimal invasive techniques in the management of tibial plateau fractures. *Curr Orthop* 2006;20:411-417
- van Glabbeek F, van Riet R, Jansen N, D'Anvers J, Nuyts R. Arthroscopically assisted reduction and internal fixation of tibial plateau fractures: report of twenty cases. *Acta Orthop Belg* 2002; 68(03):258-264
- Manidakis N, Dosani A, Dimitriou R, Stengel D, Matthews S, Giannoudis P. Tibial plateau fractures: functional outcome and incidence of osteoarthritis in 125 cases. *Int Orthop* 2010;34(04): 565-570
- Spagnolo R, Pace F. Management of the Schatzker VI fractures with lateral locked screw plating. *Musculoskelet Surg* 2012;96(02):75-80
- Duan XJ, Yang L, Guo L, Chen GX, Dai G. Arthroscopically assisted treatment for Schatzker type I-V tibial plateau fractures. *Chin J Traumatol* 2008;11(05):288-292
- Mahajan N. Evaluation of results of various operative method in the management of tibial plateau fractures in adults. *JK Science*. 2009;11(01):27-30
- Solomon LB, Callary SA, Stevenson AW, McGee MA, Chehade MJ, Howie DW. Weight-bearing-induced displacement and migration over time of fracture fragments following split depression fractures of the lateral tibial plateau: a case series with radiostereometric analysis. *J Bone Joint Surg Br* 2011;93(06):817-823
- Benea H, Tomoaia G, Martin A, Bardas C. Arthroscopic management of proximal tibial fractures: technical note and case series presentation. *Clujul Med* 2015;88(02):233-236
- Shen C, Ma J, Chen XD, Dai LY. The use of beta-TCP in the surgical treatment of tibial plateau fractures. *Knee Surg Sports Traumatol Arthrosc* 2009;17(12):1406-1411
- Thewlis D, Callary SA, Fraysse F, Solomon LB. Peak loading during walking is not associated with fracture migration following tibial plateau fracture: A preliminary case series. *J Orthop Res* 2015;33(09):1398-1406
- Ali AM, Burton M, Hashmi M, Saleh M. Outcome of complex fractures of the tibial plateau treated with a beam-loading ring fixation system. *J Bone Joint Surg Br* 2003;85(05):691-699
- Wang Y, Luo C, Zhu Y, et al. Updated Three-Column Concept in surgical treatment for tibial plateau fractures - A prospective cohort study of 287 patients. *Injury* 2016;47(07):1488-1496
- Giannotti S, Giovannelli D, Dell'Osso G, et al. Angular stable plates in proximal meta-epiphyseal tibial fractures: study of joint restoration and clinical and functional evaluation. *Musculoskelet Surg* 2016;100(01):15-18
- Larsson S, Bauer TW. Use of injectable calcium phosphate cement for fracture fixation: a review. *Clin Orthop Relat Res* 2002;(395): 23-32
- Sament R, Mayanger JC, Tripathy SK, Sen RK. Closed reduction and percutaneous screw fixation for tibial plateau fractures. *J Orthop Surg (Hong Kong)* 2012;20(01):37-41
- LeGeros RZ. Properties of osteoconductive biomaterials: calcium phosphates. *Clin Orthop Relat Res* 2002;(395):81-98
- Bottner F, Su E, Nestor B, Azzis B, Sculco TP, Bostrom M. Radiostereometric analysis: the hip. *HSS J* 2005;1(01):94-99
- Youdas JW, Kotajarvi BJ, Padgett DJ, Kaufman KR. Partial weight-bearing gait using conventional assistive devices. *Arch Phys Med Rehabil* 2005;86(03):394-398
- Rasmussen PS. Tibial condylar fractures. Impairment of knee joint stability as an indication for surgical treatment. *J Bone Joint Surg Am* 1973;55(07):1331-1350
- Chan YS. Arthroscopy- assisted surgery for tibial plateau fractures. *Chang Gung Med J* 2011;34(03):239-247