





Spastic Hips in Cerebral Palsy – Retrospective Study of Salvage with the McHale Procedure*

Quadrís espásticos da paralisia cerebral – Estudo retrospectivo do salvamento com a cirurgia de McHale

Helder Henzo Yamada¹  Dante Galvanese Amato Neto¹  Juliano Mangini Dias Malpaga¹ 
 Patricia Maria de Moraes Barros Fucs¹ 

¹ Orthopedics and Traumatology Department, Faculdade de Ciências Médicas, Santa Casa de Misericórdia de São Paulo, São Paulo, SP, Brazil

Address for correspondence Helder H. Yamada, Master, Rua Dr. Cesário Motta Jr., 112, São Paulo, SP, Brazil
 (e-mail: helderyamada@gmail.com; helder.henzo@gmail.com).

Rev Bras Ortop 2021;56(2):244–250.

Abstract

Objective To perform a retrospective and cross-sectional assessment to determine the pain and positional improvement of all patients with spastic cerebral palsy (CP) and severe hip deformity who underwent a McHale procedure in our center. A second objective was to analyze the potential complications from the procedure.

Methods All consecutive patients treated between 1995 and 2017 were analyzed. Clinically, the patients should present pain on hip mobilization, difficulty in positioning for sitting and hygiene care, and medical records with complete data; functionally was assessed through the Gross Motor Function Classification System (GMFCS). In the preoperative radiographs, we analyzed the migration percentage (MP), the type of deformity according to the Melbourne Cerebral Palsy Hip Classification Scale (MCPHCS), and the type of deformity of the femoral head. After the surgery, we assessed the proximal migration of the proximal femoral fragment, implant changes and/or failure, and potential heterotopic ossification. The outcomes were reported as successful (D1) in patients presenting remission of pain, painless mobility, and improved positioning, or unsuccessful (D2) in those presenting procedural failure that required a new surgery.

Results In total, 47 patients (53 hips) were treated. Functionally, 43 patients were classified as GMFCS V (91%), 3 as GMFCS IV patients (6%), and 1 as GMFCS III (2%). The mean age was 13 years and 2 months. The follow-up ranged from 1 year to 15 years and 4 months, with an average of 4 years and 8 months. A total of 36 patients (41 hips) presented successful (D1) outcomes after the McHale procedure, corresponding to 77% of our cases, whereas 11 (23%) cases had unsuccessful (D2) outcomes.

Keywords

- ▶ cerebral palsy
- ▶ hip/deformities
- ▶ hip/surgery

* Study performed by the Neuromuscular Diseases Group, Orthopedics and Traumatology Department, Faculdade de Ciências Médicas da Santa Casa de São Paulo, Santa Casa de Misericórdia de São Paulo, São Paulo, Brazil.

received
 September 17, 2019
 accepted
 April 15, 2020
 published online
 September 22, 2020

DOI <https://doi.org/10.1055/s-0040-1713391>.
 ISSN 0102-3616.

© 2020. Sociedade Brasileira de Ortopedia e Traumatologia. All rights reserved.

This is an open access article published by Thieme under the terms of the Creative Commons Attribution-NonDerivative-NonCommercial-License, permitting copying and reproduction so long as the original work is given appropriate credit. Contents may not be used for commercial purposes, or adapted, remixed, transformed or built upon. (<https://creativecommons.org/licenses/by-nc-nd/4.0/>)

Thieme Revinter Publicações Ltda., Rua do Matoso 170, Rio de Janeiro, RJ, CEP 20270-135, Brazil

Resumo

Conclusion The McHale procedure is a treatment option for GMFCS IV and V, but we must be aware of the potential complications.

Objetivo Fazer uma avaliação retrospectiva e transversal quanto à melhora da dor e do posicionamento de todos os pacientes portadores de paralisia cerebral (PC) espástica com deformidade grave no quadril submetidos ao procedimento de McHale em nosso centro. Secundariamente, objetivou-se analisar as possíveis complicações do procedimento.

Métodos Foram analisados todos os pacientes consecutivos tratados no período entre 1995 e 2017. Clinicamente, os pacientes deveriam apresentar dor à mobilização do quadril, dificuldade de posicionamento para se sentar e para os cuidados de higiene, e prontuário médico com dados completos; quanto ao grau de função motora, utilizou-se o Sistema de Classificação da Função Motora Grossa (Gross Motor Function Classification System, GMFCS, em inglês). A avaliação radiográfica no período pré-operatório analisou a porcentagem de migração (PM), o tipo de deformidade de acordo com a Escala de Classificação de Quadril na Paralisia Cerebral de Melbourne (Melbourne Cerebral Palsy Hip Classification Scale, MCPHS), e a deformidade da cabeça femoral. No período pós-operatório, analisaram-se a presença de migração proximal do fragmento do fêmur proximal, as alterações e/ou a falha do implante utilizado, e a possível ossificação heterotópica. Consideraram-se como desfechos: D1- satisfatório: remissão da dor, mobilidade indolor, melhora do posicionamento; e D2- insatisfatório: falha no procedimento, que necessitou de reabordagem cirúrgica.

Resultados No total, 47 pacientes (53 quadris) foram tratados. Funcionalmente, quanto à classificação no GMFCS, 43 pacientes eram GMFCS V (91%), 3 pacientes eram GMFCS IV (6%), e 1 paciente era GMFCS III (2%). A média da idade foi de 13 anos e 2 meses. O tempo de seguimento variou de 1 ano a 15 anos e 4 meses, com média de 4 anos e 8 meses. Quanto ao desfecho da cirurgia de McHale, ele foi satisfatório (D1) em 36 pacientes (41 quadris), perfazendo 77% dos nossos casos, e insatisfatório (D2) em 11 (23%) casos.

Conclusão A cirurgia de McHale é uma opção no tratamento para os níveis IV e V, mas devemos estar alertas para as possíveis complicações.

Palavras-chave

- ▶ Paralisia cerebral
- ▶ Quadril/deformidades
- ▶ Quadril/cirurgia

Introduction

Hip deformities occur in more than a third of children with cerebral palsy (CP), constituting the second most common deformity after equinus foot.¹⁻⁵

The “spastic hip disease” results from muscle imbalance in a growing skeleton. Flexion and adduction gradually become contractures until a deformity is established. The deformity in flexion and adduction and the limitation in joint mobility prevent or hinder general hygiene care and sitting position, significantly compromising the quality of life of these patients. In addition, degenerative joint changes can become painful, worsening the condition of such individuals.^{1,2}

The treatment of spastic hip deformities aims to maintain painless hip mobility and proper location, with a symmetrical range of motion compared to the contralateral side.^{1,2,5}

Subluxation or dislocation are surgical indications for hip reconstruction.^{2,4,6-13} However, femoral head deformity and joint incongruity mean that there is no opportunity for reconstruction. These cases require the so-called “salvage”

procedures, including proximal femoral resection arthroplasty,¹⁴ valgus osteotomy of the proximal femur with or without femoral head and neck resection (the McHale procedure),^{15,16} hip arthrodesis,¹⁷ total hip arthroplasty¹⁸ and proximal femur prosthetic interposition arthroplasty.^{1,13}

Even today, after several literature reviews on the subject¹⁹⁻²¹ there is no consensus on the best treatment for these cases. This is true especially because the publications are often case series, with a lack of uniformity regarding the conditions and comorbidities of the patients, as well as the therapeutic environment, that makes comparison difficult.

It is known that the pain associated with hip deformity in spastic patients is directly related to their quality of life.^{1,2,12} The main reason for treatment in patients with spastic CP with symptomatic and severe hip deformities who are no longer subject to reconstructive surgery is to improve pain and facilitate positioning.

The goal of the present study was to make a retrospective and cross-sectional evaluation of all patients with spastic CP with severe hip deformity undergoing the McHale procedure.

We performed a retrospective and cross-sectional assessment of all patients with spastic CP and severe hip deformity who underwent the McHale procedure¹⁵ in our center and determine pain and positional improvement. A second objective was to analyze the potential complications from the procedure.

Patients and Methods

The present study was approved by the Ethics Committee of our hospital (under CAEE 94352318.9.0000.5479), and the patients' legal guardians signed the informed consent forms allowing the inclusion of clinical data in the research.

All consecutive patients undergoing the McHale procedure between 1995 and 2017 were analyzed by the Neuro-muscular Diseases Group of our institution. The inclusion criteria were patients with spastic CP with subluxated or dislocated hips and femoral head deformity preventing joint reconstruction. Clinically, the patients presented pain during hip mobilization and difficulty in sitting and positioning for hygiene care; in addition, all of them had complete medical records. Patients with incomplete data and who did not return for outpatient evaluations were excluded.

No objective scale was used to assess the level of preoperative pain; the medical records informed that all patients had pain during mobilization of the affected hip and/or difficulties or intolerance to sit prior to the procedure. Since this is a retrospective evaluation, the improvement reported by the patient and/or caregiver at the last outpatient visit was considered. All patients are still being followed up in our service.

Radiographic evaluations were performed preoperatively and at the last outpatient evaluation, and they included an anteroposterior radiograph of the pelvis and panoramic posteroanterior and lateral views of the spine. Preoperatively, the radiographic pelvic analysis was performed using the following parameters: migration percentage (MP),²² type of deformity according to the Melbourne Cerebral Palsy Hip Classification Scale (MCPHCS)⁵ and the type of deformity of the femoral head.¹ Postoperatively, the proximal migration of a proximal femur fragment, implant alterations, and/or failure and potential heterotopic ossification were also determined. The Cobb angle was measured on a posteroanterior spine radiograph in supine position for the diagnosis of scoliosis; angles $\geq 40^\circ$ were deemed moderately severe.²³ Angles and distances with up to 2 decimal places were determined with the MB-Ruler software, version 5.3 for Windows (MB-Softwaresolutions, Iffezheim, Germany). The radiographic measurements were made by two experienced and independent evaluators, and the interobserver intraclass correlation coefficient (ICC) was calculated.

In total, 8 patients (15 hips) had been previously submitted to surgical procedures, including 7 bilateral adductor tenotomies and 1 open hip reduction with variant osteotomy, proximal femur external rotation and unilateral Dega pelvic osteotomy, which was performed in another service.

The surgical technique, according to its original description (McHale et al.¹⁵), includes the following steps: with the patient in horizontal supine position, tenotomy of the adduc-

tors is performed by their route; the hip is exposed through an anterolateral (Watson-Jones) approach. With the femoral head exposed, an osteotomy is performed at the base of the femoral neck using a nitrogen saw. The femoral head is removed, while the ligament teres is preserved within the acetabulum. A bone wedge with a lateral base is removed from the proximal femur at the level of the lesser trochanter to promote an abduction of approximately 45° . The osteotomy is fixed using a straight dynamic compression plate (DCP) or locking compression plate (LCP) (Synthes, Solothurn, Switzerland) molded for distal fragment abduction for an average of 45° . The lesser trochanter is moved to the acetabulum. The ligament teres is then sutured in the tendon of the psoas muscle. A capsulorrhaphy is performed, and the lower part of the capsule often cannot be closed. Suture is performed by planes. Postoperative immobilization is not required.¹⁵

The postoperative complications were divided into minor and major events. Minor complications were defined as implant-related pain with or without implant exposure, fractures of operated lower limbs, and presence of heterotopic ossification. The major complications included further hospitalization and referral to another surgical procedure.

The final evaluation addressed two outcomes: a successful outcome (D1), in which the patients remained well (with less pain and able to sit) or presented minor complications after the procedure, and an unsuccessful outcome (D2), in which the patients presented major complications and subsequently underwent a new surgical procedure, the Castle procedure.¹⁴

Results

In total, 57 patients were treated, with 65 operated hips. We excluded 10 patients (12 hips) who did not return for the reassessment; as such, 47 patients (53 hips) comprised the study group.

A total of 19 patients were male, and 28 were female. Regarding laterality, the right hip was affected in 15 patients, whereas the left hip was affected in 26 individuals; there were 6 bilateral cases. According to the Gross Motor Function Classification System (GMFCS),²⁴ there were 43 level-V patients (91%), 3 level-IV patients (6%), and 1 level-III patient (2%). The mean age of the patients at the time of the surgery was 13 years and 2 months (median: 12 years and 8 months), ranging from 5 years and 4 months to 35 years and 10 months (**► Table 1**).

On average, the length of the hospital stay was of five days; consolidation of the osteotomy required six to eight weeks.

The follow-up period ranged from 1 year (12 months) to 15 years and 4 months (184 months), with a mean time of 4 years and 8 months (56 months) and a median time of 3 years and 10 months (46 months).

In the radiographic evaluation, the ICC was excellent, higher than 0.80; therefore, only the arithmetic mean value and the final median value were used. The initial MP ranged from 60% to 100%, with an average of 96.75% and a median value of 100%; 6 hips presented 33% to 89%, while 47 hips has MPs higher than 90%. According to the MCPHCS, 6 hips were

Table 1 Demographic data of the patients

Number of patients (number of hips)	47 (53)
Age (years and months)	mean value: 13 + 2 (163.28) minimum value: 5 + 4 (64) maximum value: 35 + 10 (430)
Gender	male: 19 female: 28
GMFCS	III - 1 IV - 3 V - 43
Previous surgeries	8 (15 hips): 7-bilateral adductor tenotomy 1-open reduction + femoral and pelvic osteotomy
Presence of scoliosis	35 (75%) cases
Follow-up years + months (months)	minimum time: 1 + 0 (12) maximum time: 15 + 4 (184) mean time: 4 + 8 (56) median time: 3 + 10 (46)

Abbreviation: GMFCS, Gross Motor Function Classification System.

Table 2 Radiographic outcomes

		Percentage
Migration percentage	33%-89% - 6 cases	11%
	> 90% - 47 cases	89%
Type of femoral-head deformity	TYPE 1 - 10	19%
	TYPE 2 - 22	41%
	TYPE 3 - 21	40%
MCPHCS Grade	Grade 5-6 cases	11%
	Grade 6-47 cases	89%

Abbreviation: MCPHCS, Melbourne Cerebral Palsy Hip Classification Scale.

grade 5 and 47 hips were grade 6. Regarding femoral head deformity, 10 hips (19%) were grade 1, 22 (41%) were grade 2, and 21 (40%) were grade 3. Among the 47 patients, 35 (75%) had scoliosis at the last reevaluation (→ **Table 2**).

Clinically, there was no change in the functional level of the patients. In total, 25 individuals (53%; 29 hips) presented

pain reduction or remission, in addition to free, painless mobility and improved positioning (→ **Figure 1**).

Minor complications were reported in 11 patients (23%; 12 hips), including 8 patients subjects (9 hips) with pain and/or exposure of the implant material that required its removal. The average time between the 2 procedures was 1 year and 9 months; after the removal, the surgical wound healed with no complications or pain. Within this group, one patient was operated bilaterally, and the implant exposure occurred only on one side, in what was deemed a minor complication. Two patients had a fracture at the ipsilateral femoral shaft; one case was treated with open reduction and internal fixation with plate and screws, while the other was submitted to a closed reduction and plaster placement. Both progressed satisfactorily, with fracture consolidation. One last patient (one hip) presented painful dislocation of the contralateral hip and underwent a Castle procedure; the side operated according to the McHale technique was well, mobile and pain free. Therefore, 36 patients (41 hips) submitted to the McHale technique presented successful outcomes (D1), with no pain, free lower limb mobility and ability to sit in a wheelchair, corresponding to 77% of our cases.

Major complications were observed in 11 patients (12 hips), including 6 subjects (6 hips) who underwent implant removal and unilateral Castle procedure, 3 patients (4 hips) who underwent implant removal and bilateral Castle procedure, and 2 patients (2 hips) treated with a hip arthrodesis. Of the latter, one case (one hip) presented a femoral fracture, which was treated with external fixation and subsequent hip arthrodesis revision, whereas the other case underwent two hip arthrodesis revisions and evolved with no consolidation, requiring a Castle procedure. Due to procedural failure, the outcome was considered unsuccessful (D2) in 11 (23%) cases (→ **Table 3**).

The postoperative radiographs showed no heterotopic ossification or proximal migration of the operated femur.

Patients still presenting pain were subsequently submitted to the Castle procedure, which resulted in pain remission and improved sitting position; however, this assessment is not within the scope of the present study (→ **Figure 2**).

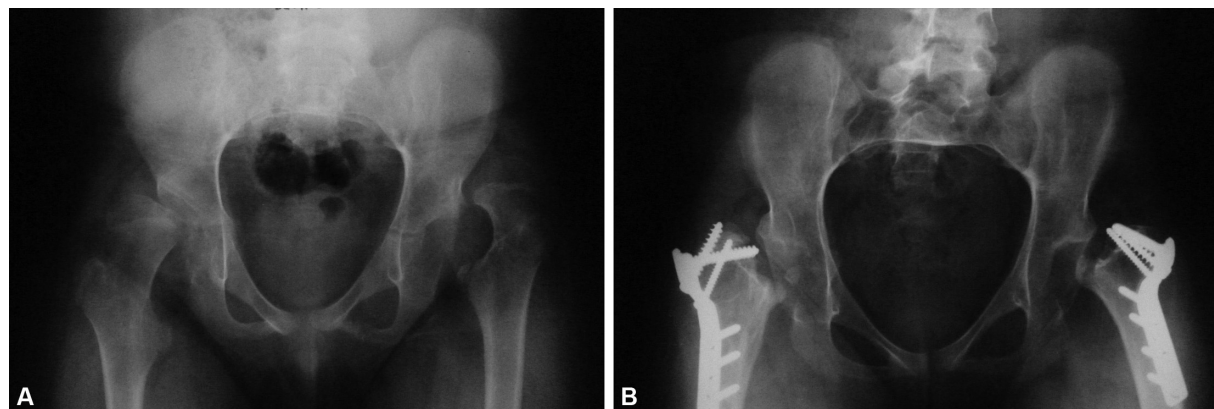


Fig. 1 Tetraparetic female patient, GMFCS grade V. (A) Pelvic radiograph at the initial follow-up, at 12 years and 2 months old. (B) Postoperative pelvic radiograph, 4 years and 2 months after the bilateral McHale surgery at 16 years old.

Table 3 Complications and outcomes

	Without complications	With complications	
Number of patients (hips)	25 (28) - 53%	22 (24) - 47%	
		<i>Minor complications</i> 11 (12) - 23%	<i>Major complications</i> 11 (12) - 23%
		8 (9) removals of implant	6 (6) implant removals and unilateral Castle procedure
		2 (2) ipsilateral femur fractures	3 (4) implant removals and bilateral Castle procedure
		1 (1) implant removal and contralateral Castle procedure	2 (2) hip arthrodeses
Outcomes	<i>D1—successful outcome</i>		<i>D2—unsuccessful outcome</i>

Discussion

Hip dislocation is common, and its incidence is directly related to the severity of the spasticity and the functional degree of the patient.^{1,3,4,10–13,25} According to the literature, the incidence of dislocation associated pain ranges from 25% to 55%, reaching up to 90% in the most severe cases.^{1,6,26} The same was verified in our patients, since most of them presented functional levels IV and V.

Since 79.5% of the cases present scoliosis,⁷ sometimes it is difficult to identify whether pain was due only to the dislocation or to the scoliosis in these critically ill patients. The

relationship between hip morphology and pain in subjects with CP is unclear and remains controversial. Some studies have reported high levels of pain in individuals with dislocated hips, and many adolescents require “salvage surgery”, which is defined as hip joint loss.^{1,2} The factors accounting for pain in dislocated hips can include degeneration of the articular cartilage, the associated inflammatory response, and an overload of pain mediators at the hip joint capsule.²⁷ The severity and frequency of the pain increased with the increase in physical disability, according to the GMFCS classification.⁸ Regarding the MCPHCS,⁵ due to the severity of the condition and the difficulties in accessing treatment in our health

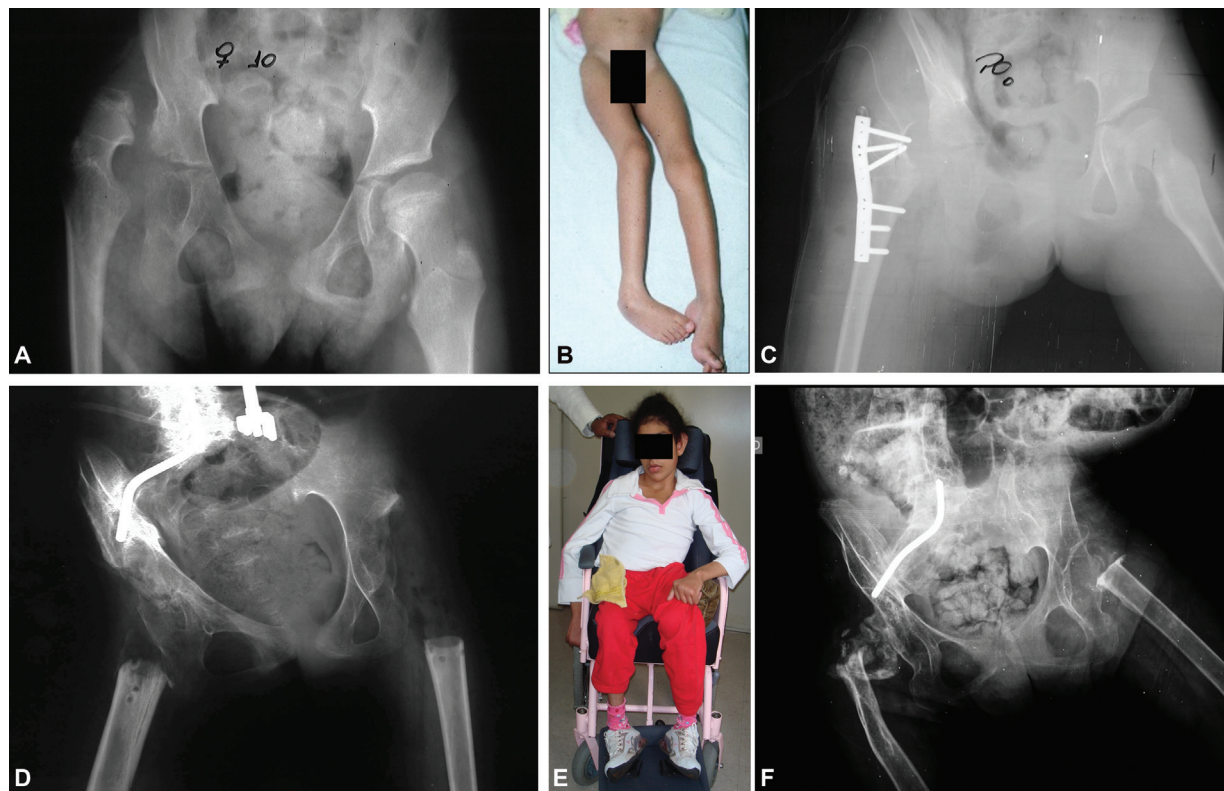


Fig. 2 Tetraparetic female patient, GMFCS grade V. (A) Pelvic radiograph at the initial follow-up, at 10 years and 2 months old. (B) Clinical image at the initial follow-up, at 10 years and 2 months old. (C) Pelvic radiograph soon after a McHale procedure on the right hip. (D) Pelvic radiograph soon after a bilateral Castle procedure at 14 years old. (E) Clinical image 7 years after a bilateral Castle at 21 years old. (F) Postoperative pelvic radiograph 14 years after a bilateral Castle technique, at 29 years old.

system, there were 10 hips at level 5 and 43 hips at level 6, indicating that salvage surgery was the only treatment option. The decision to perform the McHale procedure, except in cases of severe femoral head deformity, is made intraoperatively when more than 50% of the joint surface is injured. In cases with 30% and 50% of joint surface lesion, we perform a reconstructive surgery.

In dislocated hips, the lesser trochanter is usually positioned in front of the acetabular cavity, requiring only osteotomy of the proximal femoral valgus. Head resection improves abduction – in our opinion, it complements the first description of intertrochanteric valgus osteotomy by Schanz.²⁸ Tenodesis of the ligament teres in the psoas tendon, as in the original description, also provides greater stability to the construction and prevents proximal migration, which in fact happened in our cases.

In our patients, unilateral deformity had a special indication for the McHale procedure because, although it is a salvage procedure, it results in a more harmonious aspect of the pelvis. This new positioning reflects in the postoperative improvement of the patient's position, which was reported in our cases and in those of other authors.²⁹

Regarding complications, in the original description of the McHale procedure,¹⁵ with four patients, the authors mention postoperative pain, believing it to be the result of friction of the neck surface within the capsule of the closed joint. In our cases, the patients reported pain for a long period, on average for six months, and no anatomical explanation was found. These patients need close monitoring for pain control, which is performed with medication and physical therapy. Cases of protrusion of the osteosynthesis plate reaching the skin required the surgical removal of the implant material. Plate exposure generally occurs in patients with low weight, low muscle mass and poor nutritional support, often from the public health system, with difficult preoperative compensation; once treated with removal of the implant material and local care, the patients become asymptomatic. Adding the patients who remained with the implant and those who only underwent its removal due to the complication of plate exposure, 77% of the hips showed good evolution, with no other major postoperative complications, despite their functional severity.

Another complication in GMFCS-V patients, which is not uncommon, is lower limb fracture; in patients unable to walk, with visibly low bone mass (although undetermined) and joint contractures, any sudden movements during care represent important risk factors for fractures. Depending on the type and location of the fracture, the treatment can be closed or open, always considering the patient's functional aspect. A fracture episode does not imply that, after treatment, the goal of the McHale procedure has not been achieved. As such, fractures were considered minor complications.

For some patients, pain was an important limiting factor for daily care, even after the McHale procedure. These cases required an expanded resection and conversion into a Castle technique. The goal was always to relieve pain and improve patient positioning.

Another option for the two patients after failure of the McHale osteotomy was hip arthrodesis; in the first subject, with functional level V, this was an attempt for hip stabilization and pain resolution. However, the vertebral deformity worsened, and, after a vertebral arthrodesis, the patient was unable to sit; subsequently, a bilateral Castle procedure was successfully performed. The other patient, with functional level IV, despite having an ipsilateral femoral fracture that was treated with an external fixator, presented and still maintains a good position.

We agree with the literature^{6,19,20,30} that the surgical treatment for painful and dislocated spastic hips in the context of CP is not perfect. A large percentage of failures remain, despite the numerous surgical techniques designed to treat this condition. We must consider that, even though the literature uses the GMFCS as an evaluation standard, spasticity homogeneity in patients with the same functional level is unclear. Furthermore, these patients often present comorbidities that influence the outcome of any surgical treatment.

The present study has some limitations. Since it was based on an analysis of medical records, it was not possible to reevaluate the patients regarding pain using validated scales. A questionnaire was also not applied to analyze patients' quality of life. The medical records included the description of the physical examination, the presence or absence of pain during hip movement and difficulties in patient positioning. On the other hand, all patients were treated by the same medical team, using the same treatment protocol, which in some way standardizes their assessment. Prospective studies prioritizing the impact on quality of life are required.

Conclusion

The present study shows that McHale procedure is an option to treat painful hips in cases of spastic CP with functional levels IV and V, leading to an improvement in pain and patient positioning; however, we must be prepared to address the potential complications, such as fractures and the persistence of pain.

Conflict of Interests

The authors have no conflict of interests to declare.

References

- 1 Miller F. Cerebral Palsy. New York: Springer Science; 2005
- 2 Horstmann HM, Bleck EE. Orthopaedic Management in Cerebral Palsy. London: MacKeith Press; 2007:344–379
- 3 Robin J, Graham HK, Baker R, et al. A classification system for hip disease in cerebral palsy. *Dev Med Child Neurol* 2009;51(03):183–192
- 4 Robin J, Graham HK, Selber P, Dobson F, Smith K, Baker R. Proximal femoral geometry in cerebral palsy: a population-based cross-sectional study. *J Bone Joint Surg Br* 2008;90(10):1372–1379
- 5 Howard JJ, Khot A, Graham HK. The hip in cerebral palsy. In: Alshryda S, Howard J, Huntley J, Schoenecker J, eds. *The pediatric and adolescent hip*. Basel, Switzerland: Spinger Nature Switzerland; 2019:467–530
- 6 Wright PB, Ruder J, Birnbaum MA, Phillips JH, Herrera-Soto JA, Knapp DR. Outcomes after salvage procedures for the painful dislocated hip in cerebral palsy. *J Pediatr Orthop* 2013;33(05):505–510

- 7 Knapp DR Jr, Cortes H. Untreated hip dislocation in cerebral palsy. *J Pediatr Orthop* 2002;22(05):668–671
- 8 Wawrzuta J, Willoughby KL, Molesworth C, et al. Hip health at skeletal maturity: a population-based study of young adults with cerebral palsy. *Dev Med Child Neurol* 2016;58(12):1273–1280
- 9 Terjesen T. The natural history of hip development in cerebral palsy. *Dev Med Child Neurol* 2012;54(10):951–957
- 10 Shore BJ, Yu X, Desai S, Selber P, Wolfe R, Graham HK. Adductor surgery to prevent hip displacement in children with cerebral palsy: the predictive role of the Gross Motor Function Classification System. *J Bone Joint Surg Am* 2012;94(04):326–334
- 11 Shore BJ, Graham HK. Management of moderate to severe hip displacement in nonambulatory children with cerebral palsy. *JBJS Rev* 2017;5(12):e4
- 12 Ramstad K, Terjesen T. Hip pain is more frequent in severe hip displacement: a population-based study of 77 children with cerebral palsy. *J Pediatr Orthop B* 2016;25(03):217–221
- 13 Silverio AL, Nguyen SV, Schlechter JA, Rosenfeld SR. Proximal femur prosthetic interposition arthroplasty for painful dislocated hips in children with cerebral palsy. *J Child Orthop* 2016;10(06):657–664
- 14 Castle ME, Schneider C. Proximal femoral resection-interposition arthroplasty. *J Bone Joint Surg Am* 1978;60(08):1051–1054
- 15 McHale KA, Bagg M, Nason SS. Treatment of the chronically dislocated hip in adolescents with cerebral palsy with femoral head resection and subtrochanteric valgus osteotomy. *J Pediatr Orthop* 1990;10(04):504–509
- 16 Girdlestone GR. Acute pyogenic arthritis of the hip: an operation giving free access and effective drainage. *Lancet* 1943;241:419–421
- 17 Fucs PM, Yamada HH. Hip fusion as hip salvage procedure in cerebral palsy. *J Pediatr Orthop* 2014;34(Suppl 1):S32–S35
- 18 Root L, Goss JR, Mendes J. The treatment of the painful hip in cerebral palsy by total hip replacement or hip arthrodesis. *J Bone Joint Surg Am* 1986;68(04):590–598
- 19 Kolman SE, Ruzbarsky JJ, Spiegel DA, Baldwin KD. Salvage options in the cerebral palsy hip: a systematic review. *J Pediatr Orthop* 2016;36(06):645–650
- 20 de Souza RC, Mansano MV, Bovo M, et al. Hip salvage surgery in cerebral palsy cases: a systematic review. *Rev Bras Ortop* 2015;50(03):254–259
- 21 Givon U. Management of the spastic hip in cerebral palsy. *Curr Opin Pediatr* 2017;29(01):65–69
- 22 Reimers J. The stability of the hip in children. A radiological study of the results of muscle surgery in cerebral palsy. *Acta Orthop Scand Suppl* 1980;184(184):1–100
- 23 Murphy RF, Mooney JF III. Current concepts in neuromuscular scoliosis. *Curr Rev Musculoskelet Med* 2019;12(02):220–227
- 24 Palisano R, Rosenbaum P, Walter S, Russell D, Wood E, Galuppi B. Development and reliability of a system to classify gross motor function in children with cerebral palsy. *Dev Med Child Neurol* 1997;39(04):214–223
- 25 Flynn JM, Miller F. Management of hip disorders in patients with cerebral palsy. *J Am Acad Orthop Surg* 2002;10(03):198–209
- 26 Soo B, Howard JJ, Boyd RN, et al. Hip displacement in cerebral palsy. *J Bone Joint Surg Am* 2006;88(01):121–129
- 27 Masłoń A, Józwiak M, Pawlak M, Modrzewski T, Grzegorzewski A. Hip joint pain in spastic dislocation: aetiological aspects. *Dev Med Child Neurol* 2011;53(11):1019–1023
- 28 Schanz A. Zur Behandlung der veralteten angeborenen Hüftverrankung. *Munch Med Wochenschr* 1922;23:930–931
- 29 Leet AI, Chhor K, Launay F, Kier-York J, Sponseller PD. Femoral head resection for painful hip subluxation in cerebral palsy: Is valgus osteotomy in conjunction with femoral head resection preferable to proximal femoral head resection and traction? *J Pediatr Orthop* 2005;25(01):70–73
- 30 Boldingh EJ, Bouwhuis CB, van der Heijden-Maessen HC, Bos CF, Lankhorst GJ. Palliative hip surgery in severe cerebral palsy: a systematic review. *J Pediatr Orthop B* 2014;23(01):86–92