



Original Article

Revision of unicompartmental knee arthroplasty: implants used and causes of failure[☆]



Alan de Paula Mozella^{*}, Felipe Borges Gonçalves, Jansen Osterno Vasconcelos, Hugo Alexandre de Araújo Barros Cobra

Knee Surgery Center, Instituto Nacional de Traumatologia e Ortopedia (Into), Rio de Janeiro, RJ, Brazil

ARTICLE INFO

Article history:

Received 3 April 2013

Accepted 9 April 2013

Available online 31 March 2014

Keywords:

Arthroplasty, replacement, knee

Revision

Bone graft

ABSTRACT

Objective: to determine the causes of unicondylar knee arthroplasty failures, as well as identify the implants used and the need of bone grafting in patients undergoing revision UKA in Center of Knee Surgery at the Instituto Nacional de Traumatologia e Ortopedia (INTO) in the period between January 1990 and January 2013.

Methods: a retrospective analysis of the medical documentation and imaging, determining the cause of failure of UKA and the time of its occurrence, as well as prosthetic components implanted during the review and the need for bone grafting.

Results: in this study, 27 UKA failures in 26 patients were included. Collapse of one or more components was the main cause of failure, occurring in 33% of patients. Aseptic failure was identified in 30% of cases, progression of osteoarthritis in 15%, infection and pain 7% each, and osteolysis and polyethylene failure in 4% each. Early failure occurred in 41% of all revisions of UKA and late failure in 59%. 23 patients have undergone revision of UK.

Conclusion: in 35% of revisions the use of bone grafting was needed in tibial area; in 3 cases we needed allograft from Tissue Bank. We did not use metal increase in any of the revision. In one patient we used implant constraint for instability.

© 2014 Sociedade Brasileira de Ortopedia e Traumatologia. Published by Elsevier Editora Ltda. All rights reserved.

Revisão de artroplastia unicompartmental de joelho: implantes usados e causas de falha

RESUMO

Objetivo: determinar as causas de falha da artroplastia Unicondilar, assim como identificar os implantes utilizados e a possível necessidade de enxertia óssea nos pacientes submetidos à cirurgia de revisão de AUJ no Centro de Cirurgia do Joelho do Instituto Nacional de Traumatologia e Ortopedia - INTO, no período entre janeiro de 1990 a janeiro de 2013 foram analisados.

Métodos: análise retrospectiva da documentação médica e exames de imagem, determinando-se a causa da falha da AUJ e o momento de sua ocorrência, assim como os componentes protéticos implantados durante a revisão e a necessidade de enxertia óssea.

Palavras-chave:

Artroplastia do joelho

Revisão

Enxerto ósseo

[☆] Please cite this article as: Mozella AdP, Backer RC, Borges Gonçalves F, Osterno Vasconcelos J, de Araújo Barros Cobra HA. Revisão de artroplastia unicompartmental de joelho: implantes usados e causas de falha. Rev Bras Ortop. 2014;49:154-159.

^{*} Corresponding author.

E-mail: apmozella@terra.com.br (A.d.P. Mozella).

2255-4971/\$ - see front matter © 2014 Sociedade Brasileira de Ortopedia e Traumatologia. Published by Elsevier Editora Ltda. All rights reserved. <http://dx.doi.org/10.1016/j.rboe.2014.03.018>

Resultados: foram incluídos nesta série 27 falhas de revisão de AUJ (26 pacientes). Colapso (afundamento) de um ou mais componentes representou a principal causa de falha, ocorrendo em 33% dos pacientes, soltura asséptica foi identificado em 30% dos casos, por progressão da osteoartrose em 15%, infecção e dor em 7% cada, desgaste do polietileno e osteólise em 4% cada. Falha precoce ocorreu em 41% de todas as indicações de revisões e falha tardia em 59%. A cirurgia de revisão da artroplastia unicompartmental foi realizada em 23 pacientes.

Conclusões: em 35% das cirurgias de revisão foi necessária enxertia óssea no lado tibial, sendo três casos necessário enxerto homólogo de Banco de Tecidos Músculo Esquelético. Não utilizamos aumento metálico em nenhum caso. Em um caso foi implantado prótese semiconstrita por instabilidade.

© 2014 Sociedade Brasileira de Ortopedia e Traumatologia. Publicado por Elsevier Editora Ltda. Todos os direitos reservados.

Introduction

Unicompartmental knee arthroplasty (UKA) was introduced into clinical practice for treating unicompartmental osteoarthritis by McKeever,¹ who performed the first implant in 1952. At the end of the 1960s, Marmor² disseminated the technique and it was subsequently advocated by Cartier et al.³

Over the course of these years, the popularity of this technique and the enthusiasm for applying it oscillated greatly. Several short and medium-term studies published in the 1980s, which compared the clinical and radiographic results from this technique, came to unfavorable conclusions because they found that the results were not reproducible and there was a high failure rate, in relation to total knee arthroplasty (TKA).^{2,4-6}

Over the last decade, the advent of the concepts of minimally invasive surgery together with evolution of the rigor of patient selection and development and refinement of surgical techniques and implant design have led to favorable evolution of the clinical results and, consequently, renewed interest in UKA.^{7,8}

Recently published studies, with medium and long-term follow-up, which evaluated unicompartmental arthroplasty using modern implants in properly selected patients, have confirmed these good and excellent results and have demonstrated durability comparable to that of TKA.⁹⁻¹²

Although UKA is a therapeutic method of proven effectiveness and safety, it may lead to either early or late failure with unsatisfactory results in a few cases.^{13,14} In the initial series reported by Marmor,² with first-generation implants, reoperation was necessary in 35% of the cases. Studies analyzing modern implants have identified rates of conversion to TKA ranging from 6% to 8%.¹⁵⁻¹⁷

Preservation of the bone stock in cases of failure of UKA theoretically makes conversion to conventional total arthroplasty possible. Thus, there would not be a need for metallic expanders, intramedullary nails, bone grafts or increased constriction of the implants.^{18,19}

However, several authors have questioned the possibility of converting TKA without the need for metallic expanders, intramedullary nails or bone grafts.²⁰⁻²⁴

The aims of the present study were to determine the causes of failure of UKA in patients who underwent revision

at a single hospital institution and to identify the implants used and the possible need for bone grafting.

Materials and methods

The medical files of patients who underwent UKA revision surgery at the Knee Surgery Center of the National Institute of Traumatology and Orthopedics (Instituto Nacional de Traumatologia e Ortopedia, INTO) between January 1990 and January 2013 were analyzed.

This study was firstly submitted to and approved by this institution's Research Ethics Committee.

A retrospective analysis was conducted on the medical files and the cause of UKA failure and time of its occurrence were determined, along with the prosthetic components implanted during the UKA revision and any need for bone grafting.

Demographic data were gathered and the patients' histories, preoperative physical examinations, laboratory tests and imaging examinations were evaluated, along with the surgical descriptions and findings from the operation. In addition, information obtained from cultures on fluids and tissues was analyzed.

UKA revision was defined as any surgical procedure performed subsequent to unicompartmental arthroplasty in which prosthetic components were removed, added or exchanged.

UKA failures were categorized in conformity with current concepts in the literature, as due to mechanical, septic or disease progression factors, in compartments that had not come back to the surface.

Mechanical failure of UKA was defined as situations in which alterations to one or more compartments occurred, culminating in imposing limitations on the functioning of the prosthetic device and, consequently, limitations on the clinical results.

Failures due to mechanical alterations were subdivided into loosening of one or more components of the prosthetic device, worn-out polyethylene, migration or collapse of one or more components, instability and periprosthetic fractures.

Diagnoses of infection were proven based on the criteria established by the Centers for Disease Control and Prevention (CDC), in the USA.²⁵

Progression of osteoarthritis in compartments that had not been replaced by a prosthetic implant, which caused

clinical manifestations of pain and functional limitation that incapacitated the individual with regard to activities of daily living, were considered to be UKA failures and indicated the need for conversion to TKA. Manifestations of this nature were proven by means of radiographic examinations with weight-bearing, when these showed severe degenerative alterations in compartments that had not come back to the surface.

In chronological terms, failures were divided into early, when they occurred not more than two years after UKA, or late, when they occurred after this time.

Data relating to the implant used during the unicompartmental arthroplasty procedure and the revision surgery were gathered from the surgical report.

The unicompartmental implants used were the Omnifit implant (Stryker®) with a first-generation cemented fixed metallic platform and the Miller Galante implant (Zimmer®) with the same specifications, of second and third generations.

The implants used during the revision surgery were part of the PFC Sigma DePuy® system and were categorized as primary conventional or semi-constricted (Total Condylar III DePuy®).

Likewise, we analyzed occurrences of bone defects that may have existed and how they were managed: bone grafting, with discrimination between autologous and homologous; and also use of wedge-like metallic expanders, with or without associated intramedullary nails.

Results

Twenty-seven UKA revision surgeries were included in this series (26 patients). Ten patients were male and 17 were female. Their ages at the time of the conversion procedure on the UKA ranged from 45 to 78 years, with a mean of 64.8 years. The failure of the unicompartmental arthroplasty occurred on the right side in 14 patients and on the left side in 13. In 25 patients, the unicompartmental arthroplasty had been performed at INTO and in one case, at another institution.

The most prevalent etiology for UKA was unicompartmental osteoarthritis, in the cases of 14 patients (52%), followed by osteonecrosis of the medial femoral condyle in 11 cases (41%), while UKA was post-traumatic in two cases (7%).

Unicompartmental arthroplasty was performed in the medial compartment in 22 patients and in the lateral compartment in five.

In evaluating the total sample of 27 UKA failures, collapse (sinking) of one or more components was the main cause of failure, in 33% of the patients (nine cases). Aseptic loosening was the second most frequent cause of failure, in 30% of the cases (eight patients). These were followed, in order of prevalence, by the following other causes: progression of osteoarthritis in 15% (four patients), infection and pain in 7% each (two patients) and worn-out polyethylene and osteolysis in 4% each (one patient).

Cases of loosening of only one component occurred more frequently on the tibial side (60%) (Fig. 1).

Early failure of the UKA occurred in 11 cases, which represented 41% of all the indications for revision made during the period studied. Late failure occurred in 16 cases and corresponded to 59%.

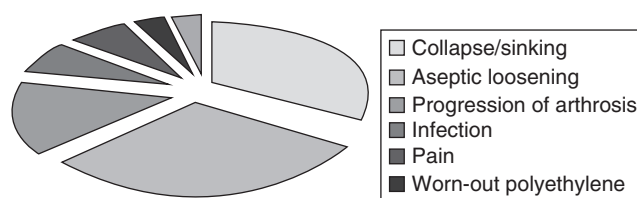


Fig. 1 – Distribution of the causes of UKA failure (n = 27).

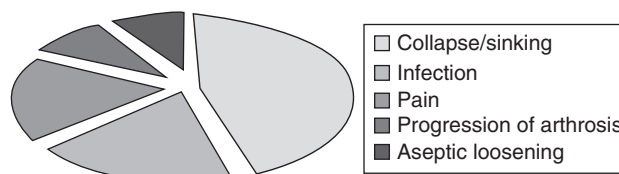


Fig. 2 – Distribution of early causes of UKA failure (n = 11).

The main cause of early failure was collapse/sinking of the tibial component, in 45.5% of the cases (five times). This was followed by infection and pain, in 18.25% of the patients (two cases), among other causes in smaller numbers. Progression of the arthrosis and loosening of the femoral component were identified as the cause of revision in 9% each (one case) (Fig. 2).

The main cause of failure in the group with revision after more than two years (16 patients) was aseptic loosening of one or more components, in 44% (seven cases). This was followed by collapse/sinking of one or more components in 25% each (four cases) and progression of the osteoarthritis in 19% (three patients). Worn-out polyethylene and osteolysis were identified in 6% each (one case).

In the cases of loosening or migration of a single component, this occurred on the tibial side in 75% of the cases (Fig. 3).

Revision surgery on unicompartmental arthroplasty was performed on 23 patients. Detailed analysis on the implants used and the need for grafts, along with the time and cause of failure, is shown in Table 1 (Fig. 4A-D).

Discussion

Many studies have analyzed details of the surgical technique for UKA and implants available, and the clinical results. However, studies reporting the causes and chronology of these failures, along with the implants needed during the revision surgery, are rare in the literature.⁴⁻¹⁴

Despite the low incidence of failure of modern unicompartmental arthroplasty, the personal impact, expenditure of financial resources and incidence of morbidity and mortality

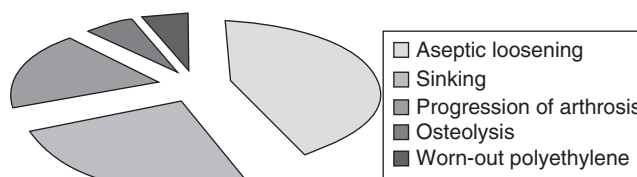


Fig. 3 – Distribution of late causes of UKA failure (n = 16).

Table 1 – Distribution of the implants used during the revision, numbers of cases and time and cause of failure.

Revision implant	No. of patients	Causes of failure	Time	Unicondylar implant
TKA	14	Aseptic loosening of component (7) Progression of arthrosis (3) Tibial collapse/sinking (2) Infection Pain	Early (6) Late (8)	Ominifit (12) MGalante (2)
TKA + autologous graft	5	Tibial collapse/sinking Femoral collapse/sinking (1) Aseptic loosening of 2 components (1)	Early (1) Late (4)	Omnifit (3) MGalante (2)
TKA + homologous graft	3	Femoral sinking (2) Osteolysis (1)	Early (1) Late (2)	Omnifit (3)
TC III (semi-constricted)	1	Progression of arthrosis (1)	Late (1)	MGalante
Not operated	1	–	–	–

relating to revision procedures make it necessary for surgeons to seek to understand the mechanisms that lead to occurrences of failure, so that these causes can be prevented and corrected.¹³⁻¹⁶

Data from the Swedish arthroplasty register, in which approximately 15,000 unicondylar implants were evaluated, showed that failure with a need for revision occurred in 7.7% of the patients. Aseptic loosening was identified as the main failure mechanism, in 43% of the revisions. Progression of the osteoarthritis was responsible for 26% of the cases of revision and was the second most prevalent cause. Worn-out polyethylene, mechanical failures and fractures represented 15% of the procedures for conversion to TKA.¹⁵

Our study analyzed surgical procedures performed using first, second and third-generation implants and at different times during the development of knowledge of this technique. Thus, it included some patients who underwent procedures with characteristics that do not express today's level of

technological development. Thus, the types of failure may have presented changes over the course of development of the technique.

In our series, component migration with sinking/collapse of the compartment was the main type of failure, in 33% of our sample. Most of the cases occurred in the tibial component. Our data are concordant with those of the study by Aleto et al.,²³ in which tibial collapse was identified in 47% of the cases of revision and also represented the most prevalent cause. However, this cause differs from the main failure mechanism identified in larger series.^{13-15,20-26}

In the Swedish register¹⁵ and Norwegian register,²⁶ collapse with sinking of the component occurred in less than 10% of the sample. However, aseptic loosening was the main cause of failure, in approximately 40% of the cases.

In our study, aseptic loosening of one or more components was the second most prevalent cause, and was identified in 30% of the revision surgical procedures. In analyzing a series with 15 years of survival, Foran et al.¹⁶ did not identify aseptic loosening as a cause of failure in their sample. However, Saragaglia et al.²⁷ identified aseptic loosening in 67% of their sample.

Several authors, such as Froimson et al.⁶ and Saragaglia et al.,²⁷ highlighted progression of osteoarthritis in compartments that had not come back to the surface as frequent alterations in radiographic examinations following unicompartamental arthroplasty, with a range of occurrence from 17% to 60%. However, the need for revision due to this cause was 3-12%. In our series, 15% of the indications for revision of a unicompartamental prosthesis occurred due to functional limitations caused by progression of osteoarthritis.

Froimson et al.⁶ emphasized that infection may be an early cause of failure or may occur later on and affect a smaller number of cases (not more than 10%). In our sample, infection was responsible for revision in two patients (8%), during the early period in both cases, which is therefore concordant with the data in the literature.

It was noted that a worn-out polyethylene component was the reason for revision in only one patient in our series. Therefore, our data are not concordant with those of the studies by Springer et al.¹⁴ and Levine et al.²² We believe that part of this difference can be attributed to differences in the manufacture

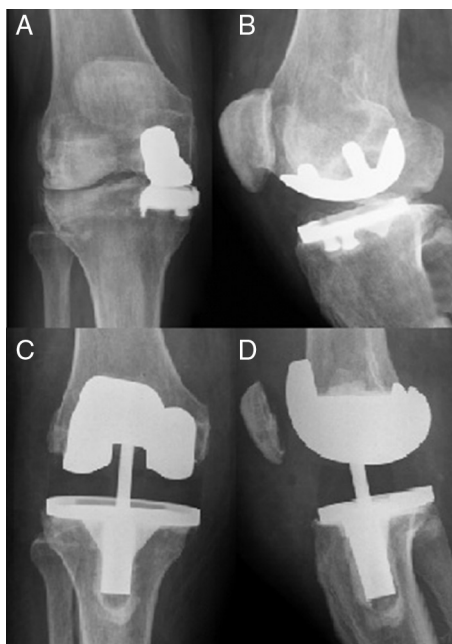


Fig. 4 – (A-D) Failure of unicompartamental arthroplasty revised using a semi-constricted implant.

and sterilization of polyethylene components from different manufacturers during the initial period of development of the technique.

UKA has the theoretical advantage of being technically easy to revise, with limited bone losses and without ligament insufficiency, which enables conversion to TKA with conventional implants. However, several authors have identified needs for bone grafting, metallic expanders and intramedullary nails, and to a lesser extent, a need for implantation of semi-constricted prostheses.^{20,27-29}

Barret et al.²⁰ studied failures in first-generation unicompartmental arthroplasty procedures and found that the cause of the revision was aseptic loosening of components in 55% of the cases and progression of osteoarthritis in 31%. Out of 29 conversions to total prostheses, 93% were to implants that preserved the posterior cruciate ligament (PCL). However, more than half of the series required bone grafts, metallic expanders or nails. The difficulties were attributed to underdeveloped implant design and limitations relating to selection of the patients who underwent UKA.

In a series published by Padgett et al.,²¹ bone defects requiring treatment were identified in 76% of the surgical procedures. These authors classified revision of unicompartmental prostheses as a procedure of technical difficulty similar to that of TKA revision.

Among revisions of 31 second-generation unicompartmental arthroplasty procedures published in a study by Levine et al.,²² defects that could be dealt with using autologous grafts were identified in 23% of the cases, while 19% of the bone defects had to be managed using metallic expanders and three patients required an intramedullary nail. All the revisions had been indicated due to worn-out polyethylene or progression of arthrosis.

A study on conversion of 32 modern unicompartmental implants conducted by McAuley et al.²⁴ showed that there was a need for autologous bone grafts in 31%, while in 25% of the cases the defect was managed using a metallic expander and, in 44%, implants with the addition of an intramedullary nail were needed.

Springer et al.¹⁴ highlighted that 68% of the patients who underwent conversion of third-generation UKA presented bone defects with a need for management using autologous bone grafts, while metallic expanders were used in 23%. Chou et al.²⁸ corroborated these data and found in their series that autologous bone grafts were used in 67% of the cases, while metal wedges were used as fillers in 33%.

In our sample, 61% of the revision surgeries were performed using conventional implants and without the addition of bone grafts. The bone defects were concentrated in the tibia and required autologous grafting in 22% of the surgical procedures (five cases) and homologous grafting in 13% (three cases). Management of bone defects using metallic expanders was not observed in our study.

Aleto et al.²³ and Springer et al.¹⁴ highlighted that the type of failure was a predictive factor for a bone defect during the revision surgery. This was proven in our series, in which migration or collapse of the medial compartment more frequently led to a need for bone grafting.

Several authors, such as Aleto et al.,²³ McAuley et al.,²⁴ Springer et al.¹⁴ and Lai et al.,¹⁸ did not identify any need for

homologous grafting for managing bone defects. However, as noted in our study, use of tissue bank grafts was also identified by Saldanha et al.¹³ and Otte et al.,²⁹ in 6% and 69% of their surgical procedures, respectively.

In our series, a need for an implant with a greater degree of constriction was seen in the case of one patient (5%) who presented progression of osteoarthritis in a lateral compartment, associated with valgus deformity and insufficiency of the medial structures. In the study by Saldanha et al.,¹³ although the anterior cruciate ligament was intact in 77% of their sample, semi-constricted implants were needed in 22% of the cases because of insufficiency of the medial collateral ligament.

Conclusions

We identified the following as causes of failure of unicompartmental arthroplasty: collapse (sinking) of one or more components, in 33% of the patients; loosening in 30%; progression of osteoarthritis in 15%; infection and pain in 7% each; and worn-out polyethylene and osteolysis in 4% each.

A need for bone grafting was seen in 35% of the patients. No metallic expanders or intramedullary nails were used, although a semi-constricted implant had to be used in one case because of ligament insufficiency.

The cause of failure was related to the need for bone grafting. Among the eight patients who needed bone grafts, the failure mechanism was migration/collapse of the compartment in six cases.

Conflicts of interest

The authors declare no conflicts of interest.

REFERENCES

1. McKeever DC. The choice of prosthetic materials and evaluation of results. *Clin Orthop*. 1995;6:17-21.
2. Marmor L. Unicompartmental arthroplasty of the knee with a minimum ten-year follow-up period. *Clin Orthop Relat Res*. 1988;228:171-7.
3. Cartier P, Chaib S, Vanvooren P. Unicompartmental prosthetic replacement of the knee. Apropos of 159 cases maximum follow-up of 10 years. *Rev Chir Orthop*. 1987;73:130-3.
4. Laskin RS. Unicompartmental tibiofemoral resurfacing arthroplasty. *J Bone Joint Surg Am*. 1978;60:182-5.
5. Insall J, Aglietti P. A five-seven year follow-up unicompartmental arthroplasty. *J Bone Joint Surg Am*. 1980;62:1329-37.
6. Froimson MI, Bloomfield MR, Sherman RA. Revision of the failed unicompartmental knee arthroplasty. *Semin Arthroplasty*. 2009;20:23-8.
7. Gioe TJ, Killen KK, Hoeffel DP, Bert JM, Confort TK, Schetelma K, et al. Analysis of unicompartmental knee arthroplasty in a community-based implant registry. *Clin Orthop Relat Res*. 2003;416:111-9.
8. Carlsson LV, Albrektsson BEJ, Regnér LR. Minimally invasive surgery vs conventional exposure using the Miller-Galante unicompartmental knee arthroplasty. *J Arthroplasty*. 2006;21(2):151-6.

9. Biswal S, Brighton RW. Results of unicompartmental knee arthroplasty with cemented, fixed-bearing prosthesis using minimally invasive surgery. *J Arthroplasty*. 2010;25(5):721-7.
10. Camanho GL, Viegas AC, Camanho LF, Camanho CR, Forgas A. Artroplastia unicompartmental no tratamento da osteoartrose medial do joelho. *Rev Bras Ortop*. 2007;42(9):285-9.
11. Newman J, Pydisetty RV, Ackroyd C. Unicompartmental or total knee arthroplasty. *J Bone Joint Surg Br*. 2009;91-B: 52-7.
12. Borus T, Thornhill T. Unicompartmental knee arthroplasty. *JAAOS*. 2008;16(1):9-18.
13. Saldanha KAN, Keys GW, Svard UCG, White SH, Rao C. Revision of Oxford medial unicompartmental knee arthroplasty to total knee arthroplasty – results of a multicentre study. *Knee*. 2007;14: 275-9.
14. Springer BD, Scott RD, Thornhill TS. Conversion of failed unicompartmental knee arthroplasty to TKA. *Clin Orthop Relat Res*. 2006;446:214-20.
15. Lewold S, Robertsson O, Knutson K, Lidgren L. Revision of unicompartmental knee arthroplasty: outcome of 1,135 cases from the Swedish Knee Arthroplasty study. *Acta Orthop Scand*. 1998;69:469-74.
16. Foran JR, Brown NM, Della Valle CJ, Berger RA, Galante JO. Long-term survivorship and failure modes of unicompartmental knee arthroplasty. *Clin Orthop Relat Res*. 2013;471:102-8.
17. Steele RG, Hutabarat S, Evans RL, Acroyd CE, Newman JH. Survivorship of the St Georg Sled medial unicompartmental knee replacement beyond ten years. *J Bone Joint Surg Br*. 2006;88:1164-8.
18. Lai CH, Rand JA. Revision of failed unicompartmental total knee arthroplasty. *Clin Orthop Relat Res*. 1993;287: 193-201.
19. Berend KR, George J, Lombardi AV. Unicompartmental knee arthroplasty to total knee arthroplasty conversion: assuring a primary outcome. *Orthopedics*. 2009;32(9):684.
20. Barret WP, Scott RD. Revision of failed unicompartmental knee arthroplasty. *J Bone Joint Surg Am*. 1987;69(9):1328-35.
21. Padgett DE, Stern SH, Insal JN. Revision total knee arthroplasty for failed unicompartmental replacement. *J Bone Joint Surg Am*. 1991;73A(2):186-90.
22. Levine WN, Ozuna RM, Scott RD, Thornhill TS. Conversion of failed modern unicompartmental arthroplasty to total knee arthroplasty. *J Arthroplasty*. 1996;11(7):797-801.
23. Aleto TJ, Berend ME, Ritter MA, Faris PM, Meneghini RM. Early failure of unicompartmental knee arthroplasty leading to revision. *J Arthroplasty*. 2008;23(2):159-63.
24. McAuley JP, Engh GA, Ammeen DJ. Revision of failed unicompartmental knee arthroplasty. *Clin Orthop Relat Res*. 2001;392:279-382.
25. Garner JS, Jarvis WR, Emori TG, Horan TC, Hughes M. CDC definitions for nosocomial infections. In: Olmsted RN, editor. *APIC infection control and applied epidemiology: principles and practice*. St. Louis: Mosby; 1996. p. A-1-20.
26. Furnes O, Espehaug B, Lei S. After unicompartmental and tricompartmental primary knee replacement with cement. *J Bone Joint Surg Am*. 2007;89:519-25.
27. Saragaglia D, Estour G, Nemer C, Colle PE. Revision of 33 unicompartmental knee prostheses using total knee arthroplasty: strategy and results. *Int Orthop*. 2009;33:969-74.
28. Chou DTS, Swamy GN, Lewis JR, Badhe NP. Revision of implant constraint on results of conversion of unicompartmental knee arthroplasty to total knee arthroplasty. *Orthopedics*. 2002;25:1353-7.
29. Otte KS, Larsen H, Jensen TT, Hansen EMB, Rechnagel K. Cementless ACG revision of unicompartmental knee arthroplasty. *J Arthroplasty*. 1997;12(1):55-9.